

BIOCHEMICAL AND HISTOLOGICAL STUDY OF *CYSTICERCUS TENUICOLLIS* OF SHEEP IN DUHOK PROVINCE

Saad M.Al-Bayati* Omar H.Azeez* Adnan M.Abdullah**

* Colege of Veterinary Medicine, University of Duhok, Duhok, Iraq

** College of .Agriculture, University of Duhok, Duhok, Iraq.

(Received 15 August 2010, Accepted)

Key words: *Cysticercus tenuicollis* , Biochemical , sheep.

ABSTRACT

Biochemical composition of *Cysticercus tenuicollis* (n=11) which isolated from local native sheep showed they have varied averages and ranges in compare with plasma level which reflected various stages of growth .Glucose, cholesterol, triglycerides total protein, uric acid, urea , Ca^{2+} , Mg^{2+} and creatinine levels were involved.

Histochemical study of parasite bladder revealed it composed from various kind of cells which are fibroblast , mesenchimal cell ,squamous epithelial like cell , and vacuolated undifferentiated cell with semi-gelatinous mucoid tissue.

INTRODUCTION

Cysticercus tenuicollis is the larval stage of the canine tapeworm *Taenia hydatigena* ,or thin – necked bladder worm which it presence has been reported in wild and domestic ruminants all over the world as a cosmopolitan in distribution (1 ,2) . *C. tenuicollis* is general seen attached to the omenta, the mesenteries or also in the liver (3) . The larval stage may caused an out break in there occurrence which may be responsible for a high degree of morbidity and mortality in livestock (4) and that takes place where migration through liver tissue and encysts on the peritoneal membrane. In general the parasite have veterinarian importance because of the economic losses due to condemnation of infected offal or meat (5) .

Previous study (6) work on some biochemical parameters in goats and pigs but not sheep , either the histological nature of larval stage of this parasite where they are targeted in this study for the first time in Iraq-Kurdistan area.

MATERIAL AND METHODS

Cysticercus tenuicollis bladders were collected from local slaughterhouse of Duhok province (n = 11) , photographed (fig.1) and transferred within cool box to biochemistry lab at vet. med. col./ Uni. Duhok .

Bladders washed with normal saline and the outer surrounding host fibrous capsule removed(7) to obtained the parasite bladder which lately treated for obtained there internal fluid with sterile disposable syringes gage 20 , then

transferred to non-heparinized vacutainer tube which cooled (4°C). This process done for each sample in combination with 5 ml of blood of each infected animals for prepare plasma to make suitable comparison.

The deranged parasite bladders trimming and pieces from each fixed with 10% formal saline for histological techniques (8).

Biochemical tests involved Glucose, Cholesterol, Triglyceride, Total protein, Uric acid, Urea, Calcium, Magnesium, and creatinine. These items investigated with traditional kits and by 3 replicates model (9).

The means and ranges of each samples of parasites bladders and plasma were compared with t-paired test through SPSS program.

RESULTS

Cysticercus tenuicollis bladders identified according to their feature where single scolex evaginated with fibrous capsule (fig. 1) according to references (9). This identification based on their host and site specificity (7).

Biochemical results (tab.1) showed that glucose has no significant difference but the range of it is wider in parasite bladders (2.635-9.152), Cholesterol reduced significantly ($P<0.01$) for parasite in both of mean and range but not for triglyceride. Total protein had the same manner of reducing ($P<0.01$). Uric acid and urea had slight difference but not significant for parasite bladders. The chosen minerals (Ca^{2+} and Mg^{2+}) showed higher significance difference ($P<0.01$) for parasite bladders, also for means and ranges. Lately, Creatinine differed but not in significant for parasite bladder.

The histological technique of parasite bladders which depend H&E stain showed that parasite bladder under low power of magnification (X10) showed multi layers tissues with distinguished marked figuration like zigzag limited layers aged by squamous like layer (fig. 2), and by higher magnification (X40, X100) these layer had seen to be composed from various undifferentiated cells (fig. 2) which may be fibroblast, mesenchymal cells, squamous epithelial like cell and vacuolated cell with semi gelatinous mucoid tissue which had seen to be non cellular in its nature.

DISCUSSION

Biochemical of this parasite study which done for the first time in local sheep of Duhok area reflected continuous independent growth of their host, this growth had various intervals period which could be observed by various ranges (tab.1). Also, the most reduced level of many of studied parameters reflected in some how kind of isomers of involved enzymes and that could be attributed to genetic developmental varieties.

Totally, Biochemical substance within *Cysticercus tenuicollis* could be important for metabolism, physiology, immunology and genetically with various isolates through all over the world as individual variation. This phenomenon observed in hydatid cyst of echinococcosis in human or animals (1,5). The study showed that parasite bladder fluid differ significantly ($p<0.01$) from host plasma which may be refer to host fibrous capsule function in control of transport across it.

This observation seen in previous study related with hydatid cyst of *Ecchinococcus granulosus* (10,11,12).

The histological observation confirmed for the first time that parasite had various specific cell which may related to the nature of this parasite where it

occupied the gastrointestinal tract which required epithelial cells especially squamous type as they protect and could do other sensory function, gelatinous nature also may related to embryonic stage of this parasite which lately permitted for specific development and growth specifically by undifferentiated cells, and at last the total nature of parasitic bladders have a wide range of similarities with known connective tissue and its contain of various cells, fibrous and other matrix components.

Table (1) : Biochemical values of *Cysticercus tenuicollis* fluid vs. plasma of infected sheep.

Parameters	<i>Cysticercus tenuicollis</i> fluid (n=11)		Plasma of infected sheep (n=11)		Units
	Mean±SE	Range	Mean±SE	Range	
Total protein	1.90±0.75	0.62-2.49	13.87±10.58**	3.42-18.07	gdL ⁻
Glucose	4.76±1.71	2.63-9.15	4.54±0.73	3.55-5.56	mmolL ⁻
Tot. Cholesterol	0.15±0.06	0.09-0.21	1.91±1.07**	0.37-3.72	mmolL ⁻
Triglyceride	0.17±0.10	0.00-0.37	0.11±0.06	0.02-0.20	mmolL ⁻
Uric acid	0.05±0.02**	0.01-0.08	0.005±0.001	0.004-0.006	mmolL ⁻
Urea	0.75±0.10	0.03-0.79	0.54±0.37	0.15-1.22	mmolL ⁻
Calcium	17.31±9.98**	0.56-68.08	5.98±3.42	1.53-9.55	mmolL ⁻
Magnesium	1.56±1.30**	0.30-3.91	0.56±0.43	0.07-0.74	mmolL ⁻
Creatinine	164.16±39.19	136.28-202.05	154.96±28.10	131.02-214.15	μmolL ⁻

** = P<0.01



Fig.(1) : *Cysticercus tenuicollis* bladder ,left higher arrow : parasite bladder; left lower arrow : single parasite scolex ; right thin arrow : parasite bladder ; right thick arrow : fibrous host capsule of parasite (Normal size in Formal saline 10%).

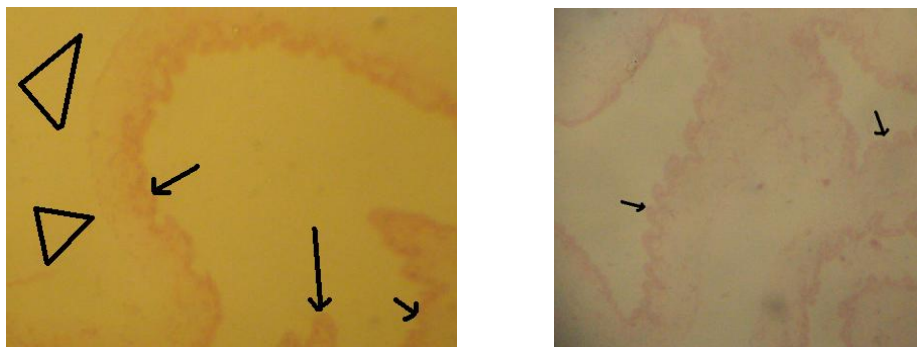


Fig.(1a): Histological composition of *Cysticercus tenuicollis* bladder:
Above left , arrows, zigzag squamous like layer, triangles a non cellular layer/
Above right, arrows zigzag multi branched layer (X10) H&E.

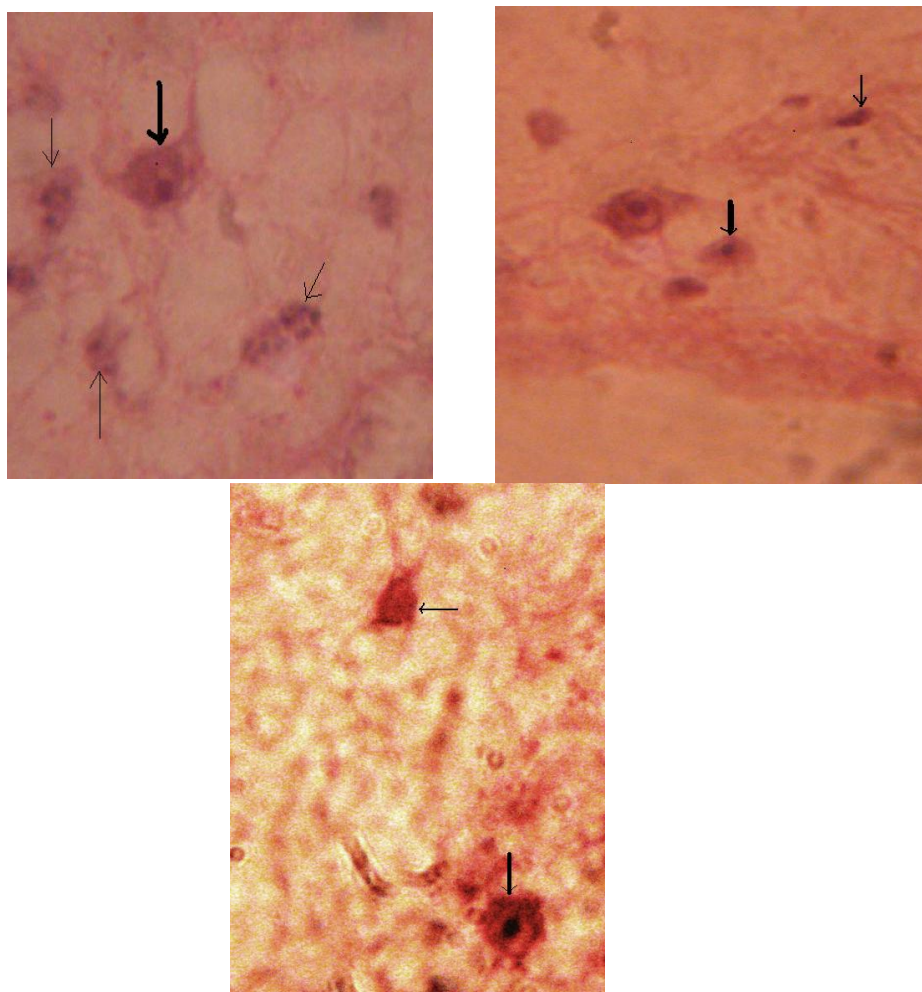


Fig.(1b): Histological composition of *Cysticercus tenuicollis* bladder:
Above left , ,thin arrow fibroblast like cell ,thick arrow mesenchymal cell/above
right,thin arrow fibroblast cell,thick arrow undifferentiated cell (X100) /down left
thick arrow fibroblast cell,thin arrow vacuolated cell /down right multi nucleated cell
in semi-gelatinous non cellular layer(X100) –all in H&E stain.

دراسة كيموحيوية ونسجية لطفي الكيسانية الغلالية (*Cysticercus tenuicollis*) في الضان لمحافظة دهوك

سعد محي حيدر البياتي¹ عمر حسن عزيز¹ عدنان محمد عبدالله²

كلية الطب البيطري ، جامعة دهوك ، دهوك ، العراق.
كلية الزراعة ، جامعة دهوك ، دهوك ، العراق.

الخلاصة

اظهر التركيب الكيموحيوي لطفي الكيسانية الغلالية (*Cysticercus tenuicollis*) لاثنا عشر منها
والمعزولة من الضان المحلية انها تتباين في معدلات ومديات اقيامها مقارنة بالتراكيز الملاحظة ببلازما
الدم مما يعكس مراحل النمو المختلفة لها. وتضمنت الدراسة تراكيز سكر العنب (Glucose) والشحمين
(Cholesterol) والكليريد الثلاثي (triglycerides) والبروتين الكلي (total protein) والحمض البولي (uric acid)
و اليوريا (Urea) وايوني الكالسيوم والمغنيسيوم والكرياتينين (creatinine).

واظهرت الدراسة النسيجية للمثانة الطفيلية (Parasitic bladder) انها تتكون من خلايا مختلفة مثل المولدة للاليف (fibroblast) و الخلايا الحشوية (mesenchimal cell) والشبيهة بالخلايا الحرشفية الطلائية (squamous epithelial like cell) والخلايا غير المتميزة الفجوية (vacuolated undifferentiated cell) مع انسجة مماثلة للمخاطية الجلاتينية (semi-gelatinous) (mucoid tissue).

REFERENCES

- 1- Radfar MH , Simin T and Mansooreh T (2005). Prevalence and morphological characterization of *Cysticercus tenuicollis* (*Taenia hydatigena*) From sheep and goat in Iran. Veterinarski Archiv. 75(6):469-476.
- 2- Payan-Carreira R , Silva F , Rodringues M and Dos Anjos Pires M (2008). *Cysticercus tenuicollis* in fetal structures : Reprod.Domest.Anim.43(6):764-766.
- 3- Kara M , Sarimehmetoglu HO and Gonene B (2005).The determination of immune reactive proteins in *Cysticercus tenuicollis* cyst fluid by SDS-PAGE and western blotting in sheep. Parasite 10(20):141-145.
- 4- Manfredi MT , Ghirardelli R and Zanzani S (2006). *Cysticercus tenuicollis* infection in a goat farm.Parassitologia 48(3):433-436.
- 5-Blazek K, Schramlov J and Hulanska D (1985).Pathology of the migration phase of *Taenia hydatigena* (Pallas,1766) Larvae . Folia Parasitol. (Praha) , 32(2):127-137.
- 6- Abidi SM , Nizami WA , Khan P , Ahmed M and Irshadullah M (1989). Biochemical characterization of *Taenia hydatigena cysticercci* from goats and pigs. J.Helminthol., 63(4):333-337.
- 7- Bowman DD , Iynn RC , ELerherd ML , AL Caraz A (2003). " Georgis Parasitology for veterinarian " 8th ed., Saunders , USA.
- 8- Kanek JJ , Harvey TW and Bruss ML (1997)." Clinical biochemistry of Domestic animals " 5th ed., Academic Press , USA.
- 9- Soulsby JP (1982). Arthropod , Helminth
- 10- Al-Zubaidy AB (1985). Chemical composition of hydatid fluid and germinal layer M.Sc. of *Ecchinococcus granulosus* from human and other intermediate hosts of Iraq. thesis , Col. Scien. Mosul Uni., Iraq.
- 11- Al-Ebadi FAM (1984). Inorganic composition of hydatid fluid and germinal layer of *Ecchinococcus granulosus* from human and other intermediate hosts of Iraq. M.Sc. thesis , Col. Scien. Mosul Uni., Iraq.
- 12- Bayati SM , Adnan NA, Omar AH and Abed SA (2010). Biochemical profile of *Echinococcus garulosus* of sheep in Duhok area.Iraqi J Vet.Science (Accepted).