

Clinical and epidemiological assessment of supracondylar humeral fractures in children in Alhusain teaching hospital

Wahby Ghalib Shaty, FJMS, CABM, MRCS*

ABSTRACT:

Supracondylar humeral fracture represents the commonest pediatric elbow fracture. It mostly occurs below the age of 10 years after simple fall on outstretched hand or on the elbow. The factors that contribute to its high frequency include weakness of the supracondylar area and the relative ligamentous laxity in children as well as the more liability to fall in this age group. It is a source of relatively high morbidity rate. Possible complications include neurovascular injury, compartment syndrome, joint stiffness and deformity. In this study we to assessed multiple epidemiologic factors including the crude number of cases over the period of time of the study, the fracture type according to displacement and rate of each possible complication. We also followed cases prospectively documenting the modality of treatment offered, the healing time, the way of dealing with complications and their prognosis. The output results of the study help in standardizing the orthopaedic handling of this fracture in our locality. This includes the proper assessment of the size of the problem and its complications and the best way of dealing with it.

* Lecturer, Department of Surgery, College of Medicine, Thiqr University

Introduction

Supracondylar humeral fracture represents the most common elbow fracture in children. It is the second commonest of all pediatric fracture. It is challenging and is associated with high complication rate. It occurs just above the humeral epicondyles. The peak incidence is below 10 years of age. Boys are classically more commonly affected. The commonest mechanism for this fracture is a fall on outstretched hand. Associating injuries are not uncommon especially distal radius and proximal humerus fractures.

Types: Extension type is the most common. It occurs because of a fall on outstretched hand (elbow extended). The pattern of displacement is in the form of posterior angulation of the distal fragment which also tilts and rotates medially in the majority of cases. The medial displacement is attributed to the pronated forearm position at time of falling and to the effect of the biceps muscle. Posterolateral displacement is less common. The latter is found to be more associated with risk of vascular and nerve injury. Flexion type injury is rare and occurs because of fall on the point of the elbow. It is characterized by anterior displacement.

Classification: The commonest classification in clinical practice is that set by Gartland and modified by Wilkins.

In type I, the fracture is not displaced and the anterior humeral line cuts the capitellum. In type II the fracture is displaced with the anterior humeral line doesn't intersect the capitellum. The hallmark of this type is that the anterior cortex is broken while the posterior one is still intact. This type is subdivided into 2 subtypes, A, with just angulation, and B, with angulation and malrotation. In type III, both cortices are broken with complete separation.

Early complications

Missed diagnosis: This occurs with undisplaced fractures due to failure to interpret the subtle XR signs. Useful resorts include an oblique XR view, XR of the opposite elbow and fat pad sign.

Nerve and vascular injuries: They occur because of either the force causing the fracture or that of manipulation. The commonest nerve injured is the anterior interosseous while the ulnar nerve is the most common to be injured iatrogenically. These complications usually follow benign course, however, serious nerve or vascular compromise can happen.

Compartment syndrome: It is uncommon event. However it is limb-threatening and predisposes for Volkmann's contracture.

Late complications: They include permanent nerve dysfunction, elbow deformity, joint stiffness, growth affection, heterotopic ossification nonunion and avascular necrosis.

Patients and methods

The age limit for inclusion in this study was considered to be 14 years. Children with elbow trauma attending the emergency and outpatient departments in Al-Husain Teaching Hospital in Nasiriya in the period from November, 1st, 2011 to April, 31th, 2012 were considered possible candidates. Full history taking, physical examination and XR images in indicated cases were done. Information forms were set for those found to have supracondylar humeral fractures. XR views were anteroposterior and lateral as standard for all patients. Oblique views and/or XR for the opposite side were done in query cases. For those patients with obviously normal XR, subtle signs (fat pad sign and anterior humeral line) were considered and correlated with the clinical picture as a standard for inclusion. Later in the follow up only

cases which proved to be true fracture ones were only included.

Results

During the period of the study which extended for 6 months (November, 1, 2011 to April, 31, 2012), the number of supracondylar humeral fractures in children registered in Al-Husain Teaching Hospital was 196. The follow up period ranged from 64-98 days with a mean of 84 days. The number of cases which missed follow up was 21 cases. The age of patients ranged from 2.3-12.6 years with a mean age of 6.1 year. The number of patients who presented within the first 24 hours was 163 while 33 patients reached our hospital after this time. Out of the total number, 122 were males making the male-female ratio 1.6:1. The total number of paediatric elbow trauma cases was 382. Table-1 and chart-1 show the frequency of the various diagnoses for the elbow trauma cases.

Clinical and epidemiological assessment of supracondylar of humeral fractures in children in Alhusain teaching hospital

89

Table-1 and chart-1: Frequency distribution of elbow trauma cases.

Diagnosis	Number of cases	Percentage
Supracondylar fracture	196	51.3%
Pulled elbow	54	14.1%
Lateral condylar fracture	34	8.9%
Soft tissue injuries	34	8.9%
Radial neck fracture	26	7.6%
Medial epicondylar fracture	19	5.0%
Proximal ulnar fracture	9	2.4%
Lateral epicondylar fracture	7	1.8%
Elbow dislocation	0	0.0%
Total	382	100%

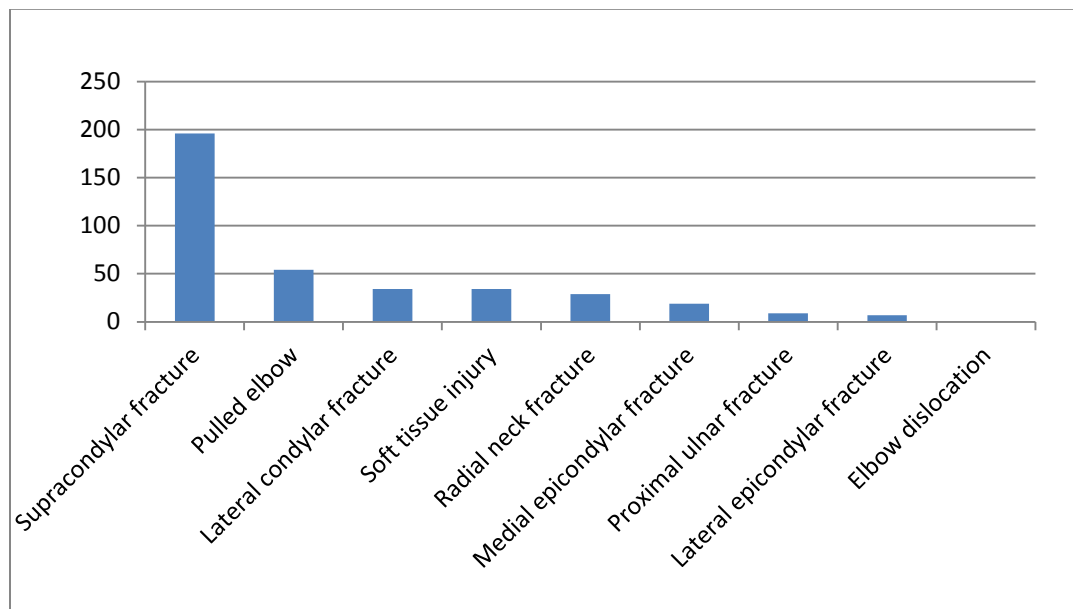


Figure-1: Frequency distribution of elbow trauma cases.

So, the incidence of the supracondylar fractures out of all elbow trauma cases was 51.3%; while it represents 66.6 % from all elbow fractures in children in this study. Of the total number of fractures, 102 affected the left side against 94 affected the right side making

very slight left side preponderance. Only one case was bilateral (both were Gartland IIB). The distribution of the different types of the fracture according to Gartland classification is emphasized in table-2 and chart-2.

Table-2: Number of cases according to fracture classification.

Fracture type	Number of cases	Percentage
Type I	54	27.6%
Type IIA	21	10.7%
Type IIB	37	18.9%
Type III	84	42.9%
Total	196	100.0%

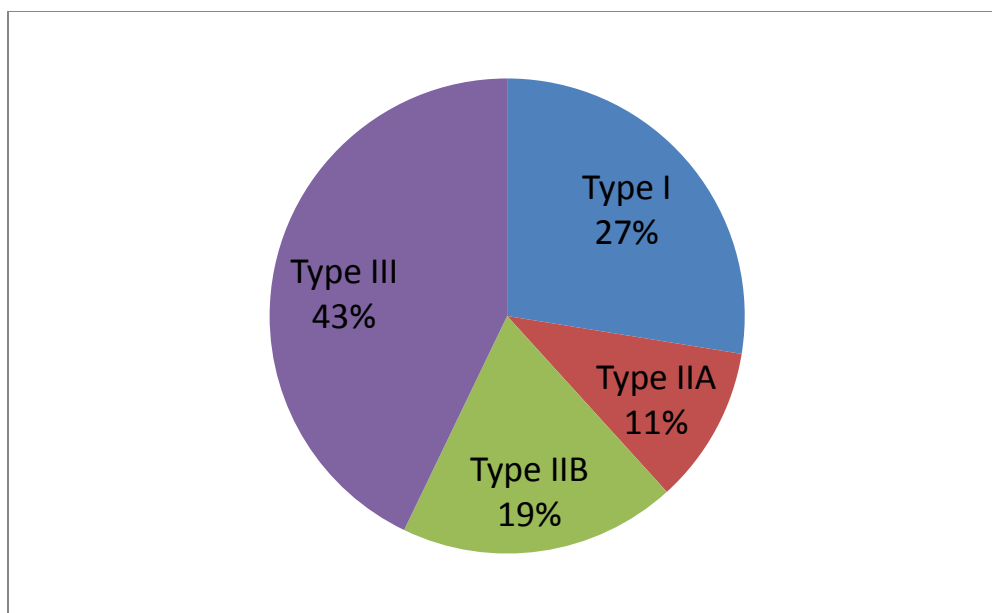


Figure-2: Percentage distribution of cases according to fracture classification.

The pattern of fracture displacement in types IIB and III was carefully assessed. We found that out of the total number of cases in these two categories, 85 (70.2%) showed clear posteromedial displacement in apposition to 36 (29.8%) cases showed clear posterolateral displacement. Regarding the mechanism of injury, in 144 cases, the parents gave history of falling from a height (68.4%). This included falling from a bed or the hand of a care-taker in children less than 4 years or falling down stairs, furniture or play-yard construct in children older. There were 19 cases of fall on the ground while

playing football. In 33 cases, the family could not recall a history of trauma mostly because there was no witness at time of injury. There were no cases sustained secondary to road traffic accident or direct trauma. From the total cases and basing on the XR evidence, we had only 5 cases (2.5%) of flexion type injury. In the majority of patients, the bone quality was normal while it was considered abnormal in 8 cases (4%) only so as to consider the fracture pathological. Table-3 shows the distribution of these pathological fractures according to the cause.

Table-3: Cases of pathological fractures.

Bone pathology	Number	Percentage
Rickets	2	25.0%
Osteogenesis imperfecta	2	25.0%
Bone cyst	2	25.0%
Bone tumour	1	12.5%
Bone infection	1	12.5%
Total	8	100.0%

Sixteen cases (8.1%) were associated with other fractures and these are clarified in table-4 which shows that the commonest associating fracture is that of the distal radius.

Table-4: Cases of associating fractures with supracondylar fracture.

Associating fractures	Number	Percentage
Contralateral distal radius	5	31.3%
Ipsilateral distal radius	3	18.8%
Proximal humerus	2	12.5%
Clavicle	2	12.5%
Radial neck	2	12.5%
Radius and ulna shafts	2	12.5%
Total	16	100.0%

In 35 patients out of the 163 patients who presented within the first 24 hours after the injury had occurred (21.4%), it was found that, at the initial presentation, the radial pulse was negative (on manual palpation). This phenomenon was in clear direct proportion to two factors namely the fracture displacement and the amount of swelling. However, in all cases, except one, there was no significant vascular jeopardy and the cases followed benign

course after fracture reduction and subsidence of swelling. It was very clear that capillary refilling sign was more reliable guide than distal pulse. In the only case in which there was clear-cut distal ischaemia the fracture type was Gartland III with skin puckering and posterolateral displacement. Vascular surgeon services were asked for and later the condition settled with operative fracture management while vascular exploration was normal.

Out of the total number, we had one case (0.5%) of compartment syndrome. The case was a referral from another hospital with 14 hours delay. The fracture was Gartland IIB with associating forearm both bones fracture (green stick) with tight slab and elbow immobilization in 110° flexion. Compartment syndrome of volar forearm was diagnosed on clinical picture and fasciotomy plus surgical

stabilization of fracture were effected with good subsequent prognosis. Open fracture seen in two cases of Gartland III fracture in the form of skin puncture by a bone spike (Gustilo I). They were treated by irrigation and antibiotics with no subsequent complications. Fracture-induced nerve injuries were found in 19 patients (9.7%). Table-5 shows the frequency of different nerve injuries.

Table-5: nerve injuries associating supracondylar fractures.

Nerve affected	Number of cases	Percentage
Median	12	63.2%
Ulnar	5	26.3%
Radial	2	10.5%
Total	19	100.0%

So, it is obvious that the commonest nerve injured was the median (12 cases, 63.2%). Four cases (21%) of nerve injuries were found with mild fracture displacement (Gartland IIA). The rest associated more severe displacement. The pattern of displacement in the cases of median nerve injury was posteromedial in 7 cases and posterolateral in 5 cases. Out of the total nerve injuries, 14 recovered within

2-3 months without intervention while 3 needed 5 months to spontaneously recover. In the remaining 2 cases, the nerve affected was the median and EMG showed no signs of recovery at 2 and 4 months interval. In both, exploration was needed and the nerves were found to be in continuity. Neurolysis was done with satisfactory results. We found 14 cases of iatrogenic nerve injuries. Six of these occurred

after closed manipulation. So, the risk of manipulation-induced palsy is $6/142=4.2\%$. The nerve affected was the

median in 4 and the ulnar in 2 cases. In 4 cases the condition was discovered late(>10 days) and it was associated with good prognosis while in the other 2 cases nerve affection was discovered immediately and ORIF was done with nerve exploration; there was no anatomic nerve affection and the prognosis was good. Iatrogenic ulnar nerve injury post-medial pinning occurred in 8 cases (so risk of iatrogenic surgical ulnar nerve injury is $8/60=13\%$). In 6 out of these, the nerve was not explored before pinning. In 6 cases the condition was discovered early and was treated by nerve exploration(where it was found that the nerve was penetrated in 4 cases and tethered in 2) and pinning in another place. In the remaining 2 cases the condition was discovered late(>10 days)and was treated by just pin removal. The long term follow up of both groups showed good-very good recovery with only one case needed neurolysis in the group of early removal and exploration. Regarding the definitive management and subsequent events, they can be summarized as it follows. All cases of Gartland I fractures were managed by POP cast immobilization and follow up. The healing time ranged from 18 to 26 days (mean 23 days). After cast removal, 43 patients were found to have good range of movement. These needed only

home physiotherapy. Eleven patients were found to have more limitation of movement which ranged from 20-40 degrees. However, they showed very good response to physiotherapy. Factors which were found to be related to the prognosis of joint motion are age (the younger the better the prognosis), initial swelling and the period of immobilization. All patients in the category of Gartland IIA were treated by closed manipulation (1-2 trials) and POP casting. Healing time ranged from 21-28 days (mean 26 days). Half of cases needed home versus formal physiotherapy and all showed very good range of movement. Regarding cases of Gartland IIB fracture, the protocol was to try closed manipulation twice before considering the patient eligible for open reduction. Closed reduction was successful in 28 cases out of the total number of 37 (75.6%) while open reduction was needed in the remaining 9 cases. The healing time ranged from 24-30 days (mean 28days). Most patients needed formal physiotherapy. For patients with Gartland III group, all of them underwent one trial of closed reduction and this was found to be successful in 29 cases (34.5%). The rest of patients were treated by open reduction and pin fixation. The range of the healing time in the subset treated closed was 24-30 days with mean of 28 days while it was 26-32 and 30 days respectively in the group of open reduction. All patients needed formal

physiotherapy (5-12 sessions, mean 7). The majority gained good to very good range of movement. We had 12 patients with persistent loss of an average 7 degrees of movement. We found that in this group of patients the main common point was the lack of optimum restoration of the shaft-condylar angle to the accepted 30-35 degrees. However there was good gradual improvement in the subsequent follow up. All those patients who needed open reduction were operated via posterior approach. Pinning was achieved by medial and lateral Kirschner wires. We had 3 infection cases out of the total number of those who underwent ORIF (making the incidence of infection after this procedure 4.6%). This does not take in consideration pin-track infection. All the cases resolved with conservative treatment. During follow up we found one case of myositis ossificans. It occurred following Gartland IIB fracture treated operatively and subjected to aggressive physiotherapy. The ossification occurred in the brachialis muscle. The case was followed for up to

4 months till the cessation of this study and it showed persistent pain and limitation of movement. We did not have any case of nonunion or avascular necrosis. Regarding the latter complication, it is recommended to extend the follow up period to detect it as it is a late complication. During the period of follow up, we registered 12 cases of cubitus varus deformity (6.8% after excluding cases which missed follow up). We expect the number to be slightly higher if follow up period is to be extended. The carrier angle for these cases ranged from -8 to -18 degrees. In 8 cases, there was inadequate initial correction of medial angulation and rotation. The total number of cases in which medial be inadequately corrected was 27. This makes the risk of subsequent cubitus varus in this group 29.6%. Out of the total number of cubitus varus cases, 7 were treated originally by closed reduction and cast and 5 were treated by by ORIF. Four cases were associated with hyperextension. There was no improvement in deformity over time

Discussion

Supracondylar fractures were found in this study to represent 51.3% out of all paediatric elbow trauma cases and 66.6% of all paediatric elbow fractures. Similar prevalence rates were retrieved

from other studies(1). The average age of occurrence was found to be 6.1 year (2.3-12.6 year). This also accords figures in similar studies (2). The high frequency of these fractures in the immature

skeleton is explained by the greater likelihood of falls, general ligamentous laxity, weak bone structure in the supracondylar area and joint position of hyperextension. Although we found that males outnumbered females (1.6:1), recent publications imply more female affection reflecting more indulgence in athletic activities (3,4,5). The left side was found to be affected more in accordance to most other studies (3,4,5). This can be explained by the slightly weaker muscular strength on the nondominant side making the elbow more vulnerable. Table-2 shows that the commonest type is Gartland III (42.9%). This is not accurate prevalence as referral cases to Alhusain hospital usually involve the more severe cases while simpler cases are managed in peripheral hospitals and clinics. There is no consensus among various reports regarding the relative incidence of fracture types although many found that Gartland II is more common (6,7). In most series, it was found that the distal fragment displaces in posteromedial direction in approximately 75% (8). Our figure was 70.2%. This is attributed to the axis of the biceps muscle which lies medial to the axis of the humerus as well as to the position of pronation at the moment of injury. The significance of the mediolateral displacement is that it determines which soft tissue structure is at risk. With lateral displacement the median nerve and brachial artery are at

more risk. This explains why we found that out of the 12 cases of median nerve injury, 5 were associating lateral displacement despite that the latter mode of displacement was found in less than one third of cases. In majority of cases, the mechanism of injury was falling from a height on outstretched hand (68.4%). It is the commonest injurious force that children in the affected age group may sustain. Only in few cases (8), the bone quality was considered abnormal as shown in table-3; so, mostly, this is a fracture of normal bone. In table-4, it is clear that in minority (8.1%) of cases, there is an associating fracture and the commonest is that of the distal radius; so, it is worth remembering to check for another skeletal affection. In the context of clinical evaluation, it was found that the distal pulse was negative in 21.4%. The figures were lower in other studies (9,10,11,12). However, in all studies it was found that vascular insufficiency that requires surgical intervention is rare (1-2%). We had only one case (0.5%) of compartment syndrome. The contributory factors were the considerable fracture displacement, delay of presentation, associating forearm fracture and immobilization in excessive flexion. Nerve palsy was found in 9.7% of cases and the commonest nerve affected was the median (63.2%). Figures in other studies ranged between 8-20% and again the median was the commonest (10,13,14). This can be

explained by the closed vicinity of the nerve to the medial spike of the proximal fragment specially with posterolateral displacement. Spontaneous recovery occurred in 89.4% of cases within 5 months while exploration revealed intact nerve in the 2 cases that needed exploration and neurolysis. Post-closed manipulation palsy occurred in 4.2% with the median and ulnar nerves being affected. The overall prognosis was very good regardless of time of discovery and way of management. Post-ORIF ulnar nerve palsy occurred in 13%. The most important factor appeared to be failure to explore the nerve in the context of operative fixation. In most cases the condition was discovered early and managed by exploration and re-pinning. However, the overall prognosis was good including the cases of delayed recovery and those in which the pin was found to penetrate the nerve. Regarding fracture management lines and healing, we can set several notes. The healing time ranged from average 20 days in Gartland type I to 30 days in type III. This discrepancy can be explained by difference in amount of displacement and soft tissue injury. All cases of type I needed only cast immobilization and follow up for proper time. For this category almost only home physiotherapy was adequate for rehabilitation. All cases of type IIA fractures responded to conservative treatment involving maximum 2 trials of

closed reduction. For cases of type IIB, the success rate of closed reduction was 75.6% of maximum 2 trials. Conditions which appeared to be associated with failure of closed reduction included delay of presentation, soft tissue swelling and faulty maneuver. In type III, closed reduction was less successful (34.5%) and this is attributable to the lack of the helpful effect of the posterior periosteal hinge. As severity of displacement increased, more sessions of physiotherapy were needed. However, the overall prognosis of joint mobility was very good. One important point determining the joint mobility was the restoration of normal shaft – condylar angle. Internal fixation was achieved via posterior approach. In recent years there was a lot of evidence recommending lateral and anterior approaches as they result in less risk of joint stiffness (15).

We used only the medial and lateral pinning technique and we did not assess the difference from the two lateral pins technique although most of studies mention that the former one is more stable (16,17,18,19). We did not have any cases of nonunion or avascular necrosis although some cases are reported in the literature (20). Being a metaphyseal fracture, these complications are unlikely. We found the incidence of cubitus varus deformity to be 6.8%. The incidence was higher in other studies averaging about 15% (21,22,23). This discrepancy may be

attributed to the short period of follow up. The most factor which was found to be associated with this complication was failure to correct medial displacement. So it is mostly not a result

of a growth plate affection. The incidence was significantly higher with cases treated closed rather than by ORIF.

References

- 1-Lins RE, Simovitch RW, Waters PM. Pediatric elbow trauma. Orthop Clin North Am 1999; 30:119.
- 2.Kasser JR, Beaty JH. Supracondylar fractures of the distal humerus. In: Rockwood and Wilkins' Fractures in Children, 5th, Beaty JH, Kasser JR. (Eds), Lippincott Williams & Wilkins, Philadelphia 2001. p.577.
3. Cheng JC, Lam TP, Maffulli N. Epidemiological features of supracondylar fractures of the humerus in Chinese children. J Pediatr Orthop B 2001 10(1):63-67.
4. Farnsworth CL, Silva PD, Mubarak SJ. Etiology of supracondylar humerus fractures. J Pediatr Orthop 1998 18(1):38-42.
5. Houshian S, Mehdi B, Larsen MS. The epidemiology of elbow fracture in children: analysis of 355 fractures, with special reference to supracondylar humerus fractures. J Orthop Sci 2001 6(4):312-315.
- 6-Hart, Grottkau, Rebello, Albright. Broken bones : common pediatric upper extremity fractures – part II. Orthopaedic nursing. 2006; 25 : 311.
- 7.Lord B, Sarraf KM. Paediatric supracondylar fractures of the humerus: acute assessment and management. British Journal of Hospital Medicine. 2011;72(1):M8
8. Wilkins KE, Beaty J. Fractures in Children. Philadelphia: Lippincott-Raven, 1996.
9. Bristow WR. Myositis ossificans and Volkmann's paralysis: notes on two cases, illustrating the rarer complications of supracondylar fracture of the humerus. Br J Surg 1923 10:475-481.
10. Campbell CC, Waters PM, Emans JB, et al. Neurovascular injury and displacement in type III supracondylar humerus fractures. J Pediatr Orthop 1995 15(1):47-52.

11. Copley LA, Dormans JP, Davidson RS. Vascular injuries and their sequelae in pediatric supracondylar humeral fractures: toward a goal of prevention. *J Pediatr Orthop* 1996 16(1):99-103.
12. Schoenecker PL, Delgado E, Rotman M, et al. Pulseless arm in association with totally displaced supracondylar fracture. *J Orthop Trauma* 1996 10(6):410-415.
13. Sairyo K, Henmi T, Kanematsu Y, et al. Radial nerve palsy associated with slightly angulated pediatric supracondylar humerus fracture. *J Orthop Trauma* 1997 11(3):227-229.
14. Mehlman CT, Crawford AH, McMillion TL, et al. Operative treatment of supracondylar fractures of the humerus in children: the Cincinnati experience. *Acta Orthop Belg* 1996 62(Suppl 1):41-50.
15. . [Gennari JM](#), [Merrot T](#), [Piclet B](#), [Bergoin M](#). Anterior approach versus posterior approach to surgical treatment of children's supracondylar fractures: comparative study of thirty cases in each series. *J Pediatr Orthop B*. 1998 Oct;7(4):307-13
16. Zions LE, McKellop HA, Hathaway R. Torsional strength of pin configurations used to fix supracondylar fractures of the humerus in children. *J Bone Joint Surg (Am)* 1994; 76(2):253-256.
17. Lee SS, Mahar AT, Miesen D, et al. Displaced pediatric supracondylar humerus fractures: biomechanical analysis of percutaneous pinning techniques. *J Pediatr Orthop* 2002 22(4):440-443.
18. Onwuanyi ON, Nwobi DG. Evaluation of the stability of pin configuration in K-wire fixation of displaced supracondylar fractures in children. *Int Surg* 1998 83(3):271-274.
19. Skaggs DL, Hale JM, Bassett J, et al. Operative treatment of supracondylar fractures of the humerus in children. The consequences of pin placement. *J Bone Joint Surg (Am)* 2001 83A(5):735-740.
20. Wilkins KE, Beaty J. *Fractures in Children*. Philadelphia: Lippincott-Raven, 1996.
21. Edman P, Loehr G. Supracondylar fractures of the humerus treated with olecranon traction. *Acta Chir Scand* 1963 126:505-516.

22. Fowles JV, Kassab MT. Displaced supracondylar fractures of the elbow in children. A report on the fixation of extension and flexion fractures by two lateral percutaneous pins. J Bone Joint Surg (Br) 1974 56B(3):490-500.
23. Hoyer A. Treatment of supracondylar fracture of the humerus by skeletal traction in an abduction splint. J Bone Joint Surg (Am) 1952 24-A-3:623-637.

الكسر فوق اللقمة لعظم العضد في الاطفال. دراسة لتقييمه من الناحية الوبائية والسريرية في مستشفى الحسين(ع)
التعليمي في الناصرية

الدكتور وهبي غالب شاتي

مدرس في قسم الجراحة, كلية الطب, جامعة ذي قار

ملخص البحث

يُعتبر الكسر فوق اللقمة لعظم العضد أكثر كسور المرفق شيوعاً لدى الاطفال. وغالباً ما يحصل في الفئة العمرية التي تكون دون سن العشرة سنوات وذلك من جراء السقوط البسيط على كف اليد المبسوطة او على المرفق. ان العوامل التي تساهم في كثرة حصوله تشمل ضعف هذه المنطقة العظمية من الناحية التشريحية اضافة لوجود رخاوة نسبية للاربطة وكون الطفل اكثر عرضة للوقوع في هذه السن. ان هذه الاصابة تعتبر مصدراً للكثير من المضاعفات المبكرة والمتأخرة حيث تشمل اصابات الاعصاب والاعوية الدموية, متلازمة الحيز, تيبس مفصل المرفق وتشوه الساعد. في هذه الدراسة قمنا بتقييم العوامل احصائية ذات العلاقة بما في ذلك عدد الحالات الواردة الى مستشفى الحسين(ع) التعليمي خلال فترة الدراسة وكذلك نوع الكسر ومعدل كل من المضاعفات المحتملة وغيرها. ومن خلال متابعة هذه الحالات قمنا بتوثيق الاساليب العلاجية المتبعة وفترة الشفاء وكذلك حدوث وتطور المضاعفات المصاحبة وطريقة التعامل معها. ان نتائج هذه الدراسة تفيد في وضع الاسس المعيارية للتعامل مع هذه الاصابة في منطقتنا بما في ذلك ادراك حجم هذه المشكلة والمضاعفات الناجمة عنها وفضل الاساليب للتعامل معها.