

## Use of Infrared Light to Improve Breast Sonographic images

*Issa M. Kadhim\**

*Salma A. Redha\**

Received 20, December, 2012

Accepted 11, March, 2014

### Abstract:

It is well known that sonography is not the first choice in detecting early breast tumors. Improving the resolution of breast sonographic image is the goal of many workers to make sonography a first choice examination as it is safe and easy procedure as well as cost effective. In this study, infrared light exposure of breast prior to ultrasound examination was implemented to see its effect on resolution of sonographic image. Results showed that significant improvement was obtained in 60% of cases.

**Key words:** breast sonography, infrared heating, image processing

### Introduction:

Early detection of malignancies, including breast cancer is the aim of every imaging modality in order to get complete recovery. Mammography due to its ability to detect microcalcifications is still superior to sonography in early detection of breast carcinoma. But mammography is painful to some degree or another and has limitations in child bearing age women due to X-radiation exposure. Many workers are continuously working to improve quality of sonographic images in general and for breast condition in particular[1].

Some of the new technologies that have been developed recently or will become available in the near future are harmonic imaging, ultrasound contrast agents, elastography, sonoelastography, two-dimensional transducer arrays, and three-dimensional breast ultrasound [4].

Contrast Enhanced ultrasound does not add additional information to B-mode ultrasound in differentiating breast lesions, but it is a promising tool for evaluating the response to pre-surgical chemotherapy of breast cancer lesions[2][5].

Concerning sonography and thinking that exposure of breast to heating before examination may improve image contrast, therefore, getting better image to increase the sensitivity of sonography, a procedure using infrared radiation as a heating source is proposed in this work.

### Materials and Methods:

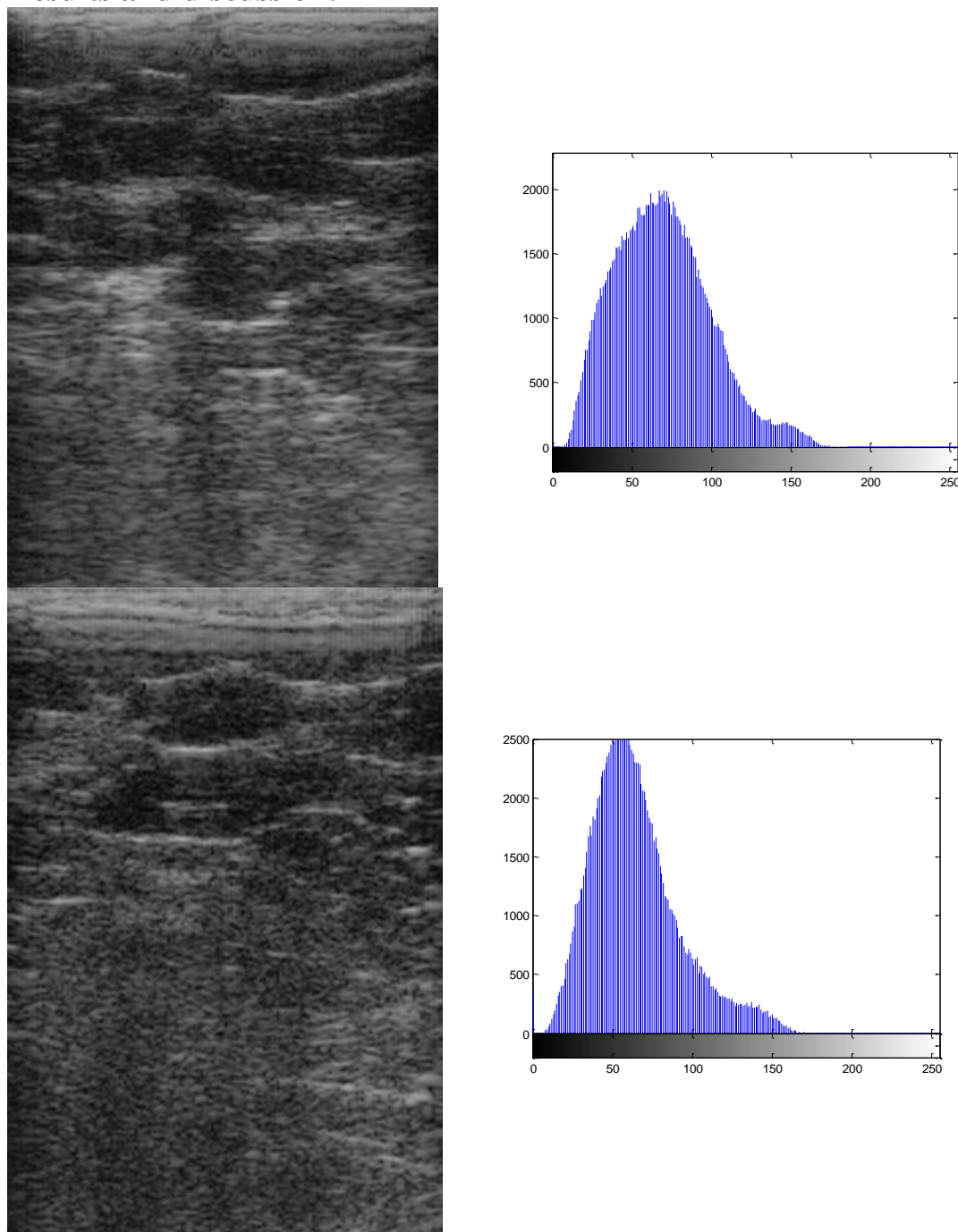
Seven randomly selected female individuals were included in this study. Breast in every female was exposed to infrared radiation by using A lamp ((Beurer infrared lamp 100 Watt)) until she feels the area becomes too hot (Duration was 3-5 minutes depending on individual tolerance). Breast was examined immediately before and after heating using Emperor portable sonographic equipment with a 7.5MHz linear probe. The gain of machine was kept constant at the same level throughout the examination time of each woman as well as all other adjustable variables. This was an essential condition so that any difference in reflectivity of breast tissues can be noticed and eventually can be extracted from histograms.

\*Department of physics, College of Science for Women, University of Baghdad.

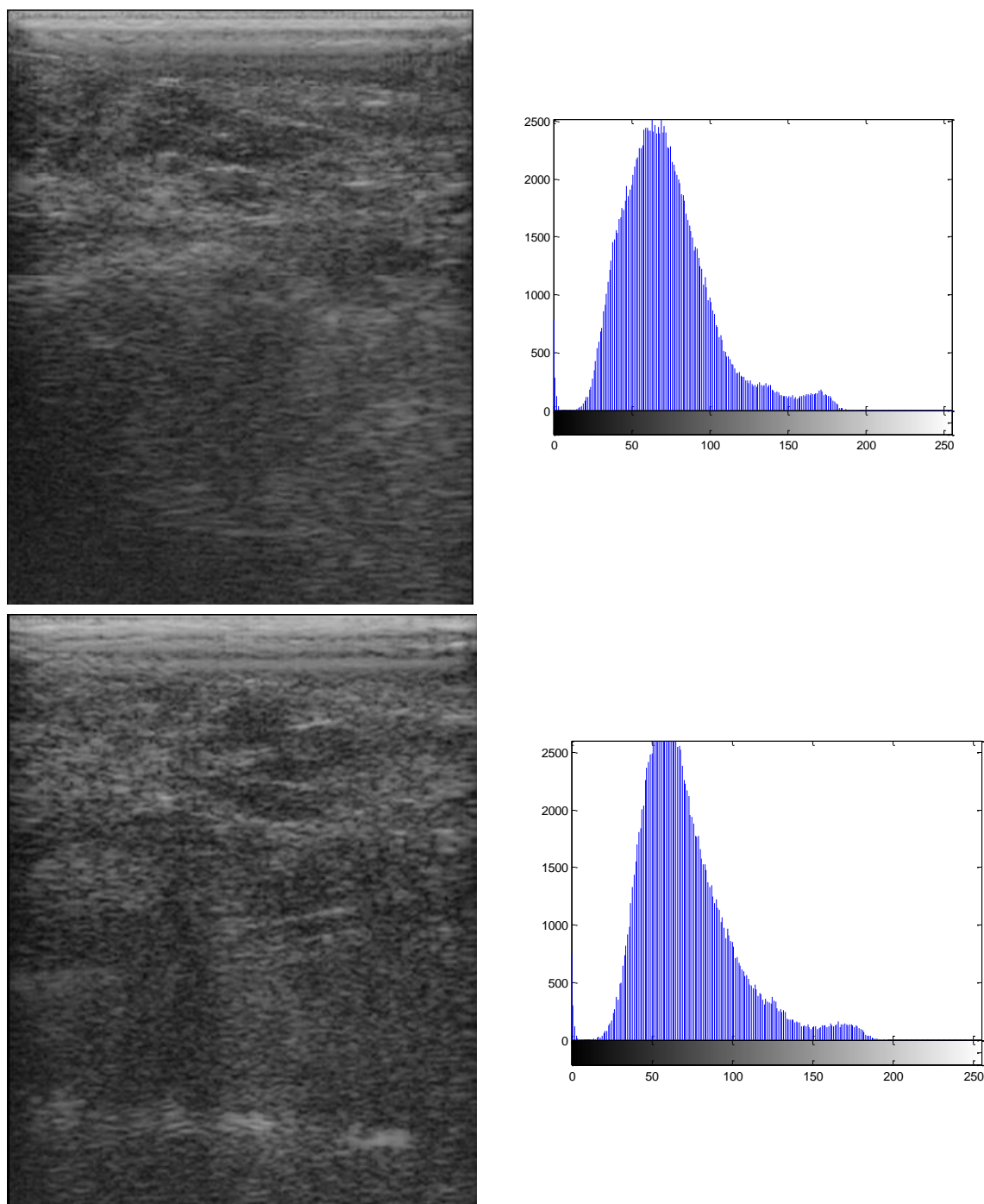
These couples of breast sonographic images were analyzed by computer program (Matlab version 7). Histogram graphs were obtained for these images (two for each breast before and after heating). From these histograms, Mean, variance and standard deviation were calculated for each image. These parameters of images before radiation

were compared with that of images after exposure. The histogram plot represents the frequency of pixel brightness against the number of gray levels as can be seen from the Matlab simulated plots. This forms a tool for segmentation of a digital mammogram [3].

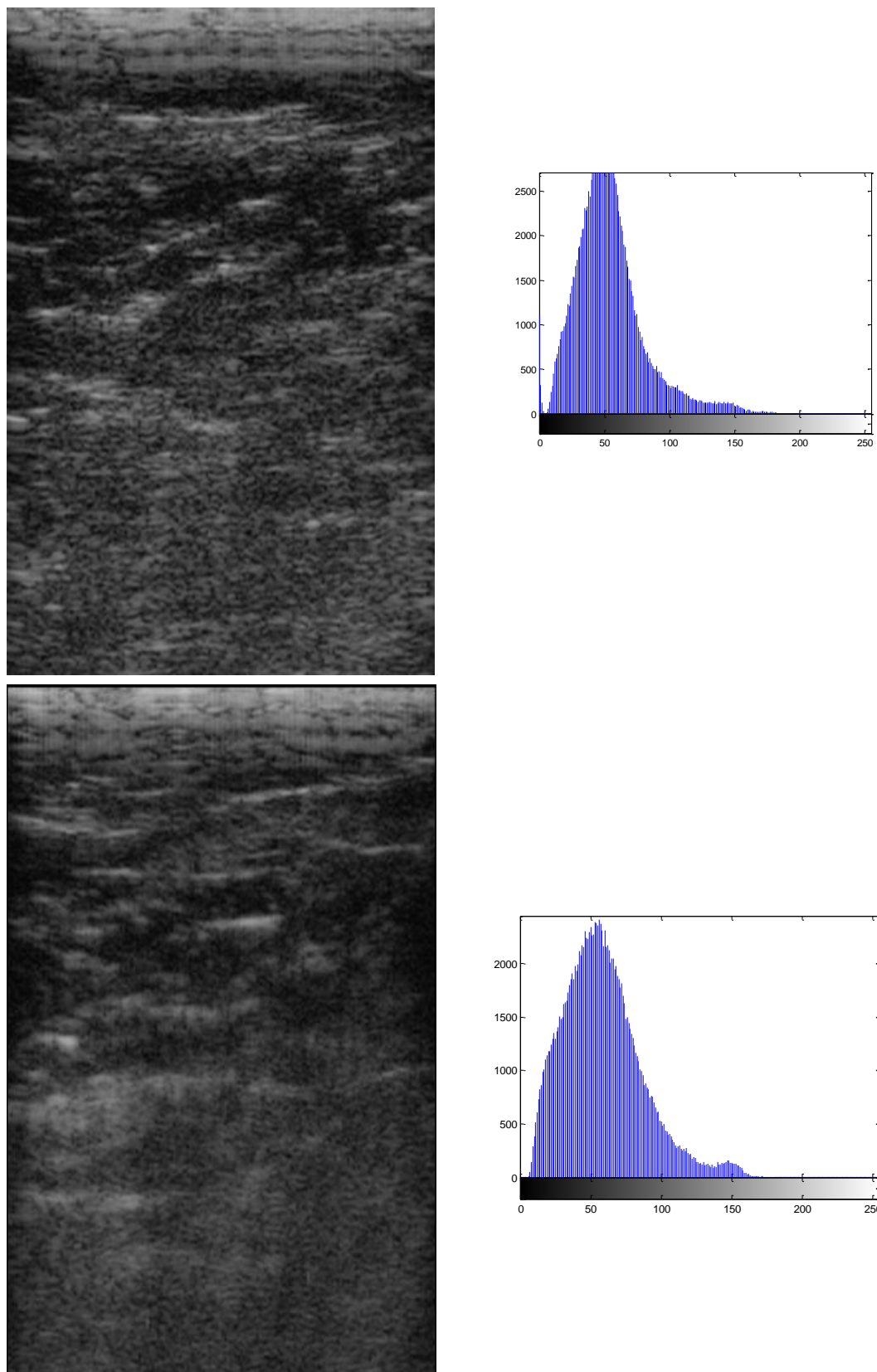
### Results and discussion:



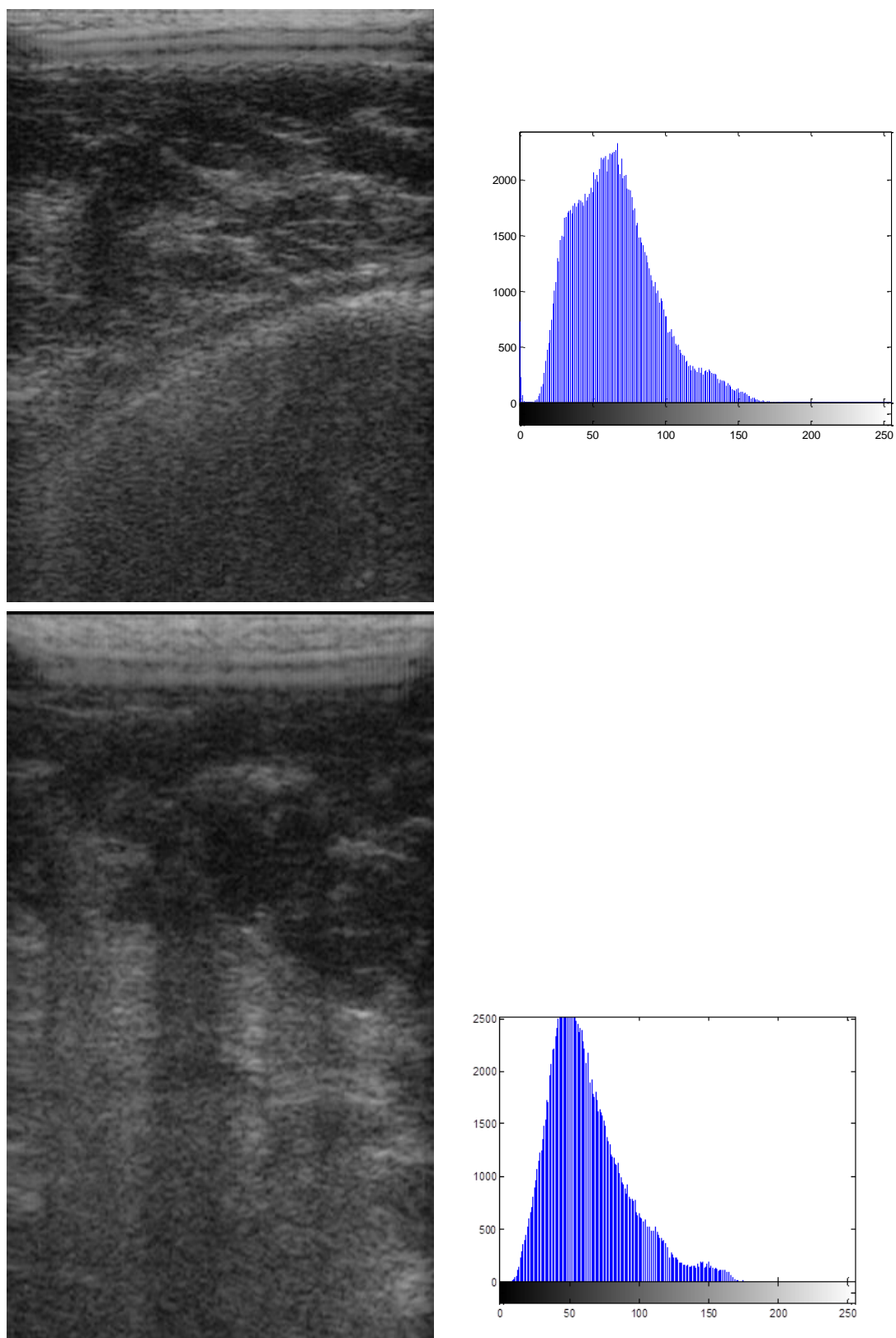
**Figure1: (Patient1) before and after exposure with corresponding histograms**



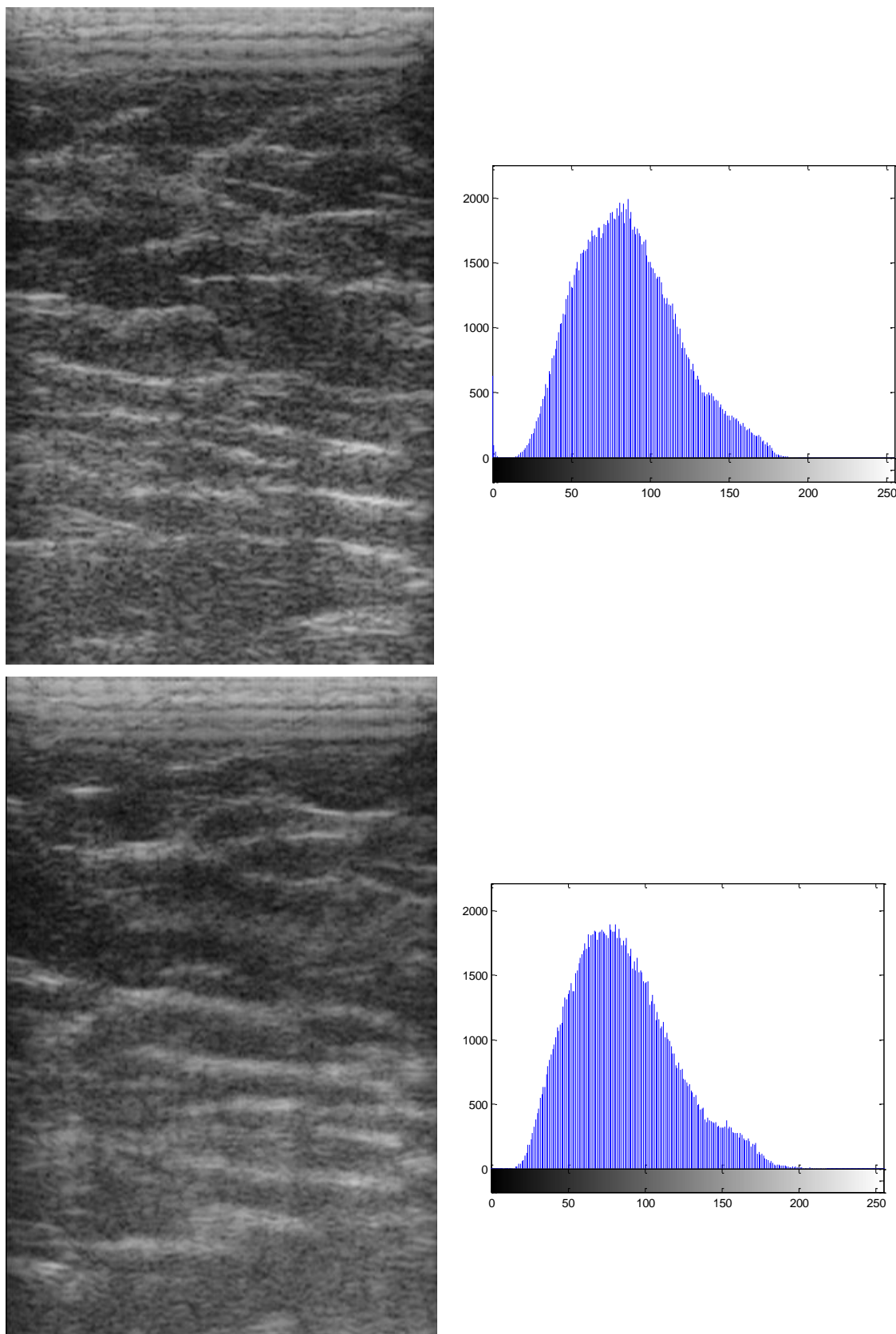
**Figure2: (Patient2) before and after exposure with corresponding histograms**



**Figure3: (Patient3)before and after exposure with corresponding histograms**

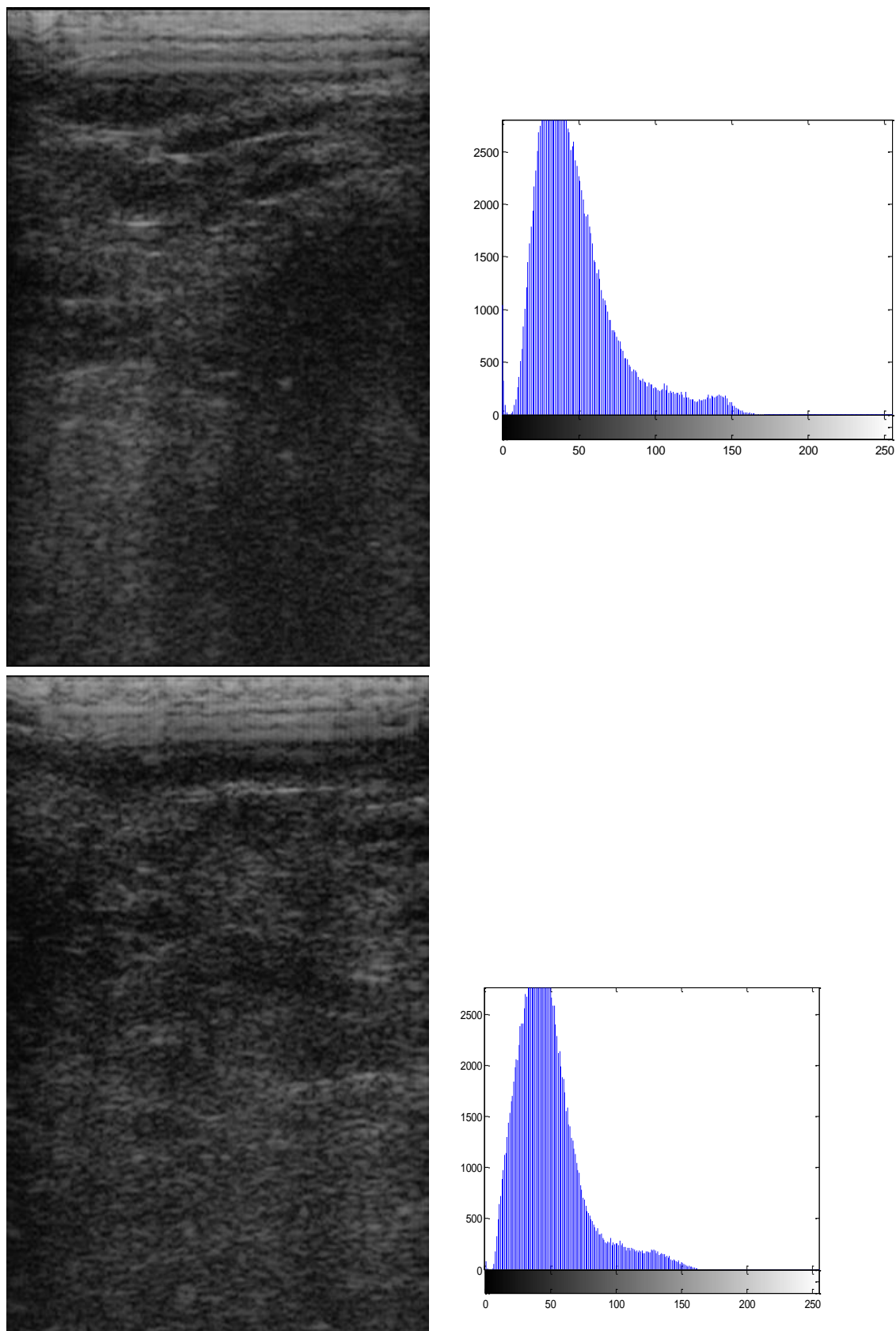


**Figure4: (Patient4) before and after exposure with corresponding histograms**

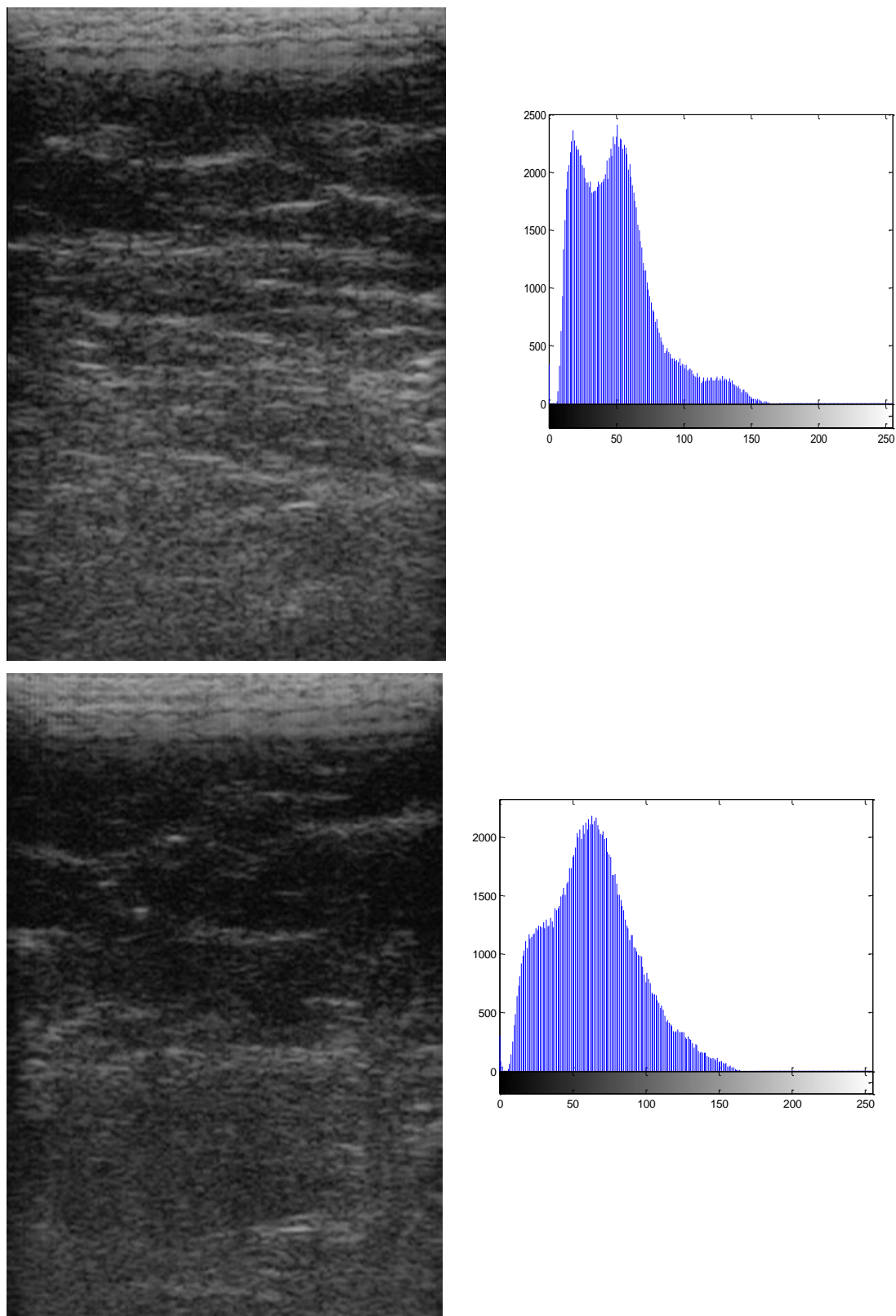


**Figure 5 : (Patient5) before and after exposure with corresponding histograms**





**Figure 6 : (Patient6)before and after exposure with corresponding histograms**



**Figure 7 : (Patient7) before and after exposure with corresponding histograms**



**Table 1: Standard deviation and mean of histograms calculated by using Matlab program.**

Figure number	Standard deviation		Mean	
	Before	After	Before	After
1	36.10	37.18	67.15	68.52
2	28.50	28.80	19.83	40.16
3	26.18	29.00	56.11	59.43
4	27.70	29.80	53.80	53.90
5	26.10	29.69	49.51	55.80
6	27.70	30.90	57.50	58.20
7	26.40	27.70	48.80	48.50
8	33.80	32.90	70.48	66.25
9	29.27	31.72	72.70	72.33

Each figure of the above corresponds to one individual, with two sonographic images, the first before infrared exposure and the second is after exposure. Each image has a histogram adjacent to it.

By visual examination of sonographic images, it can be noticed that most of them showed increased echogenicity of the slightly echogenic tissues while the hypoechoic parts remain the same. When these images are examined by Matlab, 60% of them showed increased variance and standard deviation. This supports the visual examination impression that the applied procedure of sonography increases the contrast of sonographic images. It can be said that heating of the examined part has increased the reflectivity of the already reflective tissue and has no effect on the nonreflective one like water. Physiologically speaking heating should induce hyperemia and consequently the exposed tissue becomes edematous. This means that there should be an increase in the water content of that exposed organ. So it can be hypothesized that microedema that is induced by infrared radiation increased the reflectivity of echogenic tissues. On the other hand, hypoechoic tissue has good water content, and any increase of its water due to heating should further decrease reflectivity.

This may explain the increased difference (contrast) of the after exposure images. According to this, it can be expected that microcalcifications of breast cancer can be better visualized, if the examined breast is exposed to infrared heating prior to sonography. This is an explanation of the above results, but there is another possibility: Any part of the human body exposed to heating becomes hyperemic at the beginning then with continuous exposure it becomes dry. This dryness may lead to condensation of exposed tissue resulting in increased difference in reflectivity of tissues according to their water content. So an increase in contrast is noticed after exposure to heating by infrared radiation.

The next step is to examine already diagnosed patients as having breast cancer using this procedure to confirm these results.

### References:

- 1- Caifeng Wan, Jing Du, Hua Fang, Fenghua Li, Lin Wang (2012). Evaluation of breast lesions by contrast enhanced ultrasound: Qualitative and quantitative analysis: Eur. J of Rad: 81(4): e444–e450
- 2- Cassano E., Rizzo S., Bozzini A, Menna S, and Bellomi M (2006). Contrast enhanced ultrasound of breast cancer. Cancer Imaging. 6(1): 4–6.
- 3- Sheshadri H.S. and Kandaswamy A. (2006). Breast tissue classification using statistical feature extraction of mammograms. J. Medical Imaging and Information Sciences (Japan): 23(3):105-107.
- 4- Schott AF, Roubidoux MA, Helvie MA, Hayes DF, Kleer CG, Newman LA, Pierce LJ, Griffith KA, Murray S, Hunt KA, Paramagul C, and Baker LH (2005). Clinical and radiologic assessments to predict breast cancer pathologic complete response to

neoadjuvant chemotherapy. Breast Cancer Res Treat. ;92(3):231-8.

5- V. Kumar and H.Bansal(2011)  
Performance evaluation of contrast

enhancement techniques for digital images. IJCST. 2(1): 23-27.

## استعمال الأشعة تحت الحمراء لتحسين صورة السونار في فحص الثدي

سلمى علي رضا\*

عيسى محمد كاظم\*

\*جامعة بغداد / كلية العلوم للبنات/ قسم الفيزياء

### الخلاصة:

من المعروف ان استعمال السونار هو ليس الأختيار الاول في فحص الثدي للكشف المبكر عن اورام الثدي. وان تحسين درجة الوضوح في صورة الثدي بالامواج فوق الصوتية هو هدف كثير من الباحثين جعله الخيار الاول كونه فحصا امينا خاليا من التأثيرات الجانبية وطريقة سهلة بالاضافة الى انها قليلة التكاليف مقارنة بطرق التصوير الاخرى كالماموكراف والرنين المغناطيسي. في هذه الدراسة استعملت الاشعة تحت الحمراء كمصدر حراري لتعريض منطقة الثدي قبل الفحص وذلك لكي تتحسن درجة الوضوح. أظهرت النتائج حصول تحسن مهم في درجة وضوح صورة الامواج فوق الصوتية بعد التعرض للاشعة تحت الحمراء بنسبة 60% من الحالات عما قبل التعرض.