

Anatomical and histological study of pituitary gland of the rats in Iraq

Asst. lecturer. Hussein B. Mahmood
Faculty of veterinary medicine –University of Kerbala

Abstract

In order to study the pituitary gland of rats, ten samples were collected from animal house in (Veterinary.Medicine of Kerbala university).This work contains anatomical and histological studies. The present anatomical study revealed that the rat has a disc-shape of pituitary gland, white color, tightly attached with the dura mater. The gland was 3mm in diameter, located caudally to the base of brain near the cerebellum. The present study found that the rat has a well developed adenohypophysis and full-developed neurohypophysis. The main histological results were the lobulation of the pituitary gland, adenohypophysis and neurohypophysis, these structures which appear as a wing, pars distalis it located laterally while the pars nervosa is located in middle. The pituitary gland in rats didn't surrounded by a true capsule. The acidophils were smaller than basophils while the chromophobe were largest cells in pars distalis.

المستخلص

اجريت هذه الدراسة في الغدة النخامية في الجرذان, عشر عينات جمعت من الجرذان في البيت الحيواني (كلية الطب البيطري جامعة كربلاء) اظهرت الدراسة التشريحية ان الغدة النخامية في الجرذان قرصية الشكل ذات لون ابيض مرتبطة ارتباط وثيق بالام الحنون, يبلغ قطرها 3 ملم تقع خلفيا من قاعدة الدماغ قريبة من المخيخ, واظهرت الدراسة الحالية ايضا ان الغدة تمتلك فص غدي وفص عصبي متطورين جدا. اما النتائج النسيجية بينت ان الغدة مفصصة وان الفصين الغدي والعصبي يظهران على شكل جناحين, الفص الغدي يقع وحشيا اما الفص العصبي يقع في المنتصف. لا تحاط النخامية في الجرذان بمحفظة حقيقية. اما الخلايا في الفص الغدي فقد ظهرت ان الخلايا الحمضة اصغر حجما من القعدة بينما الخلايا الكارهة للصبغة هي الاكبر.

Introduction

The hypophysis cerebri was sometime described as a master endocrine organ, since it produces certain hormones that directly influence the activities of other endocrine glands . Its location as an appendage of the brain also points its significance as the relay between the nervosa and hormonal mechanisms that jointly control certain function. The hypophysis cerebri attached at the ventral midline of the diencephalon and suspended from the midline of hypothalamus by a cylindrical stalk , this stalk was an extension of median eminence of the hypothalamus and called the pars proximalis neurohypophysis (1). The sella turcica was lined by dura mater and the pituitary gland was completely covered by a capsule called (diaphragm sella) , except for a small opening, which allows passage of pituitary stalk(2). The pituitary gland was surrounding by a thin fibrous connective tissue capsule derived from the dura mater. The loose connective tissue between the capsule and periosteum of the sphenoid bone contains dense plexus of thin-walled veins which surrounded the entire pituitary gland (3),(4). The pituitary gland of large ruminants was oval-elongated while in small ruminant is conical in shape (5) . In buffalo the pituitary gland has ellipsoidal in shape In horse, as the pituitary gland shaped flattened-rounded, the anterior lobe has brown in color and the posterior lobe was pale. In dog, the pituitary gland is ovoid in shape. Its measurement was about 1 cm in length, (0.7) cm in width and (0.5) in depth . It may weigh approximately (0.6) gm. Its dark elliptical body becomes larger during pregnancy (6),(7),(8),(9). In human the pituitary gland has bean - shaped or small flattened-Grape-pinkish in color in fresh condition. Its dimensions were (1-1.2) cm, (1-1.5) cm, (0.5) cm and (0.5) gm in length, width, thickness and weight respectively (10),(11),(12),(13). The pituitary gland was divided into

adenohypophysis and neurohypophysis. Adenohypophysis was subdivided into three portions, i.e, pars distalis, pars tuberalis and pars Intermedia.

Pars distalis: it is covered by a capsule of collagen fibers, which is continuous with the stromal fibers. The parenchyma of the pars distalis consists of cell cords and clusters interspersed with associated sinusoids. The pars distalis was based solely on the staining properties of secretory granules within the cells. Histologist identified three types of cells according to their staining reaction viz., basophils, acidophils and chromophobes (14),(15)(16).

Pars intermedia: In man , the pars intermedia is less developed than in many other animals and usually is poorly defined but may developed in fetus. It forms only about 2 percent of the hypophysis . It is composed of a thin layer of cells and vesicles which contain colloid and lies in close relation to the residual lumen, virtually is obliterated in most human. The pars intermedia in mammals generally is poorly vascularized (17).The pars intermedia contains the granular basophilic cells which are typically smaller than those in the pars distalis. Although these cells usually disposed in cords or clusters (18).

Neurohypophysis: The posterior hypophysis ceribri consists of neural lobe, the infundibular stem and the median eminence was composed of thin non-myelinated nerve fibers and associated neuroglial cells (19). The nerve fibers were oriented in different directions. The pars nervosa in buffalo was weakly vascularized. Cells from the pars intermedia were commonly present in pars nervosa and separated from the pars intermedia by a cleft, the pars nervosa contains follicles filled with colloid. The smaller nuclei were related to microglia while the larger nuclei were related to the astrocytes which extend between blood vessels and nerve tissue. Some of glial nuclei were rounded, others were triangular in shape

Materials and methods

Samples:

Ten samples were collected from rats, immediately the pituitary glands were removed and fixed in 10% buffered neutral formalin.

Anatomical techniques:

The following anatomical indices were used in this work;

The Method of dissections:

The ventral cervical muscles were removed at the joint attachment. The skin and muscles were also removed from the upper part of the head, then the bone of the skull was cut from anterior part directly to the orbit then the bones under the ear to the foramen magnum were cut transversally by two incisions. The broken bones were removed from the brain, so we must remove it firstly before starting to take the brain by cutting the cranial nerves and then the pituitary gland was removed by using the blind forceps (20).

Histological studies:-

The specimen washed with normal saline to carry out through routine procedure by taking serial sections. **Fixation** the specimens put in the fixative solution of 10% formalin for 48 hours. The samples washed up by tap water for two hours, then the tissue was prepared for the light microscope study which include :(**Dehydration, Clearing, Infiltration, Embedding, Sectioning, Staining, Mounting, Drying, cleaning and labeling respectively**) (21).

Results

Anatomical results:-

Morphology and location:-

The present study found that the pituitary gland in rat was unpaired. It was disc in shape (Fig.1), 3mm in diameter; it was surrounded by very thin white capsule which is part from the dura mater called the (sella diaphragm). This capsule enclosed the pituitary gland and tightly attached with it except at the upper part in area of connection of the pituitary gland with the infundibulum stalk. The pituitary gland in rat was located in oval - conical cavity called sella turcica. The sella turcica

appeared as a shallow depression in the caudal base of the brain near the cerebellum, in posterior part of sphenoid bone. The pituitary gland consisted of two parts which can be difficult distinguished by naked eye i.e anterior and posterior lobes. The anterior & posterior lobe was white in color. The posterior lobe was separated from the anterior one by a cleft (fig, 2). The pars intermedia was not easily distinguished. The pituitary gland was connected with the hypothalamus by a tuber hallow stalk.

Histological results:

The current results revealed that the pituitary gland has no true capsule. It was lobulated. The pituitary gland was divided by a dense connective tissue septae that containing blood, the pituitary gland was divided into two parts; **Adenohypophysis** and **Neurohypophysis** (Fig.2).

I-Adenohypophysis:-

The adenohypophysis of pituitary gland in the rat was subdivided into three parts:

1- The pars distalis:

The parenchyma of pars distalis consists of clusters and cords of cells intermingled with a large amount of connective tissue that rich in sinusoidal capillaries. The cell types of pars distalis include:

Acidophil cells:-

It was smaller than basophils and chromophobes, acidophils found as cords. The cytoplasm of the acidophils stains red to pink in hematoxylin and eosin stain. These cells may be found in two types of different size& shape.

I- Acidophils (type I).

This type of cells was irregular in shape. The cytoplasm was dark pink in color, the nuclei were irregular in shape and have dark color, and these cells were found near the sinusoid (Fig.3).

II-Acidophils (type II).

This type of cells was rounded in shape. The cytoplasm was red in color with fine homogenous secretory granules; the nuclei were rounded in shape with coarse chromatin granules.

Basophils:

This type of cells was larger than acidophils. The basophilic cells appear as clusters. These cells take the magenta-bluish color. They were varying in size and shape; two types of basophilic cells were recognized which take the positive stain with (PAS).first one regular and second one irregular in shape. Their cytoplasm was magenta in color and contains dark secretory granules with dark and oval nuclei (Fig, 4).

Chromophobe

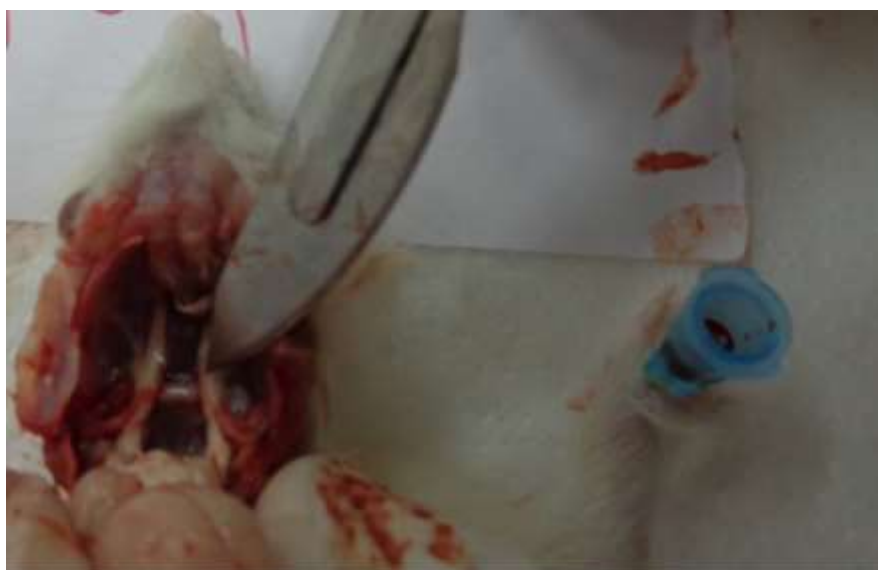Chromophobes were the largest cells in pars distalis. They were rounded-regular in shape. The cytoplasm was devoid of granules. It has easily distinguished boundaries. This type of cells has centrally located dark nuclei with clear nucleolus (Fig.3).

Pars intermedia

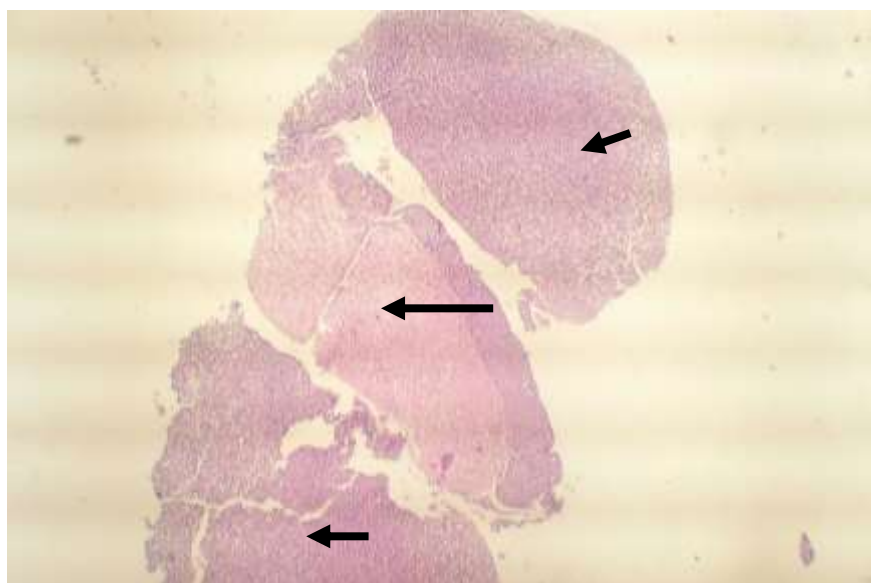
The present study revealed that the rat has well-developed pars intermedia. It lied closely to the neurohypophysis and separated from the pars distalis by a cleft. The pars intermedia was poorly and has a dense connective tissue which intermingled with the cells. Many cells may be seen migrated from the pars intermedia into the pars nervosa. Two types of cells were recognized in out the pars intermedia ;magenta cell has dark granules and chromophobe which devoid granules in cytoplasm (Fig,5).

Neurohypophysis

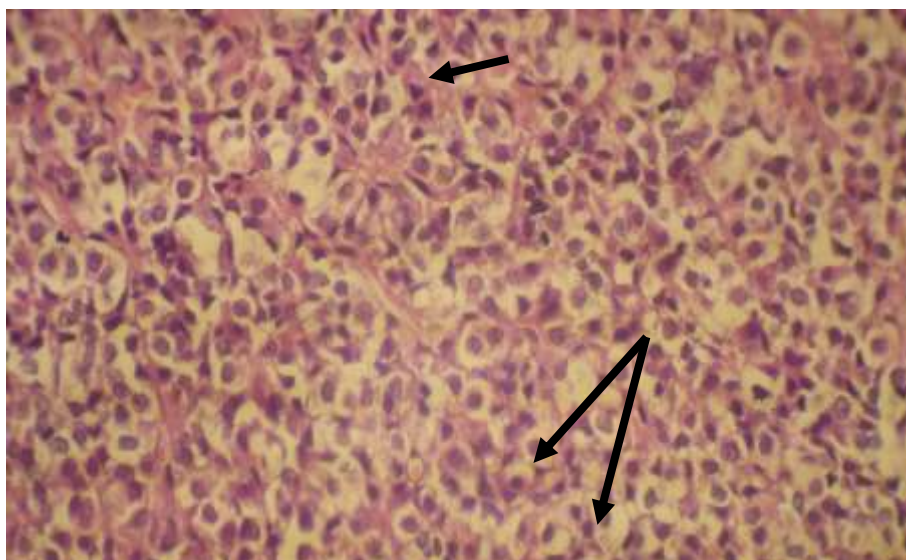
The pars nervosa was composed of thin non-myelinated nerve fibers with associated glial cells which interposed with the nerve fibers. The pituicyte lied near the sinusoidal capillaries between the terminations of nerve fibers. Sometimes, collagen fibers were present between nerve fibers. The nerve fibers were oriented in different directions. The pars nervosa in rat was weakly vascularized. Cells from the pars intermedia were commonly present in pars nervosa and separated from the pars intermedia by a cleft. In addition to the numerous axons and terminations of the hypothalamic neurosecretory neurons, the neurohypophysis contains fibroblast. Only the nuclei of glial cells tend to be visible. Three types of nuclei can be identified, oval, triangular and elongated in shape (Fig,6).



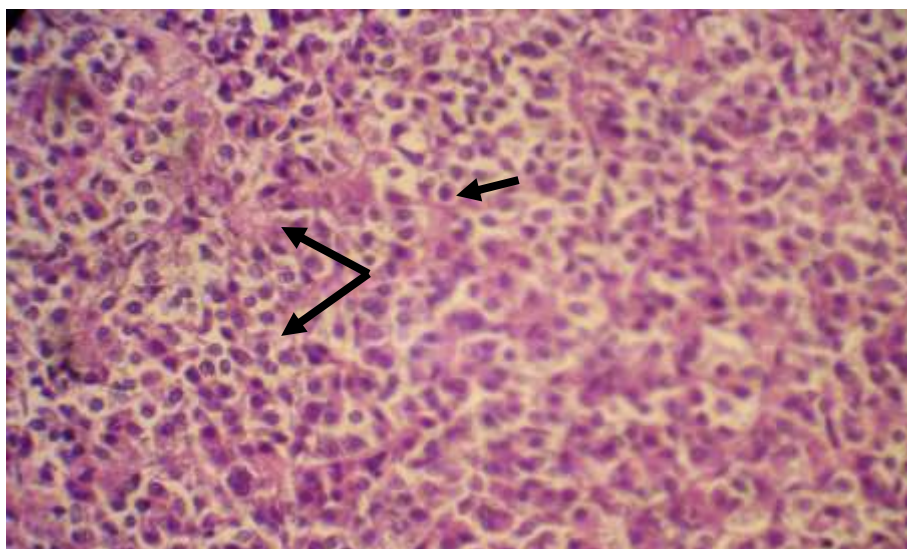
(Fig,1) Pituitary gland in rat showing the pituitary located caudal part of the brain.



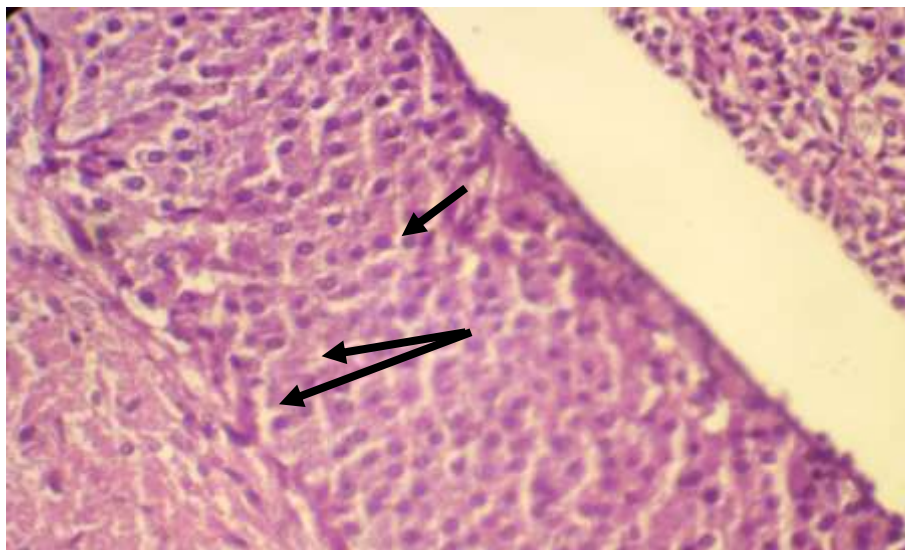
(Fig,2) Pituitary gland showing the Adenohypophysis in (short arrows) & neurohypophysis (long arrow). H&E stain



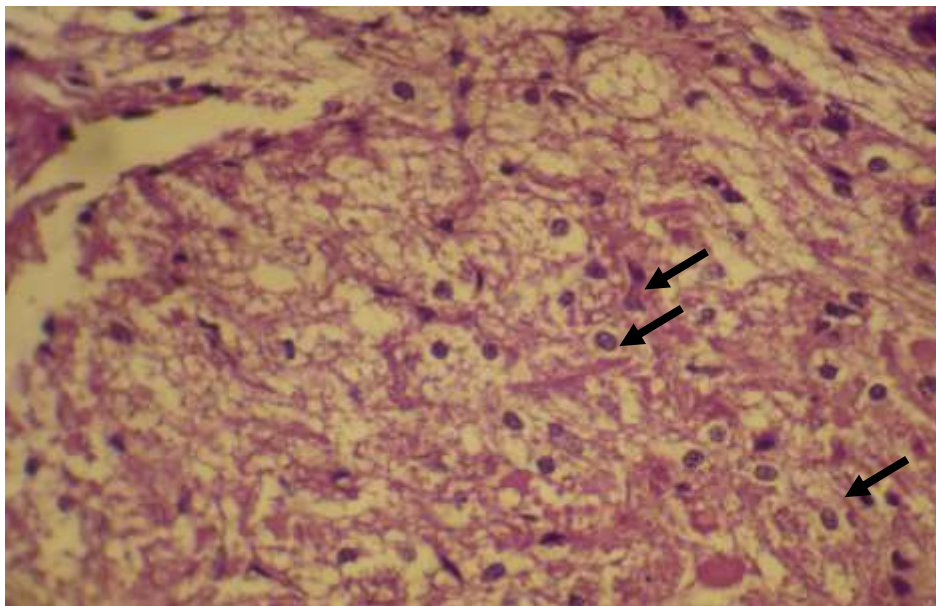
(Fig,3) Pars distalis showing acidophil irregular type (short arrow),chromophobe (long arrows). H&E stain.40X.



(Fig,4) Pars distalis showing the regular acidophil (small arrow), basophils (large arrows).PAS stain, 40X.



(Fig,5)Pars intermedia showing two type of cells, irregular cell (short arrow) and Magenta-syncytium cell(long arrow).PAS stain.40X.



(Fig,6) Neurohypophysis showing the three type of nuclei (rounded, triangular and finger). PAS stain, 40X.

Discussion

Anatomical

The pituitary gland in rat was found not to be surrounded by a special true capsule. This is attributed to its location in the protective bony sella turcica and to its envelopment by strong connective tissue capsule, the diaphragm sella, which is derived from the main dura mater of the brain. These factors probably make the pituitary gland to be not in need of a special capsule. This is in variance partially with (8), (15), (17). The absence of the dura mater capsule around the pars tuberalis may be due to the narrow area of the connection between the pituitary gland and hypothalamus. This finding agree with (7) who stated that pituitary gland were completely covered

by capsule called (diaphragm sella) except for a small opening which allows the passage of pituitary stalk. The disc shape and the small size of the pituitary gland of rat differ with other animals; this may be due to the pituitary gland in rat varying in function and other physiological effect.

Histological

The connective tissue septa which is weekly penetrated the pituitary gland was to provide support to the vascular system. These septa convey the blood and nerve supply to the deepest parts of the gland and to drain the secretory materials out of the gland. The herein study revealed that the pituitary gland of the rat has different lobes, some of these were well- developed like pars distalis and pars intermedia other lobe was ill- developed like pars nervosa.

Pars distalis

Because the pars distalis was located as a wing and occupied most area from pituitary gland this may be due to the pars distalis in rat is vary action. Most researchers classify the cellular distribution of pars distalis into two categories, cords or clusters distribution in general (22),(23),(24),(25). Our result revealed that acidophils were distributed as cords while basophils were distributed as clusters; chromophobes scattered throughout the two main above cells types, sinusoid were intermingled with these cells. Pars intermedia and pars nervosa(8),(13),(11). Large amount of blood supply, give an evidence of the activity of pars distalis in rat. The current result explained that the percentage of chromophobe may found in large amount, this is in variance with the finding of other authors (11),(26). This is owing to the hormonal state of the gland, as when the chromophobes increases in respect to the chromophils this may indicate a state of resting for cells and vis – versa. In rat, the increased number of chromophobes may indicate a state of activity into the pars distalis. In the pars distalis there is a state of the secretory cycle. when the cells secretes its granules it remain intact and the cell membrane remains unbroken and need not to compensate by mitotic figure. This is reinforced the herein study which revealed that there is little mitotic figures. Some authors revealed that the pituitary gland showing rarely cancer state (19). The degree of granularity is correlated with the physiological state of the cell when fixed. The cells were thought to secrete cyclically rather than continuously, so that the result revealed the presence of cells in a state of the resting filled with secretory granules or stimulating empty of secretory granules which the study regard as degranulated chromophils this is in accordance with (19).

Pars Intermedia:-

The presence of syncytium state of cells in pars intermedia, gives evidence that the pars intermedia is more active in rat. In other mammals like human where the pars intermedia was poorly vascularized and rudimentary and has only one or two cell types (19),(27).

Pars nervosa

The pars nervosa is not well developed because there was low density of glial cells and low vascularization. Blood sinuses and sinusoid were empty or not filled with blood.

References

- 1-Dyce, K.M. ; Sack, W.O., and Wensing, C.J.G (1987). The endocrine gland. Textbook of veterinary anatomy. Philadelphia: W.B Saunders company, pp 205-207.
- 2- Montuldo, C; Matta, G., and Marcia, S. (2002). The sellar region: anatomy, pathology and neuroradiological study. Rivista Di Neuroradiologia 13: 327-340.
- 3- William, J. (1993). Applied veterinary histology . third edition Mosby – year book. Inc . pp: 409- 413.
- 4- Slomianka, L. (2006). Blue histology- endocrines . Pituitary gland in sheep. school of anatomy and human biology – The University of Western Australia . pp 2-4.
- 5- Getty, R. (1975). The anatomy of the domestic animals. Vol. 1.5th ed. W.B. Saunders company. Toronto.

- 6- **Arthur, G . H; Noakes, D. E; Pearson. H and Hand Parkinson , T . J. (1996).** Veterinary Reproduction & Obstetric. 7th ed. W. B. Saunders company Ltd. London.
- 7- **Arthur, G . H; Noakes, D. E; Pearson. H and Hand Parkinson , T . J. (1996).** Veterinary Reproduction & Obstetric. 7th ed. W. B. Saunders company Ltd. London.
- 8- **Hullinger, R.L. (1993).** The endocrine system In: H. E. Evans,ed. Miller s' anatomy of the dog .3ed. philadelphia: W. B. saunders company. pp 561-566.
- 9- **McKleven, J. (2002).** Evaluation of the of the normal Equine pituitary gland. Thesis, Blacksburg Virginia . pp: 16-32.
- 10- **Bloom, W. and Fawcett, D. W. (1968).** A textbook of histology . ninth edition. W. B. Saunders company. Philadelphia. London. Toronto. PP:430-442.
- 11- **Lesson, S. and Lesson, M. (1985).** Textbook of histology, fifth edition . A companion volume to atlas of histology. W. B. Saunders company Philadelphia. London. Toronto. Mexico. Tokyo. PP:436-445.
- 12- **Steven, A. and Lowe, J. (1992).** The pars intermedia of pituitary gland . Gower medical publishing . histology. p: 254.
- 13- **Junqueira, L. C.; Carneiro, J. and Kelly, R. O. (2003).** Basic histology. 9th ed. Mc Graw and Hill, New York. PP: 354-360.
- 14- **Fahmy, M.P. and Nasr, H. (1963).** Morphological study of pituitary gland of the adult male camel (Camelus dromedaries), 4th Ann. Vet. Congress, Cairo Egypt .
- 15- **Dellmann, H. D. (1881).** Textbook of veterinary histology. second edition. Lea and Febiger. Philadelphia PP: 358-365.
- 16- **Ross, M.H; Romerll, L.J and Kaye, G.I. (1995).** Histology. 3rd ed Williams and Wilkins Sydney. Tokyo. PP: 609-621.
- 17- **Bloom, W. and Fawcett, D. W. (1968).** A textbook of histology . ninth edition. W. B. Saunders company. Philadelphia. London. Toronto. PP:430-442.
- 18- **Rasmussen, A. T. (1928).** The morphology of the pars intermedia of the hypophysis, endocrinology. 2:129.
- 19- **Elster, A. D (1993).** Modern imaging of the pituitary gland. Radiology. PP: 187: 1-14.
- 20- **Makawe, A. T. (1980).** Veterinary forensic medicine and Poisons. university of Baghdad .College of the veterinary Medicine.PP: 35-37.
- 21- **Luna , G . (1968) .** Manual of histological staining method of the armed forced institute of pathology . 3rd ed Mc . Graw hill book Co . New York.
- 22- **Lesson, S. and Lesson, M. (1985).** Textbook of histology, fifth edition . A companion volume to atlas of histology. W. B. Saunders company Philadelphia. London. Toronto. Mexico. Tokyo. PP:436-445.
- 23- **Dellmann, H. D. (1881).** Textbook of veterinary histology. second edition. Lea and Febiger. Philadelphia PP: 358-365.
- 24- **Ross, M.H; Romerll, L.J and Kaye, G.I. (1995).** Histology. 3rd ed Williams and Wilkins Sydney. Tokyo. PP: 609-621.
- 25- **Fahmy, M.P. and Nasr, H. (1963).** Morphological study of pituitary gland of the adult male camel (Camelus dromedaries), 4th Ann. Vet. Congress, Cairo Egypt .
- 26- **Copenhaver, W.M; Bunge, R.P; Bung, M.B. (1971).** Baileys textbook of histology. 16th ed. Williams company. PP 648-652.
- 27- **Junqueira, L. C.; Carneiro, J. and Kelly, R. O. (2006).** Basic histology.10th ed. Mc Graw and Hill , New York . PP :365-372.