

## Pathological study of therapeutic Effect of Crude Extract of *Euphorbia granulata* F. in experimentally implanted Murine Mammary Adenocarcinoma

F. J. D. Daqama<sup>1\*</sup>, N. Y. Yaseen<sup>\*\*</sup>, E. H. Y. Altaae<sup>\*</sup> and R. A. A. Al-Naimi<sup>\*</sup>

<sup>\*</sup>College of Veterinary Medicine\ Baghdad University

<sup>\*\*</sup>Iraqi Center for Cancer and Medical Genetic Research\ Al-Mustansirrya University

### Abstract

This study was designed to evaluate the cytotoxic effect of 70% ethanolic crude extract of *Euphorbia granulata* F. on normal and cancer cells. The acute toxicity of 70% ethanolic extract of the plant on normal mice has been studied. LD50 was determined by probit study (1486 mg/ kg B.W.) to calculate the therapeutic dose which was 30 mg/kg B.W S/C injection. Therapeutic effect of ethanolic extract of *E. granulata* was studied on tumor-bearing female mice after subcutaneous administration of 30 mg/kg B.W for 30 days (group II), while tumor-bearing female mice (group I) have been injected with distilled water only and served as control. The results were showed a significant reduction in tumor volume, relative tumor volume and inhibition of tumor growth rate in treated mice (group II) compared with tumor-bearing female mice of non-treated group (group I). Histopathological sections were showed large areas of necrosis, mononuclear cell infiltration and granulation tissue formation surrounding the tumor cells in tumor-bearing female mice (treated group II), hyperplasia of white pulp of the spleen with amyloid deposition and proliferation of megakaryocyte. Mononuclear cell infiltrations in liver, kidney, intestine and brain (group II) compared with non treated tumor bearing female mice (group I). The tumor growth was showed acinar like structures with milk like secretion, pleomorphic hyperchromatic tumor cells, and calcification of necrotic area. Liver showed small aggregation of tumor cells within liver parenchyma with extensive areas of coagulative necrosis and apoptosis. kidney undergo hydropic degeneration with dilation of urinary space. Brain showed perivascular and perineuronal edema with congestion, while spleen showed mild hyperplasia and proliferation of megakaryocytes. Tumor associated macrophages were infiltrated in liver and lung of control group.

دراسة مرضية لتأثير علاج خلاصة خام نبات سرطان الثيل *Euphorbia granulata* F. في

علاج سرطانة الغدة اللبنية المغروسة في اناث الفئران البيضاء

فراس جوزيف داود<sup>\*</sup> ناهي ياسين يوسف<sup>\*\*</sup> إيمان هاشم يوسف<sup>\*</sup> و راجحة عبد الستار النعيمي<sup>\*</sup>

<sup>\*</sup>كلية الطب البيطري/ جامعة بغداد

<sup>\*\*</sup>المركز العراقي لبحوث السرطان والوراثة الطبية

### الخلاصة

هدفت الدراسة إلى معرفة التأثير العلاجي للخلاصة الايثانولية الخام 70% لنبات سرطان الثيل على سرطانة الغدة اللبنية المغروسة في اناث الفئران البيضاء (داخل الجسم الحي) لقد تم دراسة التأثير العلاجي للخلاصة الايثانولية الخام

<sup>1</sup> The research has been taken from the thesis of the first author.

على الفئران الحاملة لسرطانة الغدة اللبنية بحقن جرعة 30 mg/ kg B.W. تحت الجلد لمدة 30 يوم على التوالي وأظهرت النتائج انخفاض معنوي في حجم الورم وحجم الورم النسبي وزيادة في نسبة تثبيط الورم مجموعة الحيوانات المعالجة مقارنة مع مجموعة حيوانات السيطرة التي أظهرت زيادة كبيرة في حجم الورم.

أظهر الفحص النسيجي المرضي وجود باحات كبيرة من النخر وارتشاح خلايا وحيدة النواة مع تكون النسيج الحبيبي حول الخلايا السرطانية في مجموعة الفئران الحاملة للسرطان والمعالجة بالخلاصة الايثانولية الخام لنبات سرطان الثيل بينما أظهرت المقاطع النسجية للورم لمجموعة السيطرة وجود كتلة ورمية تميزت بالتكاثر العشوائي للخلايا الورمية المتعددة الاشكال وذات النوى الغامقة مع تكوين الخلايا العملاقة وزيادة في عدد الاشكال الانشطارية مع تكوين تراكيب سنخية مع إفراز مادة شبيهة بالحليب مع وجود باحات واسعة من النخر وتكلس المناطق المتخثرة من الورم وتجمعات صغيرة متعددة من الخلايا الورمية في متن الكبد مع حصول النخر التجلطي والموت المبرمج للخلايا وارتشاح البلاع الكبيرة المصاحبة للورم في كل من الكبد والقلب والرئتين، مع فرط التنسج للمفاوي لللب الابيض وخزب واحتقان الاوعية الدموية للدماغ وزيادة الخلايا الكأسية وإفراز مادة المخاطين في الامعاء.

أما المقاطع المرضية النسجية المعالجة بالخلاصة الايثانولية لنبات سرطان الثيل فقد أظهرت وجود أورام حبيبية في الكبد والكلية أظهرت التتسكس المائي مع توسع حوض الفراغ البولي مع ارتشاح خلايا وحيدة النواة في كل من القلب، الكلية، الرئة، الدماغ والأمعاء وفرط تنسج وارتشاح مادة النشواني في الطحال والتي ظهرت بوضوح باستخدام الصبغة الخاصة مع عدم مشاهدة النقائل وخلايا بالمقاطع النسجية. لكن لوحظ وجود ارتشاح لخلايا البلاع المصاحبة للورم في الكبد والرئة في مجموعة السيطرة.

## Introduction

Cancer may affect people at all ages,even fetuses,but the risk for most varieties increases with age(1).Cancer causes about 13% of all deaths in 2004(2)and according to the American Cancer Society,7.6 million people died from cancer in the world during 2007 (3).

Concurrently, research centers in developed countries have begun to turn to alternative or complementary therapies, including medicinal herbs and about half the general population in developed countries use complementary and alternative medicine (4). Although modern medicine may be available in developing countries, herbal medicines (phytomedicines) have often maintained popularity for historical and cultural reasons (5), so medicinal plants still remain the basis for development of modern drugs and medical plants have been used for years in daily life to treat diseases all over the world, and all the researchers nowadays are looking for them (6).

Studies on genus *Euphorbia* showed that it has anti-tumor property(7).*Euphorbia granulata* contains many biological active compounds and is a source of many nutrients. Some of biological active compounds include both apigenin and luteolin(8).Studies on *E.granulata* lead to the isolation of several neutral compounds like hydrocarbons,easters and triterpenes(9).Some studies show that the source of toxin of *E.granulata* is leachate (10).

The *Euphorbia granulata* plant has different useful medical properties but there are no data that have been published regarding the antitumor activity of *Euphorbia granulata* even the relationship with cancer in Iraq or in the worldwide therefore, the present study was designed to investigate the theraputic and cytotoxic effects of *Euphorbia granulata*, through the performing the effect of alcoholic extract of *Euphorbia granulata* on tumor in vivo.

## Materials and Methods

- 1. Collection and extraction of plant:** *Euphorbia granulata* plant has been obtained from filed of College of veterinary Medicine, University of Baghdad. Representative specimens (leaves and stem) have been taken to the college of Science, Botany department, University of Baghdad and identified by scientific collage of Baghdad University as *Euphorbia granulata* L, Family Euphorbiecea.

According to 11, 70% ethanolic extract of plant has been prepared as fifty gram of fresh plant (leaves and stems) have been put in flask with 250 ml of 70% ethanol and stirred on magnetic stirrer at room temperate for 72 hrs. After 72 hours, the sediments have been filtered through gauze then by filter paper. Then was repeated (3) times. The solvent was evaporated by air convection oven at 38 °C. The weight of crude extract resulted was measured and kept at 4 °C until used. After determination of LD50 which was 1486 mg/ kg B.W.; the therapeutic dose was 30 mg/kg B.W.

- 2. Animals treated with alcoholic extract of *Euphorbia granulata*:** By returned to result of LD50, in addition to some references (8). The doses have been used in this study (30 mg/ kg B .W S/C injection daily for 30 days).
- 3. The effect of extract on tumor growth:** Single tumor mammary adenocarcinoma bearing mouse (AM3) has been supplied from ICCMGR. This mouse has been used to obtain tumor cells which later transplanted into adult female albino mice. The protocol of (12) has been followed to perform the transplantation process, which occurred under highly sterile conditions. Once tumor reached the suitable volume that reaches at least 5 mm in dimension, mice have been randomized into two treatment groups (each contain of 4 adult female albino balb/C mice). One experimental groups have been S/C administered with (30 mg/kg) daily of alcoholic extract of *Euphorbia granulata*. Another group has been injected with D.W S/C as control. These groups treated for 30 days respectively.

After (30) days both two groups, the animals have been killed by inhalation anesthesia and directly making incision as follow:

Each mouse fixed on back on anatomical dishes and washing by PBS the incision start at the end of abdominal region till the another end of animal through the chest cavity and blood have been collected from the heart then all visceral organs (heart, lung, spleen, liver, kidney and brain) have been noted, then fixed in 10% formalin in order to study the histopathological changes. After 48 hours of the fixation, then processing has been routinely done with a set of increasing alcohol concentrations, tissues sections have been embedded in paraffin blocks, and sectioned by microtome at 5µm for all tissues. All tissues have been stained with hematoxylin and eosin stain and the histopathological changes have been observed under light microscope. Special stain Congo red is used for identified amyloid substances (13).

## Results and Discussions

### Effect of ethanolic extract of *Euphorbia granulata* on transplanted mammary tumor in mice:

Subcutaneous injections with ethanolic extract of *E. granulata*, at a dose 30 mg /kg B.W for 30 days showed:

- 1. Tumor volume:** Significant rate showed ( $P \leq 0.05$ ) in tumor volume, the volume decreased at tumor-bearing female mice (group II) all the days of experiment which has

decreased significantly in tumor volume gradually ( $0.831 \pm 0.14$ ,  $0.833 \pm 0.29$ ,  $0.959 \pm 0.11$ ,  $0.916 \pm 0.14$ ,  $1.23 \pm 0.45$ ,  $2.25 \pm 0.51$ ,  $2.53 \pm 0.70$ ,  $2.64 \pm 0.65$ ,  $2.85 \pm 0.58$  and  $2.95 \pm 0.6$ ), compared with tumor-bearing female mice which was treated with distill water and served as control (group I) which recorded a significant increase in tumor volume ( $P \leq 0.05$ ) at same days ( $1.92 \pm 0.54$ ,  $2.03 \pm 0.65$ ,  $2.25 \pm 0.37$ ,  $2.39 \pm 0.92$ ,  $3.13 \pm 0.44$ ,  $6.41 \pm 1.81$ ,  $7.07 \pm 1.56$ ,  $7.45 \pm 1.76$ ,  $7.83 \pm 0.96$  and  $7.88 \pm 0.99$ ) respectively. Ethanolic extract of *E. granulata* essential phytochemicals compounds such as alkaloids, flavonoids, glycosides, saponines, few turpen and tannins, are positive reaction to phytochemicals analysis. These compounds are widely distributed in plant Kingdom, and have cytotoxic and antiproliferative effect against cancer cells(14). Our interpretation to the reduction of tumor volume in this study in tumor bearing mice treated with *E. granulata* and inhibition tumor growth have been by the action these phytochemicals compounds against tumor cells. Alkaloids are mainly cytotoxic against various types of cancer and leukemia with antiviral properties, and they have immuno-modulatory properties (14). Flavonoids generally are toxic to cancer cells or to immortalized cells, but they are less toxic to normal cells (15). Some flavonoids are found to induce tumor necrosis factor (TNF) in vivo (16). Tumor necrosis factor- $\alpha$  (TNF- $\alpha$ ) is a potent chemo attractant for neutrophils, on macrophages stimulates phagocytosis, and production of IL-1 oxidants and the inflammatory lipid prostaglandin E2 PGE2. Tumor necrosis factor promotes the inflammatory response and promotes the destruction of some types of cancer cells, it is an important cytokine associated with tumor regression and increased survival time for cancer patients (17).

Luteolin's anticancer property is associated with the induction of apoptosis, and inhibition of cell proliferation, metastasis and angiogenesis. Furthermore, luteolin sensitizes cancer cells to therapeutic-induced cytotoxicity through suppressing cell survival pathways such as phosphatidylinositol 3'-kinase (PI3K)/Akt, nuclear factor kappa B (NF-kappaB), and X-linked inhibitor of apoptosis protein (XIAP), and stimulating apoptosis pathways including those that induce the tumor suppressor p53. These observations suggest that luteolin could be an anticancer agent for various cancers. Furthermore, recent epidemiological studies have attributed a cancer prevention property to luteolin (18).

Treatment of breast-cancer-bearing nude mice with Apigenin was examined resulting in tumor growth inhibition and massive apoptosis induction, associated with proteasome inhibition in vivo (19). The proteasome pathway plays a critical role in the regulated degradation of proteins involved in cell cycle control and tumor growth. The proteasome inhibition causes dysregulation of degraded protein should which have profound effects on tumor growth and causes cell to undergo apoptosis (20).

Angiogenesis is the formation of new blood vessels and it is required for tumor growth and metastasis; a study showed that apigenin suppresses tumor angiogenesis through HIF-1 and VEGF expression (21). These two factors play a critical role in angiogenesis, the first one Hypoxia-inducible factor-1 (HIF-1) is a transcriptional activator of genes essential for adaptation to low oxygen, and important mediators of vascular cell responses such as migration, proliferation, and survival (22). Vascular endothelial growth factor (VEGF) is an endothelial cell-specific mitogen and an angiogenic inducer as well as a mediator of vascular permeability. VEGF is essential for developmental angiogenesis (23).

Glycoside compounds are regarded as anti-cancer agents, alone, or in combination with other anti-cancer agents or therapies. Some research displayed differential cytotoxicities, with breast cancer, CNS cancer, and lung cancer (24). Many glycoside anti-cancer agents

are cytotoxic by necrosis, rather than apoptosis (25). Saponins have other important implications inhibit of colon cancer. Research at the University of Toronto has shown that feeding saponins to laboratory animals reduced the number of preneoplastic colon lesions in mice (26). Several biological effects have been ascribed to saponins and its anticarcinogenic properties (27). In the past few years, tannins have also been studied for their potential effects against cancer through different mechanisms. It happens either by induction of apoptosis (28) or by suppression of tumor cell invasiveness by hydrolysable tannins via the inhibition of matrix metalloproteinase-2/-9 activity (29).

## **2. Pathological Study:**

### **2-1 Pathology of adenoacarcinoma –non treated group:**

Gross lesion revealed the presence of large highly vascularised tumor mass with irregular shape and wide area of necrosis (Fig. 1). Histopathology, the tumor mass showing acinar formation, the tumor cells are separated into varying sized lobules by interlacing strands of connective tissue. The cells are pleomorphic, with large hyperchromatic nuclei and a tendency to form giant cells with presence of large numbers of mitotic figures and high invasion of mammary stroma (Fig. 2). Many sections showed extensive proliferation of solid masses of tumor cells which undergo extensive necrosis with milk like secretion. which in many areas undergo calcification with infiltration of inflammatory cells mainly macrophages and neutrophils with wide area of haemorrhage (Fig. 3).

### **4-6-1-2 Pathology of adenoacarcinoma–treated group:**

Gross lesion: The tumor mass become smaller in size, with little blood supply (Fig. 4). Histopathology, tissue sections showed the presence of thick band of granulation tissue which is infiltrated with large numbers of mononuclear cells mainly lymphocytes and macrophages surrounding the tumor mass which undergo extensive necrosis. In addition the necrotic center of the mass showing infiltration of mononuclear cells (Fig. 5). The histopathological findings of organs of both treated and untreated group have showed different pictures. Organs of treated groups showed focal infiltrations of mononuclear cells especially in lung, and formation of early granuloma in liver (Fig. 6); this may be attributed to the active compound like antioxidant flavonoid and alkaloids which may act as immune stimulant. The patient was given a better chance for survival if the cancer tissue showed infiltration of inflammatory cells particularly lymphocytic reactions. The results suggested some extent of anti-tumour immunity is present in colorectal cancers in humans, in 2007; (30) published a papers found atumor infiltrating lymphocytes to be quite significant in human colorectal cancer(30). According to cancer immunosurveillance theory lymphocytes act as sentinels in recognising and eliminating continuously arising, nascent transformed cells (31) also inhibits carcinogenesis and maintains regular cellular homeostasis (32).Cells of the innate immune system recognize the presence of a growing tumor, followed by the induction of inflammatory signals which is essential for recruiting cells of the innate immune system (e.i. natural killer cells, natural killer T cells, macrophages and dendritic cells) to the tumor site. The infiltrating lymphocytes such as the natural killer cells and natural killer T cells are stimulated to produce IFN-gamma. The newly synthesised IFN-gamma induces tumor death (to a limited amount) as well as promoting the production of chemokines CXCL10, CXCL9 and CXCL11. These chemokines play an important role in promoting tumor death by blocking the formation of new blood vessels and recruitment of more immune cells. Tumor cell debris produced as a result of tumor death is then ingested by dendritic cells, followed by the migration of these dendritic cells to the draining lymph nodes and these cells trigger the differentiation of Th1 cells which in turn facilitates the

development of CD8<sup>+</sup> T cells. The activating tumor-killing T cells is crucial for immunotherapy success, the way by which the host dendritic cells react and uptake tumor antigens to present to CD4<sup>+</sup> and CD8<sup>+</sup> T cells is the key for success of the treatment (33).

Natural killer cells and macrophages transactivate one another via the reciprocal production of IFN-gamma and IL-12. This again promotes more tumors killing by these cells via apoptosis and the production of reactive oxygen and nitrogen intermediates. The tumor-specific CD4<sup>+</sup> and CD8<sup>+</sup> T cells destroy the antigen-bearing tumor cells which remain at the site. Lymphocytes and IFN-gamma exert a selection pressure on tumor cells. Tumor infiltration by lymphocytes is seen as a reflection of a tumor-related immune response (34). The hyperplasia of lymphoid tissue of white pulp of spleen and proliferating of megakaryocytes (Fig. 7) were due to the immune stimulant and increased splenocytes proliferation caused by active compound of the plant (35). Umran shows that spleen follicular hyperplasia was due to catechines of *E. granulata* extract (36). Deposition of amyloid was noted in spleen of treated group (Fig. 8) which appeared very clear in tissue sections stained with specific stain for amyloid. Deposition of amyloid fibril protein (amyloid light chain) type is associated with some form of mononuclear B-cell proliferation (37). And proliferation of megakaryocytes in their spleen as a result of response to multi cytokines such as Interlukin-3, Interlukin-6 and Interlukin-11 to enhance immune response and stimulate the maturation of megakaryocytic progenitor cells (38). The bleeding tumor including adenocarcinoma in several organs leads to increase in number of megakaryocytes as a result in Iron deficiency (39). Bernard *et al* state that plasma cells produced immunoglobulines light chains that are precursors to amyloids (40). Amyloid deposits can be identified histologically by Congo Red staining (33). Metastasis in liver (Fig. 9) with presence of large areas of coagulative necrosis and apoptosis are the main histopathological finding of the liver in untreated group. Coagulative necrosis may be due to increase in hepatic oxygen demand without an appropriate increase in hepatic blood flow. Apoptosis is related to slight alterations within the plasma membrane causing the dying cells to be attractive to phagocytic cells (41). Granuloma may be operative in inducing immunity since macrophages are important in the induction and regulation of the immune response (35). Tumor associated macrophage (TAMs) and tumor cells infiltration were seen in liver (Fig. 10) and lung. It is thought that TAMs are almost derived from peripheral blood monocytes recruited into the tumor rather than derived from local tissue macrophages. A number of monocyte chemoattractants derived from tumors have been shown to be correlated with increased TAM numbers in many human tumors (42). Upon activation, the TAMs can release a vast diversity of growth factors, cytokines, inflammatory mediators, and proteolytic enzymes. Many of these factors are key agents in tumor progression (43). Clinical studies have shown a correlation between the numbers of TAMs and poor prognosis for breast, prostate, ovarian, cervical, endometrial, esophageal, and bladder cancers. TAMs are associated with increased angiogenesis or lymph node metastasis in cancer tissues. These observations accord with the results of animal studies using macrophage-depleted mice to investigate the role of macrophages in tumor progression (42). The presence of extensive TAM infiltration has been shown to correlate with cancer metastasis and poor prognosis in a variety of human carcinomas. TAMs promote cancer metastasis through several mechanisms including tumor angiogenesis, tumor growth, and tumor cell migration and invasion (43).

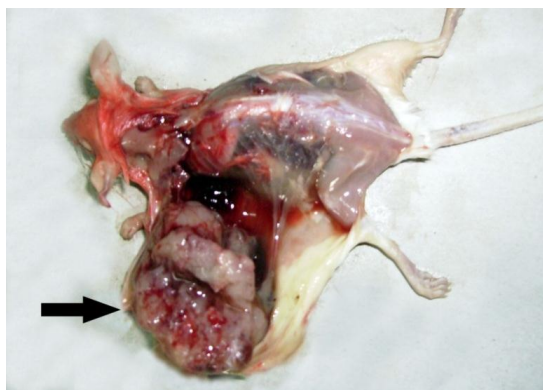


Fig. (1): Gross lesion of tumor-bearing mice treated with distilled water for 30 days as a control show large, irregular highly vascularized tumor mass ( → ).

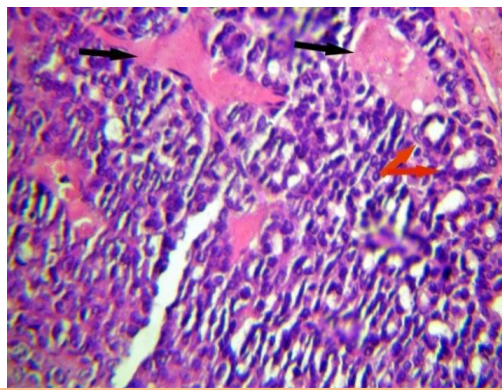


Fig. (2) Histopathological section of mammary adeno-carcinoma in tumor bearing female mice treated with distilled water for 30 days as a control group showing formation of acinar like structures ( → ) with secretion of milk like material ( → ) (H & E stain X 400).

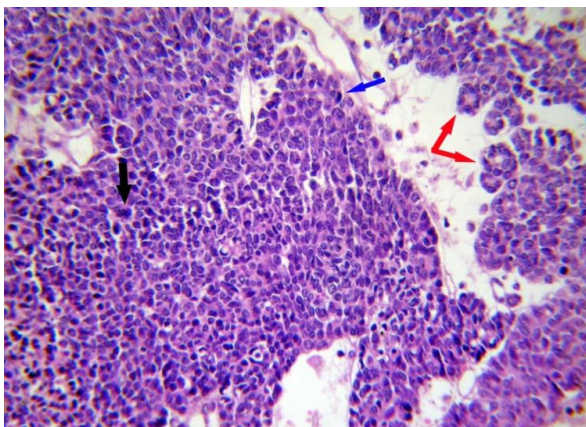


Fig. (3) Histopathological section of mammary adeno-carcinoma in tumor bearing female mice treated with distilled water for 30 days as a control group showing acinar like structures ( → ) with extensive proliferation of pleomorphic cells with hyperchromatic nuclei with formation of giant cells ( → ) and high numbers of mitotic figures ( → ) (H & E stain X 100).



Fig. (4): Gross lesion of tumor-bearing mice treated with (30 mg/kg B.W/ day of the ethnoc extract of *E. granulata* for 30 days) as a treated group showed decrease in size of tumor mass ( → )



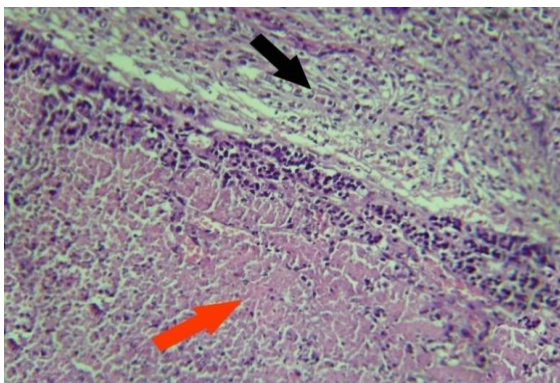


Fig. (5) Histopathological section of tumor mass in tumor bearing female mice treated with (30 mg /kg BW/ day) of the ethanolic extract of *E. granulata* for 30 days) as a treated group showing extensive necrosis of tumor cells in centre (→) surrounded by a thick band of granulation tissue which is infiltrated with mononuclear cells (→) (H & E stain X 100)

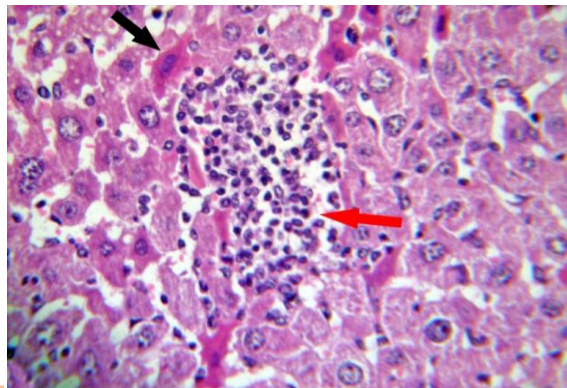


Fig. (6) Histopathological section of Liver in tumor bearing female mice treated (30 mg /kg BW/day of the ethanolic extract of *Euphorbia granulata* for 30 days) as a treated group showing formation of early granuloma (→) with presence of apoptotic cells (→) (H & E stain X 400).

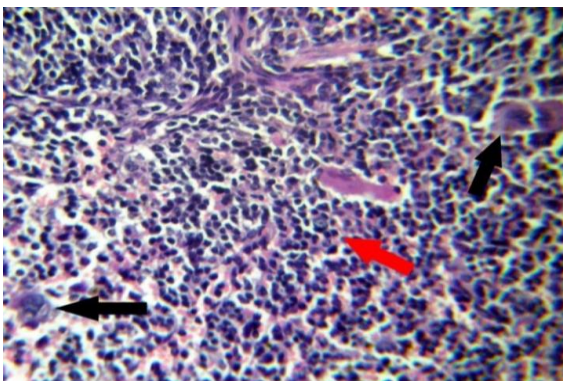


Fig. (7) histopathological section of Spleen in tumor bearing female mice treated with distilled water for 30 days as a control group showing hyperplasia of lymphoid tissue of white pulp (→) with proliferation of megakaryocytes (→) (H & E stain X 400).

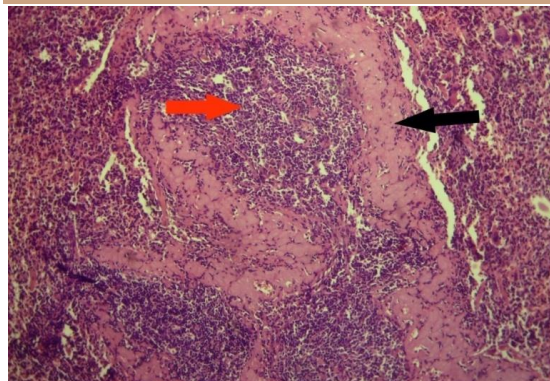


Fig. (8) histopathological section of Spleen in tumor bearing female mice treated with distilled water for 30 days as a control group showing hyperplasia of lymphoid tissue of white pulp (→) with deposition of amyloid (→) (H & E stain X 100).

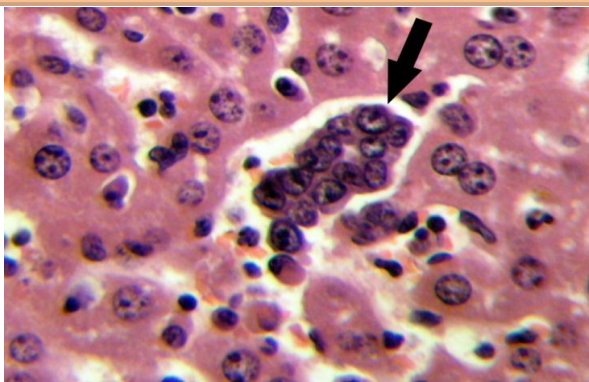


Fig. (9) Histopathological section of liver in tumor bearing female mice treated with distilled water for 30 days as a control group showing small aggregation of tumor cells within hepatic parenchyma (→) (H & E stain X 400).

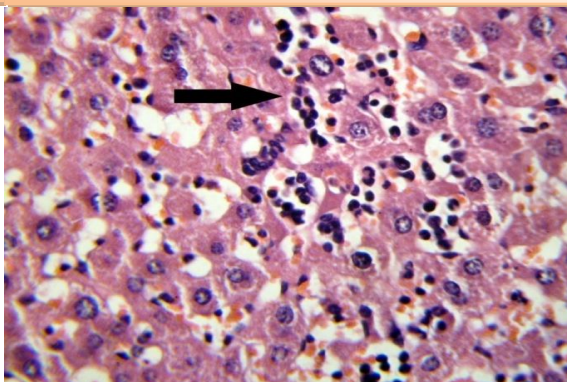


Fig. (10) Histopathological section of liver in tumor bearing female mice treated with distilled water for 30 days as a control group showing infiltration of tumor associated macrophage in the dilated sinusoids (→) (H & E stain X 400).



## References

1. Cancer Research UK. (2009). UK Cancer Incidence-age at diagnosis. London. England.
2. World Health Organization (WHO). (2009). Cancer. <http://www.who.int/mediacentre/factsheets/fs297/en/>.
3. American Cancer Society. (2009). ACS Report Focuses on Global Cancer Toll. <http://www.cancer.org/docroot/home/index.asp?level=0>. Copyright 2009 © American Cancer Society, Inc.
4. Ernst, E. (2003). Obstacles to research in complementary and alternative medicine. *Med. J. of Australia*, 179 (6): 279-280.
5. Tapsell, L. C.; Hemphill, I.; Cobiac, L.; Patch, C. S.; Sullivan, D. R.; Fenech, M.; Roodenrys, S.; Keogh, J. B.; Clifton, P. M.; Williams, P. G.; Fazio, V. A. & Inge, K. E. (2006). Health benefits of herbs and spices: the past, the present, the future. *The Med. J. of Australia*, Aug 21: 185(4 Suppl): 4-24.
6. Jiménez-Medina, E.; García-Lora, A.; Paco, L.; Algarra, I.; Collado, A. & Garrido, F. (2006). A new extract of the plant *Calendula officinalis* produces a dual in vitro effect: cytotoxic anti-tumor activity and lymphocyte activation. *BMC Cancer*, 6: 119-132.
7. Liu, W. K.; Ho, J. C.; Qin, G. & Che, C. T. (2002). Jolkinolide B induces neuroendocrine differentiation of human prostate LNCaP cancer cell line. *Bio. Pharmacol.*, Mar 1;63(5):951-957.
8. Tate, Christopher R. (1997). Use of a flavonoid-containing extract of the plant *Euphorbia prostrata* in the manufacture of a medicament for the treatment of an anorectic or colon disease, Free patent online United States Patent 7371412.
9. Pakistan Science Foundation. (2008). Structural Studies on the chemical constituents of some Indigenous Flowering Plants.
10. Hussain, F. (1980). Allelopathic Effects of Pakistani Weeds: *Euphorbia granulata* Forssk. *Oecologia* (Berl.) 45: 267-269.
11. Harborn, J. B. (1984). *Phytochemical methods: A guide to modern techniques of plant analysis*. 2nd ed. Chapman and Hall, New York. p.1-4.
12. Al-Shamary, A. M. H. (2003). The Study of Newcastle disease virus effect in the treatment of transplanted tumors in mice. PhD thesis. Collage of veterinary Medicine, University of Baghdad-Iraq.
13. Luna, L. G. (1968). *Manual of Histological Staining Methods of the Armed Forces Institute of Pathology*. (3<sup>rd</sup> ed.). McGraw – Hill Book Company. New York.
14. Kintzios, S. E.; Barberaki, M. G. & Makri, O. G. (2004). Terrestrial plant species with anticancer activity, *Plants that fight cancer*, (3th):34-194.
15. Nijveldt, R.; Van Nood, E.; Van Hoorn, D. E. C.; Boelens, P. G.; Van Norren, K. & Van Leeuwen, P. A. (2001). Flavonoids: A Review of Probable Mechanisms of Action and Potential Applications. *Am. J. Clin. Nutr.*, 74: 418-425.
16. Yamazaki, M. & Ueda, H. (1997). Stimulation of Leukocytes by Vegetable and Fruit Juices. In: H. Ohigashi, T. Osawa, J. Terao, S. Watanabe, T. Yoshikawa (Eds.), *Food Factors for Cancer Prevention*. Springer-Verlag, Tokyo. p. 159-161.
17. Maruchaa, Phillip T.; Crespinb, Timothy R.; Shelbyc, Rebecca A. & Andersend, Barbara L. (2005). TNF- $\alpha$  levels in cancer patients relate to social variables. *Brain, Behavior, and Immunity*, 19 (6): 521-525.
18. Lin, Y.; Shi, R.; Wang, X. & Shen, H. M. (2008). Luteolin, a flavonoid with potential for cancer prevention and therapy. *Curr Cancer Drug Targets*. Nov;8(7): 634-46.
19. Chen, Di.; Landis, Piwowar; Kristin R.; Chen, Marina S. & Ping, Dou. Q. (2007). Inhibition of proteasome activity by the dietary flavonoid apigenin is associated with growth inhibition in cultured breast cancer cells and xenografts. *Breast Cancer Res.*, 9(6): 80.
20. Adams, J.; Palombella, V. J.; Sausville, E. A.; Johnson, J.; Destree, A.; Lazarus, D. D.; Maas, J.; Pien, C. S.; Prakash, S. & Elliott, P. J. (1999). Proteasome inhibitors: a novel class of potent and effective antitumor agents. *Cancer Res.*, Jun 1; 59(11): 2615-2622.

21. Fang, J.; Zhou, Q.; Liu, L.; Chang, X.; Xiaowen, H.; Xianglin, S. & Bing-Hua, J. (2007). Apigenin inhibits tumor angiogenesis through decreasing HIF-1 $\alpha$  and VEGF expression. *Carcinogenesis- Oxford J.*, 28(4): 858-864.
22. Michaud, M. D.; Robitaille, G. A.; Gratton, J. P. & Richard, D. E. (2009). Sphingosine-1-Phosphate. A Novel Nonhypoxic Activator of Hypoxia-Inducible Factor-1 in Vascular Cells. *Arterioscler Thromb Vasc Biol.* 29(6): 902-908.
23. Ferrara, N. & Gerber, H. P. (2001). The role of vascular endothelial growth factor in angiogenesis. *Acta Haematol.*, 106(4):148-156.
24. Yoshihiro, M. (2004). Research and Development of New Steroidal Glycoside Anti-Cancer Agents with New Modes of Action. *Advances in Pharm. Sci. J.*, 20: 87-96.
25. Adrian, T. E. & Collins, P. (2005). Anticancer glycosides compounds. Northwestern University.
26. Cheeke, R. P. (1998). Saponins: Surprising benefits of desert plants. Comparative Nutrition OSU/LPI Affiliate Investigator. The Linus Pauling Institute.
27. Francis, G.; Kerem, Z.; Makkar, H. P. & Becker, K. (2002). The biological action of saponins in animal systems: a review. *The British J. of Nut.*, 88(6): 587-605.
28. Yang, L.; Lee, Chih-Ying & Kun-Ying, Y. (2000). Induction of apoptosis by hydrolyzable tannins from *Eugenia jambos* L. on human leukemia cells. *Cancer Letters*, 157:65-75.
29. Susumu, T.; Ryoji, K.; Takashi, T.; Ying-Jun, Z.; Isao, K. & Michiaki, K. (2005). Suppression of tumor cell invasiveness by hydrolyzable tannins (plant polyphenols) via the inhibition of matrix metalloproteinase-2/-9 activity. *Biochemical and Biophysical Research Communications* 330, p.1306–1313.
30. Ohtani, H. (2007). Focus on TILs: Prognostic significance of tumor infiltrating lymphocytes in human colorectal cancer. *Cancer Immunity*; 7: 4.
31. Burnet, F. M. (1957). Cancer- a biological approach. *Brit. Med. J.*, 1: 841–847.
32. Kim, R.; Emi, M. & Tanabe, K. (2007). Cancer immunoediting from immune surveillance to immune escape. *J. of Immunol.*, 121(1): 1-14.
33. Satoskar, A. A.; Burdge, K.; Cowden, D. J.; Nadasdy, G. M.; Hebert, L. A. & Nadasdy, T. (2007). Typing of amyloidosis in renal biopsies: diagnostic pitfalls. *Arch. Pathol. Lab. Med.*, 131 (6): 917–922.
34. Odunsi, K. & Old, L. (2007). Tumor infiltrating lymphocytes: indicators of tumor-related immune responses. *Cancer Immunity*, 7: 3.
35. Kamath, A. B.; Wang, L. & Das, H. (2003). Antigens in tea – beverage prime human V gamma 2delta zt cells in vitro and invivo for memory and nonmemory antibacterial cytokine responses. *Proc. Natl. Acad. Sci.*, 100:6009 – 6014.
36. Umran, M. A. (2008). Influence of Polyphenols Extracts of Green Tea *Camellia sinensis* on The Normal and Cancer Cells Lines in Vivo and In Vitro. College of Science, Baghdad University. Iraq.
37. Kumar, V.; Abbas, A. K.; Cotran, R. S. & Robbins, S. L. (2007). Robbins Basic Pathology (8<sup>th</sup>ed), p.165-210.
38. Gordon, M. S. & Hoffman, R. (1992). Growth factors affecting human thrombocytopoiesis: potential agents for the treatment of thrombocytopenia. *Blood.* 80, p. 302-307.
39. Withrow, J. S. & MacEwan, E. G. (2001). Small animal clinical oncology. Ed, 3.
40. Bernard, A. C. and Lehmann, U. C. (2009). Nodular amyloidosis. © DermAtlas, Johns Hopkins University.
41. Kroemer, G.; El-Deiry, W. S.; Goldstein, P.; Peter, M. E.; Vaux, D.; Vandenabeele, P.; Zhivotovsky, B.; Blagosklonny, M. V., Malorni, W., Knight, R. A., Piacentini, M.; Nagata, S. & Melino, G. (2005). Classification of cell death: recommendations of the Nomenclature Committee on Cell Death. *Cell Death Differ.*, 12:1463–1467.
42. Bij, Van der G. J.; Oosterling, S. J.; Meijer, S.; Beelen, R. H. & Van Egmond, M. (2005). The role of macrophages in tumor development. *Cell Oncol.*, 27: 203-213.
43. Shih, J.; Yuan, A.; Chen, J. J. W. & Yang, P. (2006). Tumor-Associated Macrophage: It's Role in Cancer Invasion and Metastasis. *J. of Cancer Molecules*, 2(3): 101-106.