

The Protective Effect of *Mentha spicata* Ethanolic Extract on Irinotecan-Induced Mucositis in Mice.

Aliaa A. S. Abdul Jabbar* and Sarmed H. Kathem^{*,1}

*Pharmacology and Toxicology Department, College of Pharmacy, University of Baghdad, Baghdad, Iraq

Abstract

Irinotecan induced-mucositis is an inflammatory event of the intestine caused by an increase in the concentration of active metabolite 7-ethyl-10-hydroxycamptothecin (SN-38) in the intestine. Irinotecan must first be converted by a carboxylesterase to the active metabolite (SN-38), which is subsequently glucuronidated by the hepatic enzyme to SN38G. The SN-38G is deconjugated in the intestine to SN-38 via β -glucuronidase produced by the intestinal bacterial flora, which accounts for SN-38 delayed intestinal mucositis of irinotecan. The present study was designed to evaluate the protective effect of mentha ethanolic extract on irinotecan-induced mucositis, intestinal mucositis induced by I.P injection of irinotecan (75mg/Kg/day) for 4 days. Mentha ethanolic extract orally administered to mice for 7 days starting one day before irinotecan dose. Results showed that mentha ethanolic extract significantly decreased both jejunal tissue IL-1 β (3.47 \pm 1.23 vs. 6.5 \pm 0.36 ng/ml), and fecal β -glucuronidase activity (79.78 \pm 10.7 vs. 120.6 \pm 8.3 U) compared to the model control group, also histopathological sections showed improvements in mucositis features in the mentha ethanolic extract treated animals. As a conclusion, Mentha ethanolic extract has a protective effect on irinotecan-induced mucositis.

Keywords: Intestinal mucositis, irinotecan, Mentha ethanolic extract, IL-1 β , fecal β -glucuronidase.

التأثير الوقائي للمستخلص الكحولي لأوراق النعناع المدبب ضد الالتهاب المعوي الناتج من الايرينوتيكان في الفئران

علياء عبد الستار عبد الجبار* و سرمد هاشم كاظم^{*,1}

*فرع الادوية والسموم، كلية الصيدلة، جامعة بغداد، العراق .

الخلاصة

الالتهاب المعوي المتسبب بواسطة الايرينوتيكان نتيجة لزيادته تركيز الايض الفعال للايرينوتيكان (SN-38) في الامعاء. الايرينوتيكان يجب ان يكون متحولاً أولاً بواسطة انزيم ال (carboxylesterase) الى دواء فعال (SN-38) والذي سوف يقترب بصوره متسلسله بواسطة انزيم الكبد الى (SN38G) والذي سوف يزال الاقتران بواسطة انزيم (β -glucuronidase) الذي ينتج من البكتريا الموجودة بصورة طبيعيه في الامعاء والتي تؤدي الى زياده تركيز (SN-38) والمسؤولة عن الالتهاب المعوي المتأخر للايرينوتيكان. لدراسة تأثير مستخلص النعناع المدبب للحمايه من الالتهاب المعوي المتأخر بواسطة الايرينوتيكان. يحفز الالتهاب المعوي لدى الفئران بواسطة حقن الايرينوتيكان في التجويف البروتوني بجرعه ٧٥ ملليغرام في اليوم الواحد ولمده ٤ ايام . يعطى مستخلص الايثانولي للنعناع فموي للفئران لمدة ٧ ايام تبداً قبل يوم واحد من جرعه الايرينوتيكان. نتيجة الدراسة شوهد ان مستخلص الايثانول للنعناع قلل نسبياً من (IL-1 β) للنسيج المعوي وقلل من فعاليه انزيم (β -glucuronidase) في فضلات الفئران مقارنة مع المجموعه المعالجه للايرينوتيكان فقط. ولقد شوهد في مقاطع التشريح النسيجي تحسن في خصائص الالتهاب المعوي في الحيوانات المعالجه بواسطة المستخلص الايثانولي للنعناع . وللاستنتاج، مستخلص الايثانول للنعناع لديه تأثير للحمايه من الالتهاب المعوي الناتج بواسطة دواء الايرينوتيكان.

الكلمات المفتاحية : الالتهاب المعوي، النعناع المدبب ، الايرينوتيكان

Introduction

Intestinal mucositis is damage occurs to the intestinal mucosal membrane, one of the most harmful side effects of chemotherapy and radiotherapy treatment. Mucositis presents with symptoms as intestinal and oral pain, vomiting, diarrhea, sore mouth and destruction of the gastrointestinal epithelium that contributes to poor absorption of nutrients and, consequently, weight loss⁽¹⁾. The development of mucositis can be divided into five phases, the first phase, known as the initialization phase, occurs after chemotherapy administration resulting in cell injury. This lesion might be a result of direct DNA damage or caused

via generation of reactive oxygen species (ROS)⁽²⁾. The Second phase is a Primary damage response that DNA strand breaks and reactive oxygen species (ROS) activate a series of interacting biological events by the activation of various transcription factors⁽³⁾. The third phase is signal amplification, the presence of pro-inflammatory cytokines induces heightened tissue damage leading to a vicious circle in the signal amplification keep on increasing cytokines and oxidative stress levels then resulting in more extreme tissue damage and apoptosis and the epithelium initiates to lose integrity⁽²⁾.

¹Corresponding author E-mail: skathem@copharm.uobaghdad.edu.iq

Received: 17 /9/2018

Accepted: 14 /10/2018

The fourth phase is ulceration phase, clinical appearances of mucositis become apparent as mucosal integrity is lost and formed painful lesions⁽²⁾. The final healing phase occurs after the ending of cancer therapy. Irinotecan (CPT-11) is a topoisomerase I inhibitor. It's the hydrochloride salt of a semisynthetic derivative of camptothecin with higher water solubility than camptothecin. Irinotecan was first approved for the treatment of metastatic colorectal cancer (CRC) in the United States in 1996⁽⁴⁾. Irinotecan interacts with cellular Topo I-DNA complexes and has S-phase-specific cytotoxicity. At greater concentrations of irinotecan non-S-phase cells can also be killed. The mechanism of non-S-phase cell killing appears to be related to transcriptionally induced DNA damage and through apoptosis mechanism⁽⁵⁾. Irinotecan must first be converted by a carboxylesterase (CES) to the active metabolite 7-ethyl-10-hydroxycamptothecin (SN-38). The SN-38 is the major metabolite believed to be responsible for irinotecan's biologic effects which including, efficacy and toxicity. The (SN38) is detoxified chiefly by uridine diphosphate glucuronosyltransferases (UGTs) specifically the hepatic UGT1A1 and UGT1A9, in the liver to form inactive SN-38 glucuronide (SN-38G). Common unwanted adverse effects of irinotecan are bone marrow toxicity leading to abnormal blood counts, in specific leukopenia, and mucositis, which leads to diarrhea⁽⁶⁾. SN-38G is deconjugated to SN-38 via β -glucuronidase produced by the intestinal bacterial flora which accounts for the late SN-38 double peaks in the plasma, and responsible for the delayed intestinal toxicity of irinotecan⁽⁷⁾. CPT-11 also increases nuclear factor- κ B (NF- κ B) and cytokines (TNF- α , IL-1 β , IL-6, and KC levels) and myeloperoxidase activity in intestinal tissue which involved in the pathogenesis of mucositis⁽⁸⁾. *Mentha Spicata* synonym *Mentha Viridis*, among the family of Lamiaceae (Labiatae). Used as fresh or dried leaves or powder, as a seasoning and flavouring herb or traditionally as an herbal. The mentha is also commonly used as an antimicrobial agent and as a preservative in food⁽⁹⁾. The Polar extracts of mentha leaves are characterized mostly by a high content of phenolic compounds, such as rosmarinic acid, luteolin and apigenin derivatives⁽¹⁰⁾. Some of these components have been revealed to have antioxidant properties, so, the *Mentha spicata* could also be considered an antioxidant source⁽¹¹⁾. More interestingly, the anti-inflammatory properties of Mentha extract rich in phenolic compounds have been confirmed in vivo in rats⁽¹²⁾. In term of biological uses, mentha acts as antispasmodics and anti-platelets and insecticides⁽¹³⁾. Also, mentha is

considered as herbal medicine in folklore remedies for treating of colds and flu and respiratory tract problems, gastralgia, hemorrhoids, and the stomachache. The goal of this study to evaluate the protective effect of *Mentha spicata* ethanolic extract on irinotecan-induced intestinal mucositis in mice.

Materials and Methods

Chemicals and kits

The chemicals that were used in this work includes, diethyl ether (BDH Chemicals, England), formalin (Merck Chemicals, Germany), irinotecan vial (Kocak pharma, Turkey), Mice Interleukin-1 β for enzyme-linked immune sorbent assay (ELISA) (Shanghai, China), 4- Nitrophenyl-B-D-glucuronide substrate for enzyme (Sigma, USA), Dimethyl sulfoxide (Merck chemical, Germany), Ethanol solution (Merck chemical, Germany).

Animal selection

Twenty four Albino female mice (8 weeks) weighing between (25-38 gm) were selected randomly and maintained in the Animal House at the College of Pharmacy/University of Baghdad. Animals were maintained under controlled conditions of temperature, humidity and light/dark cycle. They were fed standard rodent pellet diet and have free access to water.

Plant collection

Fresh plant of *Mentha spicata* collected from different areas of Baghdad/al-Resafa at October, the plant was identified for the authentication purpose by (Dr. Sucaina at the department of biology/College of Science/University of Baghdad). The leaves of the mentha were used and dried at room temperature, then crushed by mortar and pistol to be extracted by maceration method.

Extraction of the plant

One hundred fifty gram of air-dried leaves of mentha plant was crushed in mortar and pistol to be extracted by maceration with 1500 ml of ethanol solvent in a closed container at room temperature for three day, then the mentha ethanolic extract filtered using a Whitman filter paper and evaporated under reduced pressure by rotary evaporator at 42 C to concentrate and dry the extract⁽¹⁴⁾. After that, the collected amount was weighted.

Preparation of stock solution for ethanolic extract fraction

A stock solution of *Mentha Spicata* ethanolic extract was freshly prepared by dissolving 960 mg of ethanolic extract in 10 ml of 2% of dimethyl sulfoxide (DMSO) to obtain a concentration (9.6mg/0.1ml) according to mentha ethanolic extract dose for mice 320 mg/Kg/day⁽¹⁵⁾.

Experimental protocol

The animals used in this study divided into four groups each with 6 mice as follows:

Group I: Six mice received a single oral dose of 0.1ml of normal saline for 7 successive days starting day 0. This group served as a blank control group.

Group II: Six mice received a single dose of 0.1ml intraperitoneal irinotecan (75mg/kg) for 4 successive days starting day1. This group served as a model control group ⁽¹⁶⁾.

Group III: Six mice received a single dose of 0.1ml intraperitoneal irinotecan (75mg/kg) for 4 successive days starting day 1 with 0.1ml of 2% DMSO by oral gavage for 7 successive days starting day 0.

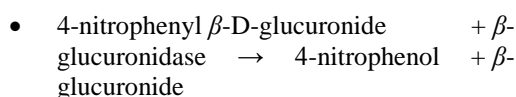
Group IV: Six mice received 0.1ml single orally dose of mentha ethanolic extract (320mg/kg/day) for 7 successive days starting day 0 with an intraperitoneally single dose 0.1ml of irinotecan (75mg/ kg) for 4 successive days starting day 1 ⁽¹⁷⁾. Animal received mentha ethanolic extract 0.1 ml by oral gavage in the morning at 8 AM before 1/2 hour of irinotecan injection. The extracts treatment started one day before irinotecan administration (day 0) and continued to the two days after the last irinotecan dose was administered, a total of 7 days.

Preparation of jejunum tissue homogenate

animals have been euthanized at (day 7) under light diethyl ether anesthesia. Abdomen is opened by a midline incision and two horizontal incisions then the jejunum of each animal utilized in this study is quickly dissected, placed in chilled phosphate buffer saline solution (PBS) at (pH7-7.2) at 4°C to remove excess blood, then the tissue dried with filter paper and weighed then was minced to small pieces; where, 1 g of jejunum was put in tube containing 9 ml of (0.01M) phosphate buffer saline solution. The resulting homogenate was centrifuged at 5000 rpm for 10 minutes at 4°C then the supernatant is separated using micropipette and store at -20°C until the day of analysis. The jejunum tissue homogenate utilized for the estimation of interleukin one beta (IL-1β) level.

Fecal β-Glucuronidase assay

The activity of intestinal bacterial β-glucuronidase in mice feces was measured by the method described by Shiau and Chang ⁽¹⁸⁾. Briefly, fresh fecal pellets were collected in the morning before and after irinotecan administration in (day 0 and day 5), then weighed and mixed with PBS (0.01 M, pH 7.5) at a (wt/wt) ratio of (1:100). After softening for 20 min, the fecal pellets were homogenized. Then 0.05 mL of 4-nitrophenyl β-D-glucuronide (0.01 M, Sigma, USA) was added to 1 mL diluted fecal homogenate to produce the following reaction:



All reaction solutions were incubated at 37°C for 60 min and then centrifuged at 3000g for 10 min.

The absorbance of each supernatant solution was measured at 405 nm in a spectrophotometer (APLE-PD303, Japan). The concentration of 4-nitrophenol in each sample was calculated by reference to a standard curve at the same time and conditions. The activity of fecal β-glucuronidase was measured as one unit of an enzyme that cleaves 1 nmol of 4-nitrophenol per hour at 37°C under saturated substrate concentrations.

Histopathological examination of the mice jejunum

At the end of the experiment period, all the animals were sacrificed, 5-cm ring from the proximal area (close to the duodenojejunal flexure) of each harvested jejunum was carefully removed, washed in a normal saline solution and fixed in 10% formalin solution. Jejunum tissues were prepared for histological examination according to the method of Junqueira LC. *et al.* ⁽¹⁹⁾, using paraffin sections technique.

Statistical analysis

The experiment design used for these studies was Rationalized Complete Block Design (RCBD). The results were presented as means ± standard deviation (SD). One way analysis of variance (ANOVA) followed by Dunnett method. The differences between the means are considered significant at the 5% confidence level.

Results

Effects of mentha ethanolic extract on intestinal tissue IL-1β level

Mice that orally treated with normal saline (group I) and mice that orally treated with mentha ethanolic extract and CPT-11 (group IV) showed a significant reduction ($p < 0.05$) in the tissue level of IL-1β compared with model control group (group II), as shown in table 1.

Table (1) Effects of mentha ethanolic extract on jejunum IL-1β level in mice.

Treatment groups N=6	Type of treatment	IL-1β (ng/ml) mean ± SD
I	Normal saline	0*
II	irinotecan	6.5±0.36
III	Irinotecan +DMSO	6.9±0.32
IV	Mentha extract +irinotecan	3.47±1.23*

(*): Significant difference with respect to the model control group ($P < 0.05$).

N: number of animals.

Effects of mentha ethanolic extract on fecal β-glucuronidase enzyme activity

As shown in table 2, on the day (0), the mean for mentha ethanol extract group showed non-significant changes in β-glucuronidase activity ($p > 0.05$) compared with model control (group II).

On the day (5), mice treated with mentha ethanolic extract and CPT-11 (group IV) showed a significant reduction in fecal β -glucuronidase activity ($p < 0.05$)

compared with model control (group II), as shown in table 2.

Table(2) Comparison of the intestinal β -glucuronidase activity in different groups.

Treatment groups N=6	Type of treatment	Day 0 β -glucuronidase activity (U) mean \pm SD	Day 5 B-glucuronidase activity (U) mean \pm SD
I	Normal saline	83.9 \pm 12.2	84.45 \pm 11.5*
II	irinotecan	74.32 \pm 13.6	120.6 \pm 8.3
III	Irinotecan +DMSO	78.69 \pm 15.7	111.25 \pm 11.2
IV	Mentha extract +irinotecan	81.19 \pm 13.3	79.78 \pm 10.7*

Notes: one unit of enzyme activity is the amount of enzyme that will cleave (1 nmol) of the colorimetric substrate per hour at 37°C under saturated substrate concentrations.

(*): Significant difference with respect to the model control group ($P < 0.05$).

N: number of animals.

Histopathological examination of mice jejunum sections

Histopathological examination of group I (normal saline group) showed the normal structure of intestinal villi, no inflammatory cell infiltration and without dysplastic cells change (Figure 1).

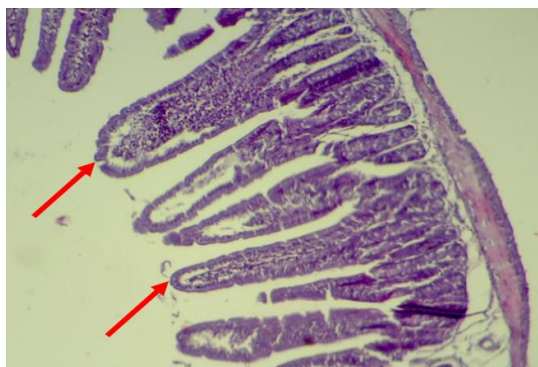

Figure (1) Cross section is showing normal mice jejunum in group I.

Magnification (100X), staining: Haematoxyline and Eosin.

Red arrow: sign to normal intestinal villi.

Histopathological examination of group II (irinotecan group) showed atrophy of intestinal villi with heavy chronic inflammatory cells infiltration and moderate dysplastic cell change (Figure 2).

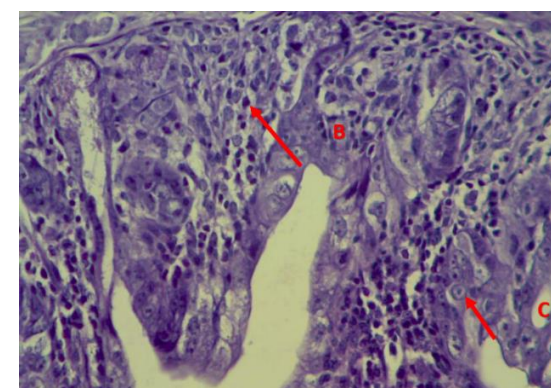
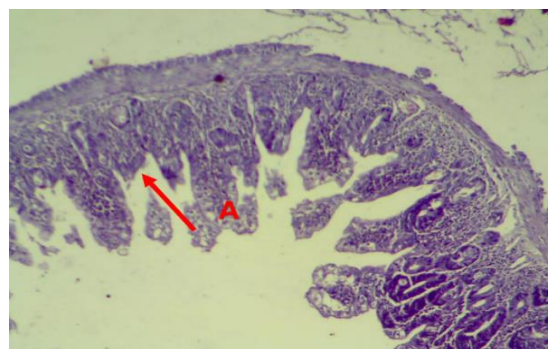

Figure (2) Cross sections showing abnormal mice jejunum in group II. Magnification: (100 X and 400 X); staining: Haematoxyline & Eosin.

A: villi atrophy.

B: chronic inflammatory cells infiltration.

C: dysplastic cell change

Histopathological examination of group III (CPT-11+ DMSO) showed atrophy of intestinal villi with heavy chronic inflammatory cells infiltration with mild to moderate dysplastic cell change (Figure 3).

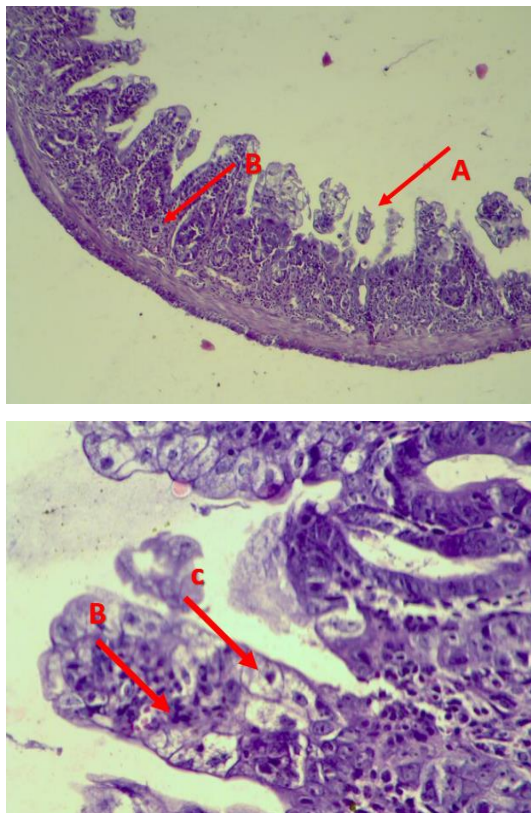


Figure (3) Cross sections showing mice jejunum in group III. Magnification: (100X, 400X), staining: Haematoxyline & Eosin. A: villi atrophy. B: chronic inflammatory cells infiltration. C: dysplastic cell change.

Histopathological examination of group IV (mentha ethanolic extract +CPT-11) showed shortening of intestinal villi with chronic inflammatory cell infiltration but less than the model control group. Sections showed no dysplastic changes (Figure 4).

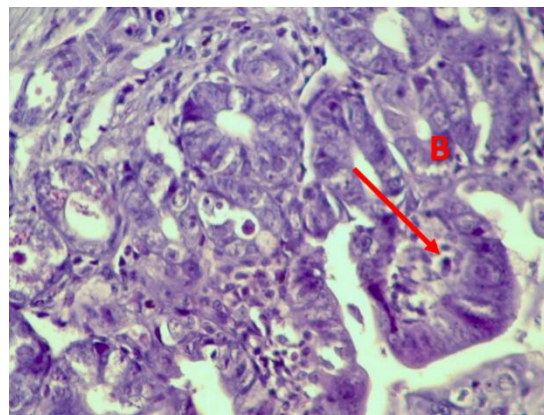
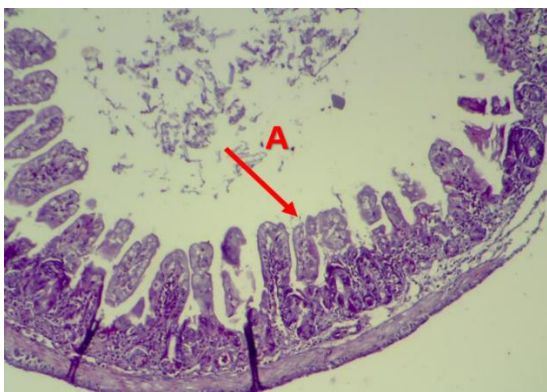


Figure (4) Cross sections showing mice jejunum in group IV. Magnification: (100 X and 400 X), staining: Haematoxylin & Eosin

A: marked shortening of intestinal villi. **B:** chronic inflammatory cell infiltration.

Discussion

Mucositis is the painful inflammation and ulceration of mucous membranes lining the digestive tract, as a result of chemotherapy and radiotherapy treatment for cancer ⁽²⁰⁾. Cytotoxic chemotherapy can cause functional and structural changes in the gastrointestinal tract (GIT). Common gastrointestinal symptoms following chemotherapy include heartburn, abdominal pain, diarrhea and constipation, bloating and nausea. These symptoms arise as the result of the damage caused by chemotherapy agents ⁽¹⁾. The pathogenesis of irinotecan-induced intestinal toxicity may involve oxidative stress; irinotecan enhanced production of reactive oxygen species (ROS) and reactive nitrogen species, which induce cell death. The ROS can also activate the transcription nuclear factor kappa-light-chain-enhancer of activated B cells (NF.κB) ⁽²⁾. The study has shown significant increases in the expression of pro-inflammatory cytokines, with key offenders TNF, IL-1β, IL-4, IL-6 ⁽²⁾. Microbiota can influence the efficacy and toxicity of drugs by regulating the levels of metabolic enzymes and transporters. Inactivated metabolite of irinotecan, SN-38G, is reactivated to SN-38 by bacterial β-glucuronidase in the intestinal tract ⁽²¹⁾.

In the present study, histological examination of the jejunum sections from mice received irinotecan showed atrophy of intestinal villi with heavy chronic inflammatory cells infiltration, few crypt glands with moderate dysplastic cell change. These changes indicated that irinotecan-induced intestinal mucositis as shown in (Figure 2). This result confirmed by other study reported that irinotecan causes severe jejunum and colonic damage like villous atrophy, crypt hypoplasia, increased apoptosis, dilation, and excessive mucous secretion. Increased levels of cell apoptosis combined with the histopathological changes in both the jejunum and colon and the changes in goblet cell numbers may

cause changes in absorption rates, possibly leading to diarrhea⁽²²⁾.

The present study showed a significant increase in the IL-1 β in mice jejunum that confirmed irinotecan-induced intestinal mucositis mediated by inflammation. Other study confirmed that IL-1 β production plays a crucial role in mucositis⁽²³⁾. Importantly, this study showed that irinotecan significantly increased fecal β -glucuronidase activity. The structure of the intestinal microbial community and increase β -glucuronidase activity by irinotecan. These changes increase irinotecan toxicity as more SN-38 (the active form of the drug responsible for toxicity) will be liberated⁽²⁴⁾.

Histological examination of the jejunum section from animal received irinotecan with mentha ethanolic extract showed improvements in histopathological finding compared with models control group for intestinal toxicity induced by irinotecan. These improvements include mild shortening of intestinal villi, with mild chronic inflammatory cells infiltration, no dysplastic cell change compared with the model control group. The successful reduction in intestinal toxicity induced by irinotecan in mice treated with mentha ethanolic extract showed in the jejunal histopathological sections confirmed by reduction in tissue IL-1 β level. The Polar extract of mentha leaves is characterized by a high content of phenolic compounds, such as rosmarinic acid, luteolin and apigenin derivatives⁽¹⁰⁾. More interestingly, the anti-inflammatory properties of Mentha extract rich with phenolic compounds have been confirmed *in vivo* in rats⁽¹²⁾. In addition, mentha ethanolic extract significantly decreased fecal β -glucuronidase activity (Table 2). The lower β -glucuronidase activity by mentha extract leads to the lower liberation of SN-38, which ultimately decreased intestinal mucositis. The resulted improvements in irinotecan-induced mucositis obtained from Mentha extract may be explained by First, the novel direct inhibitory effect of the extract on β -glucuronidase activity that reduced mucositis as confirmed by this study⁽¹²⁾. Second, the indirect effect of the extract on mucositis due to mentha anti-inflammatory effect as confirmed in this study by reduction of the IL-1 β level^(25,26).

Conclusion

Data obtained from the presented study suggested that mentha ethanolic extract has anti-inflammation activity and anti- β -glucuronidase activity, by the decreased intestinal level of IL-1 β and fecal β -glucuronidase activity, respectively. So, the ethanolic mentha extract has protective effects against irinotecan-induced mucositis.

References

1. Stringer AM, Gibson RJ, Bowen JM, Logan RM, Yeoh AS-J, Keefe DMK. Chemotherapy-induced mucositis: the role of gastrointestinal

- microflora and mucins in the luminal environment. J Support Oncol [Internet]. 2007;5(6):259–67.
2. Araújo RS, de Barros ALB. Intestinal Mucositis Induced by Chemotherapy: an Overview. J Mol Pharm Org Process Res [Internet]. 2015;03(03):18–9.
3. Sultani M, Stringer AM, Bowen JM, Gibson RJ. Anti-Inflammatory Cytokines: Important Immunoregulatory Factors Contributing to Chemotherapy-Induced Gastrointestinal Mucositis [Internet]. Vol. 2012, Chemotherapy Research and Practice. 2012. p. 1–11.
4. Fujita KI, Kubota Y, Ishida H, Sasaki Y. Irinotecan, a key chemotherapeutic drug for metastatic colorectal cancer. World J Gastroenterol. 2015;21(43):12234–48.
5. Xu Y, Villalona-Calero MA. Irinotecan: Mechanisms of tumor resistance and novel strategies for modulating its activity. Vol. 13, Annals of Oncology. 2002. p. 1841–51.
6. Tukey RH, Strassburg CP, Mackenzie PI. Pharmacogenomics of Human UDP-Glucuronosyltransferases and Irinotecan Toxicity [Internet]. Vol. 62, Molecular Pharmacology. 2002. p. 446–50.
7. Stringer AM, Gibson RJ, Bowen JM, Logan RM, Ashton K, Yeoh ASJ, et al. Irinotecan-induced mucositis manifesting as diarrhoea corresponds with an amended intestinal flora and mucin profile. Vol. 90, International Journal of Experimental Pathology. 2009. p. 489–99.
8. Kanarek N, Grivennikov SI, Leshets M, Lasry A, Alkalay I, Horwitz E, et al. Critical role for IL-1 β in DNA damage-induced mucositis [Internet]. Vol. 111, Proceedings of the National Academy of Sciences. 2014. p. E702–11.
9. Cirilini M, Mena P, Tassotti M, Herrlinger KA, Nieman KM, Dall'Asta C, et al. Phenolic and volatile composition of a dry spearmint (*Mentha spicata* L.) extract. Molecules. 2016;21(8):1–15.
10. Pierluigi Caboni, Marco Saba, Graziella Tocco LC, Antonio Murgia AM, Urania Menkissoglu-Spiroudi NN. Nematicidal Activity of Mint Aqueous Extracts against the Root-Knot Nematode *Meloidogyne incognita*. Vol. 61, Journal of Agricultural and Food Chemistry. 2013. p. 9784–9788.
11. Kanatt, S.R.; Chander R. S. Antioxidant potential of mint (*Mentha spicata* L. 2007. p. 100, 451–458.
12. Arumugan, P.; Gayatri Priya, N.; Subathra, M.; Ramesh A. Anti-inflammatory activity of four solvent fractions of ethanol extract of *Mentha spicata* L. 2008. p. 26, 92–95.
13. Tognolini M, Barocelli E, Ballabeni V, Bruni R, Bianchi A, Chiavarini M, et al. Comparative screening of plant essential oils: Phenylpropanoid moiety as basic core for antiplatelet activity. Vol. 78, Life Sciences.

2006. p. 1419–32.
14. Arumugam P, Ramamurthy P, Ramesh A. Antioxidant and cytotoxic activities of lipophilic and hydrophilic fractions of *Mentha spicata* L. (Lamiaceae). *Int J Food Prop.* 2010;13(1):23–31.
 15. Arumugam P, Priya NG, Subathra M, Ramesh A. Anti-inflammatory activity of four solvent fractions of ethanol extract of *Mentha spicata* L. investigated on acute and chronic inflammation induced rats. *Environ Toxicol Pharmacol.* 2008;26(1):92–5.
 16. Arifa RDN, Madeira MFM, De Paula TP, Lima RL, Tavares LD, Menezes-Garcia Z, et al. Inflammasome activation is reactive oxygen species dependent and mediates irinotecan-induced mucositis through IL-1 β and IL-18 in mice. Vol. 184, *American Journal of Pathology.* 2014. p. 2023–34.
 17. Arumugam P, Ramesh A. Protective effects of solvent fractions of *Mentha spicata* (L .) leaves evaluated on 4-nitroquinoline-1-oxide induced chromosome damage and apoptosis in mouse bone marrow cells. 2009;852:847–52.
 18. Shiau SY, Chang GW. Effects of dietary fiber on fecal mucinase and beta-glucuronidase activity in rats. Vol. 113, *The Journal of nutrition.* 1983. p. 138–44.
 19. Junqueira, LC; Carneiro, J. and Kelley R. *Basic Histology.* 8th Ed, Lange Medical Book. 1995. p. 30G–314G: p.1–2.
 20. Stringer AM, Gibson RJ, Logan RM, Bowen JM, Yeoh ASJ, Laurence J, et al. Irinotecan-induced mucositis is associated with changes in intestinal mucins. Vol. 64, *Cancer Chemotherapy and Pharmacology.* 2009. p. 123–32.
 21. Deng C, Deng B, Liqin jia et al. Preventive Effects of a Chinese Herbal Formula, Shengjiang Xiexin Decoction, on Irinotecan-Induced Delayed-Onset Diarrhea in Rats. 2017.
 22. Gibson RJ, Bowen JM, Inglis MRB, Cummins AG, Keefe DMK. Irinotecan causes severe small intestinal damage, as well as colonic damage, in the rat with implanted breast cancer. Vol. 18, *Journal of Gastroenterology and Hepatology (Australia).* 2003. p. 1095–100.
 23. Arifa RDN, Madeira MFM, De Paula TP, Lima RL, Tavares LD, Menezes-Garcia Z, et al. Inflammasome activation is reactive oxygen species dependent and mediates irinotecan-induced mucositis through IL-1 β and IL-18 in mice. *Am J Pathol.* 2014;184(7):2023–34.
 24. Stringer AM, Gibson RJ, Logan RM, Bowen JM, Yeoh ASJ, Keefe DMK. Faecal microflora and beta-glucuronidase expression are altered in an irinotecan-induced diarrhea model in rats. [Internet]. Vol. 7, *Cancer biology & therapy.* 2008. p. 1919–25.
 25. Abdul-Lateef Molan* and Abdulkhaliq Saleh Mahdy. Iraqi medicinal plants: Total flavonoid contents, free-radical\scavenging and bacterial beta-glucuronidase inhibition activities\ n. *IOSR J Dent Med Sci [Internet].* 2014;13(5):72–7.
 26. Raghad A. Khaleel, Munaf H. Zalzala. Ameliorating effect of oral guggulsterone administration in imiquimode-induced psoriasis in mice. *Iraqi J Pharma Sci.* 2018;27:15-23.