



The effect of theranekron D6 on the healing of intestinal anastomosis in dogs

A.S. Al-Qadhi^{ID}, I.A. Zedan^{ID}, R.R. Al-Ajeli^{ID}, M.T. Salem^{ID} and A.Kh. Ali^{ID}

Department of Surgery and Theriogenology, College of Veterinary Medicine, University of Mosul, Mosul, Iraq

Article information

Article history:

Received April 18, 2021

Accepted July 12, 2021

Available online December 26, 2021

Keywords:

Tarantula cubensis extract

Intestinal anastomosis

Dogs

Correspondence:

A.S. Al-Qadhi

ahmedqadhi84@yahoo.com

Abstract

To investigate the effects of systemic administration of Theranekron (*Tarantula cubensis*) extract as homeopathic remedy on anastomosis healing after surgical intestinal resection. Eight healthy stray dogs (age 1-1.5 years, weight 15-20 kgs) were randomly divided into two groups; control (4 animals) and treatment group (4 animals). Intestinal resection and anastomosis were performed in all animals in both groups. Theranekron D6 (3 ml) was administered subcutaneously one week before surgery and at operation time in the treatment group whereas animals of the control group were injected 3 ml of normal saline at the same time points of treatment group. All animals were kept for 15 days following surgery and a segment of intestine was removed for histopathological and press pressure measurement. The results showed that no post-operative complications have been observed in both groups. The gross examination of the anastomosis site revealed sever adhesions with omentum and other intestinal segment of the all animals of the control group in comparison to the treatment group where lesser adhesions with omentum without any adhesion with the other intestinal segment have been noticed. There was slight difference between control and treatment group in relation to histopathological examination. In conclusion, the findings of this study showed that Theranekron was able to improve the healing process of the resected and anastomosed intestinal segment.

DOI: [10.33899/ijvs.2021.129975.1712](https://doi.org/10.33899/ijvs.2021.129975.1712), ©Authors, 2022, College of Veterinary Medicine, University of Mosul.

This is an open access article under the CC BY 4.0 license (<http://creativecommons.org/licenses/by/4.0/>).

Introduction

Intestinal anastomosis can be defined as the creation of a connection between two intestinal segments to re-establish intestinal continuity. An intestinal anastomosis becomes necessary when resection of a segment on the gastrointestinal tract is performed for benign or malignant indications and gastrointestinal continuity needs to be restored (1). Techniques used for intestinal anastomosis include hand-sewn suture techniques, stapled techniques, and sutureless anastomosis. Different tissue sealants have been used involving fibrin glue with or without a collagen patch, platelet-rich plasma or cyanoacrylate adhesives (2). The basic and simple objective of sutured or stapled anastomosis construction is to ensure an appropriate edge-to-edge apposition for healing. It is necessary to achieve

optimal distance, lesser tension and suitable suture or staple tightness to preserve appropriate blood perfusion to the anastomotic parts of the intestine (3). The ideal anastomosis is one, which does not associate with leakage, obstruction, and facilitates restoration of normal bowel function within a few days of reconstruction. The greatest morbidity and mortality is not related to the development of postoperative bowel complications but to delay in recognizing problems and instituting management (4). Intestinal anastomosis is evaluated by many common parameters such as histologic healing (microcirculation and adhesion formation), bursting, breaking, tensile strength and luminal diameter, morbidity and mortality (5). Histologically, variable healing models are showed by different anastomotic patterns, but in evaluating technique it must be mentioned that an intestine shows the basic healing curve of all soft tissues. Theranekron D6 is

veterinary product which includes *Tarantula cubensis* alcoholic extract and it is prepared from the spider *Tarantula cubensis*. The homeopathic usage of this product in veterinary medicine involves demarcation provider, epithelialization accelerator and edema relieving effects in trauma or necrosis caused by disorders and various infectious diseases (6). Many studies confirmed the positive effects of the theranekron in wound healing, contraction of wound and epithelization (7). The most common indications for intestinal resection and anastomosis include many affections such as intestinal neoplasia, intussusception, ischemia and trauma. Perforated or ulcerated intestines that are obstructed by foreign bodies may also require resection (2). The main objective of this study was to assess mechanically and histologically the effect of theranekron D6 on healing process of intestinal anastomosis in dogs.

Materials and methods

Animals Eight healthy stray dogs 15-20 Kg body weight and 1-1.5 years old were used in this study. Animals were randomly divided into 2 groups: control and treatment group, each one consisted of 4 animals. Intestinal resection and anastomosis was performed in all animals. Theranekrone 3 ml was injected at time of surgery and seven days later in the treatment group where as normal saline was injected in the control group. The operated animals were evaluated by postoperative gross examination of the anastomosis for wound infection, adhesion formation, leakage, stricture and pathological examination for inflammatory cell infiltration, neovascularization, and collagen deposition.

Surgical procedures

The operation was done under general anesthesia using a mixture of ketamine 10mg/Kg and xylazine 4mg/Kg. ventral abdominal wall was prepared for aseptic surgery and an incision of 5-7 cm length was made in midline through skin, subcutaneous fascia and linea alba to expose and pullout the segment of small intestine to be respected. Complete circular incision was used to perform intestinal resection and the two ends of intestine was sutured together with 3/0 synthetic absorbable suture material (Vicryl) by simple interrupted technique. The abdominal wall was closed by surgical routine method. 3ml of Theranekron D6 Injectable solution was administered two times subcutaneously one weak prior to surgery and at operation time whereas animal of control group was received 3 ml of normal saline as mentioned in treatment group. The dogs remain under observation for 15 days and intestinal samples were collected at the end of the study for histopathological examination and comparative measurement of the pressure tolerance applied on all intestinal segment which were subjected to anastomosis.

Results

Clinical evaluation

The daily clinical inspection and monitoring of animals revealed no severe signs which might be reported as sequelae to intestinal surgery such as severe abdominal pain, abdominal distension which may result from post-operative hemorrhage and other signs of wound infection. Both groups show no post-operative clinical complications. In control group, the gross anastomosis site findings revealed Sever adhesions with omentum and other intestinal segment of all animals in comparison to the treated group where lesser and absent adhesions with omentum and other intestinal segment were observed. Other complications related to intestinal surgery in dogs such as leakage and stricture were not observed in the both control and treatment groups. Furthermore, wound intestinal infection in the anastomotic site was noticed in the both group of the study.

Histological evaluation

Histological examination of the intestine at the site of anastomosis for the control group showed degeneration and necrosis of epithelial cells lining the villi and mucous glands and sloughing of villi apex, proliferation of inflammatory cells (Figure 1) formation of granulation tissue at the site of anastomosis with extensive proliferation of inflammatory cells (lymphocytes, macrophages, plasma cells with fibroblast and collagen fibers) (Figure 2) sever congestion of blood vessels, slight infiltration of inflammatory cells noted in the sub mucosal layer, formation of granulation tissue ,deposition of collagen fibers, newly blood vessels formation and proliferation fibroblast was also observed at the site of anastomosis (Figure 3).

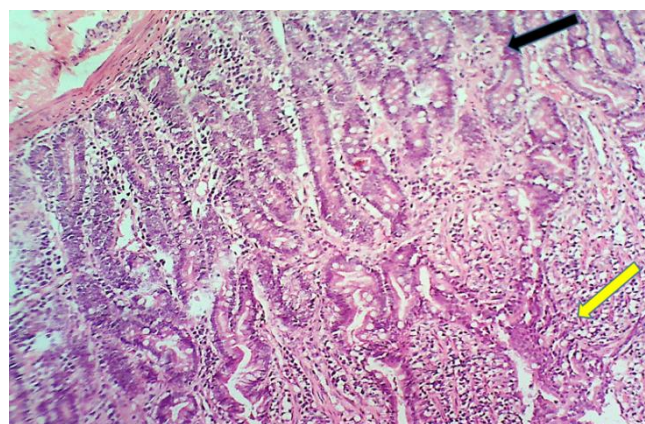


Figure 1: Microscopic section of the anastomotic site of intestine, control group shows degeneration and necrosis of epithelial cells lining the villi and mucous glands (Black arrow) and inflammatory cells (Yellow arrow). H&E, x10.

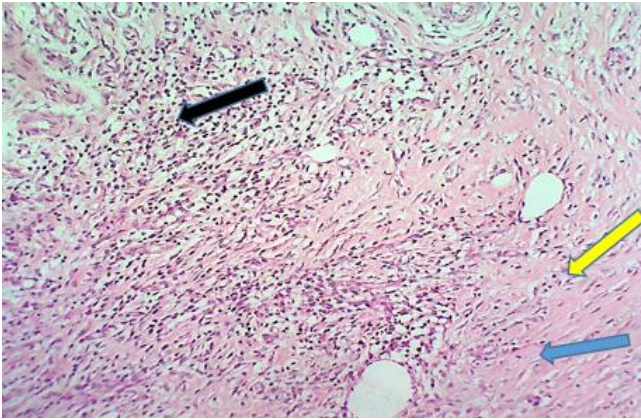


Figure 2: Microscopic section of the anastomotic site of intestine, control group shows inflammatory cells (Black arrow), fibroblasts (Yellow arrow) and collagen fibers (Blue arrow). H&E, x10.

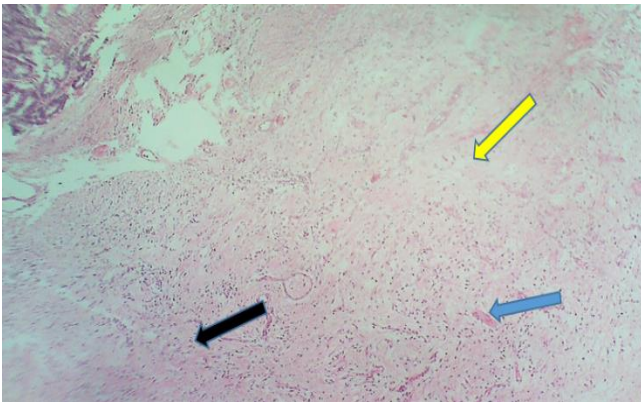


Figure 3: Microscopic section of the anastomotic site of intestine, control group shows slight infiltration inflammatory cells (Black arrow), collagen fibers (Yellow arrow) and new blood vessel (Blue arrow). H&E, x10.

In the treated group, histological examination of the intestinal mucosa in the anastomotic site showed infiltration of inflammatory cells in the mucosal layer and lamina propria (lymphocyte, macrophage and plasma cells), distortion of intestinal villi with variable height and shape. Proliferation of intestinal glands and crypts were also noted (Figure 4). Chronic inflammation and granulation tissue at the site of anastomosis was observed (Figure 5).

Sloughing and desquamation of villus epithelial cells. Sloughing and desquamation of villus epithelial cells (Figure 6) were also observed. Inflammatory granulation tissue with infiltration of mononuclear cells with foreign body giant cells macrophages and lymphocytes.

Granulomatous inflammation increased thickness of blood vessels wall and granulomatous reaction (Figure 7 and 8) was also noted.

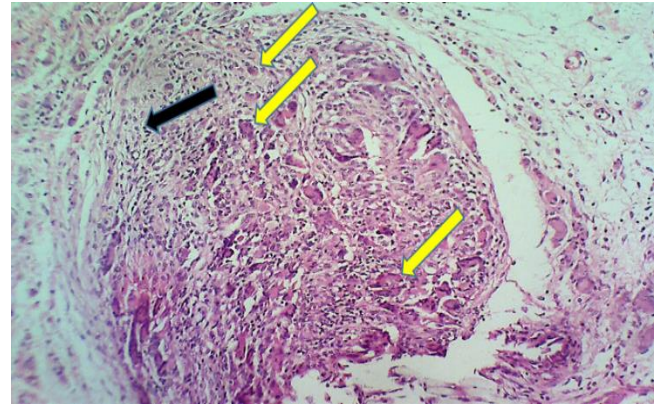


Figure 4: Microscopic section of the anastomotic site of intestine, treatment group shows lymphocyte (Black arrow) and macrophages (Yellow arrows). H&E, x40.

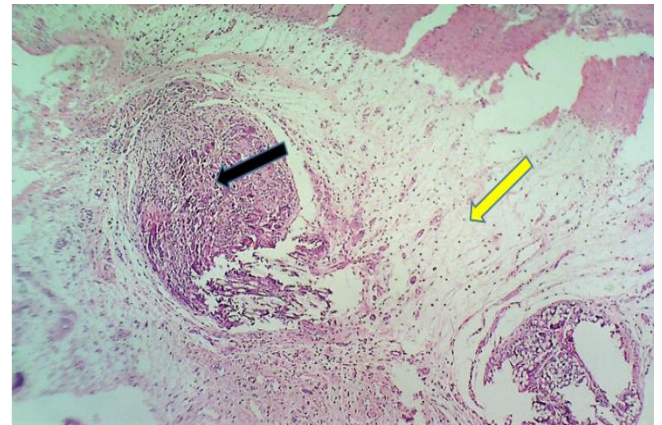


Figure 5: Microscopic section of the anastomotic site of intestine, treatment group shows chronic inflammation (Black arrow) and granulation tissue (Yellow arrow). H&E, x10.

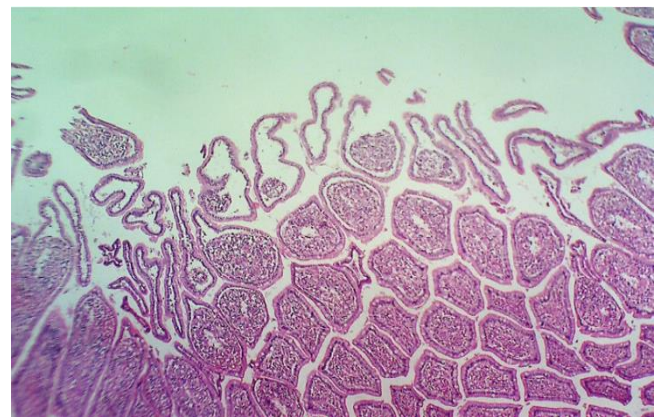


Figure 6: Microscopic section of the anastomotic site of intestine, treatment group shows desquamation and sloughing of villi apex. H&E, x10.

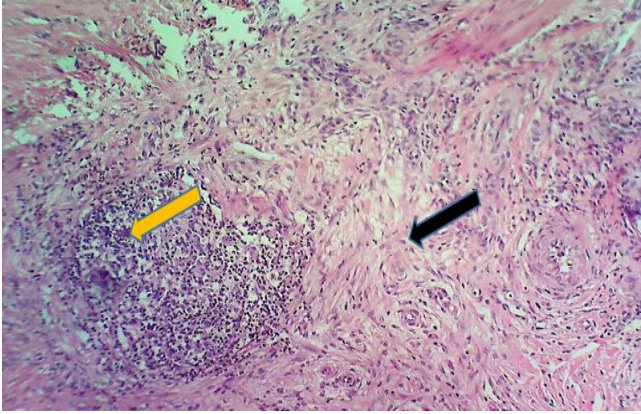


Figure 7: Microscopic section of the anastomotic site of intestine, treatment group shows mild granulation tissue (Black arrow) with focal infiltration of mono nuclear inflammatory cells (yellow arrow). H&E, x10.

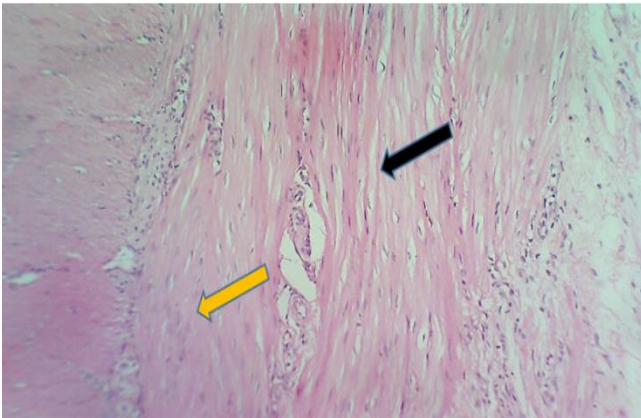


Figure 8: Microscopic section of the anastomotic site of intestine, treatment group shows mature collagen fibers (Black arrow) with few numbers of fibroblasts and inflammatory cells (yellow arrow). H&E, x10.

Discussion

Intestinal healing is a complex process. Inflammatory responses at any part within the bowel lead to an increased collagenase activity throughout the gastrointestinal tract. The collagenase activity reduces the collagen content of the submucosa, which is insides the holding layer for intestinal apposition. Collagen content reaches the lowest level during the lag phase of healing, approximately 3 days following surgery, and the decreased collagen concentration results in weakness of the tissue and delays healing (8).

The present study aimed to evaluate the clinical and pathological effects of theranekron on intestinal anastomosis. The results of our study in both groups showed no post-operative clinical complications which could be attributed to either well planned and performed surgical

procedures and attentive post-operative care as reported by previous study which demonstrated that the use of either hand-sewn or intestinal stapling devices, attention to detail is very important to achieve a satisfactory outcome (5) or to the positive effects of theranekron on the healing process of the intestinal tissue at the anastomosis site (2) who revealed that the use theranekron resulted in significant decreased number of inflammatory cells and significant higher level of collagen. Histopathological observations have also referred to an increased granulatous angiogenesis, and the repair process can be accelerated by the decrease in the inflammatory cells that reduces local inflammation resulting in the reduction of the inflammatory phase and accelerates the recovery process. Furthermore, the higher levels of collagen and increased thickness improves the repair process. The gross findings of our study revealed that there were no severe adhesions with omentum and other intestinal segment in all animals of the treatment group of the anastomosis site in comparison to the control group where lesser and relatively absent adhesions with omentum and other intestinal segment were observed (9).

In our study, wound infection or anastomotic leakage in both control and treated groups was not reported. The effectiveness and safety of using cyanoacrylate adhesive for sutureless colonic anastomosis and as a protective seal for leakage prevention where no anastomotic leakage or infection was observed in any group (3). The use theranekron resulted in significant decreased number of inflammatory cells and significant higher level of collagen (10). Histopathological observations have also referred to an increased granulatous angiogenesis, and the repair process can be accelerated by the decrease in the inflammatory cells that reduces local inflammation resulting in the reduction of the inflammatory phase and accelerates the recovery process. This result was in agreement with our current study. Furthermore, the higher levels of collagen and increased thickness improves the repair process (11) which was also agreed the results of the present study.

Conclusion

There were no post-operative clinical complications in both groups. In the control group, sever adhesions with omentum and other intestinal segment of all animals were grossly more prominent in the anastomotic site in comparison to the treated group. Histological examination of the intestine at the site of anastomosis for the control group showed more extensive proliferation of inflammatory cells and collagen fibers, sever distraction of villi and crypts, sever congestion of blood vessels in sub mucosal layer in comparison to treatment group.

Conflict of interest

No conflict.

References

1. Chen C. The art of bowel anastomosis. Scandinavian J Surg. 2012;101(4):238-240. DOI: [10.1177/145749691210100403](https://doi.org/10.1177/145749691210100403)
2. Tobias KM. Manual of small animal soft tissue surgery. NY: CRC press: 2010. 1-52 p.
3. Osama HG, Alaa MK, Wesam MA, Ashraf GM. Comparative study between sutured intestinal anastomosis. Zagazig Uni Med J. 2014;20(2):145-154. DOI: [10.21608/ZUMJ.2014.4380](https://doi.org/10.21608/ZUMJ.2014.4380)
4. Vella M, O'Dwyer P. Techniques of bowel resection and anastomosis. J Gynecol Oncol. 2002;7(3):290-292. [\[available at\]](#)
5. Chen C. The art of bowel anastomosis. Scandinavian J Surg. 2012;101(4):238-240. DOI: [10.1177/145749691210100403](https://doi.org/10.1177/145749691210100403)
6. Ellison GW. End to-end anastomosis in the dog: A comparison of techniques. Comp Med Edu. 1981;3(6):486-495. [\[available at\]](#)
7. Peacock EE. Surgery and biology of wound repair. Philadelphia: Blackwell; 1978. 100-129 p.
8. Sardari K, Kakhki EG, Mohri M. Evaluation of wound contraction and epithelialization after subcutaneous administration of Theranekron® in cows. Comp Clin Pathol. 2007;16(3):197-200. DOI: [10.1007/s00580-006-0657-8](https://doi.org/10.1007/s00580-006-0657-8)
9. Lakhani CM. Ntra-abdominal complications following intestinal anastomoses by suture and staple techniques in dogs Christine. Physiol Behav. 2019;176(3):139-148. DOI: [10.1016/j.physbeh.2017.03.040](https://doi.org/10.1016/j.physbeh.2017.03.040)
10. Adib-Hashemi F, Farahmand F, Hesari SF, Rezakhaniha B, Fallah E, Fayyaz AF, Dadpay M. Anti-inflammatory and protective investigations on the effects of Theranekron® an alcoholic extract of the *Tarantula cubensis* on wound healing of peritoneal in the rat: An in vivo comparative study. Diag Pathol. 2015;10(1):19. DOI: [10.1186/s13000-015-0252-x](https://doi.org/10.1186/s13000-015-0252-x)
11. Bigham-Sadegh, Amin IK, Farzaneh HM. Concurrent use of theranekron with hydroxyapatite on bone healing in rabbit model: radiographic and histologic evaluation. Iranian J Orthopaed Surg. 2017;15(2):56-64. [\[available at\]](#)

دراسة تأثير مستخلص الثيرانكرون على عملية تجدد والتئام الأمعاء في الكلاب

احمد سعد القاضي، إبراهيم احمد زيدان، رضوان رياض العجيلي، منير سالم طه و احمد خلف علي

فرع الجراحة وعلم تناسل الحيوان، كلية الطب البيطري، جامعة الموصل، الموصل، العراق

الخلاصة

أجريت هذه الدراسة لدراسة تأثير مستخلص عقار الثيرانكرون على عملية تجدد الأمعاء بعد إزالة جزء منها جراحيا. استخدمت في هذه الدراسة ثمانية كلاب محلية تراوحت أعمارها ما بين ١-١٥ سنة وأوزانها ما بين ١٥-٢٠ كجم حيث قسمت حيوانات التجربة عشوائيا إلى مجموعتين: مجموعة السيطرة (٤ حيوانات) ومجموعة المعالجة (٤ حيوانات). تم إزالة جزء من الأمعاء جراحيا مع عمل مفاغرة في كلا المجموعتين. تم حقن ٣ مل من مستخلص الثيرانكرون تحت الجلد بواقع جرعتين (الجرعة الأولى قبل أسبوع من إجراء العملية والثانية بعد إجراء العملية مباشرة) فيما تم حقن حيوانات مجموعة السيطرة بثلاثة مليلترات من محلول المح الفسيولوجي بنفس طريقة ومدة حقن حيوانات المجموعة المعاملة. تمت عملية مراقبة حيوانات التجربة لمدة أسبوعين بعد إجراء العملية الجراحية وفي نهاية التجربة، تم اخذ عينات من منطقة القطع لغرض إجراء الفحص النسيجي المرضي وإجراء اختبار الضغط. لم يلاحظ حدوث أي مضاعفات في كلا المجموعتين، كما اظهر الفحص العياني لمنطقة التفاعر وجود التصاقات شديدة بين الثرب وجزء من الأمعاء في كل حيوانات مجموعة السيطرة بالمقارنة مع حيوانات المجموعة المعالجة إذ كانت الالتصاقات اقل بصورة ملحوظة. أظهرت نتائج الدراسة النسيجية وجود فروقات بسيطة بين حيوانات التجربة في كلا المجموعتين. يمكن الاستنتاج من خلال نتائج التجربة أن لمستخلص الثيرانكرون تأثيرا إيجابيا على عملية التئام الجزء المقطوع والمفاغرة من الأمعاء.

