

## The histological effect of the injection of nonsteroidal anti-inflammatory drugs on sciatic nerve of rats

M.M. Taha<sup>id</sup> and A.H. Qassim<sup>id</sup>

Department of Anatomy, Histology and Embryology, College of Medicine, University of Mosul, Mosul, Iraq

### Article information

#### Article history:

Received September 17, 2021

Accepted September 29, 2021

Available online June 4, 2022

#### Keywords:

Axonal degeneration

Diclofenac sodium

Intraneural injection

Meloxicam

Sciatic nerve

#### Correspondence:

A.H. Qassim

[ahmedhq@uomosul.edu.iq](mailto:ahmedhq@uomosul.edu.iq)

### Abstract

The ongoing work aims to compare the effect of extraneural and intraneural injection of therapeutic doses of meloxicam and diclofenac sodium on the sciatic nerve of rats. Six groups of adult albino rats were used with five animals per group. Control group (A), group (B), and group (C) received a single extraneural injection of normal saline (NS) 0.25 ml/kg/rat, meloxicam (M) 0.11 mg/kg/0.25ml/rat and diclofenac sodium (V) 1.1 mg/kg/0.25ml/rat respectively. In contrast, control group (D), group (E), and group (F) received a single intraneural injection of the same doses of normal saline, meloxicam, and diclofenac sodium, respectively. Histological evaluation reveals an increased thickening of epineurium, dilatation, congestion of epineurial blood vessels, intrafascicular edema, axonal degeneration, myelin degeneration, and vacuolization in group (C) which was higher than those in the group (B). These changes were also greater in group (F) compared to groups (D) and (E). The histopathological changes of the sciatic nerve were greatest in the case of intraneural injection of saline, meloxicam, and diclofenac sodium, which means that the damaging effect of intraneural injection of the drug was greater than the extraneural injection of the same drug. It is concluded that extraneural and intraneural injections of therapeutic doses of meloxicam cause less damage to the sciatic nerve compared to diclofenac sodium. Thus, it is considered to be more secure than diclofenac sodium after intramuscular injection. Sciatic nerve injury can occur following intramuscular injection into the gluteal region, particularly if the needle hits the nerve.

DOI: [10.33899/ijvs.2021.131529.1961](https://doi.org/10.33899/ijvs.2021.131529.1961), ©Authors, 2022, College of Veterinary Medicine, University of Mosul.

This is an open access article under the CC BY 4.0 license (<http://creativecommons.org/licenses/by/4.0/>).

### Introduction

Drugs, in general, can be given orally, rectally, parenterally, and even applied locally. Within the category of parenteral medications are intramuscular injections, which are widely used for medication administration worldwide (1). Among the drugs which can be given by intramuscular injection are vitamins, vaccines, steroid hormones, antibiotics, tranquilizers, and analgesics (2). The most available and used analgesics and antipyretics in humans and animals are the nonsteroidal anti-inflammatory drugs (NSAIDs) (3-5). Following intramuscular administration of

drugs, adverse effects such as infection, abscess, necrosis, tissue irritation, contracture, hematoma, periostitis, chronic pain, and injuries to the blood vessels, bone, or nerves may occur (6). Nonsteroidal anti-inflammatory drugs, along with diclofenac sodium, can cause a pathological case called Nicolau syndrome, a rare condition that occurs when a drug is injected intramuscularly or intra-articularly, causing necrosis of tissue at the site of injection (7). Moreover, intramuscular injection of metamizole sodium (NSAID) can produce several histopathological changes on rat sciatic nerve (8). Since injury of the sciatic nerve always significantly impacts patients' productivity and quality of

life, especially in children, underweight patients, and the elderly, thus it represents a widely used subject for pre-clinical histopathological research (9,10).

The present study compares the effect of extraneural and intraneural injection of therapeutic doses of meloxicam and diclofenac sodium on sciatic nerve tissue of adult rats.

## **Materials and methods**

### **Ethical approve**

The research was approved by the Medical Research Ethics Committee, College of Medicine, University of Mosul. Ref. no.: UOM/COM/MREC/20-21. Date: 30/4/2021.

### **Animals**

Thirty healthy adult male Wistar albino rats close to 13-15 weeks old and weighing 250-300 grams were collected from the Animal House of College of Veterinary Medicine, University of Mosul, Mosul, Iraq. Animals were kept in specially designed cages (1 rat/ cage) in the laboratory under a suitable environment for seven days before the experiment. The rats were fed a typical diet and water *ad-libitum*.

### **Drugs**

Meloxicam (M) (Mobic®, Boehringer Ingelheim, Germany) of 15mg/1.5ml Ampule and Diclofenac sodium (V) (Voltex®, PIONEER Co. for Pharmaceutical Industries, Sulaymaniyah - Iraq) of 75mg/3ml Ampule, were purchased from a standard drug store. The drugs were diluted with normal saline in order to estimate the doses. The dose of injection for each drug was similar to the human therapeutic dose (11).

### **Groups and experimental design**

The animals were randomly separated into six equal groups, with five rats for each. Subsequently, all of the rats were weighed before starting the treatment to calculate their doses.

#### **Extraneural injection groups**

Rats received a single injection of medication to the area surrounding the sciatic nerve (8). Group A control rats received normal saline (NS) in the dose of 0.25ml/kg/rat. Group B received meloxicam (M) in the dose of 0.11mg /kg /0.25ml/rat. Group C received diclofenac sodium (V) in the dose of 1.1mg /kg /0.25ml/rat.

#### **Intraneural injection groups**

Rats received a single injection of medication into the sciatic nerve (12). Group D control rats received normal saline in the dose of 0.25 ml/kg/rat. Group E received meloxicam in the dose of 0.11mg /kg /0.25ml/rat. Group F received diclofenac sodium in the dose of 1.1mg /kg /0.25ml/rat.

### **Protocol**

The animals were anesthetized using ketamine and xylazine. The sciatic nerve was exposed after dissecting the gluteal muscles. The saline or drugs were extraneural and intraneural injected at the point just above the branching of the sciatic nerve in all groups (Figure 1). The muscles and skin were sutured. The rats were kept for one week in cages. Then, all rats were decapitated after deep anesthesia with ketamine and xylazine, and the sciatic nerves were dissected and removed.

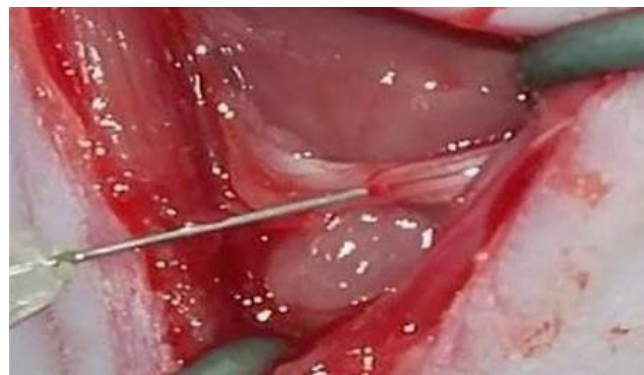

Figure 1: A picture illustrates the site of injection in the sciatic nerve.

### **Histological preparation and evaluation**

The sciatic nerve specimens were fixed for more than 24 hours in neutral buffered formalin (10%), dehydrated with ethanol, cleared by xylene, embedded in paraffin, and cross-sectioned into five  $\mu\text{m}$  sections (13). The sections were stained using Hematoxylin and Eosin, in addition to Masson's Trichrome. Qualitatively all sections obtained from the six groups were examined by light microscope (Novex, Holland) to detect the thickening of epineurium of the sciatic nerve, congestion, and/or dilatation of blood vessels within epineurium and intrafascicular edema. A quantitative study of the sciatic nerve was performed using simple counting method by examination of the abnormal cells after taking a digital picture for the section by 48 Megapixels digital camera with unique microscope fixer and using (ACDSee Photo Studio Ultimate 2019) program for counting the following: Axonal degeneration, myelin degeneration, and vacuolization within the sciatic nerve sections. The counting unit of abnormal cells was (nerve cell / 400X field) (14).

### **Statistical analysis**

A computer package (Sigma plot V12.0 / SYSTAT software) was applied to manage the histomorphometric analysis. Data were displayed as means $\pm$ SE (Standard error) and were analyzed using Duncan's test with a significant level set on  $P < 0.05$  (15).

## Results

### Group A (control group)

The sciatic nerve in the control group histologically appears to be expected. Epineurium was normal with no increase in thickening (Figure 2). Within the epineurium, the blood vessels look normal without any dilatation or congestion (Figure 3). There was no intrafascicular edema, though few changes in the histological structure of the sciatic nerve were observed, such as axonal degeneration in the average of  $1.2 \pm 0.1$ , myelin degeneration  $1.5 \pm 0.23$ , and vacuolization  $0.3 \pm 0.1$  per 400X field. (Figure 4, Table 1).

### Group B (extraneural meloxicam injection)

The epineurium mildly increases in thickening. The blood vessels within the epineurium show mild dilatation without congestion (Figures 5 and 6). There was no intrafascicular edema. In the fascicle, there were axonal degeneration  $5.3 \pm 0.3$ , myelin degeneration  $7.6 \pm 0.35$ , and vacuolization  $0.9 \pm 0.19$  per 400X field significantly higher than the group treated with normal saline (Figure 7, Table 1).

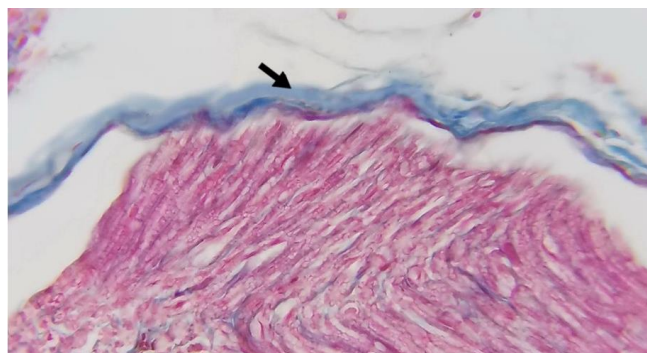


Figure 2: A photomicrograph of a section of the sciatic nerve of group A showing normal epineurium (arrow). Masson's Trichrome, X 400.

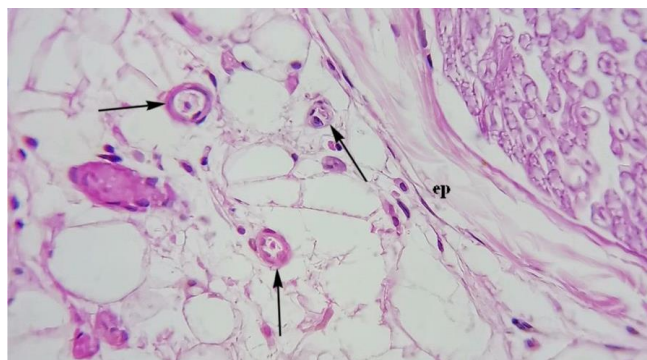


Figure 3: A photomicrograph of a section of the sciatic nerve of group A showing epineurium (ep) and normal blood vessels (arrows). H&E, X400.

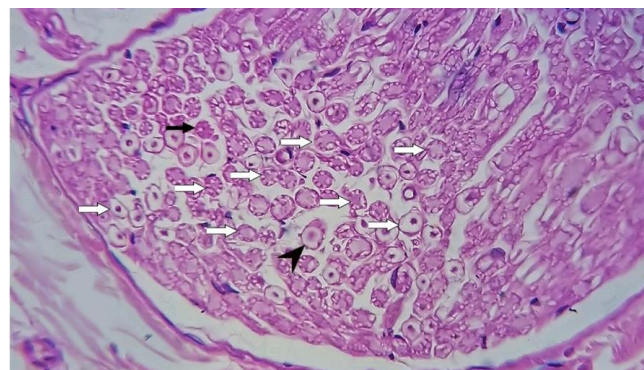


Figure 4: A photomicrograph of a section of the sciatic nerve of group A showing normal axons (white arrows), degenerated axons (arrowhead), and myelin degeneration (black arrow). H&E, X400.

Table 1: Histopathological changes in the sciatic nerve following extraneural injections in different groups

Changes	Groups		
	An (NS)	B (M)	C (V)
Axonal degeneration	$1.2 \pm 0.1^a$	$5.3 \pm 0.3^b$	$8.2 \pm 0.3^c$
Myelin degeneration	$1.5 \pm 0.2^a$	$7.6 \pm 0.3^b$	$12 \pm 0.6^c$
Vacuolization	$0.3 \pm 0.1^a$	$0.9 \pm 0.1^a$	$2.5 \pm 0.2^b$

The different letters in rows mean a significant difference at  $P \leq 0.05$ .

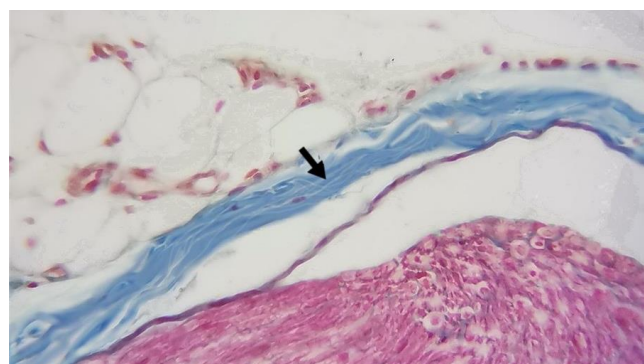


Figure 5: A photomicrograph of a section of the sciatic nerve of group B showing a mild increase in the thickening of epineurium (arrow). Masson's Trichrome, X400.

### Group C (extraneural diclofenac sodium injection)

There was a mild to moderate increase in the thickening of epineurium after staining with Masson's Trichrome (Figure 8). Also, there was mild to moderate dilatation and congestion of blood vessels within the epineurium (Figure 9). There was intrafascicular edema. Additionally, many histopathological changes appeared within the neural cells compared with groups A and B; axonal degeneration



$8.2 \pm 0.360$ , myelin degeneration  $12 \pm 0.62$ , and vacuolization  $2.5 \pm 0.29$  per 400X field (Figures 10 and 11, Table 1).

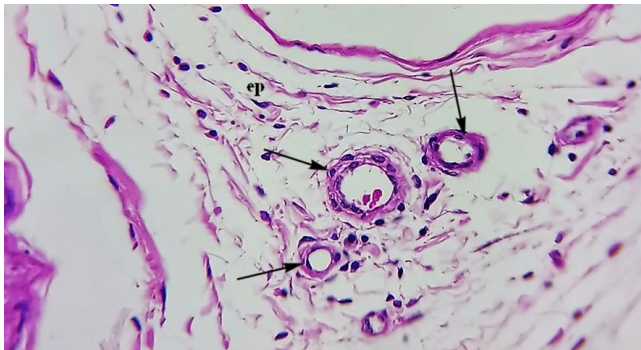


Figure 6: A photomicrograph of group B's sciatic nerve section showing epineurium (ep) and mild blood vessels dilatation (arrows). H&E, X400.

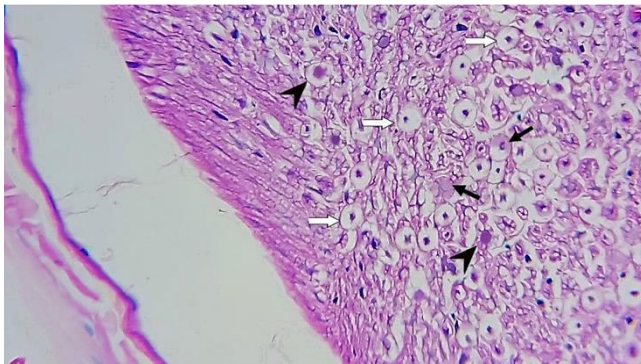


Figure 7: A photomicrograph of a section of the sciatic nerve of group B showing normal axons (white arrows), degenerated axons (arrowheads), and myelin degeneration (black arrows). H&E, X400.

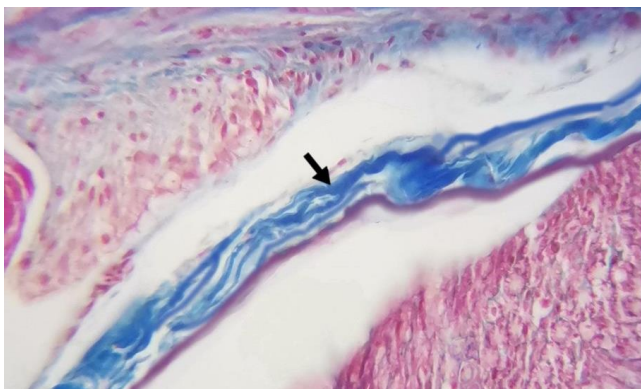


Figure 8: A photomicrograph of a section of the sciatic nerve of group C showing mild to moderate increase in thickening of epineurium (arrow). Masson's Trichrome, X400.

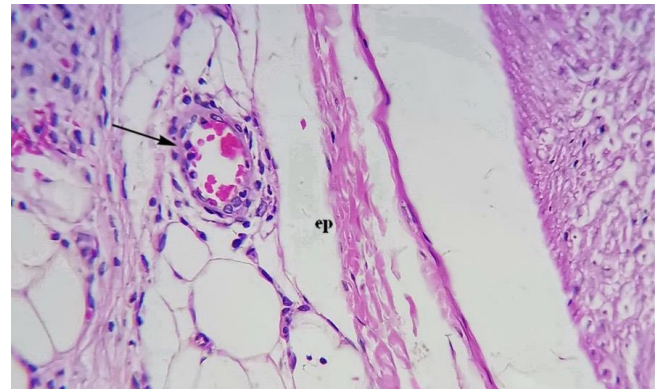


Figure 9: A photomicrograph of group C's sciatic nerve section showing epineurium (ep) and mild to moderate blood vessels dilatation and congestion (arrow). H&E, X400.

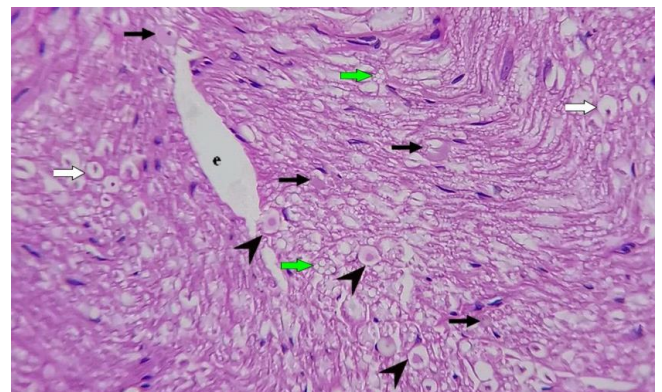


Figure 10: A photomicrograph of a section of the sciatic nerve of group C showing normal axons (white arrows), degenerated axons (arrowheads), myelin degeneration (black arrows), vacuolization (green arrows), and edema (e). H&E, X400.

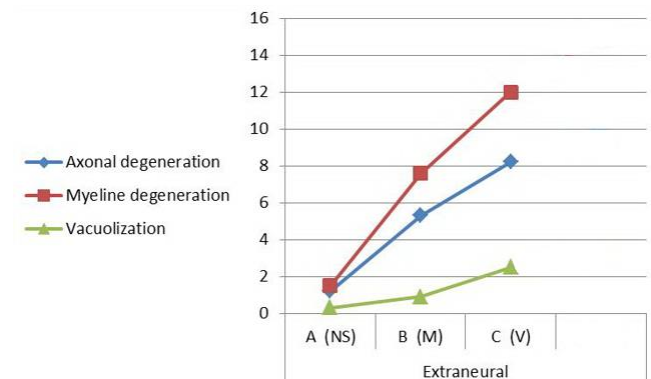


Figure 11: A histogram showing the histopathological changes in the sciatic nerve after extraneural injection of the drugs in control and treated groups.



### Group D (control group)

The histological examination of the sciatic nerve of group D appears normal, except a few histopathological changes occur within axons. The epineurium appears normal (Figure 12). The blood vessels in the epineurium appear normal without dilatation or congestion (Figure 13). There was intrafascicular edema, and there were few histological changes inside the fascicle, such as axonal degeneration  $2.8 \pm 0.2$ , myelin degeneration  $5.5 \pm 0.29$ , and vacuolization  $0.6 \pm 0.13$  per 400X field (Figure 14, Table 2).

Table 2: Histopathological changes in the sciatic nerve following intraneural injections in different groups

Changes	Groups		
	D (NS)	E (M)	F (V)
Axonal degeneration	$2.8 \pm 0.2^a$	$9.6 \pm 0.7^b$	$20.4 \pm 0.8^c$
Myelin degeneration	$5.5 \pm 0.2^a$	$10.8 \pm 0.8^b$	$16.6 \pm 0.7^b$
Vacuolization	$0.6 \pm 0.1^a$	$1.3 \pm 0.2^a$	$4.3 \pm 0.5^b$

The different letters in rows mean a significant difference at  $P \leq 0.05$ .

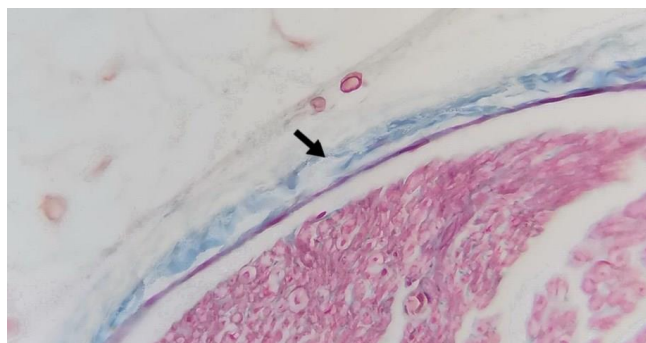


Figure 12: A photomicrograph of group D's sciatic nerve section showing normal epineurium (arrow). Masson's Trichrome, X400.

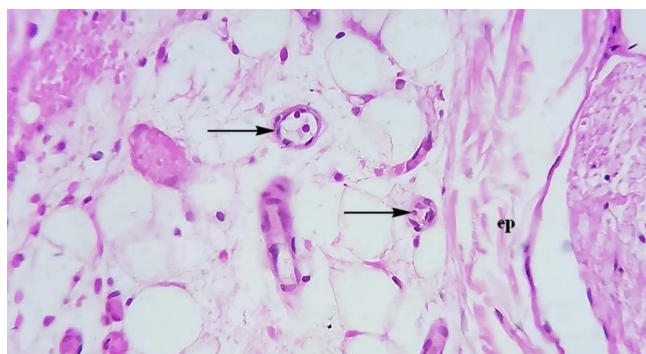


Figure 13: A photomicrograph of group D's sciatic nerve section showing epineurium (ep) and normal blood vessels (arrows). H&E, X400.

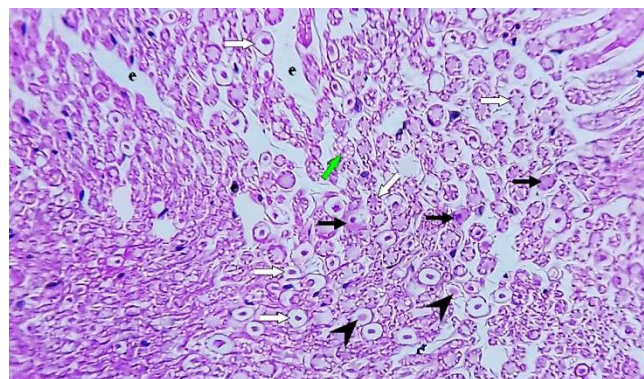


Figure 14: A photomicrograph of a section of the sciatic nerve of group D showing normal axons (white arrows), degenerated axons (arrowheads), myelin degeneration (black arrows), vacuolization (green arrow), and edema (e). H&E, X400.

### Group E (intraneural meloxicam injection)

The epineurial layer of the sciatic nerve mildly increased in thickening. The epineurium contains mildly dilated and congested blood vessels (Figures 15 and 16). There was edema inside the fascicle. Moreover, there were axonal degeneration  $9.6 \pm 0.7$ , myelin degeneration  $10.8 \pm 0.81$ , and vacuolization  $1.3 \pm 0.23$  per 400X field, all of which were considered higher than the control group (Figure 17, Table 2).

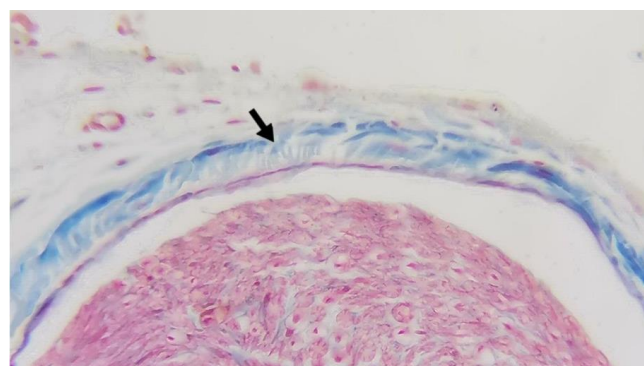


Figure 15: A photomicrograph of a section of the sciatic nerve of group E showing a mild increase in the thickening of epineurium (arrow). Masson's Trichrome, X400.

### Group F (intraneural diclofenac sodium injection)

There was a moderate increase in the thickening of epineurium (Figure 18). The blood vessels revealed mild to moderate dilatation and congestion (Figure 19). There was edema inside the nerve fascicle, axonal degeneration in an average of  $20.4 \pm 0.8$ , myelin degeneration  $16.6 \pm 0.75$ , and vacuolization  $4.3 \pm 0.57$  per 400X field (Figures 20 and 21, Table 2).



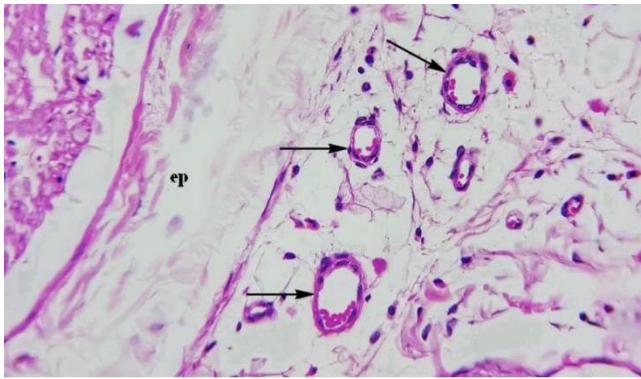


Figure 16: A photomicrograph of group E's sciatic nerve section showing epineurium (ep) and mild blood vessels dilatation and congestion (arrows). H&E, X400.

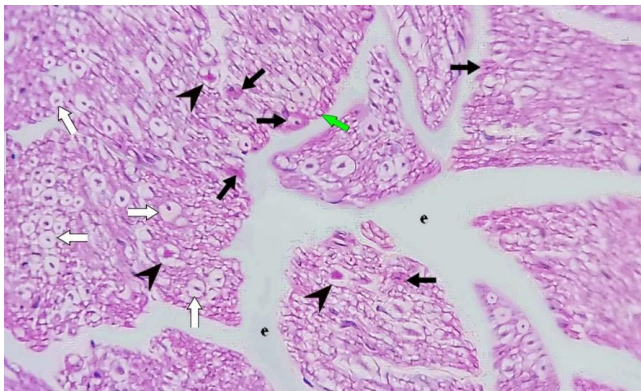


Figure 17: A photomicrograph of a section of the sciatic nerve of group E showing normal axons (white arrows), degenerated axons (arrowheads), myelin degeneration (black arrows), vacuolization (green arrow), and edema (e). H&E, X400.

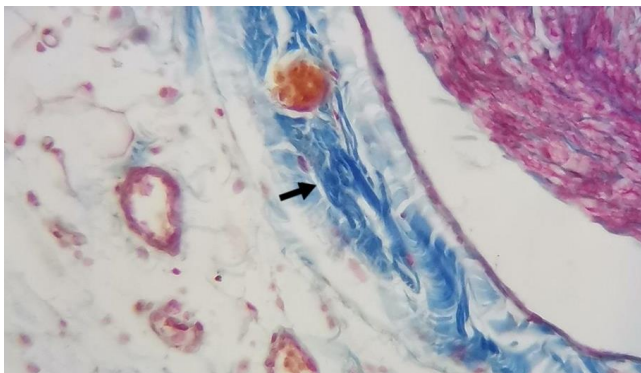


Figure 18: A photomicrograph of a section of the sciatic nerve of group F showing a moderate increase in the thickening of epineurium (arrow). Masson's Trichrome, X400.

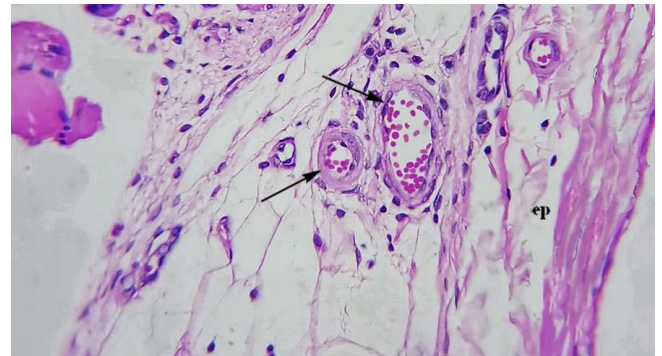


Figure 19: A photomicrograph of group F's sciatic nerve section showing epineurium (ep) with mild to moderate blood vessels dilatation and congestion (arrows). H&E, X400.

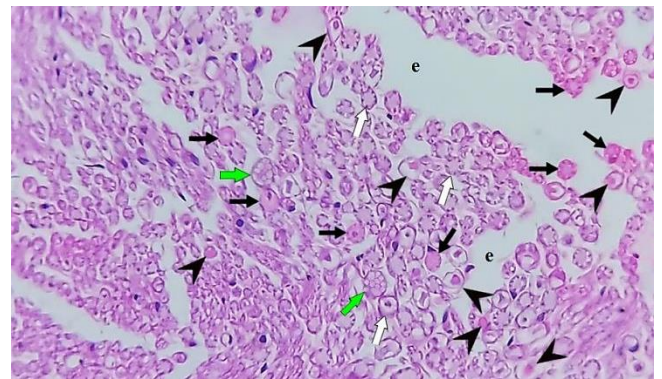


Figure 20: A photomicrograph of a section of the sciatic nerve of group F showing normal axons (white arrows), degenerated axons (arrowheads), myelin degeneration (black arrows), vacuolization (green arrows), and edema (e). H&E, X400.

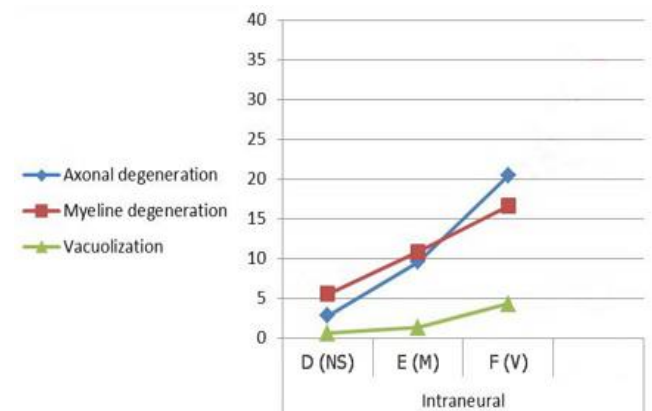


Figure 21: A histogram showing the histopathological changes in the sciatic nerve after intraneural injection of the drugs in control and treated groups.

Comparison between the histopathological changes of extraneural and intraneural injections of each drug in different treated groups is shown in table 3.

Table 3: Comparison between histopathological changes of extraneural and intraneural injections of each drug

Drugs	NS	M	V
Axonal degeneration			
Extraneural	1.2±0.1 <sup>a</sup>	5.3±0.3 <sup>a</sup>	8.2±1.6 <sup>a</sup>
Intraneural	2.8±0.2 <sup>b</sup>	9.6±3.1 <sup>b</sup>	20.4±0.8 <sup>b</sup>
Myelin degeneration			
Extraneural	1.5±0.2 <sup>a</sup>	7.6±0.3 <sup>a</sup>	12±0.6 <sup>a</sup>
Intraneural	5.5±0.2 <sup>b</sup>	10.8±0.8 <sup>b</sup>	16.6±0.7 <sup>b</sup>
Vacuolization			
Extraneural	0.3±0.1 <sup>a</sup>	0.9±0.1 <sup>a</sup>	2.5±0.2 <sup>a</sup>
Intraneural	0.6±0.1 <sup>a</sup>	1.3±0.1 <sup>a</sup>	4.3±0.5 <sup>b</sup>

The different letters in columns mean a significant difference at  $P \leq 0.05$ .

## Discussion

Due to the difficulty in dissecting and examining the nervous tissue in humans, histological examination of the sciatic nerve injury after drug injection into the gluteal region of rats was performed in this study. The sciatic nerve appears to be normal in the extraneural control-treated group, but few changes like axonal degeneration, myelin degeneration, and vacuolization were observed. Many studies agreed that normal saline has minimal damage or no damage to the sciatic nerve (8).

In the meloxicam treated group, the epineurium thickening was mildly increased, possibly because of the excessive fibrin formation by the epineurial fibroblast in order to replace the damaged tissue (16). Meloxicam causes mild intrafascicular damage within the nerve fiber axons, including axon degeneration, myelin degeneration, and vacuolization. Compared with the control group, there was a significant difference between histopathological changes at ( $p \leq 0.05$ ) except vacuolization, which indicates that both normal saline and meloxicam had minimal damage. This damage was probably not enough to produce cell death of myelinated axons and thus minimize vacuolization. Unfortunately, there were no available articles that discuss that, but Bostan *et al.* (17) support this explanation. They mentioned that lornoxicam (same family of meloxicam) had a mild effect when injected into the sciatic nerve's neighboring tissue.

In the diclofenac sodium treated group, there was a mild to moderate increase in the epineurial thickening, which means more damage to the area surrounding the fascicle due to the toxic effect of diclofenac sodium, which was more than that induced by saline and meloxicam. Similarly,

Bostan *et al.* (17) found that all rats injected extraneural with diclofenac had epineurium thickening. More than that, there was mild to moderate dilatation and congestion of blood vessels in the extrafascicular epineurial layer. Qassim *et al.* (18) noticed congestion of blood vessels when diclofenac was injected into the gluteal muscles. This bolsters the present study and leads to the fact that the irritation and toxicity of the drug will create congestion of the epineurial blood vessels. The presence of intrafascicular edema after extraneural injection of diclofenac sodium which was absent in the meloxicam and saline groups, was in agreement with Bostan *et al.* (17), who found that injection of diclofenac sodium into the area surrounding the sciatic nerve will cause edema inside the nerve fascicle. This is perhaps due to the damage of blood vessels by the toxicity of diclofenac sodium after extraneural injection, which will result in increased vascular permeability with subsequent accumulation of fluid inside the nerve (19).

Furthermore, there were axonal degeneration, myelin degeneration, and vacuolization. Compared with sections of control and meloxicam groups, there was a significant difference between histopathological changes ( $P \leq 0.05$ ). This occurs due to increased damage produced by diclofenac sodium as approved by Bostan *et al.* (17). Also, Canan *et al.* (20) considered that axon's defect was significantly prominent after diclofenac sodium injection. As diclofenac is a cyclo-oxygenase inhibitor, it inhibits prostaglandin synthesis, thus creating vasoconstriction, which would cause ischemia and necrosis of deep tissue or muscle or even skin after intramuscular injection (21). This explains the extent of damage formed by diclofenac sodium in the sciatic nerve tissue, as observed in the current study.

The findings which were mentioned above summarized that meloxicam had lower toxicity and damage than diclofenac. This is because meloxicam had a slower release rate compared to diclofenac. It reaches the maximum concentration in the plasma 1 to 2 hours after injection (22), whereas diclofenac reaches its maximum concentration after 20-40 minutes (23). This explanation was supported by Sutton *et al.* (24), who mentioned that following intramuscular injection, local tissue damage was in relation with the local concentration of the drug besides its release from the formulation, as the slower drug release leads to lower tissue damage since the drug is diluted in the interstitial fluid and cleared by lymphatics.

In the intraneural control-treated group, the histological appearance of the sciatic nerve was similar to that described by other authors (8,25). There was intrafascicular edema and several intrafascicular histopathological changes involving axonal degeneration, myelin degeneration, and vacuolization. These changes were considered to be less than those in other treated groups, and this may be due to the non-toxic and non-irritant behavior of normal saline that was in agreement with other studies (17, 26).



In the meloxicam treated group, the sciatic nerve was mildly affected, and there was edema inside the fascicle. It is suggested that intraneural injection of the drug will cause pressure on the blood vessels, thus causing inhibition of microvascular blood flow, producing an increase in the vascular permeability leading to edema (27). The histopathological changes involving the nerve axons were significantly different from the control group ( $P \leq 0.05$ ) except for vacuolization. It seems that meloxicam causes minimal tissue damage, supported by Bostan *et al.* (17), who said that intraneural injection of lornoxicam had minimal damage on nerve tissue.

In the diclofenac sodium treated group, there was moderate damage to the sciatic nerve. This result was congruent with Bostan *et al.* (17). There were significant differences between histopathological changes of nerve axons compared with saline and meloxicam groups at ( $P \leq 0.05$ ) and non-significant difference of myelin degeneration between meloxicam and diclofenac at ( $P \leq 0.05$ ). Alabdaly *et al.* (28) mentioned that NSAIDs could cause oxidative stress. Oxidative stress and mitochondrial dysfunction will lead to nerve cell damage represented by axonal degeneration, myelin degeneration, and vacuolization (29). In the present study, there was intrafascicular edema which was also described by Emir *et al.* (8), perhaps because of the increased perineural permeability induced by the drug (30).

Diclofenac in this work shows more significant damage than meloxicam on the neural tissue, probably because it is a mixed COX-I and COX-II inhibitor. The inhibition of COX-I will interrupt homeostatic function, resulting in vasoconstriction and ischemic necrosis, causing more damage to the tissue (6), while meloxicam has minimal damage on the neural tissue because it is a preferential selective COX-II inhibitor (31).

Generally, from the results mentioned before, apart from vacuolization, all the histological changes of the sciatic nerve were so evident in the case of intraneural injection of saline, meloxicam, and diclofenac sodium, which means that the damaging effect of intraneural injection of the drug was more significant than the extraneural injection of the same drug.

The mechanical trauma to the sciatic nerve fibers which is exerted by the sharp edge of the needle (32), as well as, the injection of the drug by the needle into the nerve which will bypass the protective barrier of the epineurium and perineurium (12), in addition to the increased intraneural volume and concentration of the drug after intraneural injection (8); these hypotheses may be the reason for this significant damage induced by intraneural injection in comparison to extraneural one.

## Conclusion

Extraneural and intraneural injections of therapeutic doses of meloxicam cause minor damage to the sciatic nerve

compared to diclofenac sodium. Thus, intramuscular injection of meloxicam seems to be more secure than that of diclofenac sodium. Sciatic nerve injury can occur following intramuscular injection when the needle hits the nerve, so precaution is mandatory during intramuscular injection, and selection of the correct size is crucial to prevent this injury.

## Acknowledgments

The authors would like to thank the College of Medicine, the University of Mosul for supporting this work. Our appreciation to the staff members of Animal House in the College of Veterinary Medicine, the University of Mosul, for the help they gave us to accomplish the work.

## Conflict of interest

There is no conflict of interest as declared by the authors.

## References

1. Soliman E, Ranjan S, Xu T, Gee C, Harker A, Barrera A, Geddes J. A narrative review of the success of intramuscular gluteal injections and its impact in psychiatry. *Biodes Manuf.* 2018;1(3):161-170. DOI: [10.1007/s42242-018-0018-x](https://doi.org/10.1007/s42242-018-0018-x)
2. Mishra P, Stringer MD. Sciatic nerve injury from intramuscular injection: a persistent and global problem. *Int J Clin Pract.* 2010;64(11):1573-1579. DOI: [10.1111/j.1742-1241.2009.02177.x](https://doi.org/10.1111/j.1742-1241.2009.02177.x)
3. Yekkirala AS, Roberson DP, Bean BP, Woolf CJ. Breaking barriers to novel analgesic drug development. *Nat Rev Drug Discov.* 2017;16(8):545-564. DOI: [10.1038/nrd.2017.87](https://doi.org/10.1038/nrd.2017.87)
4. Albadrany YM, Naser AS, Hasan MM. Study the analgesic effect of diclofenac and silymarin coadministration in chicks. *Iraqi J Vet Sci.* 2021. In Press. DOI: [10.33899/ijvs.2021.127065.1453](https://doi.org/10.33899/ijvs.2021.127065.1453)
5. Al-Alsadoon LH, Al-Saffar MT, Taqa GA. Comparative antinociceptive effect of aspirin and aspirin nanoparticles in semisolid formulae in mice. *Iraqi J Vet Sci.* 2021; 35(3): 535-539. DOI: [10.33899/ijvs.2020.127138.1467](https://doi.org/10.33899/ijvs.2020.127138.1467)
6. Kim KK. Nicolau syndrome inpatient following diclofenac administration: a case report. *Ann Dermatol.* 2011; 23(4):501-503. DOI: [10.5021/ad.2011.23.4.501](https://doi.org/10.5021/ad.2011.23.4.501)
7. Lardelli PF, Jermini LM, Milani GP, Peeters GG, Ramelli GP, Zraggen L, Terrani I, Bianchetti MG, Vanoni F, Faré PB, Lava SA. Nicolau syndrome caused by nonsteroidal anti-inflammatory drugs: Systematic literature review. *Int J Clin Pract.* 2020;74(10):e13567. DOI: [10.1111/ijcp.13567](https://doi.org/10.1111/ijcp.13567)
8. Emir A, Kalkan Y, Bostan H. Histopathological effects of intramuscular metamizole sodium on rat sciatic nerve. *Iran J Basic Med Sci.* 2016;19(8):829-836. [\[available at\]](#)
9. AlFaris HS and Al-Muhaizea MM. Traumatic Sciatic Nerve Injury Following Intramuscular Injection: A Case Report. *Int J Med Res Prof.* 2018; 4(2):246-247. DOI: [10.21276/ijmrp.2018.4.2.055](https://doi.org/10.21276/ijmrp.2018.4.2.055)
10. Al-khafaf A, Ismail HKH, Alsaidya AMA. Histopathological effects of experimental exposure to lead on nervous system in albino female rats. *Iraqi J Vet Sci.* 2021; 35(1): 45-48. DOI: [10.33899/ijvs.2019.126248.1273](https://doi.org/10.33899/ijvs.2019.126248.1273)
11. Sulaiman AHK. The effect of diclofenac and meloxicam on liver and kidney of male rats. A histo-morphometrical study. [PhD Thesis]. Mosul: College of Medicine, University of Mosul; 2010.
12. Hadzic A, Dilberovic F, Shah S, Kulenovic A, Kapur E, Zaciragic A, Cosovic E, Vuckovic I, Divanovic KA, Mornjakovic Z, Thys DM, Santos AC. Combination of intraneural injection and high injection



- pressure leads to fascicular injury and neurologic deficits in dogs. Reg Anesth Pain Med. 2004;29(5):417-423. DOI: [10.1016/j.rapm.2004.06.002](https://doi.org/10.1016/j.rapm.2004.06.002)
13. Phelps JM. Cross-Section Sample Preparation of a Free-Standing Thin-Film Coupon for Transmission Electron Microscopy Analysis. Microscopy Microanalysis. 1998;4(2):128-132. DOI: [10.1017/S1431927698980114](https://doi.org/10.1017/S1431927698980114)
14. De-Oliveira RC, Murillo S, Saikia P, Wilson SE. The Efficacy of Topical HGF on Corneal Fibrosis and Epithelial Healing after Scar-Producing PRK Injury in Rabbits. Transl Vis Sci Technol. 2020;9(4):29. DOI: [10.1167/tvst.9.4.29](https://doi.org/10.1167/tvst.9.4.29)
15. Systat Software Inc. Sigma plot V12.0 / SYSTAT software. 2016.
16. Kulkarni GS. Textbook of Orthopaedics and Trauma. India: Jaypee Brothers Medical Publication; 2009. 895-898 p.
17. Boston H, Cabalar M, Altinay S, Kalkan Y, Tumkaya L, Kanat A, Balik S, Erkut A, Altuner D, Salihoglu Z, Kocer A. Sciatic nerve injury following analgesic drug injection in rats: A histopathological examination. North Clin Istanb. 2018;5(3):176-185. DOI: [10.14744/nci.2017.28190](https://doi.org/10.14744/nci.2017.28190)
18. Qassim AH, Hamdi OR., Ayoob AA., Taher MT. Local Effect of Intramuscular Injection of Meloxicam and Diclofenac: An Experimental, Comparative and Histological Study. Ann Coll Med Mosul. 2019;41 (2):163-169. DOI: [10.33899/mmed.2020.164159](https://doi.org/10.33899/mmed.2020.164159)
19. Guionaud S. The Far Side of Vascular Injury: Nonconventional Vasoconstrictors, DNA-targeting Agents, and Agents Toxic to Vascular Smooth Muscle. Toxicol Pathol. 2015;43(7):945-958. DOI: [10.1177/0192623315601905](https://doi.org/10.1177/0192623315601905)
20. Canan S, Aktaş A, Ulkay MB, Colakoglu S, Ragbetli MC, Ayyildiz M, Geuna S, Kaplan S. Prenatal exposure to a nonsteroidal anti-inflammatory drug or saline solution impairs sciatic nerve morphology: a stereological and histological study. Int J Dev Neurosci. 2008;26(7):733-738. DOI: [10.1016/j.ijdevneu.2008.07.005](https://doi.org/10.1016/j.ijdevneu.2008.07.005)
21. Aktas H, Yilmaz OE, Ertugrul G, Terzi E. Intramuscular diclofenac is a cause of Nicolau syndrome in obese women: An observational study of consecutive ten patients. Dermatol Ther. 2020;33(3):e13392. DOI: [10.1111/dth.13392](https://doi.org/10.1111/dth.13392)
22. Davies NM, Skjodt NM. Clinical pharmacokinetics of meloxicam. A cyclo-oxygenase-2 preferential nonsteroidal anti-inflammatory drug. Clin Pharmacokinet. 1999;36(2):115-126. DOI: [10.2165/00003088-199936020-00003](https://doi.org/10.2165/00003088-199936020-00003)
23. Leuratti C, Loprete L, Rossini M, Frangione V, Rovati S, Radicioni M. Pharmacokinetics and Safety of a Diclofenac Sodium 75 mg/1 mL Solution (Akis®/Dicloin®) Administered as a Single Intravenous Bolus Injection in Healthy Men and Women. Eur J Drug Metab Pharmacokinet. 2019;44(5):681-689. DOI: [10.1007/s13318-019-00558-8](https://doi.org/10.1007/s13318-019-00558-8)
24. Sutton SC, Evans LA, Rinaldi MT, Norton KA. Predicting injection site muscle damage. II: Evaluation of extended-release parenteral formulations in animal models. Pharm Res. 1996;13(10):1514-1518. DOI: [10.1023/a:1016027528937](https://doi.org/10.1023/a:1016027528937)
25. Rayan GM, Gannaway JK, Pitha J, Dale GL. Peripheral nerve changes following epineurial injection of saline and blood in rat sciatic nerve. Clin Orthop Relat Res. 1985;03(193):299-307. DOI: [10.1097/00003086-198503000-00040](https://doi.org/10.1097/00003086-198503000-00040)
26. Ihara A, Kurita M, Ozaki M, Fujiki M, Kaji N, Takushima A, Harii K. Subcutaneous injection of normal saline prevents cutaneous complications of ethanol sclerotherapy for superficial vascular lesions: an experimental study. Dermatol Surg. 2011;37(8):1125-1132. DOI: [10.1111/j.1524-4725.2011.01992.x](https://doi.org/10.1111/j.1524-4725.2011.01992.x)
27. Rempel D, Dahlin L, Lundborg G. Pathophysiology of nerve compression syndromes: response of peripheral nerves to loading. J Bone Joint Surg Am. 1999;81(11):1600-1610. DOI: [10.2106/00004623-199911000-00013](https://doi.org/10.2106/00004623-199911000-00013)
28. Alabdaly YZ, Saeed MG, Al-hashemi HM. Effect of methotrexate and aspirin interaction and its relationship to oxidative stress in rats. Iraqi J Vet Sci. 2021;35(1):151-156. DOI: [10.33899/ijvs.2020.126490.1335](https://doi.org/10.33899/ijvs.2020.126490.1335)
29. Nawaz H, Ali A, Rehman T, Aslam A. Sclerotherapy effects of nonsteroidal anti-inflammatory drug therapy on oxidative stress and antioxidant status in patients with rheumatoid arthritis. Clin Rheumatol. 2021;40(5):1767-1778. DOI: [10.1007/s10067-020-05438-0](https://doi.org/10.1007/s10067-020-05438-0)
30. Mizisin AP, Kalichman MW, Myers RR, Powell HC. Role of the blood-nerve barrier in experimental nerve edema. Toxicol Pathol. 1990;18(1):170-185. DOI: [10.1177/019262339001800123](https://doi.org/10.1177/019262339001800123)
31. Del-Tacca M, Colucci R, Fornai M, Blandizzi C. Efficacy and tolerability of meloxicam, a COX-2 preferential nonsteroidal anti-inflammatory drug. Clin Drug Invest. 2002;22(12):799-818. DOI: [10.2165/00044011-200222120-00001](https://doi.org/10.2165/00044011-200222120-00001)
32. Hogan QH. Pathophysiology of peripheral nerve injury during regional anesthesia. Reg Anesth Pain Med. 2008;33(5):435-441. DOI: [10.1016/j.rapm.2008.03.002](https://doi.org/10.1016/j.rapm.2008.03.002)
- ## التأثير النسيجي لحقن مضادات الالتهاب اللاستيرويدية على العصب الوركي للجرذان
- مصطفى محمد طه و احمد هشام قاسم
- فرع التشريح والأنسجة والأجنة، كلية الطب، جامعة الموصل، الموصل، العراق
- ### الخلاصة
- يهدف هذا العمل إلى مقارنة تأثير الحقن خارج العصب وداخل العصب للجرعات العلاجية من الميلوكسيكام وديكلوفيناك الصوديوم على العصب الوركي للجرذان. تم استخدام ستة مجاميع من الجرذان البالغة بواقع ٥ حيوانات لكل مجموعة. تلقت مجموعة السيطرة (المجموعة الأولى) والمجموعة الثانية والمجموعة الثالثة حقنة واحدة خارج العصب من محلول ملحي عياري ٠,٢٥ مل/كغم/جرذ، ميلوكسيكام ٠,١١ ملغ/كغم/ ٠,٢٥ مل/جرذ وديكلوفيناك الصوديوم ١,١ ملغ/كغم/ ٠,٢٥ مل/جرذ على التوالي، بينما تلقت مجموعة السيطرة (المجموعة الرابعة) والمجموعة الخامسة والمجموعة السادسة حقنة واحدة داخل العصب لنفس الجرعة من المحلول الملحي العياري، الميلوكسيكام وديكلوفيناك الصوديوم وعلى التوالي أيضا. يظهر التقييم النسيجي زيادة في سماكة الغشاء فوق العصبي، توسع واحتقان الأوعية الدموية في هذا الغشاء، وذمة داخل العصب، تنكس محوري، تنكس المايلين وفجوات داخل العصب في المجموعة الثالثة والتي كانت أعلى من تلك الموجودة في المجموعة الثانية. هذه التغيرات كانت أشد كذلك في المجموعة السادسة مقارنة بالمجموعتين الرابعة والخامسة. كانت التغيرات النسيجية للعصب الوركي أشد في حالة الحقن داخل العصب للمحلول الملحي والميلوكسيكام وديكلوفيناك الصوديوم، مما يعني أن التأثير الضار للحقن داخل العصب للدواء كان أشد من الحقن خارج العصب لنفس الدواء. نستنتج بأن الحقن خارج العصب وداخل العصب للجرعات العلاجية من الميلوكسيكام يسبب ضررا أقل للعصب الوركي مقارنة بديكلوفيناك الصوديوم، وبذلك يعتبر أكثر أمانا من ديكلوفيناك الصوديوم بعد الحقن العضلي. يمكن أن تحدث إصابة العصب الوركي بعد الحقن العضلي في منطقة الألوية خاصة إذا اصطدمت الإبرة بالعصب.

## التأثير النسيجي لحقن مضادات الألتهاب اللاستيرويدية على العصب الوركي للجردان

مصطفى محمد طه و احمد هشام قاسم

فرع التشريح والأنسجة والأجنة، كلية الطب، جامعة الموصل،  
الموصل، العراق

## الخلاصة

يهدف هذا العمل إلى مقارنة تأثير الحقن خارج العصب ودخل العصب للجرعات العلاجية من الميلوكسيكام وديكلوفيناك الصوديوم على العصب الوركي للجرذان. تم استخدام ستة مجاميع من الجرذان البالغة بواقع ٥ حيوانات لكل مجموعة. تلقت مجموعة السيطرة (المجموعة الأولى) والمجموعة الثانية والمجموعة الثالثة حقنة واحدة خارج العصب من محلول ملحي عياري ٠,٢٥ مل/كغم/جرذ، ميلوكسيكام ٠,١١ مل/كغم/ ٠,٢٥ مل/جرذ وديكلوفيناك الصوديوم ١,١ مل/كغم/ ٠,٢٥ مل/جرذ على التوالي، بينما تلقت مجموعة السيطرة (المجموعة الرابعة) والمجموعة الخامسة والمجموعة السادسة حقنة واحدة داخل العصب لنفس الجرعة من المحلول الملحي العياري، الميلوكسيكام وديكلوفيناك الصوديوم وعلى التوالي أيضا. يظهر التقييم النسيجي زيادة في سماكة الغشاء فوق العصبي، توسع واحتقان الأوعية الدموية في هذا الغشاء، وذمة داخل العصب، تنكس محوري، تنكس المايلين وفجوات داخل العصب في المجموعة الثالثة والتي كانت أعلى من تلك الموجودة في المجموعة الثانية. هذه التغيرات كانت أشد كذلك في المجموعة السادسة مقارنة بالمجموعتين الرابعة والخامسة. كانت التغيرات النسيجية للعصب الوركي أشد في حالة الحقن داخل العصب للمحلول الملحي والميلوكسيكام وديكلوفيناك الصوديوم، مما يعني أن التأثير الضار للحقن داخل العصب للدواء كان أشد من الحقن خارج العصب لنفس الدواء. نستنتج بأن الحقن خارج العصب وداخل العصب للجرعات العلاجية من الميلوكسيكام يسبب ضررا أقل للعصب الوركي مقارنة بديكلوفيناك الصوديوم، وبذلك يعتبر أكثر أمانا من ديكلوفيناك الصوديوم بعد الحقن العضلي. يمكن أن تحدث إصابة العصب الوركي بعد الحقن العضلي في منطقة الألية خاصة إذا اصطدمت الإبرة بالعصب.

