

Study the effects of Spearmint *Mentha Spicata* Extracts on Mammary Gland in Female Rats

دراسة بعض التغيرات النسجية والكيموحيوية والقياسات النسجية لتأثير المستخلص المائي لأوراق النعناع *Mentha spicata* على الغدد اللبنية لإناث الجرذ

Sinaa Jaboori Al-Bazii¹ Fadhil Jawad Al-Tu'ma² Salim Rasheed Al-Obaidi³

¹Department of Biology – College of Pure Sciences Education – University of Kerbala / Kerbala – Iraq.

²Department of Biochemistry – College of Medicine – University of Kerbala / Kerbala – Iraq.

³Department of Histology – College of Medicine – University of Baghdad / Baghdad – Iraq.

Summary:

This study was carried out to investigate the effect that result from taking of the 5.25 ml of aqueous extract of spearmint *Mentha spicata* leaves in the growth and development of mammary glands during virgin , pregnancy and lactating stages for 14 days. Forty five (45) rats were used in this experiment divided into nine groups, three groups at maturity stages, three groups at pregnancy stages and three groups at lactating stages (5 rats\groups). The following studies were decided: histological, biochemical and morphometrical studies for each group. Microscopic examination of mammary gland in the virgin rats that treated with spearmint showed more growth in the size of lobules and alveoli. In pregnant, the treated groups showed more branching of alveoli with more flattened epithelium. In lactating treated group showed the lobules were expanded and contained more branching alveoli with discontinuous flattened epithelium.

The biochemical studies showed a significant increase ($p<0.05$) in the serum reduced glutathione concentration with decrease in the malondialdehyde concentration in the three physiological stages that treated with spearmint compared with control. The morphometrical study indicated a noticeable increase in the alveolar diameters and numbers in all groups of animals for the three physiological stages (virgin, pregnant and lactating).

الخلاصة

أجريت هذه الدراسة بهدف تسليط الضوء على التأثيرات التي يمكن أن يؤديها تناول الخلاصة المائية لأوراق نبات النعناع *Mentha spicata* في زيادة ونمو وتطور الغدد اللبنية أثناء مراحل (البلوغ "العذارى" والحمل والرضاعة). لقد استهدفت التجربة دراسة تأثير الخلاصة المائية لنبات النعناع وبجرعة قدرها 5.25 مل على نمو وتطور الغدد اللبنية لمدة 14 يوم. استخدمت 45 جرذ في هذه التجربة و قسمت إلى تسع مجاميع، ثلاث مجاميع في مرحلة البلوغ والثلاثة الأخرى في مرحلة الحمل بالإضافة إلى ثلاثة مجاميع في مرحلة الرضاعة (5 جرذان \مجموعة) ، ثم أجريت عليها دراسات نسجية وكيموحيوية بالإضافة إلى القياسات النسجية لكل مجموعة. بينت النتائج المعطيات التالية: أظهرت المقاطع النسجية المصبوغة بصبغة الأيوسين والهيموتوكسلين إن الحيوانات العذاري المجرعة بالخلاصة المائية للنعناع زيادة في حجم وعدد الفصيصات. في مرحلة الحوامل لوحظ وجود تفرعات في الأسناخ مع تسطح في البطانة الطلانية بالإضافة الى ع توسع في النبيبات الفصيصية. أما عند معاملة مجاميع المرضعات فإن الفصيصات أكثر توسعا وتحوي على أسناخ أكثر تفرعا. أما الدراسات الكيموحيوية فأظهرت المجاميع المعاملة بخلاصة المائية للنعناع ارتفاعا معنويا ($p<0.05$) في مستوى الكلوتاثيون في مصل الجرذان وانخفاضاً معنوياً في مستوى المالون داي الديهايد في مصل الجرذان المعاملة بالخلاصة المائية للحالات الفسلجية الثلاث مقارنة بالسيطرة.

أوضحت نتائج القياسات النسجية زيادة ملحوظة في أقطار الأسناخ الغدد اللبنية وإعدادها في كل من الحيوانات المعاملة بالخلاصة المائية لأوراق النعناع وللحالات الفسلجية الثلاث (العذارى والحوامل والمرضعات).

Introduction:

The mammary gland are compound tubuloalveolar glands whose function is to produce and secrete milk. The milk has an important role in human feeding by direct consumption or via food industry, so that an increase in milk production has attracted world wide interested by scientific researches.(1). Mother's milk is supplied to the neonate through breast feeding- the feeding of an infant or young child with milk from a woman's breast (2). Low supply of milk is one of the most common reasons given for discontinuing breast feeding. Galactagogues are medications or substances believed to assist initiation, maintenance and augmentation of maternal milk production.(3). There is a continuing interest in identification and better understanding of lactogenic plants and their extracts(4). Therefore, this investigation was directed to cast a light on the capability of spearmint on mammary gland development in three physiological stages (virgin, pregnant and lactating rats).

Material and Methods:

Their average body weight ranged between 140 -200gm. They were kept at a temperature between 20-24°C (room temperature). Animals were housed individually in wire - meshed stainless steel cages. The light / dark cycle was maintained as 12 hr.s /12hr.s. Rats were fed the ordinary pallet diet and maintained on free access to food and water. Forty five (45) adult female rats were divided into 3 experimental rats (each 15 rats were fed one type of plants) in three physiological stages(virgin, pregnant and lactating) (5rats\plant\stage) and (5\stage) rats as a control for (14) days.

Spearmint leaves were cleaned and dried, then grinding into powder. Boiling distilled water was added to the powder(5 gm of mint/100 ml water) then soaked in boiled water for (60) minute with continuous shaking then filtered through a filter paper and stored in dark bottles immediately (5).

Fasting blood samples were drawn via intra-cardiac puncture, blood was kept into epindrof tube without EDTA, held for not more than four hours before serum collection by centrifugation 3000 rpm for 15 minutes and frozen at 20C⁰ until analysis.

Serum samples were used for measurements of glutathione (GSH), malondialdehyde (MDA) concentrations. For histological study of rat tissue, the rats were anaesthetized by chloroform and killed. Immediately after death the mammary gland was excised and preserved in fixative solution till the preparation of histological sections. Several tissue sections were prepared according to (6).

Results

Microscopic examination of sections of mammary gland in treated virgin animals with spearmint showed more growth in the size of lobules and alveoli that showed more dilated compared with their control(figure 1 and 2).In pregnant mammary tissue that treated with spearmint revealed an increase in branching of alveoli with more flattened luminal epithelium, treated lactating mammary tissue revealed greatly dilated lobules containing more branching and more dilated alveoli with flattened epithelium figures (3,4and5). The serum MDA concentration was decreased significantly ($p<0.05$) and increase significantly ($p<0.05$) in GSH concentration level in all groups that treated with spearmint comparing to control (table 1 and 2) respectively. Diameters and number of alveoli were significantly increased($p<0.05$) in virgin, pregnant and lactating rats treated with spearmint.(table 3).

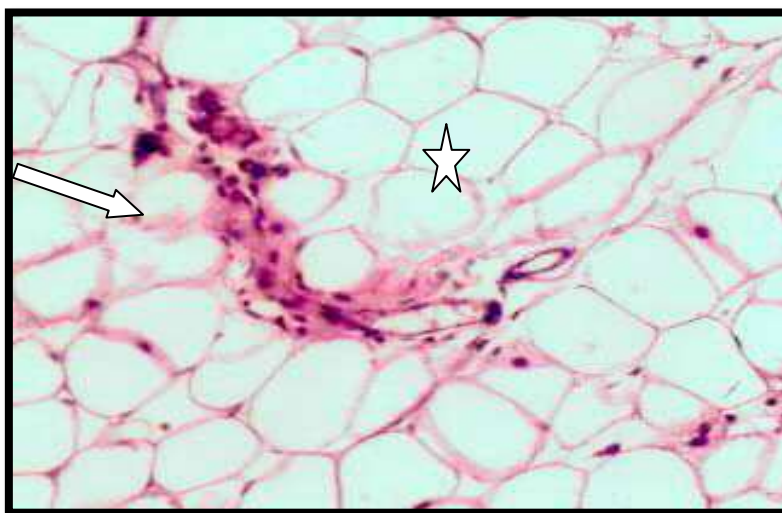
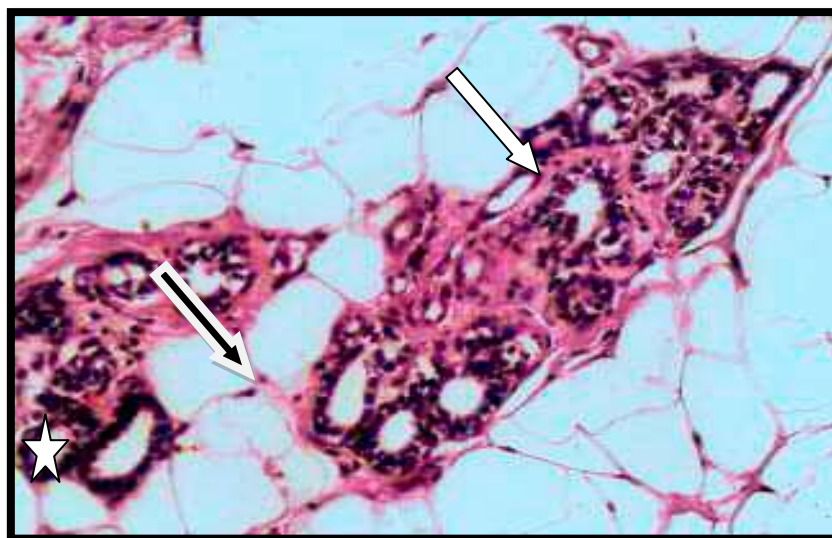
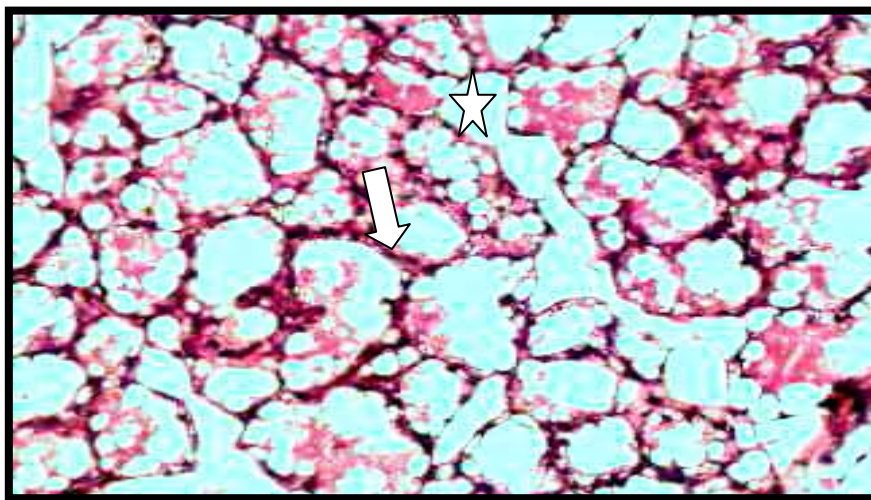


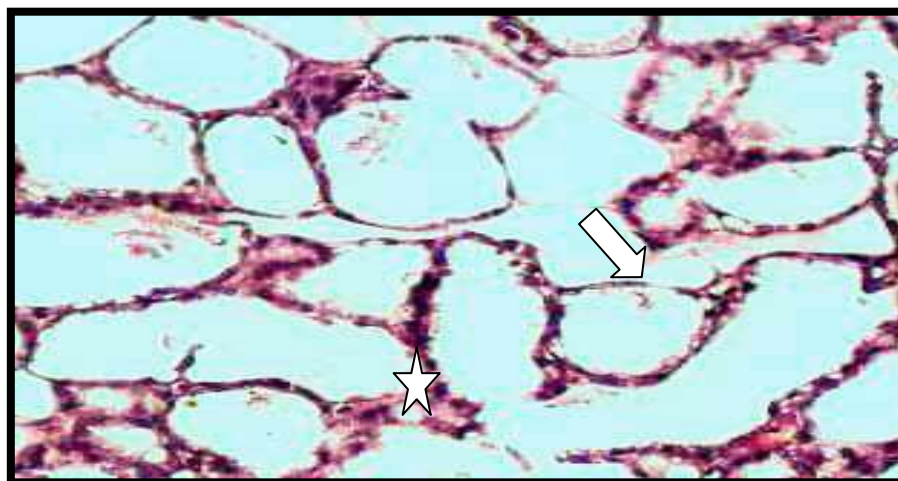
Figure (1) Histological section of mammary glands of virgin in control group. Showed small lobules (arrow) scattered among huge amount of adipose tissue (star) (H & E) (200X).



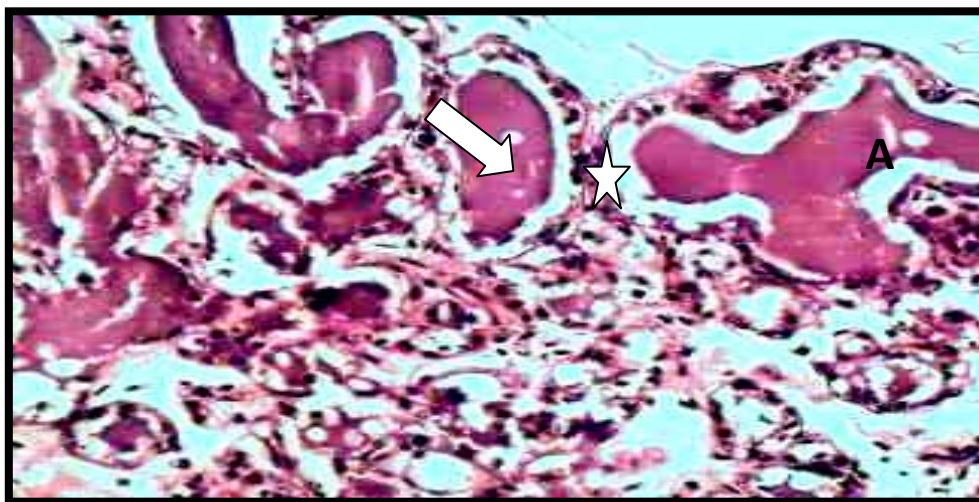
Figure(2) Histological section of mammary gland of virgin in spearmint treated group show large size of lobules (arrow) packed by alveolar ducts (star) with interlobular ducts (black arrow) (H & E stain) (200X).



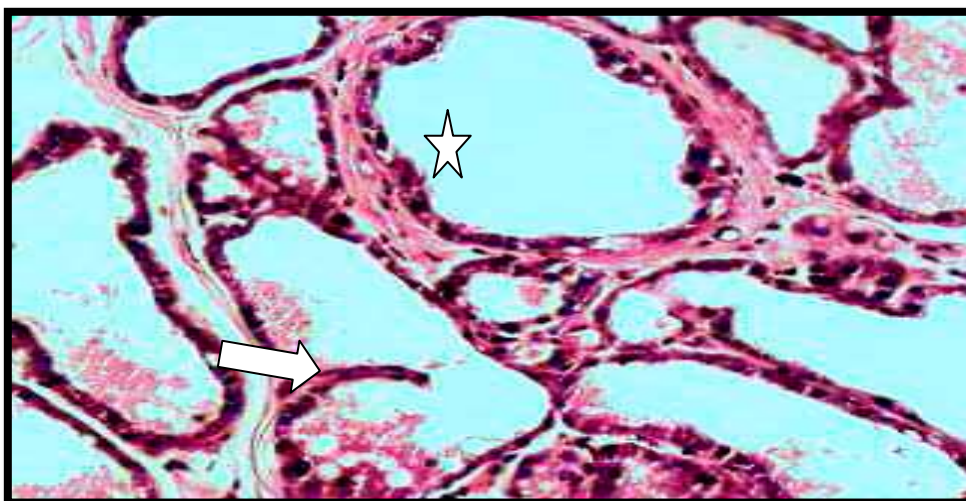
Figure(3) Histological section of mammary gland of pregnant in control group large size of alveoli (arrow) some of these alveoli filed with secretory product(star) (H & E stain) (200X).



Figure(4) Histological section of pregnant rat treated group with spearmint mammary gland show branching alveoli (star) with flattened epithelium (arrow)(H & E stain) (200X).



Figure(5) Histological section of mammary gland lactating rat in control group show dilated alveoli (arrow) with secretory products (star)(H a& E stain) (200X).



Figure(6). Histological section mammary gland of lactating rat in spearmint treated group show the alveoli were more dilated (star)and more branched (arrow)than other groups (H & E stain) (200X).

Table (1) Serum Malondialdehyde concentration (mg/dl) in female rats treated with aqueous extract of Spearmint for two weeks in different physiological stages

Stages Group	Virgin	Pregnant	Lactation
Control	3.07 A a ±0.73	3.22 A b ±0.65	3.25 A c ±0.60
Spearmint	2.85 B a ±0.78	2.83 B a ±0.69	2.79 B b ±0.71

Values are expressed as mean ± SE. N= 5/ group. Small letters denote difference within group p<0.05. Capital letters denote difference between groups p<0.05.

Table (2) Serum glutathione concentration (μmol/L) in female rats treated with aqueous extract of Spearmint for two weeks in different physiological stages.

Stages Group	Virgin	Pregnant	Lactation
Control	1.22 C a ±0.21	1.01 C c ±0.30	1.07 C b ±0.29
Spearmint	1.31 B a ±0.30	1.33 B a ±0.37	1.30 B a ±0.28

Values are expressed as mean ± SE. N= 5/ group. Small letters denote difference within group p<0.05. Capital letters denote difference between groups p<0.05

Table(3)Effect of daily oral intubation of effective dose of aqueous extract of spearmint in two weeks on the number and diameter of alveoli in mammary glands of treated rats.

Groups	Mean of the Number of alveoli			Mean of alveolar diameter		
	Virgin	Pregnant	Lactation	Virgin	Pregnant	Lactation
Control	0.2 ±0.06 A c	4.6 ±0.9 A a	2 ±0.3 A b	22.98 ±3.8 B c	33.88 ±5.0 C b	40.54 ±4.6 C a
Spearmint	1.5 ±0.4 B b	2 ±0.2 B a	1.4 ±0.3 B b	38.22 ±5.5 A c	47.36 ±5.9 A b	56.527 ±3.2 A a

n= 5/ group. Small letters denote within group difference p<0.05. Capital letters denote between groups difference p<0.05.

Discussion:

The present study pointed that the intubation of female rats in all physiological stages with 5.25 ml of aqueous extract of spearmint caused an increase in the size of lobules that packed with branching dilated alveoli, especially during pregnant and lactation stages compared with control. These histological features indicate that the control mammary glands revealed features of a resting mammary gland, which match the age and physiology of this group (7), while the spearmint treated groups showed that the spearmint had ability to induce mammary glands in the mammary glands of virgin ,pregnant and lactating rats in addition to estrogen , progesterone and prolactine., this might be due to increase in estrogen level that found in experiments treated with spearmint such as Akdogan and others where they found increased in level of estrogen, luteinizing hormone (LH) and Follicle-stimulating hormone (FSH) serum level with decreased in free testosterone when drink spearmint tea which found the spearmint act as anti androgen (8, 9). In mammary tissue, only one Androgen Receptor (AR) type has been reported. Several study observations suggest that androgens may suppress the growth of mammary epithelium, (10,11). The exact factor in the spearmint that caused these effect is unknown. It may be due to the production of ovarian steroid hormones is coordinated by the hypothalamic-pituitary gonadal axis which is activated in puberty. The hypothalamus produces and secretes luteinizing hormone-releasing hormone (LHRH), which binds to it is receptors in pituitary gland, this causes cascade of biochemical events culminating in the production of two hormones in pituitary gland (LH) and (FSH). LH and FSH are secreted into the general blood circulation and attach to receptors on the ovary, where they trigger ovulation and stimulate the production of estrogen and progesterone (12), so that spearmint have ability to increased growth of mammary gland by decreased the level of androgen hormones .

Our study also showed there was a significant decrease in the level of lipid peroxidation end product MDA and an increase in GSH level , this result agreement with previous study done by Padmini and co-worker (13) that found the addition of tea of spearmint extracts to the placental explants significantly decreased the level of MDA and increased in GSH , this reduction in lipid peroxidation level and increased in GSH may be attributed to the inbuilt scavenging and reducing property of the plant extracts. This property is attributed to the *Mentha spicata* extract has been found to have antioxidant and anti-peroxidant properties due to the presence of α -tocopherol, flavonoid compounds, eugenol and rosmarinic acid . (14 , 15 ,16, 17 ,18). The presences of free hydroxyl group in phenolic compounds of spearmint are mainly responsible for antioxidant activity in mint extract that contains provitamins enabling the iron to be available in soluble state, thereby increasing its absorption (19, 20).

In table(3) showed that in all experimental groups, there is a significant increase in the diameter of alveoli and the number of alveoli per lobule, when compared with their controls. Morphometrical analysis approves all earlier parameters , the highly significant increase of alveolar diameter, in experimental rats, is most probably reflecting the active condition of mammary gland. Similar changes were recorded during pregnancy and lactation(21).

This result was agreement with previous studies such as the study the effect of Fenugreek (22) , Anise (23) , Cresson (24) Harmal and Borage (25).

Conclusion

Evaluation of the galactagogue action of the leaves of *Mentha spicata* In the female rats in the virgin pregnant and lactating states, that exhibits galactagogue activity in comparison with the control group without any significant acute toxicity effect. A probable reason for this galactagogue effect could be the presence of some compound in this plant. This plant has been antioxidant activity that caused significantly increased in reduced GSH and decreased in MDA .

Reference:

1. **Bath,D. ; Dickinson, F.; Tucker, H. and Appleman, R. (1985).** Dairy cattle : principles, practices, problem,profits, 3rd ed.. The Iowa state University Press , USA.
2. **Lawrence ,R.(1985) .** Induced lactation and re-lactation (including nursing the adopted baby) . In : Breast feeding : A guide for the medical profession , 2nd ed., Lawrence RA (Ed.) . Mosby Co., Baltimore , Philadelphia , Toronto .
3. **Sjolin, S.; Hofvander, Y. and Hillervik, C.(1977).** Factors related to early termination of breast feeding: A retrospective study in Sweden. Acta. Paediatr. Scand ., 66:505-11.
4. **Lompo-Ouedraogo, Z. ; Van der, H.D. ; Van der Beek, E.M. ; Swarts, H.J.; Mattheij, J.A. and Sawadogo, L. (2004).** Effect of aqueous extract of *Acacia nilotica* ssp. *adansonii* on milk production and prolactin release in the rat. J. Endocrinol. 182 : 257-266.
5. **Newall, A. ; Linda, A. ; and David, Phillipson (1996).** Herbal medicines: A guide for health-care profess-Lionel's. ,The Pharmaceutical press,London.: 49-70.
6. **Bancroft, J. and Stevens , A(1982).**Theory and Practice of histological techniques , 2nd ed., Churchill Livingstone, Edinburg,London.
7. **Junqueira, L. and Carneiro, J.(2003).**Basic histology, 10th ed. The Mc Graw- Hill companies, Inc,USA.
8. **Akdogan, M. ; Ozunger, M. ; Aydin, G. and Gokalp, O. (2004).** Investigation of biochemical and histological effect of menthe piperita and *Mentha spicata* on liver tissue in rat. Human Toxicol. , 23(1) : 21-28.
9. **Akdogan, M. ; Tamer, E. ; Cure, B. ; Koroglu, B. and Delibas, N. (2007).** Effect of *Mentha spicata* Labiate teas on Androgen level in women with hirsutism. Phytother. Res., 21: 444-447.
10. **Dimitrakakis, C. ; Zhou. J. ; Wang, J. ; Belanger, A. ; Labrie, F. ; Cheng, C. and Powell, D, (2003)** A physiologic role for testosterone in limiting estrogenic stimulation of the breast. Menopause 10 : 292–298.
11. **Von Schoultz B (2007)** Androgens and the breast. Maturitas , 57:47–49.
12. **Tamm,K; Suhorutshenko, M; Rõõm,M ; Simm,J and Metsis,M, (2012).**steroid -basic science. Steroid hormones ..intech, Open Access Publisher. Tallinn University of Technology , Faculty of Science, Centre for Biology of Integrated Systems.
13. **Padmini,E. ; Valarmathi, A. and Usha Rani" M.(2010).** omparative analysis of chemical composition and antibacterial activities of *Mentha spicata* and *Camellia sinensis* .Asian J. Exp. Biol. Sci. 1(4) 2010:- 772- 781.
14. **Arumugam, P. ; Ramamurthy, P. ; Santhiy, S. and Ramesh, A. (2006).** Antioxidant activity measured in different solvent fractions obtained from menthe spicata Linn.: An analysis by ABTS(+) decolorization assay. Asia pacific J. of Clin. Nutri., 15 (1) : 119-124.
15. **Padmini E. ; Prema K. ; Vijaya Geetha B. and Usha Rani M.(2008)** Comparative study on composition and antioxidant properties of mint and black tea extract. Int J Food Sci and Technol. 2008a; 43(10): 1887-1895.
16. **Padmini E. ; Usha Rani M. and Lavanya S.(2008b)** Effect of mint and tea infusions on the antioxidant capacity of preeclamptic endothelial cells. Asian J Microbiol Biotechnol Environ Sci. 10: 903-909.
17. **Hussain, A. (2009).** Characterization and biological activate of essential oil of some species of lamiacea . Ph.D. University of Agriculture, Faisalabad, Pakistan.
18. **Fodal, M. ; El-Sayed M. ; Hassan, A. ; Rasmy, N. and El-Moghazy, M. (2010).** Effect of spearmint essential oil on chemical composition and sensory properties of white cheese .J.American.Sci., 6(5) :272-279.
19. **Padmini E. and Lavanya S.(2009).** In vitro studies on the activity of glutathione peroxidase in preeclamptic endothelial cells with mint tea extracts. Biomed.; 29: 165-169.
20. **Bicudo L. ; Muradian A. ; Vanderlinde D.W. and Sasaki R. (2000).** Provitamin activity of raw and cooked brazilian leaves. Cienc Technol Alimen. ; 20: 21-27.

21. **Backwell R. (2001).** Morphology of normal breast, its hormonal control and pathophysiology. In: (Principles and Practice of Endocrinology and Metabolism) .Lippincott Williams and Wilkins.
22. **Al-Khateeb, H. (1996).** Some morphological and histolochemical studies on rats mammary gland. Ph.D. Thesis, College of Medicine-University of Baghdad.
23. **Al-Saidi, W. (1997).** Study the effect of carrier factor and Peganum harmala as immunological titer of visceral leishmaniasis .M.Sc. thesis. College of Science - Al-Mustansiriyah University.
24. **Al-Yawer, M. A. (2003).** Evaluation of some galatagogues in the femal rat: Histological and morpholometrical studies .Ph.D. Thesis, College of Medicine - University of Baghdad.
25. **Al-Saidi, W. (2005).** Effect of some folk galatagogues on the mammary glands of the female rat: Histological , histochemical and immunohistochemical studies. Ph.D. Thesis. College of Science - Al-Mustansiriyah University.