

Focus Assessment of Transthoracic Echocardiography post septostomy Procedure in Patients Undergoing Ablation of Left Atrial Supraventricular Tachycardia

DOI: <https://doi.org/10.32007/jfacmedbagdad.6431949>

Marwa A. Mansour* MBChB
Ameen A. Al Alwany** MD, PhD



This work is licensed under a [Creative Commons Attribution-Noncommercial 4.0 International License](https://creativecommons.org/licenses/by-nc/4.0/)

Abstract

Background: Echocardiography has an important role to follow up patients with Iatrogenic atrial septal defect (IASD) and after Catheter ablation during electro-physiological study.

Objectives: evaluating the impact of non-invasive Transthoracic Echocardiography (TTE) parameters (LAVI, LVEF, ASD size and E/e') post radiofrequency ablation of left atrial arrhythmia.

Patients and methods: for the evaluation of the atrial septal defect, a transthoracic echocardiography (TTE) was used in patients who underwent left atrial arrhythmia ablation, enrolled in prospective study in the Iraqi center for cardiac diseases, in cooperation with university of Baghdad /college of medicine

Results: The outcomes of the present study were assessed according to Transthoracic Echocardiographic parameters with a median period of follow up of six months post-radiofrequency procedure for each patient. The mean of age was (36.28±10.34 years), females were 24 (51.1%) while males were 23 (48.9%), with no structured heart diseases and normal LV function with mean EF (64.68±5.23%) and the mean LA diameter (35.75±2.92mm). Iatrogenic atrial septal defects (IASDs) were detected by TTE in all patients with range from (2-5) mm with mean of (3.47±0.92). Also we noticed that patients with smaller ASD size had higher LVEF than those who had larger ASD size with (P=0.007), while there was no significant association between ASD size with left atrial volume index (LAVI) and E/e'.

Conclusions: Non-invasive Transthoracic Echocardiography (TTE) study that was used post atrial septostomy for monitoring the closure of residual atrial septal defect is useful and applicable. And may be used in daily practise post atrial septostomy procedure and recommended rather than the use of invasive Transoesophageal Echocardiography (TEE).

Keywords: Transseptal puncture, Iatrogenic atrial septal defect, transthoracic echocardiography, Radiofrequency ablation

JFac Med Baghdad
2022; Vol.64, No. 3
Received: July. 2022
Accepted: Aug. 2022
Published: Oct. 2022

Introduction:

Echocardiography has an important role to follow up patient post catheter ablation during electrophysiological study, is considered nowadays the primary focus of patient management with supraventricular tachycardia (SVT)1 and has gradually expanded the role it plays in the treatment of different types of arrhythmias. Due to the interatrial septum's oblique position and the left atrium's (LA) long and narrow appendage, the LA has a complex morphology that may make echocardiographic assessment challenging. Current echocardiographic techniques, which permit surface and volume assessment, assume spherical, cube, or ellipsoid models for the LA that are not entirely

accurate and may result in error. 2 The detection of iatrogenic or persistent defects of atrial septum, which have been presented to occur in the predominance (eighty-seven percent) of individuals in the immediate post-procedure period but with a significant decreasing of percentage (seven percent) over the following twelve months, is a significant concern with transseptal puncture (TSP) and the subsequent use of large-bore sheaths through septum.1, 3. Iatrogenic atrial septal defect (IASD) and shunt degree can both be identified with TTE and TEE. Studying IASD morphology and size is more accurate with TEE3, 4. Understanding the nature of IASDs is limited due to the paucity of long-period follow up in patients undergoing transcatheter operations involving TSP. According to current research, IASD closure is recommended if patients experience symptoms including increasing refractory hypoxemia, heart failure, cryptogenic stroke, or even other paradoxical embolic events.5 Leaving a defect following transseptal puncture is not currently thought of as a problem. Shunting by IASD is widely

*Kirkuk General hospital:
marwamansour799@gmail.com

** Corresponding Author: Dept. of Medicine,
College of Medicine, University of Baghdad
amen.a@comed.uobaghdad.edu.iq

documented, however closure or follow-up are not always done. In a heart that is generally anatomically sound, the shunt is primarily left to right, whereas right to left shunting can be seen in patients who have underlying right atrial pressure elevation.⁶ In this case, a recently developed defect may cause acute right ventricular failure in an unprepared ventricle and biatrial pressure equalization, which may result in no flow stage.^{3,7}

A basic, non-invasive method for detecting ASD, two-dimensional (2D) transthoracic echocardiography (TTE), has a high sensitivity and specificity. Harmonic imaging, a suitable contrast agent (often agitated saline), provocative manoeuvres and color Doppler can all be used to increase sensitivity.⁸ When there are weak acoustic windows or tiny (five mm) faults, TEE might be preferable over TTE.^{3,9} The septal structure and extent of the defect or defects can be more clearly seen with 2- or 3-dimensional (3-D) TEE, but it is a more invasive treatment. ¹⁰ Using color Doppler in subcostal view, measure the largest dimension in individuals with atrial septal defect (ASD). The individuals who maintained sinus rhythm showed improved left ventricle systolic and diastolic performance concurrently with the improvement in LA function, according to the novel tissue Doppler-derived measures.^{11, .12}

Patients and methods

During the period from April 2019 to June 2020, a prospective study was carried out in the Iraqi Center for Cardiac Diseases with patients who had undergone an electrophysiology procedure and had their left atrial SVT ablation. Patients were chosen based on exclusion and including criteria and referred to the echo-cardiographic unit.

Patients with atrial septal aneurysm (ASA), Patent foramen oval (PFO), and atrial septal defect (ASD) were diagnosed on initial baseline Echo report, LV systolic dysfunction, Structural heart disease, poor image quality and, CHA2DS2-VASc score > 1, were excluded from this study.

Data were collected by using questionnaire designed by the investigator and the supervisor Anthropometric measurements were done while the patients with light clothing and without shoes.

(BSA) Body surface area was calculated by Mosteller equation as:

$$\{BSA (m^2) = \sqrt{\text{Weight (kg)} \times \text{height (cm)} / 60\}.$$

Echocardiography: Under an ECG connection, a standard echocardiogram was conducted. Using a

(GE Vivid E9 ultrasonography) machine with a 5 MHz phased array probe with the participant lay in supine and in the left lateral decubitus position, echo doppler examinations were performed. LA anteroposterior dimension was measured by 2-D in PLAX view. The LV ejection fraction was assessed by M-mode in PLAX view. Pulse tissue Doppler imaging was obtained from medial and lateral mitral annulus and early diastolic annulus velocity (E') was measured. Trans mitral Doppler flow was obtained by PW Doppler on the tip of mitral valve leaflet from apical four-chamber view and peak early filling velocity (E) wave was measured. LA volume was measured by biplane area-length method from 2-D Echocardiography from apical two and four chamber views then indexed to body surface area. The size of inter atrial septal defect was measured in subcostal view by using colour Doppler and the direction of inter atrial defect flow was also assessed and LA area was traced at end systole before mitral valve opening by 2-D in apical four chamber view.

Statistical test:

The gathered information was entered into the Microsoft EXCEL program before being analysed with the SPSS program (version 23, Inc., Chicago, IL, USA 2018). Both descriptive and inferential statistics were applied to the data analysis. The mean and standard deviation numbers (Mean and standard deviation) were used to express continuous data. The minimum and maximum values, frequencies, and percentages were used to express categorical data. Independent sample t-tests were used to compare means within groups of two, and the one-way ANOVA test was employed to determine the significance of differences between more than two means. The risk factors for the success and failure of ASD were found using multivariate logistic regression analysis.

Results

Standard characteristics: According to Echocardiographic parameters the findings of this study were tested and the data collected following electrophysiology study. 47 patients were recruited in this study including 24, (51.1%) female (mean age 37.38± 11.62years) and 23, (48.9%) males (mean age 35.13 ±8.93years) (Table 3.1), those patients had radiofrequency ablation of left atrial SVT and single-puncture of interatrial septum.

Table3.1: starting demographic characteristics of the studt group.

Gender (%)		Age (yrs.) (Mean ± SD)		Min	Max	BSA (m2) (Mean ± SD)		Min	Max
Female	24 (51.1)	37.38	(11.62)	19	57	1.80	(0.15)	1.60	2.10
Male	23 (48.9)	35.13	(8.93)	17	53	1.91	(0.16)	1.60	2.20

Concerning the starting echo values shown in Table 3.2, which shown that a left to right shunting was also present through the defect in 47 patients with an iatrogenic ASD that had a diameter ranging from (2 to 5) mm.

Table 3.2: Starting Echo parameters

Echo parameters	(Mean \pm SD)	Minimum	Maximum
LVIDd	47.13 (5.31)	40	74
LVEF (%)	64.68 (5.23)	56	77
E wave	73.23 (12.99)	45	97
IVSd	8.81 (1.33)	7	12
A wave	59.43 (8.54)	30	74
E/A ratio	1.25 (0.36)	0.7	3
PWd	8.62 (1.21)	7	12
E / e` ratio	6.45 (1.80)	4	12
LA area	17.87 (2.53)	13	23
IASD size	3.47 (0.92)	2	5
e` lateral	12.23 (2.49)	7	19
LA diameter	35.75 (2.92)	30	34

* IVSd interventricular septum in diastole, LVIDd left ventricle internal dimension in diastole, LVEF left ventricle ejection fraction IASD (iatrogenic atrial septal defect), PWd posterior wall in diastole, LA (left atrium).

Transthoracic echocardiography at the initial visit, three and six months later:

All 47 patients had iatrogenic ASD detected the day after the procedure, and after three months of follow-up, we saw that 35 (74%) of the participants had ASD spontaneous closure, while the remaining 12, 26% had persistent ASD. as shown in (figure 3.1).

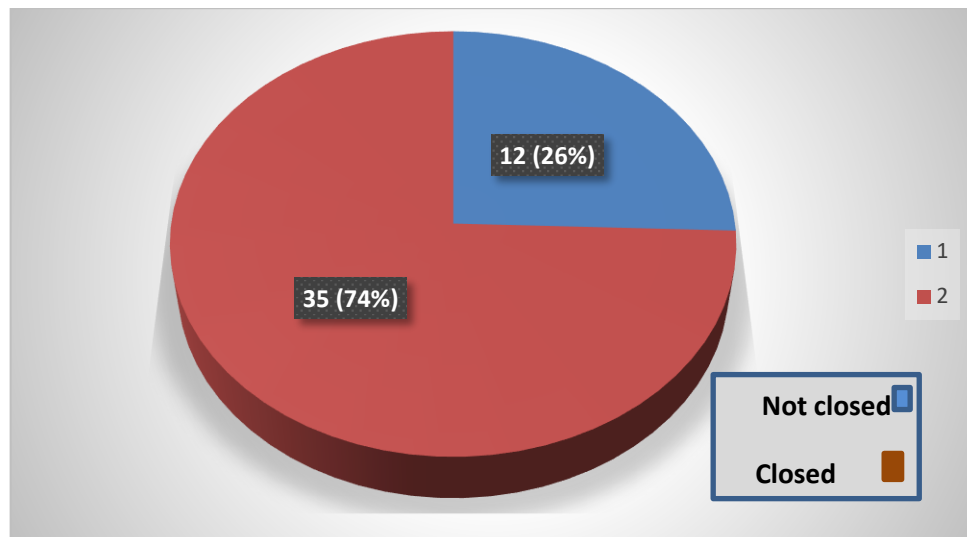


Figure 3.1 ASD closure rates and percentages at three months' follow-up

Regarding to LVEF of all patients it was within normal ranges, we noticed that patients with smaller ASD size had higher LVEF than those who had larger ASD size (P= 0.007) (Table 3.3).

Table (3.3) Association between ASD size and LVEF

Size of ASD	LVEF (%)				P -value
	No	(Mean \pm SD)	Min	Max	
2mm	6	69.83 (3.82)		64	0.007
3mm	21	64.71 (4.30)		57	
4mm	12	64.92 (6.27)		57	
5mm	8	60.38 (3.25)		56	

There was no significant relation regarding the size of ASD with each of LAVI and E/e`.

Table 3.4: Association between ASD size with LAVI and E/e`

Size of ASD	LAVI (ml/m2)			P value	E/e` ratio			P -value
	No	(Mean \pm SD)			No	(Mean \pm SD)		
2mm	6	28.83 (2.3)		0.108	6	6.33 (1.63)		0.689
3mm	21	27.14 (4.6)			21	6.24 (1.22)		
4mm	12	26.42 (5.79)			12	6.42 (2.35)		
5mm	8	31.63 (6.07)			8	7.15 (2.39)		

*LAVI left atrium volume index

Following LVEF, BSA, catheter type, troponin level, and ASD size each of which may be taken into consideration as independent predictors for ASD closure after three months of follow-up, according to the logistic regression analysis of various factors as shown in (Table 3.5).

Table 3.5: ASD closure delays following a three-month follow-up are predicted using a logistic regression table.

Predictors	Odds ratio	Coefficient	Confidence Lower	interval upper	P value
Gender	0.21	- 5.01	0.01	0.157	5.23
Age	1.06	0.06	0.89	0.056	1.30
BSA	1.89	- 14.87	1.21	0.023	3.84
LVEF	1.67	- 2.136	1.08	0.045	5.45
LAVI 1st	0.98	0.021	0.02	0.460	7.89
ASD Size	2.01	- 15.36	1.81	0.001	4.25

Discussion:

As a less invasive method during follow-up, transthoracic echocardiography with color Doppler was utilized in our study to evaluate iatrogenic ASD. The defect means size discovered was (3.47 0.92) with a left to right shunt and no notable hemodynamic effects. While numerous studies found lower rates of permanent abnormalities when using transthoracic echocardiography (TTE) for the monitoring of iatrogenic ASD³, 14 The TEE evaluation is more invasive, though, and for many patients, it might not be a practical surveillance test. On the other hand, the current study shows that LA pressure is not substantially correlated with the size and closure of ASD, as determined by the TTE E/e ratio, and this conclusion can be attributed to all of the participants who were chosen for the study had a normal ratio. Singh et al.'s¹⁵ study, which demonstrated that LA pressure increases the patency and/or identification of persistent ASD on TEE imaging, suggested a relationship between higher baseline LA pressure and persistent iatrogenic ASD. Although Riling A has not verified these findings¹⁶, ¹⁷ they show no association with iatrogenic ASD size or incidence with LA size or LA pressure. According to our study, neither the body surface area (BSA) nor the patient's gender had a discernible impact on the resolution of ASD. These results are not consistent with Nagy Z et al.^{17,18} relating to the finding that patients with IASD after three months' follow-up had a greater BMI than patients without IASD. Our results show that the left atrium volume indexed to body surface area (LAVI) was normal or modestly enlarged. Following three months of follow-up, LAVI decreased, and there was no significant correlation between LAVI and the size or closure of ASD³. The healthy LA is more flexible and stretched, with less stiffness, which causes a larger size for high pressure and more reversibility from structural remodeling, as an explanation for this¹⁸. While less flexible and stiffer in the reconstructed LA where the myocardium has transformed into fibrous tissue, resulting in a smaller size and reduced reversibility, this condition is referred to as stiff LA syndrome.²⁰, ²²

Conclusions:

Non-invasive Transthoracic Echocardiography (TTE) study that used post- atrial septostomy for monitoring the closure of residual defect of the atrial septum is safe and applicable, and might be used in daily practise post- atrial septostomy procedure and

recommended rather than the use of invasive Transoesophageal Echocardiography (TEE).

Author's contributions:

All authors contributed to data analysis, drafting, and revising of the paper and agreed to be responsible for all the aspects of this work.

References

1. Al-Alwany A. AH jump as predictor for successful Ablation of atrioventricular nodal re-entrant tachycardia (AVNRT). *J Fac Med Baghdad* 2015; Vol.57, No .2 Received Oct 2014 Accepted Jan.2015
2. Armstrong, William F.; Ryan, Thomas: *Feigenbaum's Echocardiography*, 7th edition copyright C 2010 Lippincott Williams &Wilkins.p. 649-656
3. Al-Alwany A. Iatrogenic atrial septal defect post radiofrequency ablation in patients with left atrial SVT: predictors and outcome. *Revista Latinoamericana de Hipertensión*. Vol. 16 - N° 3, 2021
4. Simpson J, Lopez L, Acar P, et al. Three-dimensional Echocardiography in Congenital Heart Disease: An Expert Consensus Document from the European Association of Cardiovascular Imaging and the American Society of Echocardiography. *J Am Soc Echocardiogr*. 2017; 30:1-27
5. Chandraprakasam S, Satpathy R. When to close iatrogenic atrial septal defect after percutaneous edge to edge repair of mitral valve regurgitation. *Cardiovasc. Revasc. Med* 2016; 17:421-423
6. Chan N-Y, Choy C-C, Lau C-L, et al. Persistent iatrogenic atrial septal defect after pulmonary vein isolation by cryoballoon: an under-recognized complication. *EP Europace*. 2011; 13:1406-10.
7. Ussia GP, Cammalleri V, Marchei M, et al. Hemodynamic patterns of residual interatrial communication after transcatheter mitralclip repair. *J Cardiovasc Med (Hagerstown, Md.)*. 2014; 15:343-349.
8. Soliman OI, Geleijnse ML, Meijboom FJ, et al. The use of contrast echocardiography for the detection of cardiac shunts. *Eur J Echocardiogr* 2007; 8(3): S2- S12. Crossref PubMed Web of Science@Google Scholar
9. Hausmann D, Daniel WG, Mgge A, et al. Value of transesophageal color Doppler echocardiography for detection of different types of atrial septal defect in adults. *J Am Soc Echocardiogr* 1992; 5(5): 481-488. Crossref CAS PubMed Google Scholar

10. Hoey ETD, Gopalan D, Ganesh V, et al. Atrial septal defects: Magnetic resonance and computed tomography appearances. *J Med Imaging Radiat Oncol* 2009; 53(3): 261– 270. Wiley Online Library CAS PubMed Web of Science@Google Scholar.
11. Shimamoto K, Kawagoe T, Dai K, et al. Thrombus in the left atrial septal pouch mimicking myxoma. *J Clin Ultrasound* 2014; 42:185-8.
12. Ameen Abdulhasan Al Alwany, Echocardiographic Assessment of the Aortic Stenosis Valve Area: Parameters and Outcome. *J. Med. Chem. Sci.*, 2022, 5(7) 1281-1288
<https://doi.org/10.26655/JMCHMSCI.2022.7.17>
URL:
http://www.jmchemsci.com/article_154735.htm
13. Tops LF, van der Wall EE, Schalij MJ, et al: Multimodality imaging to assess left atrial size, anatomy and function. *Heart* 2007; 93:1461-1470. Doi:10.1136/hrt.2007.116467.
14. Grzegorz R., Aleksander P., Marek K., Body surface area formulae: an alarming ambiguity. *Sci Rep*. 2016; 6: 27966.
15. Schueler R, Ozturk C, Wedekind JA et al. Persistence of iatrogenic atrial septal defect after interventional mitral valve repair with the MitraClip system: a note of caution. *JACC Cardiovasc Interv* 2015; 8:450-9.
16. Singh SM, Douglas PS, Reddy VY et al. The incidence and long-term clinical outcome of iatrogenic atrial septal defects secondary to transseptal catheterization with a 12F transseptal sheath. *Circ Arrhythm Electrophysiol* 2011; 4:166-71.
17. Rillig A, Meyerfeldt u, Kunze M et al, Persistent iatrogenic atrial septal defect after a single-puncture, double-transseptal approach for pulmonary vein isolation using a remote robotic navigation system: results from a prospective study, *EP Europace*, Volume 12, Issue 3, March 2010, Pages 331–336, <https://doi.org/10.1093/europace/eup428>.
18. Nagy Z, Kis Z, Géczy T, et al. Prospective evaluation of iatrogenic atrial septal defect after cryoballoon or radiofrequency catheter ablation of atrial fibrillation-"EVITA" study. *J Interv Card Electrophysiol*. 2019;56(1):19-27. doi:10.1007/s10840-019-00598-9
19. Abbas, H.H., Al-Alwany, A.A., Dleikh, F.S.: Impact of smoking on cardiac electrophysiological parameters of symptomatic sinus node patients in Iraq: *Pakistan Journal of Medical and Health Sciences*, 2020, 14(4), pp. 1643–1650
20. Calkins H, Kuck KH, Cappato R, et al. 2012 HRS/EHRA/ECAS expert consensus statement on catheter and surgical ablation of atrial fibrillation, *Heart Rhythm* 2012;9:632–696. e621.
21. Al-Alwany A., Haji G.F., Hassan Z.F., His-Ventricle (HV) Interval And Syncope As Predictor For Pacemaker Implantation In Patients With Bifascicular Block (BFB), *Medical Journal of Babylon*, 2017, 14:126
22. Abbas, H.H., Al-Alwany, Shareefdleikh, E.: Relation of red cell width diameter with some electrophysiological parameters of symptomatic sinus node patients in Iraq: *Pakistan Journal of Medical and Health Sciences*, 2020, 14(4)

التقييم المركز لتخطيط صدى القلب عبر الصدر بعد الفتحة في الجدار الأذين للمرضى الذين يخضعون لاستئصال تسارع دقات القلب فوق البطينية في الأذين الأيسر

د. مروه عبد العظيم منصور: بكالوريوس في الطب والجراحة العامة
أ.م.د. أمين عبد الحسن مانع العلواني: فوق الدكتوراه (أختصاص دقيق) في التداخل القسطاري الكهربائي كلية الطب جامعة بغداد

الخلفية: تخطيط صدى القلب له دور مهم في متابعة مرضى عيب الحاجز الولادي علاجي المنشأ، وبعد الاستئصال بالقسطرة أثناء دراسة الفيزيولوجيا الكهربائية، والتي تعتبر في الوقت الحاضر الخط الرئيسي في إدارة المرضى الذين يعانون من أنواع مختلفة من عدم انتظام ضربات القلب. من خلال البزل عبر البزل ثقب واحد أو ثقب مزدوج يسهل طريقة مرور القسطرة بسهولة إلى الأذين الأيسر لاستئصال دقات القلب فوق البطينية.

الأهداف: تهدف دراستنا إلى تحديد معدل حدوث عيب الحاجز الأذيني علاجي المنشأ (IASD) وإجراء عملية استئصال بالترددات الراديوية (RF) لإضطراب انتظام ضربات القلب الأذيني الأيسر باستخدام صدى القلب عبر الصدر (TTE). ولتقييم تأثير حجم الغمد وعددها على إغلاق عيب الحاجز الأذيني.

الطرق والأساليب: تم استخدام تخطيط صدى القلب عبر الصدر لتقييم عيب الحاجز الأذيني في 47 مريضاً خضعوا لاجتثاث انتظام ضربات القلب الأذيني لأيسر، مسجلين في دراسة مستقبلية (من مايو 2019 إلى مايو 2020) في المركز العراقي لأمراض القلب، بعد إجراء فترة متابعة متوسطة ستة أشهر لكل مريض. كان متوسط عمر المرضى 8.93 ± 35.13 سنة، الذكور 23 (48.9%) والإناث 24 (51.1)، بدون أمراض قلب هيكلية ووظيفة البطين الأيسر جيدة بمتوسط EF (5.23 ± 64.68) % ومتوسط الأذين الأيسر قطره (2.92 ± 35.75) ملم.

النتائج: تم الكشف عن عيب الحاجز الأذيني علاجي المنشأ (IASD) بواسطة صدى القلب عبر الصدر (TTE) في جميع المرضى الذي يتراوح حجمه بين (2-5 ملم) بمتوسط (0.92 ± 3.47) . يحدث الإغلاق التلقائي في 35 (74%) مريضاً في الأشهر الثلاثة الأولى مع ارتباط واضح بين حجم عيب الحاجز الأذيني (ASD) المرتبط بحجم الغمد ومدة إجراء العملية ($P < 0.0001$).

الاستنتاجات: يعتبر صدى القلب عبر الصدر طريقة غير غازية بسيطة وقابلة للتطبيق لمتابعة المرضى بعد استئصال تسارع دقات القلب فوق البطينية (SVT) في الأذين الأيسر وظهرت معدل إغلاق تلقائي مرتفع خلال السنة الأولى بعد إجراء العملية سواء تم استخدام غمد فردي أو مزدوج دون حدوث خطر المضاعفات.

الكلمات المفتاحية: عيب الحاجز الأذيني علاجي المنشأ، ثقب الحاجز، استئصال الترددات الراديوية، صدى صوت القلب عبر الصدر.