

# **EFFECT OF ACUTE EXPOSURE OF LEAD ACETATES ON THE MORPHOLOGY OF LIVER AND KIDNEY OF MICE (*MUS MUSCULUS*) AND THE ROLE OF VITAMIN C AS A REPAIRING AGENT**

Wissam S.H. Al-Uboody; Ishraq J. H.<sup>2</sup>; M.A. Al-Diwan<sup>3</sup>

. Department of Physiology, College of Medicine, University of Al-Muthanna, Al-Muthanna ,Iraq

. Department of Physiology, College of Medicine, University of Maysan, Maysan,Iraq.  
Department of Physiology, College of Veterinary Medicine, University of Basrah,Basrah,Iraq.

*(Received 13 February 2010, Accepted 18 April 2011)*

**Keywords:** lead, vitamin C, mice.

## **ABSTRACT**

The objective of this study is to elicit the destructive effect of lead on the tissues of liver and kidney of mice and if vitamin C is capable of repairing the damage caused by lead. In this study, 40 male mice were used and divided into three groups as: Control group which consists of 16 mice; 8 of them were injected intraperitoneally with (0.9 % N.S.) for 15 days daily then they were sacrificed and the remainder 8 mice were injected intraperitoneally with (0.9 % N.S.) for additional 15 days daily then they were sacrificed, First treated group (T1 group) which consists of 8 mice only; they were injected intraperitoneally with (80 mg/kg) lead acetates then with (400 mg/kg) vitamin C after one hour of lead acetates injection for 15 days daily then they were sacrificed, Second treated group(T2 group) which consists of 16 mice; they were injected intraperitoneally with (80 mg/kg) lead acetates for 15 days daily then 8 of them were sacrificed and called as (T2a) and the remainder 8 mice were injected with (400 mg/kg) vitamin C for additional 15 days daily and called as (T2b). Histologically, the kidneys of the lead acetates treated group indicated undefined epithelial cell lining and also the presence of giant-like cells. When vitamin C offered, it decreased the damage that caused by lead where the kidneys indicated the

presence of cuboidal epithelial cells with disrupted epithelial cell lining, and increased intracellular space in the lumen.

The livers of the lead acetates treated group indicated the presence of abnormal hepatocytes with distorted shape and undefined epithelial cell lining enlarged nucleus with vacuolations. The incidence of changes and severity were less in the vitamin C treated group. The effect of vitamin C was similar if it is offered after one hour of lead injection or for additional 15 days after lead injection. Hence acute exposure to lead causes morphological changes in the liver and kidney of mice. Hence acute exposure of lead may be toxic and is associated with various pathological conditions such as hepatic and renal dysfunction and cancers.

## **INTRODUCTION**

Lead (Pb) is one of the most important toxic metals due to its increasing level in the environment as the result of industrial practices. Lead poisoning is considered to be a main threat to human health, together with other elements such as cadmium, mercury and arsenic (10). However Pb levels in the environment are vary widely depending on the presence of industrial sites (17).

Nowadays, it is known that occupational and environmental Pb exposure can result in nephrotoxicity (3), hepatotoxicity (7) , skeletal damage (1) and several types of cancer in organs such as the urinary bladder, pancreas, breast, kidney, lung and prostate. Pb administration produced damage to the entire kidney, including proximal tubular cell degeneration, interstitial inflammation and fibrosis, glomerular swelling, atrophic and pyknotic nuclei, interstitial edema, glomerular basement membrane swelling, mitochondrial swelling, clear, vacuoles, apoptosis, necrosis, occasional segmental sclerosis and mesangial expansion in the glomeruli (11).

Vitamins are known as organic substances of nutritional nature, present in low concentration as a natural component of an enzyme system and catalyze required reactions and may be derived externally or by extrinsic biosynthesis. They act as co-factors in enzyme systems, antioxidants or antagonist (6) .

The properties of ascorbic acid (vitamin C) are well documented and have generated a great deal of interest in recent years for a wide range of protective effects in biological systems (8) .

Ascorbic acid is a powerful antioxidant that can neutralize harmful free radicals, and it helps the formation of collagen, a tissue needed for healthy bones, teeth, gums and blood

vessels (4) . Excellent food sources of vitamin C are citrus fruits or citrus juices, berries, green and red peppers, tomatoes, broccoli, and spinach (2). The present study was designed to focus on the effect of vitamin C on tissues damage resulting from lead toxicity , therefore ; the aim was to assess the histological changes in the kidney and liver tissues of mice which were exposed to lead acetates  $\text{Pb}(\text{CH}_3\text{COO})_2$ . The effect of acute exposure of  $\text{Pb}(\text{CH}_3\text{COO})_2$  on the morphology of the kidney and liver of mice were determined at (80mg/kg/body weight) for 15 days daily.

## **MATERIALS AND METHODS**

The experiment was conducted at the animal house of the Veterinary Medicine College–University of Basrah, where 40 males mice (*Mus musculus*) sexually mature, 12 weeks old, and of 20–25 grams weights were used. The experiment conditions were unified for all animals, where the room temperature was set between 20–25 C by the use of an air conditioner, and the daily light period was 12 hours by the use of two fluorescent lamps, and the humidity rate was about 50 %. Food and water were provided daily (*ad libitum*). Three days later, the animals were separated in three groups:

Control group: Consisted of 16 male mice.

First treated group (T1): Consisted of 8 male mice.

Second treated group (T2): Consisted of 16 male mice.

The animals of the control group were injected intraperitoneally with (0.9 % N.S.) for 15 days daily, then 8 mice of them were sacrificed and the remaining were injected with (0.9 % N.S.) for additional 15 days and then sacrificed.

T1 group animals were injected I.P. with vitamin C at a dose (400 mg/kg) after one hour of  $\text{Pb}(\text{CH}_3\text{COO})_2$  I.P. injection at a dose (80 mg/kg) for 15 days daily then they were sacrificed.

T2 group animals were injected I.P. with  $\text{Pb}(\text{CH}_3\text{COO})_2$  at a dose (80 mg/kg) for 15 days daily then 8 mice of them were sacrificed as (T2a) and the remaining were injected I.P. with vitamin C at a dose (400 mg/kg) for additional 15 days daily as (T2b) then they were sacrificed.

Whole liver and kidneys were removed, and fixed in 10% formaldehyde for 48hrs for histological analysis. The liver and kidney tissues were processed and embedded in

paraffin wax. 6µm thick sections were obtained and stained by the haemotoxylin and eosin (H&E) method and examined under light microscope to determine the morphological changes (13).

## **RESULTS AND DISCUSSION**

### **Effect of lead acetates on kidney histology**

Histologically, the control kidney tissue (Fig.1A) indicated the presence of normal cuboidal shaped cell with defined epithelial cell lining. In (T2a) group the disruption of the cuboidal cell was prominent with undefined epithelial cell lining and clumping of nucleus (formation of giant-like cells) in addition to interstitial hemorrhage in kidneys of lead acetates treated animals (T2a) (Fig. 1B).

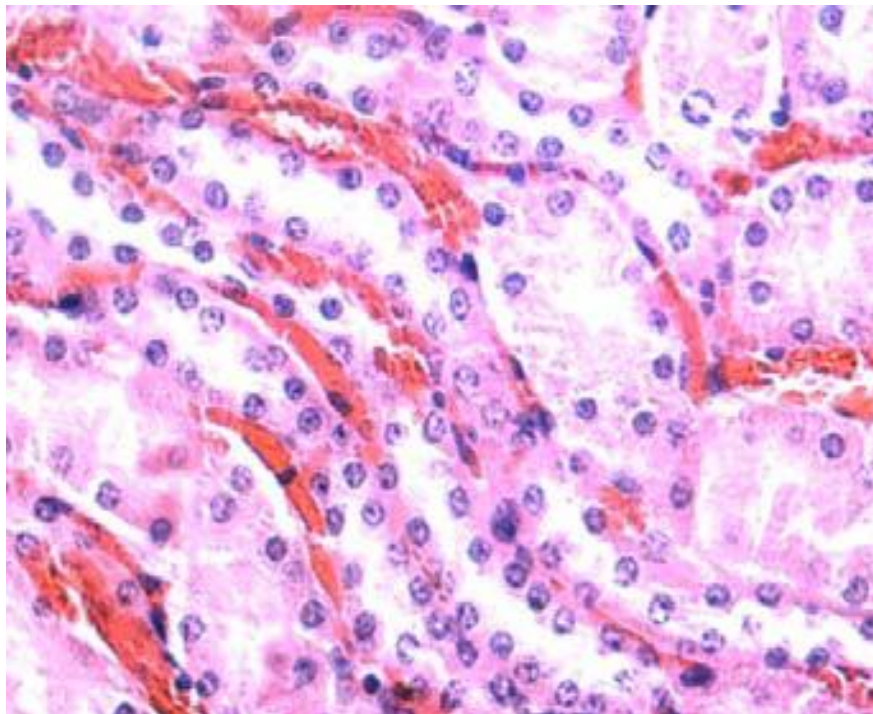
When vitamin C was offered either after one hour after lead injection (T1) or for additional 15 days after lead injection (T2b) the cuboidal shaped cell has been slightly disrupted with less defined epithelial cell lining , increased intracellular space or lumen and fibrosis (Fig.1C,D). The clumping of nucleus in the certain portion of the tissue reflects the abnormality of the kidneys in the treated group (15).

### **Effect of lead acetates on liver histology**

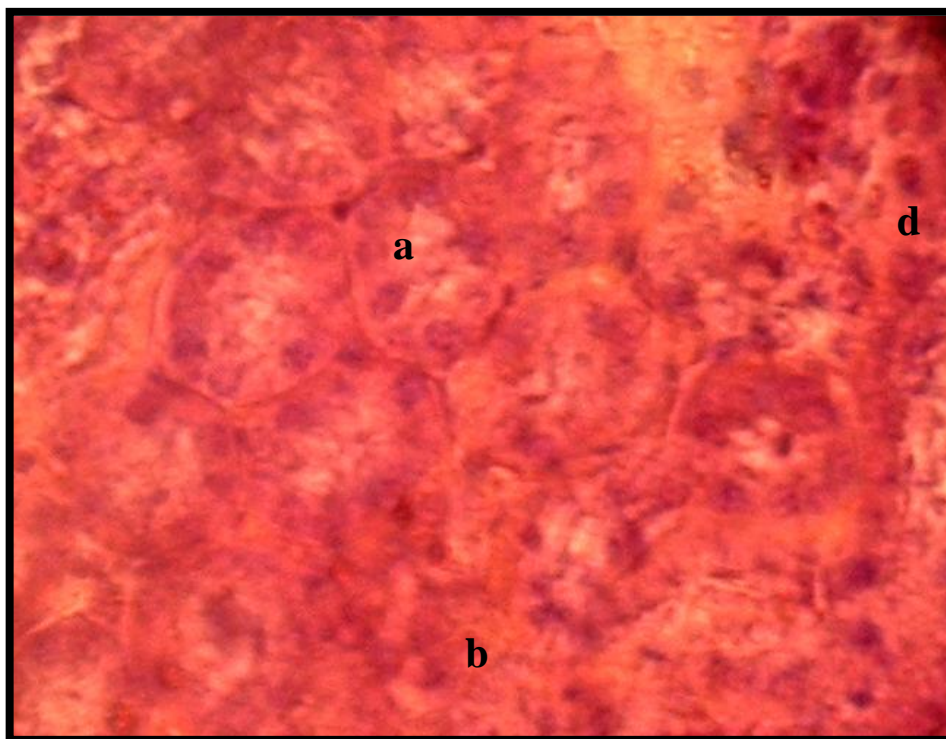
Histologically, the control liver tissue indicated the presence of normal hepatocytes which are polyhedral in shape with defined cell lining, nuclei are distinctly rounded, with one or two prominent nucleoli (Fig 2 A).

The livers sections of the T1 and (T2b) vitamin C treated groups indicated the presence of abnormal hepatocytes with a distorted shape and undefined cell lining (Fig 2 C and D). The incidence of changes were more prominent in lead acetates treated group (T2a), where massive cytoplasm associated with the reduction in intracellular space was also observed in this group (Fig 2B). Vacuolation of hepatocytes and enlarged nucleus was also observed in (T2a) lead acetates treated group. Vacuolation or fatty change (the excessive accumulation of fat in the cytoplasm) is a characteristic of many exposed livers, the large vacuole in the cell forces the nuclei to the periphery of the hepatocyte is usually accompanied by nuclear atrophy (9). The morphological changes in the liver may be due to the the toxic effect of the Pb which may affect the normal liver functions.

Pb mainly accumulates in the liver and kidney because they contain metallothionein (MT), a metal binding protein which has high affinity for Pb (12). After absorption, most of the Pb is accumulated in the liver where it induces the production of MT, when the synthesis of MT becomes insufficient for binding the Pb and can cause hepatocyte injury and taken up by the proximal tubular cells of the kidney (5), (16). Cell damage is followed by the release of a number of cytoplasmic enzymes to the blood, indicating the liver dysfunction due to the acute effects of cadmium exposure (14).

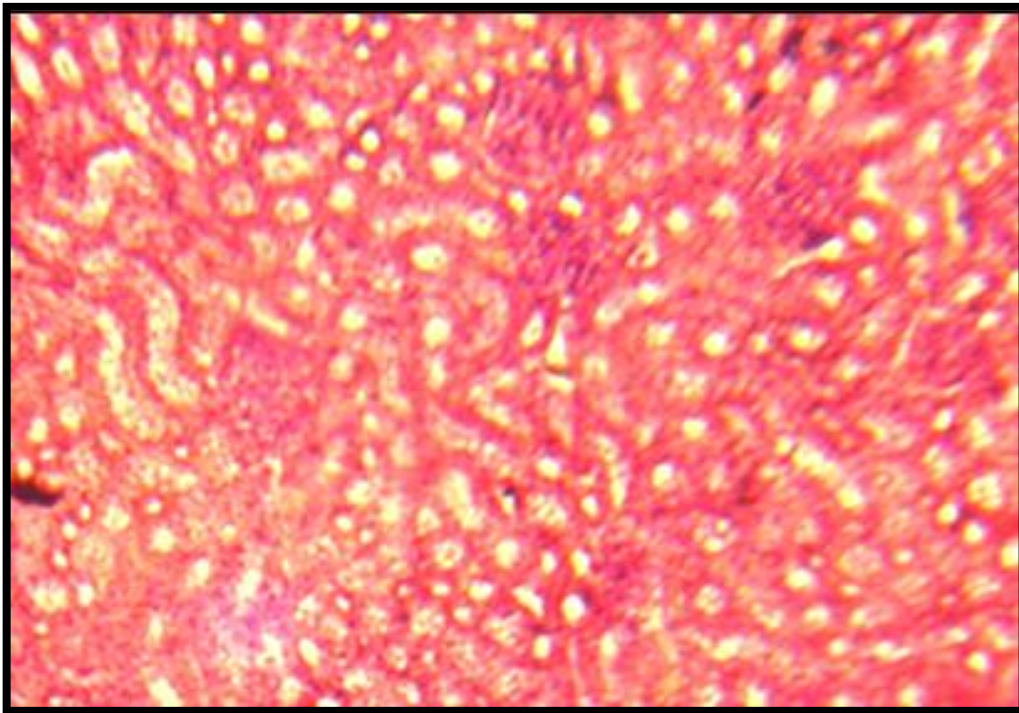


**Figure 1 A** - Section of kidney from the control group, x 100 (H&E).



**Figure 1 B** - section of kidney from **(T2a)**group, x 100 (H&E).

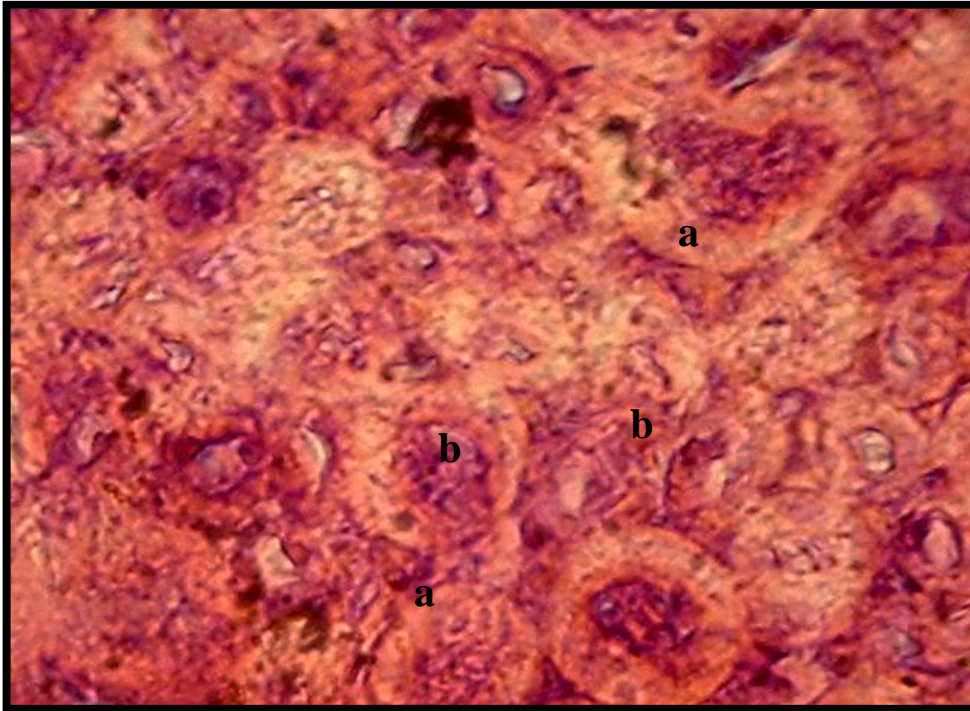
- a - prominent disruption of the cuboidal cells.
- b - Undefined epithelial cell lining.
- c - Clumping of nuclei (formation of giant-like cells).
- d - Interstitial hemorrhage.



**Figure 1 C** - section of kidney from **T1** group, x 100 (H&E).

- a - The cuboidal shaped cell has been slightly disrupted with less defined epithelial cell lining.
- b - Increased intracellular space or lumen.



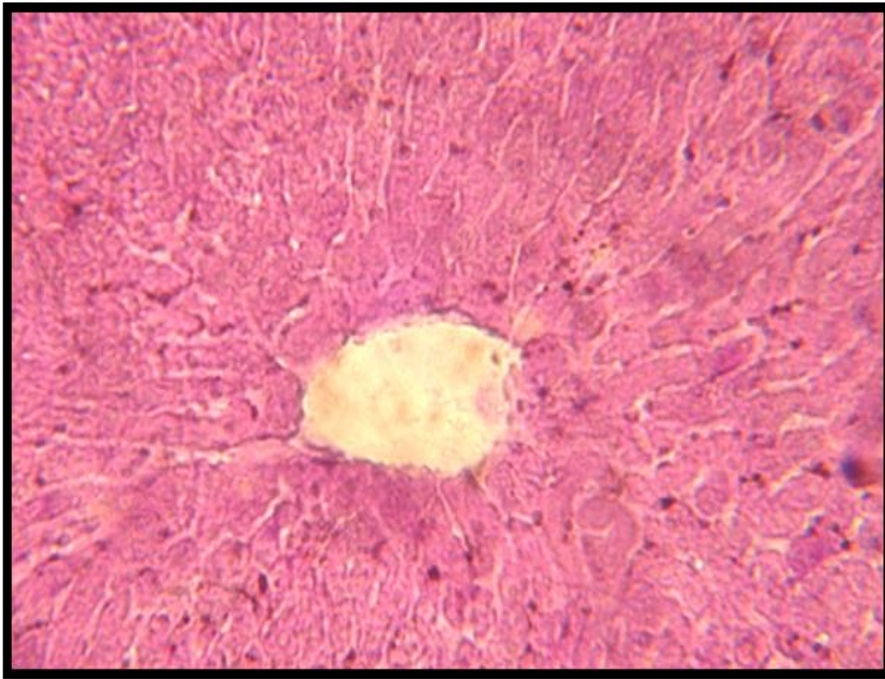


**Figure 1 D** - section of kidney from (T2b) group, x 100 (H&E).

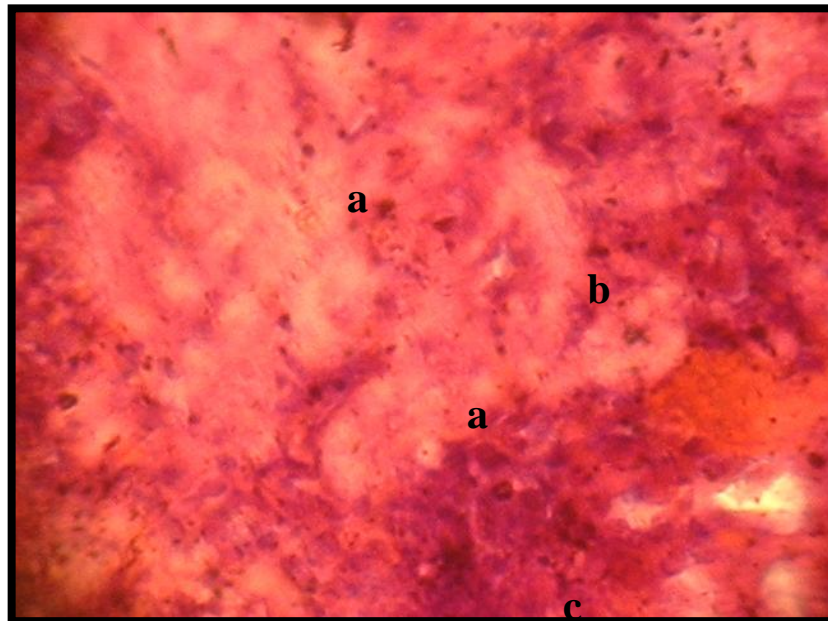
a – Slightly disrupted cuboidal shaped cells and less defined epithelial cell lining.

b – Widely spread fibrosis.



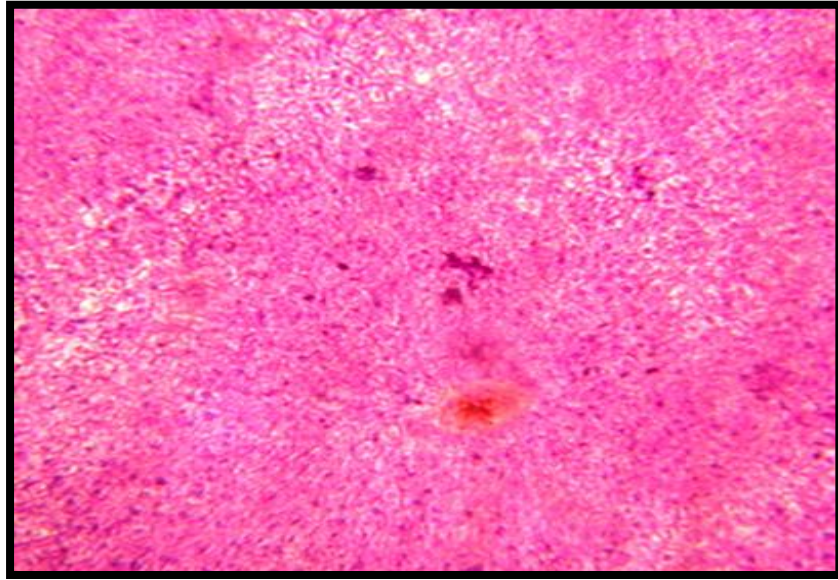


**Figure 2 A - section of liver from control group x 100, (H &E).**



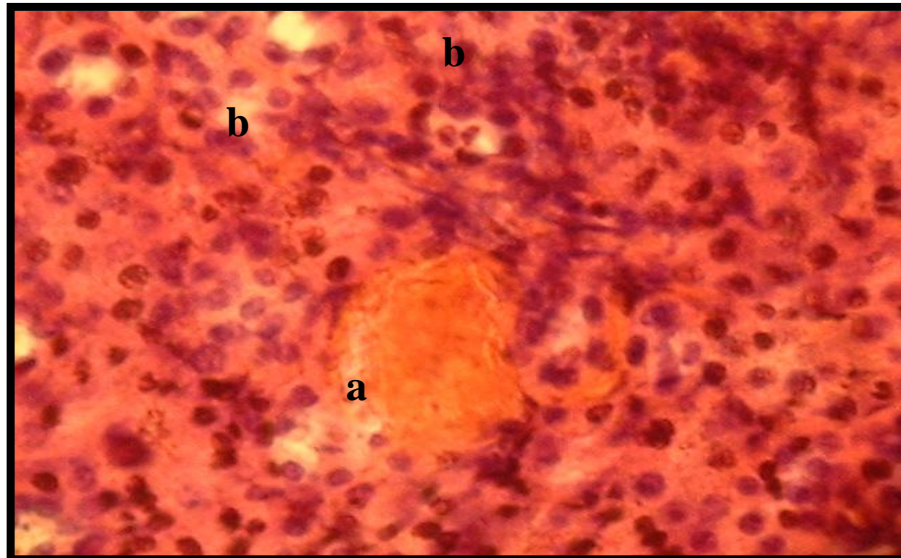
**Figure 2 B - section of liver from (T2a) lead acetates treated group.**

- a - More prominent distortion of polyhedral hepatocytes with undefined cell lining.
- b - Massive cytoplasm enlarged nuclei.
- c – Vacuolated hepatocyte.



**Figure 2 C - Section of liver from T1 group x 100, (H &E).**

- a - The presence of abnormal hepatocytes with a distorted shape and undefined cell lining.
- b – Vacuolation.



**Figure 2 D - Section of liver from (T2b) group x 100, (H &E).**

- a – Abnormal distorted hepatocytes with undefined cell linings.
- b – Vacuolation of the hepatic cells.

## تأثير التعرض الحاد لخلات الرصاص على التركيب النسيجي لكبد وكلية الفئران المختبرية ( *Mus musculus* ) ودور فيتامين C كعامل اصلاح.

وسام ساجد هاشم العبودي<sup>1</sup>؛ اشراق جاسم حسن<sup>2</sup>؛ محمد علي الديوان<sup>3</sup>

فرع الفلسفة، كلية الطب، جامعة المثنى، المثنى، العراق.  
فرع الفلسفة، كلية الطب، جامعة ميسان، ميسان، العراق .  
فرع الفلسفة، كلية الطب البيطري، جامعة البصرة، البصرة، العراق.

### الخلاصة

ان الغرض من هذه الدراسة هو لبيان التأثير المدمر للرصاص على انسجة الكبد والكلية للفئران المختبرية وبيان قدرة الفيتامين C على اصلاح التلف الناتج من التعرض للرصاص. ففي هذه الدراسة، تم استخدام 40 ذكرا من الفئران المختبرية وقسمت الى ثلاثة مجاميع كالاتي: مجموعة السيطرة والتي تتكون من 16 فارا حققت في التجويف البريتوني ب(0,9 % محلول فسلجي طبيعي) لمدة 15 يوما ثم تم قتل 8 فئران منها لاجراء الفحص النسيجي والثمانية المتبقية حققت ب(0,9 % محلول فسلجي طبيعي) لمدة 15 يوما اضافية ثم تم قتلها لاجراء الفحص النسيجي اللازم ؛ مجموعة المعاملة الاولى (T1 group) والتي تكونت من 8 فئران فقط، تم حقنها في التجويف البريتوني بخلات الرصاص ( 80 ملغم \ كغم ) ومن ثم بفيتامين C ( 400ملغم \ كغم ) بعد ساعة واحدة من حقنها بخلات الرصاص لمدة 15 يوما يوميا ومن ثم تم قتلها؛ مجموعة المعاملة الثانية (T2 group) والتي تكونت من 16 فارا، تم حقنها بخلات الرصاص ( 80 ملغم \ كغم ) لمدة 15 يوما يوميا ثم تم قتل 8 فئران منها لاجراء الفحص النسيجي اللازم وسميت هذه المجموعة ب(T2 a) و( T2 b) والثمانية فئران المتبقية منها تم حقنها بفيتامين C ( 400ملغم \ كغم ) لمدة 15 يوما اضافية ثم تم قتلها لاجراء الفحص النسيجي اللازم وسميت هذه المجموعة ب(T2 b).

اظهرت الدراسة النسيجية للكلية في المجاميع المعاملة بخلات الرصاص عدم وضوح الخلايا الطلائية المبطنة للنبيبات الكلوية مع وجود خلايا تشبه الخلايا العملاقة، وعندما استعمل فيتامين C فانه قلل التلف الكلوي الناتج من الرصاص حيث ظهرت الخلايا الطلائية المكعبة في النبيبات الكلوية مع تهتك في خلايا البطانة وزيادة في الفراغات بين الخلوية.

اما انسجة الكبد في المجاميع المعاملة بخلات الرصاص فقد ظهرت فيها خلايا كبديّة غير طبيعية ذات اشكال مشوهة مع عدم وضوح الخلايا الطلائية بالاضافة الى تضخم الانوية وتفجّي الخلايا الكبديّة.

ان حدوث التغيرات وشدها في الخلايا الكبديّة كانت اقل في المجاميع التي عوملت بفيتامين C. فقد كان تأثير الفيتامين متماثلا في حالة استخدامه بعد ساعة واحدة من حقن خلّات الرصاص او لمدة 15 يوما اضافية بعد حقن خلّات الرصاص.

فنتنتج مما سبق بان الرصاص يسبب تغيرات نسيجية واضحة في انسجة الكبد والكلية للفئران المختبرية، وان التعرض الحاد للرصاص ذو تأثير سام يؤدي الى العديد من الحالات المرضية كالاغتيال في الوظائف الكلوية والكبدية والسرطانات.

## REFERENCES

1. Akesson, A., Bjellerup, P., Lundh, T., Lidfeldt, J., Nerbrand, C., Samsioe, G., Skerfving, S., & Vahter, M. (2006). Cadmium-induced effects on bone in a population-based study of women. *Environ. Health Perspect.*, 114: 830–834.
2. Aurand, L. W. and Woods, A. E. (1973). *Food chemistry*. 1<sup>st</sup> ed. Westport, connecticut. The A VI puplishing company, INC., Pp: 287.
3. Bernard, A. (2004). Renal dysfunction induced by cadmium: biomarkers of critical effects, *Biometals.*, 17: 519–523.
4. Carr, A.C. and Frei, B. (1991) . Towards a new recommended dietary allowance for vitamin C based on antioxidant and health effects in humans . *Am J Path .*, 18:499 .
5. Dudley, R.E., Gammal, R.M., & Klaassen, C.D. (1990). Cadmium-induced hepatic and renal injury in chronically exposed rats: likely role of hepatic cadmium-metallothionein in nephrotoxicity. *Toxicol Appl Pharmacol.*, 77: 414–426.
6. Englard, S. and Seifter, S. (1986). The biological functions of ascorbic acid. *Ann Rev Nutr .*, 6: 365-406.
7. Gubrelay, U., Mehta,A., Singh, M., & Flora, S.J. (2004). Comparative hepatic and renal toxicity of cadmium in male and female rats. *J. Environ. Biol.*, 25: 65–73.
8. Henson, D.E.; Block, G. and Levine, M. (1991) . Ascorbic acid : biological functions and relation to cancer . *J Nat Cancer Ins .*, 83: 547-550 .
9. Hibiya, T. (1992). An Atlas of Fish Histology: Normal and Pathological Features, *J Toxicol Environ Health.*, 21: 82–90.
10. Jarup.,L. (2003). Hazards of heavy metal contamination. *Br. Med. Bull.*, 68: 167–182.
11. Kaur, J., Sharma,N., Attri, S., Gogia, L., and Prasad, R. (2006). Kinetic characterization of Zinc transport process and its inhibition by Cadmium in isolated rat renal basolateral membrane vesicles: in vitro and in vivo studies, *Mol. Cell. Biochem.*, 283: 169–179.
12. Klaassen, C.D., Liu, J., and Choudhuri, S. (1999). Metallothionein: an intracellular protein to protect against cadmium toxicity. *Annu Rev Pharmacol Toxicol.*, 39: 267–294.

13. Luna, L.G., (1968). Manual of histology staining method of the armed forces. Institute of pathology. 3<sup>rd</sup> ed. M.H. GrawHill Book CO., USA, pp. 258.
14. Samir, H., Najla, H., Mohamed, F. N., Abdelhamid, E., and Rachid S. (2007). Accumulation of cadmium and its effects on liver and kidney functions in rats given diet containing cadmium-polluted radish bulb. *Experimental and Toxicologic.*, 59: 77-80.
15. Sandy, T., Ivo, L., John, M., and Emmy, V.K. (2007). Changes in expression of fibrotic markers and histopathological alterations in kidneys of mice chronically exposed to low and high Cd doses. *Toxicology.*, 238: 200-210.
16. Sudo, J., Hayashi, T., Kimura, S., Kakuno, K., Terui, J., and Takashima, K. (1996). Mechanism of nephrotoxicity induced by repeated administration of cadmium chloride in rats. *J Toxicol Environ Health.*, 48: 333–348.
17. Tsukahara, T., Ezaki, T., Moriguchi, J., Furuki, K., Shimbo, S., Matsuda-Inoguchi, N., and Ikeda, M. (2003). Rice as the most influential source of cadmium intake among general Japanese population, *Sci Total Environ.*, 305: 41–51.