

Effect of cottonseed oil on reproduction performance of male mice.

*Inaam Noori Ali**

*Sabah A.R.Al-Obaidi***

*Mohammad Baqir M-R. Fakhrildin****

Received 3, January, 2010

Accepted 26, October, 2010

Abstract:

Oil extract of cottonseed was orally administered to male mice at doses 0%, 20% and 40% daily for 6 weeks to study their effects on male reproduction performance. The results showed that testicular weight was significantly ($P<0.05$) decrease, highly significant ($P<0.01$) decrease in the diameters of seminiferous and epididymal tubules and thickness of proliferated of spermatogenic and epithelial cells layers were revealed highly significant ($P<0.01$) decrease as compared to the control. Administration 20% and 40% cottonseed oil to male mice for 6 weeks caused a significant ($P<0.05$) and highly significant ($P<0.01$) decrease respectively in serum testosterone concentration as compared to the control. Dose 20% oil caused significant ($P<0.05$) reduction in the level of serum FSH and LH, while 40% oil caused highly significant ($P<0.01$) decrease in the level of serum FSH and LH. Finally, cottonseed oil caused histological changes in the testicular tissues which comprise different grades of degenerations in the spermatogenic layers, large numbers of germ cells were detached and sloughed in the lumen and absence of sperms from some of seminiferous tubules in addition to widening of interstitial spaces due to presence of edema and congestion of blood vessels. Objective of the present study was to knowledge the effect of cottonseed oil on male reproduction performance of mice which comprise different parameters such as measurement of reproductive organs weight, diameters of seminiferous and epididymal tubules, reproductive hormones and histological changes.

Key words: male mice, reproductive hormones, reproductive histopathological changes, cottonseed oil

Introduction:

Cottonseed oil has a mild, nut like taste. It is generally clear with a light golden color, but like most oils, the degree of color depends on the amount of refining [1]. Refined and deodorized cottonseed oil is one of the purest available food products. Unlike some oils, it does not revert rapidly in flavor when used at high temperatures [2]. Gossypol is a pigment found in cottonseed oil, the levels of most of cottonseed pigments are reduced during the normal processing of oils to

give them acceptable color, flavor and stability [3,4]. Cottonseed also contains another pigment, gossyverdurine which is more toxic than gossypol and may be responsible for the finding that signs of cottonseed toxicosis in the feed [3]. Gossypol has been used by fertile men in China as an effective male contraceptive agent for many years. The antifertility responses are both dose and time dependent [5]. Study of [6] indicated that the fertilizing ability of bull spermatozoa

*Studies and Researches Centre/Water Treatment Technology Institute/ Ministry of Science and Technology.

** Department of Biology/ College of Science for Women/ University of Baghdad.

*** Department of Clinical Physiology/ Institute of Embryo Research and Infertility Treatment/ Al-Nahrain

can be inhibited by the excessive consumption of diets containing cottonseed. Also, Results of [7] showed that the testis is the target organ of gossypol with the thickness of tunica albuginea, cluster of spermatogenic cells and reduction in the number of spermatozoa. The processes of sperm production and maturation are regulated by integrated endocrine control. Study of [8] showed that gossypol impaired the spermatogenesis through inhibition of steroidogenesis. Secretion of testosterone was decreased by effect of gossypol, which was attributed to the inhibition of adrenergic receptor in the hypothalamus, this inhibition might decrease gonadotropins releasing hormone (GnRH) and leads to decrease of LH- testosterone [9].

Materials and Methods:

1. Animals:

Healthy mature male mice of Swiss albino strain at an age (7-8) weeks were obtained from the animal house at the Institute of Embryo Research and Infertility Treatment/ Al-Nahrain University. Sixty mature male mice weighing (24 ± 1 g) were housed in plastic cages measuring about (29x15x12) cm. Floors of cages were covered with soft crushed wood shaving; all cages were washed two times per week with 70% alcohol throughout the period of the study.

2. Preparation of cottonseed oil and experimental design:

Fifty grams of the dry powder of cottonseed were dissolved in 700 mL of 95% of hexane alcohol by using soxhlet apparatus for 7-8 hrs. Then the solution was evaporated in a rotary evaporator under a reduced pressure at 60 °C. The oil was collected, put in glass containers and stored at 4 °C until used in the study [10]. In the present work, sixty male

mice were divided into 3 major groups (20 ♂/ group) depending on different doses of cottonseed oil (0%, 20% and 40%). The period of the experiment was unified for each major group during 6 weeks. Orally route of administration was used for treatment with cottonseed oil. Each major group was subdivided into four minor groups (5 ♂/ group) distributed according to the type of test (5 ♂ mice for FSH, 5 ♂ mice for LH, 5 ♂ for testosterone and 5 ♂ mice for histopathological study).

3. Body weight and reproductive organs weight:

At the end of treatment, animals were weighed, using a mechanical balance, anesthetized by exposure to amount of diethyl ether, and reproductive organs (testes and epididymes) were obtained and weighed by sensitive electric balance after being cleaned from the accessory connective and adipose tissues. Organ weight was calculated as in the following equation: **Organ weight to body weight ratio = Organ wt (mg) / Body wt (g).**

4. Collection of blood for hormonal assay:

Blood samples were drawn directly by cardiac puncture using 2 mL syringes, and then serum for hormonal assay was obtained by centrifugation of the collected blood samples for about 10 minutes at 2500 rpm and kept at -4 °C until time of the analysis [11]. Then the reproductive hormones (FSH, ICSH) and testosterone were assayed by using prepared kits (Immunotech Company, France) through Radio immuno assay (RIA) technique: LH and FSH values were measured by mIU / mL, while testosterone, values were measured by Pg / mL.

5. Histological sections:

At the end of treatment, reproductive organs (testes and epididymes) were excised and cleared

off from the attached debris (fat and connective tissue). Histological sections were prepared according to [12] for histological changes. The diameters were measured by using ocular and stage micrometer at power 40. Vertical and horizontal diameters of round seminiferous tubules were measured and means were taken. For each animal, 20 seminiferous tubules diameters were measured [13]. Also, the thickness was measured by using ocular and stage micrometer at power 40. For each animal, 20 seminiferous and epididymal tubules were measured [14].

6. Statistical analysis:

Means and standard error of mean were determined using descriptive statistical methods. The data were statistically analyzed by analysis of variance (ANOVA) to compare among different means of groups using special statistical computerized package SPSS (statistical Package of Social Science version 14) [15].

Results:

In the present work, testicular weight was significantly ($P<0.05$) decrease as compared to the control (Table 1). The diameters of seminiferous and epididymal tubules were highly significant ($P<0.01$) decrease when compared with the control (Table 2 and 3). Also, thickness of proliferated of spermatogenic cells layers and epithelial cells layers were highly significant ($P<0.01$) decrease as compared to the control (Tables 2 and 3).

In this study, administration 20% and 40% cottonseed oil to male mice for 6 weeks caused significant ($P<0.05$) and highly significant ($P<0.01$) decrease respectively in serum testosterone concentration as compared to the control (Figure 1).

Dose 20% oil caused significant ($P<0.05$) reduction in serum FSH and LH concentration as compared to the control (Figures 2 and 3). However, administration 40% oil to male mice for 6 weeks caused highly significant ($P<0.01$) decrease in serum FSH and LH concentrations (Figures 2 and 3).

Microscopical examination of testicular tissues from control mice showed normal cytoarchitecture and maturation of germinal epithelium (Figure 4). Testicular tissue of mice administered oil extract of cottonseed (20%/♂/day) showed different grades of degenerations in the spermatogenic layers. Some cells were completely degenerated and others were partly affected, in addition to large numbers of germ cells were detached and sloughed in the lumen and absence of sperms from some of seminiferous tubules (Figure 5). While, administration 40% oil extract of cottonseed caused degeneration in the seminiferous tubule, reduction in the diameter of seminiferous tubule and destruction of Leydig cells (Figure 6). Also, other changes include widening of interstitial spaces due to presence of edema was seen and congestion of blood vessels.

Table (1): Weight of body and reproductive organs of male mice received two concentrations of oil extract of cottonseeds for six weeks period.

Groups Weight	G1 (Control)	Oil extract	
		G2 (20% oil)	G3 (40% oil)
Body (g)	25.80±0.31 ^a	25.44±0.33 ^a	25.22±0.32 ^a
Testes (mg/g b.wt)	6.45 ±0.23 ^a	6.12± 0.20 ^{ab}	5.87± 0.17 ^b
Epididymes (mg/g b.wt)	2.80 ±0.12 ^a	2.78 ± 0.11 ^a	2.62 ± 0.12 ^a

Each value represents mean ± S.E. Means having different letters at the same row are significantly ($P<0.05$) different.

Table (2): Diameters of the seminiferous tubules and thickness of proliferated spermatogenic cells for male mice received two concentrations of oily extract of cottonseeds for six weeks period.

Groups Parameters	G1 (control)	Oil extract	
		G2 (20% /♂)	G3 (40% /♂)
Diameter of the seminiferous tubule (μ)	180.68±2.60 a	171.31±1.37 b*	164.24±2.33 c*
Thickness of proliferated spermatogenic cells (μ)	55.58±1.27 a	44.65±1.15 b*	43.78±1.41 b*

Each value represents mean ± S.E.Means having different letters at the same row are significantly (P<0.05) different. Means having different letters with * are highly significant (P<0.01) difference with control

Table (3): Diameters of the epididymal tubules and thickness of epithelial cells layer for male mice received two concentrations of oily extract of cottonseeds for six weeks.

Groups Parameters	G1 (Control)	Oil extract	
		G2 (20% /♂)	G3 (40% /♂)
Diameter of the epididymal tubule (μ)	124.80±1.71 a	115.26±2.85 b*	104.42±1.04 c*
Thickness of epithelial cells layer (μ)	26.37±0.92 a	22.85±0.58 b*	20.56±0.77 c*

Each value represents mean ± S.E.Means having different letters at the same row are significantly (P<0.05) different. Means having different letters with * are highly significant (P<0.01) difference with control

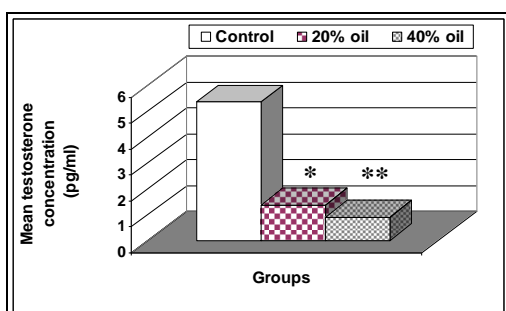


Fig. (1): Effect of oily extract of cottonseed on level of serum testosterone concentration of mature male mice.

Each value represents mean ± S.E.
 * Significantly (P< 0.05) different as compared to control group.
 ** Highly significant (P< 0.01) difference as compared to the control.

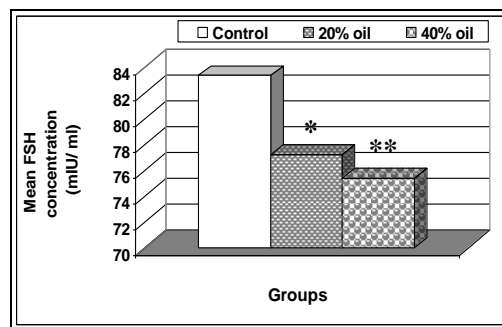


Fig. (2): Effect of oily extract of cottonseed on level of serum FSH of mature male mice.

Each value represents mean ± S.E.
 * Significantly (P< 0.05) different as compared to control.
 ** Highly Significant (P<0.01) difference as compared to control

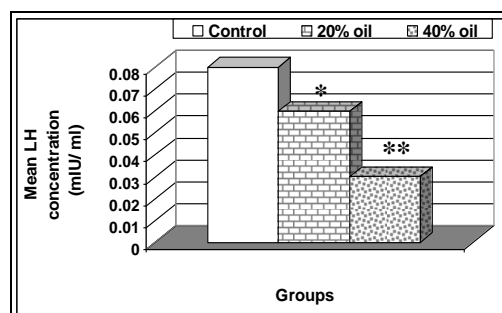


Fig. (3): Effect of oily extract of cottonseed on levels of serum LH of mature male mice.

Each value represents mean ± S.E.
 * Significant (P< 0.05) difference as compared to control group.
 ** Highly Significant (P<0.01) difference as compared to control

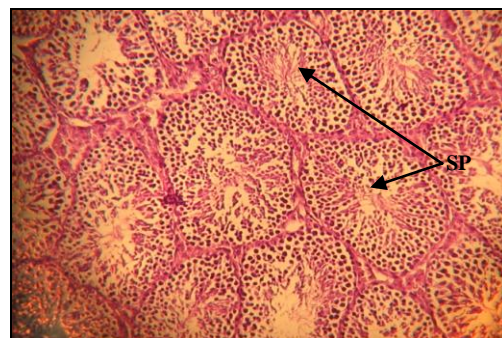

Fig. (4) Cross section of testicular tissue from the control group of mice, shows normal structure appearance of seminiferous tubules with presence of sperms inside the lumen (SP). (H &E 200 X).

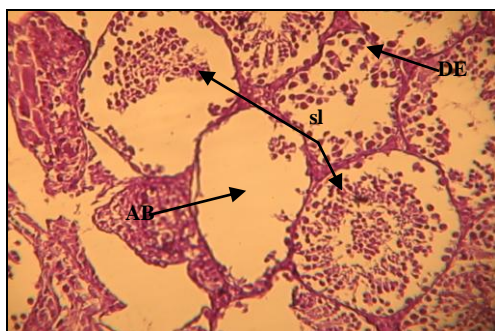


Fig. (5) Cross section of testicular tissue from mice treated with 20 %/♂/day oil extract of cottonseed shows extensive degeneration (DE), sloughing of spermatogenic cells (SL) and absence of sperms from several of seminiferous tubules (AB) (H & E 200X).

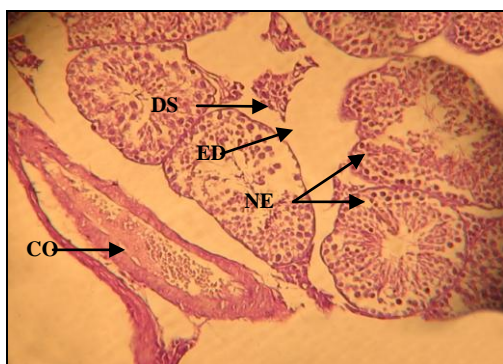


Fig. (6) Cross section of testicular tissue from mice treated with 40 % /♂/day oil extract of cottonseed shows necrosis (NE), edema (ED), congestion (CO) and destruction of Leydig cell (DS) (H & E 200X).

Discussion:

The results in this work appeared non significant decrease in the weight of body and epididymes among G2 and G3 as compared to the control. The significant decrease in the weight of testes of the treated mice may be attributed to the positive relationship between the decrease in testicular weight and the decrease in body weight [16]. The reduction in testicular weight may be attributed to an impairment of germ cell multiplication that normally stimulated by FSH and testosterone [17]. Also, the reduction of reproductive organs weight may be explained to the degeneration of spermatogenic cell, shrinkage of seminiferous and

epididymal tubule with absence of sperms in the lumen [18].

In this study, the histological preparations of testes and epididymes were showed significant reduction in the diameter of seminiferous and epididymal tubules as compared with the control group, also there were a significant reduction in the thickness and height of the epithelial lining cells of seminiferous tubules and epididymes, respectively. The reduction in seminiferous tubular diameter may reflect the tubular shrinkage, which may be due to spermatogenic cell death or sloughing of epithelial cells [19]. Another explanation of that reduction was due to diffusion of edematous fluid among semeniferous tubules leading to shrinkage of them. Result of [20] showed that bulls receiving cottonseed or cottonseed meal exhibited large lumen diameters of seminiferous tubules with reducing in their wall thickness. The reduction in diameter of seminiferous tubules was assessed to the reduction of testosterone level. Since testosterone has an important role in the development and growth of male reproductive ductus and epithelial cells of seminiferous tubules in vertebrates [21]. However, that the epididymis is an androgen dependent organ, and in the absence of androgen, a dramatic decrease occurs in the size of tubules and epithelium layers of epididymis [22; 23].

The presence of blood vessels congestion as shown in the present study may be due to the destruction of cell membranes of blood vessels which lead to increment the infiltration of blood cells from the blood vessels to the interstitial tissues of the testis [24]. While, the presence of cell debris in the lumen of the epididymal lumen is a reflection of degenerating testicular lesion observed in the treated mice which was passed to the epididymes

via the ductuli efferent [25]. Furthermore, there was reduction in the number of spermatozoa and an increase in the area of Leydig cells of mice treated with gossypol for 3 weeks [7; 26].

References:

- 1- Tyler, V.E.; Brady, L.R. and Robber, J.E. 1988. Pharmacognosy. 9th ed. Indian Edition, K.M. Varghese Company. Pp: 426-493; 67-68.
- 2- Australia Newzealand Food Standard (ANZFS) 2003. Food derived from bromoxynil-Tolerant cotton transformation events 10211 and 10222. A safety assessment technical report series No. 17 (www.foodstandards.gov.au).
- 3- Burlatschenko, S. 2003. Suspected gossypol toxicos in a sow herd. Swine health. prod. 11(3): 137-139.
- 4- Strayer, D. 2006. Food fats and oils. Institute of shortening and edible oils. 9th ed. 1750 New York. Avenue, Washington, DC.
- 5- Brueggemeier, R.W. 2003. Male sex hormones, analogs and antagonists. In: Burger's Medicinal Chemistry and Drug Discovery. Abraham, D. (ed.). Vol.3. 6th ed. John Wiley and Sons, New York. Pp: 674-746.
- 6- Tanyildizi, S. and Bozkurt, T. 2004. In vitro effects of Linamarin, Amygdalin and gossypol acetic acid on hyaluronidase activity, sperm motility and morphological abnormality in bull sperm. Turk. J. Vet. Anim. Sci. 28: 819-824.
- 7- Amini, A. and Kamkar, F. 2005. The effects of gossypol on spermatogenesis in NMRI mice. Iran. J. Sci. and Technol. Trans. 29(A1): 123-133.
- 8- Nair, I.N. and Bhiwgade, D.A. 1990. Effect of gossypol on pituitary reproductive axis: ultrastructural and biochemical studies. Indian. J. Exp. Biol. 28(8): 724-732.
- 9- Haung, H.F. and Wang, M. 1994. Effect of gossypol acetate, danazol progesterone and GnRH on estrogen and progesterone receptors of human endometrial cell. Chung. Kuo. Chung. His. I. Chieh. Ho. Tsa. Chin. 14(6): 352-353.
- 10- Chernenko, T.V.; Glustenkova, A.I. and Umarov, A.U. 1978. Extraction of cottonseed oil. Chem. Natu. Comp. 14(2): 136-138.
- 11- Al-Dujaily, S.S. 1996. In vitro sperms activation and intra-bursal insemination in mice. Ph.D. Thesis. College of Veterinary Medicine. Baghdad University.
- 12- Bancroft, J. and Stevens, A. 1982. Theory and Practice of Histological Technique. 2nd ed. Churchill Livingstone, London.
- 13- França, L.R.; Silva, V.A. Jr; Chiarini-Garcia, H.; Garcia, S.K. and Debejuk, L. 2000. Cell proliferation and hormonal changes during postnatal development of the testis in the pig. Biol. Reprod. 63: 1629 -1636.
- 14- Al-Wachi, S. and Balash, K. J. 1998. Induced alteration in spermatogenesis of mature albino mice injected with caffeine. J. Biol. Sci. Res. 19: 457-468.
- 15- SPSS. 2004. Statistical Package Social Science, Users Guide. Statistical. Version 14th ed. SPSS. Inst. Inc. Cary, N.C. USA
- 16- Murray, M. and Pizzorno, J. 1998. Encyclopedia of natural medicine. Little Brown, Quest Health Library. Pp: 135.
- 17- Haywood, M.; Spaliviero, J.; Jimenez, M.; King, N.J.C.; Handelsman, D.J. and Allan, C.M. 2003. Sertoli and germ cell development in hypogonadal (hpg) mice expressing transgenic follicle-stimulating hormone alone or in

- combination with testosterone. *Endocrinol.* 44: 509-517.
- 18- Randel, R. D.; Chase, C.C.Jr. and Wyse, S.J. 1992. Effects of gossypol and cottonseed products on reproduction of mammals. *J. Anim. Sci.* 70. 1628.
- 19- Gol'dberg, E.D.; Borovskaia, T.G.; Timina, E.A.; Fomina, T.I.; Gol'dberg, V.E. 1997. Spermatogenesis in rats after administration of the antineoplastic agent vepsid. *Bull. Eksp. Biol. Med.* 124(12): 645-648.
- 20- Chase, C.C. Jr.; Bastidas, P.; Ruttle, J.L.; Long, C.R. and Randel, R.D. 1994. Growth and reproductive development in braham bulls fed diets containing gossypol. *J. Anima. Sci.* 72: 445-450.
- 21- Guillette, L. J.; Pickford, D. B.; Crain, D. A.; Rooney, A. A. and Percival, H. F. 1996. Reduction in penis size and plasma testosterone concentration in Juvenile Alligators living in a contaminated environment. *Gene. Compa. Endocrinol.* 101: 32-42.
- 22- Krishnamurthy, H.; Kats, R.; Danilovich, N.; Javeshghani, D.; Sairam, M.R. 2001. Intercellular communication between Sertoli cells and Leydig cells in the absence of follicle-stimulating hormone-receptor signaling. *Biol. Reprod.* 65:1201-1207.
- 23- Grover, A.; Smith, C.E.; Gregory, M.; Cyr, D.G.; Sairam, M. R.; and Hermo, L. 2005. Effects of FSH receptor deletion on epididymal tubules and sperm morphology, numbers, and motility. *Mol. Reprod and Develop.* 72: 135-144.
- 24- Al-Khafaji, I.N.A. 2000. Effect of lead acetate on the reproductive system of adult male mice borne to mothers treated during pregnancy. M.Sc. thesis. College of Science. Al- Mustansiriya University.
- 25- Akinloye, A. K.; Abatan, M.O; Alaka, O. O and 'Oke, B. O. 2002. Histomorphometric and histopathological studies on the effect of Calotropis Procera (giant milkweed) on the male reproductive organs of wistar rats. *Afr. J. Biomed. Res.* 5: 57- 61.
- 26- Farrag, A.K.; Ismail, H.I.H.; Khalifa, E.A. and El- Gamal, M.M. 2007 The possible synergistic effect of gossypol (cottonseed oil) and Schistosomiasis mansoni on the male reproductive organs in experimenting infected mice. *Tanta Medical Sci. J.* 2(1): 78-91.

تأثير زيت بذور القطن على الاداء التناسلي لذكور الفئران البيض

انعام نوري علي* صباح عبد الرضا العبيدي** محمد باقر محمد رشاد***

*مركز البحوث والدراسات / وزارة العلوم والتكنولوجيا
** قسم علوم الحياة/ كلية العلوم للبنات /جامعة بغداد
*** معهد العقم لباحث الاجنة وعلاج العقم/جامعة النهريين

الخلاصة:

جرعت ذكور الفئران البيض فمويا بزيت بذور القطن وبتركيز 0% و20% و40% ولمدة ستة اسابيع يوميا لدراسة تأثيراته على الاداء التناسلي. اظهرت النتائج حصول انخفاض معنوي في وزن الخصى مقارنة مع السيطرة. سجلت ابعاد النبيبات المنوية والبربخية نقصان عالي المعنوية مقارنة مع السيطرة. كذلك سمك طبقات الخلايا الجرثومية والخلايا الطلائية اظهرت نقصان عالي المعنوية مقارنة مع السيطرة. اعطاء جرعة 20% و 40% من زيت بذور القطن لذكور الفئران ولمدة ستة اسابيع سببت نقصان معنوي وعالي المعنوية بصورة متتابعة في تركيز الشحمون الخصوي مقارنة مع السيطرة. سببت جرعة 20% من زيت بذور القطن نقصان معنوي فس مستوى الهرمون اللوتيني والهرمون المحفز لنمو الجريبات بصورة متتابعة بينما سببت جرعة 40% نقصان عالي المعنوية في مستوى هذين الهرمونين. اخيرا سبب زيت بذور القطن تغييرات نسجية في نسيج الخصية متمثلة بدرجات مختلفة من الانحلال للطبقات الجرثومية وانفصال وانسلاخ اعداد كبيرة من الخلايا الجرثومية وسقوطها في تجويف النبيبات المنوية وفقدان السبيرمات من بعض النبيبات بالإضافة الى توسع المسافات البينية بسبب الودمة واحتقان الاوعية الدموية. هدفت الدراسة الحالية معرفة تأثير زيت بذور القطن على الاداء التناسلي لذكور الفئران متمثلا بمعايير مختلفة كقياس وزن الاعضاء التكاثرية وابعاد النبيبات المنوية والبربخية والهرمونات الذكورية والتغيرات النسجية.