



Histopathological assessment of nano n-acetyl cysteine effect on postoperative adhesion in rats

S. Shahzamani¹, A. Jahandideh¹, G. Abedi¹, A. Akbarzadeh², S. Hesaraki³ and P. Parsaei⁴

¹Department of Clinical Science, Faculty of Specialized Veterinary Sciences, Science and Research Branch, Islamic Azad University, ²Universal Scientific Education and Research Network (USERN), ³Department of Pathobiology, Faculty of Specialized Veterinary Sciences, Science and Research Branch, Islamic Azad University, Tabriz, ⁴Department of Food Hygiene, Faculty of Veterinary Medicine, Shahrekord Branch, Islamic Azad University, Shahrekord, Iran

Article information

Article history:

Received March 28, 2020

Accepted June 19, 2020

Available online June 28, 2021

Keywords:

Nano N-acetylcysteine

Intra-abdominal

Adhesions

Histopathology

Rat

Correspondence:

A. Jahandideh

dr.jahandideh@gmail.com

Abstract

Abdominal adhesion is one of the main and important post-surgical problems and, according to available literature, the probability of their occurrence after surgery is higher than 50%. The present study intended to estimate the effect of Nano n-acetylcysteine on macroscopic and microscopic features post-surgical adhesions in an animal model. Twenty-five adult male Wistar rats, 200-220 gr, were randomly divided into five equal groups and underwent intramuscular anesthesia by injection of ketamine 10% at 50 mg/kg and injection of xylazine 2% at 5 mg/kg. The treatments included three Nano-NAC groups at different dosages 50, 75 and 150 mg/kg, an NAC group, and a control group. On days 14 and 28 post-surgery, the abdomens of all rats were re-opened for macroscopic and microscopic evaluation of adhesions. Based on the results of macroscopic evaluation, the group receiving Nano-NAC 50 mg/kg had the lowest and the control group the highest mean adhesion scores on days 14 and 28 post-operations. Histopathological evaluation also revealed that the group treated with Nano-NAC 50 mg/kg had the lowest level of inflammation and fibrosis score among the five groups on days 14 and 28 post-operation. Considering the results obtained in our experimental model and the increasing use of nanotechnology in the manufacture of biomedical drugs, it seems that use of Nano-NAC at low doses 50 and 75mg/kg after laparotomy can significantly reduce adhesions.

DOI: [10.33899/ijvs.2020.126857.1400](https://doi.org/10.33899/ijvs.2020.126857.1400), ©2021, College of Veterinary Medicine, University of Mosul.
This is an open access article under the CC BY 4.0 license (<http://creativecommons.org/licenses/by/4.0/>).

Introduction

Abdominal adhesion is one of the common clinical and surgical problems in humans and animals. It is estimated that postoperative adhesions happen in at least 90% of all patients undergoing abdominal surgery (1). Intra-abdominal adhesions result in critical conditions including severe abdominal pain, bowel obstructions and infertility and in serious conditions such as peritonitis they can lead to septicemia and even death (2). Available documents show that about one third of the patients that have undergone

abdominal surgery require secondary surgery to remove the adhesions and More than 25% of infertility is related to pelvic or abdominal adhesions. Also, obstruction of the intestines can be the cause of 60 to 70% of all deaths and morbidity (3). Therefore, one of the problems always faced by veterinary and human surgeons is to develop a method that prevents occurrence of abdominal adhesions. Although the main mechanisms responsible for the development of adhesions still remain unclear, they may be caused by factors such as inflammation, bleeding, ischemia, surgical injuries, foreign bodies (such as talc powder and suture material),

chemical and thermal injuries, different anastomose techniques, suture methods and genetic predisposition (3). Such traumas can injure peritoneal surfaces triggering histamine release that results in vasodilatation and exudate secretion. The exudate secreted inside the abdominal cavity is the main bedding site for creating adhesions in this area. A literature review shows that numerous local or systemic effect anti-histamine and anti-inflammatory drugs including dexamethasone, aspirin, phospholipase inhibitors, dextran, corticosteroids, and heparin have been assessed for preventing postoperative adhesions. However, none of them has been satisfactory (3,4). N-acetylcysteine (NAC) is one of the most commonly used antioxidants in human and veterinary medicine. It can be used as a specific antidote for acetaminophen poisoning. It can also prevent ischemia/reperfusion injury and modify tumorigenesis (5). NAC contains a free thiol group. It was originally administered as a mucolytic agent by using a nebulizer. NAC is a precursor of L-cysteine that results in glutathione elevation biosynthesis. Therefore, it is primarily used as a classical antioxidant (5). Evaluations to determine the efficacy of NAC in preventing intra-abdominal adhesions showed that its intraperitoneal or oral administration was able to significantly reduce intra-abdominal adhesions. However, the exact dose of NAC to use is still unknown, and new technologies such as nanotechnology are not employed in its administration. Therefore, the present study evaluated the effect of Nano- NAC on reducing adhesions (6). Nanoparticles (NPs) are very tiny particles with diameter <100nm. Their function dramatically increases due to their small size and thus they can be more effective as drugs or other therapeutic agents. Also they easily disseminated to all body organs especially liver that play an important role in metabolism, excretion and detoxification (7).

Consequently, the present research utilized nanotechnology to convert NAC to nanoparticles for the first time and gross and histopathological investigations after adding Nano-NAC for reducing post-surgical adhesions in rats.

Materials and methods

This research was conducted at the Faculty of Specialized Veterinary Sciences, Science and Research Branch, Tehran, Iran, with the permission of the Ethics Committee of Islamic Azad University Science and Research Branch. All animals' welfare regulations and policies were fully complied with on the basis of the Ethics Committee Regulations and Letter No. 139605 of Islamic Azad University of Tehran.

Surgical procedure

Twenty-five male Wistar albino rats (mean age: 4 months; mean weight: 200-250g) were used. The experimental animals were randomly divided into five equal groups: the first three groups were treated with different

dosage of Nano-NAC 50 mg, Nano-NAC 75 mg, and Nano-NAC 150mg, the NAC and the control groups. The rats were left one night without food and then anesthetized by injection of ketamine 10% at 50 mg/kg and injection of xylazine 2% at 5 mg/ kg intramuscularly (8). After a ventral abdominal region was prepared aseptically a surgery technique was used at the surgical site in the midline part of the abdominal region using 2.5% povidone-iodine. A single abdominal incision 3cm in length was made on the midline. After entering the abdomen through the incision, to induce the standard adhesion in inner abdominal wall or in the serosal surface of peritoneal cavity three 2cm incisions were made on the right abdominal wall longitudinally using a surgical blade (No. 4). To ensure the inducing of abdominal adhesion several 2×2cm pieces of abdominal wall were harvested from the peritoneal cavity by using surgical scissors (8). The abdomen was then closed after the surgical procedure using monofilament absorbable 3.0 (USP) vicryl sutures (Supa, Iran) at 1cm intervals, the fascia and midline muscles were sutured with absorbable monofilament 2.0 (USP) vicryl sutures (Supa, Iran) and, finally, the skin was closed using monofilament non-absorbable 3.0 (USP) silk sutures (Supa, Iran). The anesthetized rats were placed under a heat lamp. Their body temperature was monitored regularly and maintained at 36-38°C with the aid of a thermal lamp.

Treatments

Twenty-five male rats were randomized into 5 groups of 5 and underwent primary surgical procedure. The induced peritoneal adhesions were treated using intra-peritoneal administration of Nano NAC at five different concentrations. The study groups were as follows: (A) the Nano N-acetyl cysteine (Nano-NAC) 50 mg, (B) the Nano-NAC 75 mg, (C) the Nano- NAC 150 mg, (D) the NAC, and (E) the no-treatment (control) group.

Macroscopic evaluation

On days 14 and 28 post-surgery, the abdomen was reopened and the adhesions were examined blindly by the same surgeon and the adhesion rating was determined. To compare the adhesions, the severity of each one was determined separately based on the scale in the table 1 (9).

Table 1: Score, macroscopic classification of abdominal adhesions in the rats (9)

| Score | Description |
|-------|--|
| 0 | No adhesive bands |
| 1 | One thin, non-vascular, easily removable |
| 2 | Two non-vascular, easily removable |
| 3 | Three non-vascular, easily removable |
| 4 | More than 3 non-vascular, easily removable |

Histopathological evaluation

For histopathological examination on days 14 and 28 post-operation, a sample was separated from the adhesive tissue and placed in 10% neutral buffered formalin for 2 days. The samples were prepared for histopathological investigation. Tissue sections (4µm) were routinely stained with Harri's hematoxylin and alcoholic eosin and the stained slides were examined at 100X (8,10). Adhesions were graded based on the intensity of fibrosis and inflammation according to the following scale (8) separately for each existing adhesion (Table 2).

Table 2: Histopathological criteria for grading adhesions (8)

| Score | Degree of inflammation | severity |
|-------|----------------------------------|----------|
| 0 | No inflammation | no |
| 1 | Giant, lymphocytes, plasma cells | Mild |
| 2 | Giant, plasma cells, eosinophils | Moderate |
| 3 | Inflammatory cell infiltration | Severe |

Data analysis

Data were analyzed and reported only for the rats that completed the trial. Statistical analyses were performed using GraphPad Prism version 5.00 (GraphPad Software, San Diego, CA). Severity and fibrosis and inflammation in the abdominal wall surface were reported. All values were expressed as mean+ SEM. Statistical analysis was performed using the ANOVA test, Bartlett test, and Student-Newman-Keuls test (10,11).

Results

Macroscopic assessment results: None of the rats died along the period of treatment. After the operations, all treated rats exhibited healthy. The necrotic lesions appeared on the liver surface of all the members in the Nano-NAC 150 mg and 75 mg groups are higher than those of other groups (Figures 1 and 2). Not only was the drug effective in reducing adhesions at lower doses but there were no necrotic lesions either (Figure 3). Our macroscopic assessment of adhesion severity showed that there were statistically significant differences among the five groups. Macroscopic adhesion scores on day 14 post-operation were the lowest in the Nano-NAC 50 mg group (1 in 60% and 0 in 40% of the members) (Figure 4). However, the worst scores were observed in the control group (2 in 60%, 3 in 20%, and 4 in 20% of the members) (Figure 5), indicating that there were significant differences between the control and the Nano-NAC 50 mg group ($P=0.087$). Macroscopic results on day 28 post-operation showed that the lowest adhesion score was that of the Nano-NAC 50 mg group because in none of the members was any adhesion observed, whereas the worst result and the highest adhesion scores were those of the control group in which 40% of the members received the score zero 0, 40% the score 1, and 40% the score 2. The ANOVA test revealed

that there was a significant difference between the Nano-NAC 50 mg/kg, NAC and the control on day 28 post-operation ($P=0.087$). Among the Nano-NAC groups that received different doses of the drug, the best macroscopic results belonged to the Nano-NAC 50 mg and 75 mg groups on days 14 and 28 post-operation with no statically significant differences between them. The only difference between these two groups was that necrotic lesions in the Nano-NAC 75 mg group but not in the Nano-NAC50mg group (Figures 2 and 3).

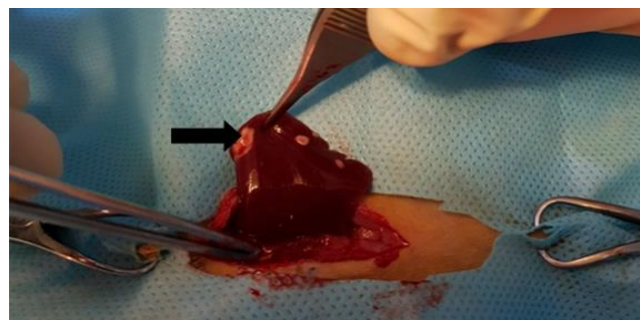


Figure 1: Macroscopic image of Nano-NAC (150 mg) group on day 14, with multiple necrotic lesions (arrow).

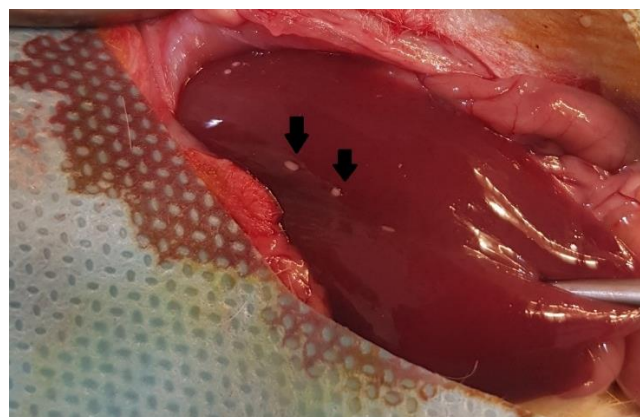


Figure 2: Macroscopic image of Nano-NAC (75 mg) group on day 14, with fewer necrotic lesions.

The results of descriptive statistics of histopathological evaluations showed that the inflammation indices on day 14 post-operation in the Nano-NAC 50 mg (mean: 0.400) and Nano-NAC 75 mg (mean: 1.200) were the lowest, whereas in the Nano-NAC 150 mg (Mean: 2.800) and in the control (mean: 2.400) groups they were the highest (Table 3).

There were also statistically significant differences between the Nano-NAC 50mg and Nano-NAC 150 groups (mean diff: 2.400) and between the Nano-NAC 50 and the control groups (mean diff: 2.000) ($P < 0:05$). In addition, on day 28 post-operation, the lowest scores belonged to the Nano-NAC 50 mg (mean: 0.0) and the Nano-NAC 75 mg

(mean: 0.6000) groups and the highest to the control group (mean: 1.800) and to the Nano-NAC 150 mg (mean: 1.800) group. In addition, there were significant differences between the Nano-NAC 50 mg and the control groups (mean diff: 1.800) and between the Nano-NAC 50 mg and the Nano-NAC 150 mg (1.800) groups (Table 4). Figure 6 presents the graph comparing the average scores for all the studied groups.

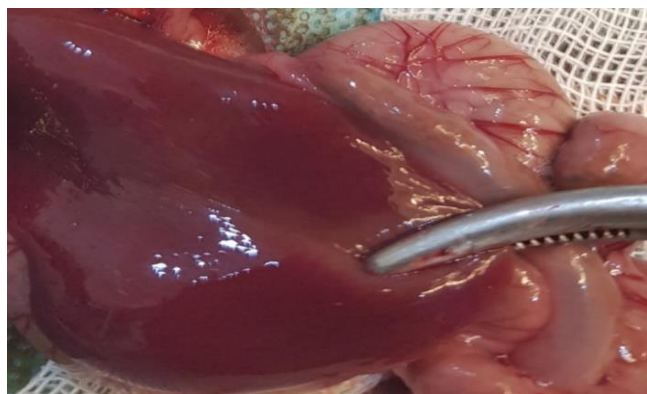


Figure 3: Macroscopic image of Nano-NAC (50 mg) group on day 14, with no necrotic lesions.

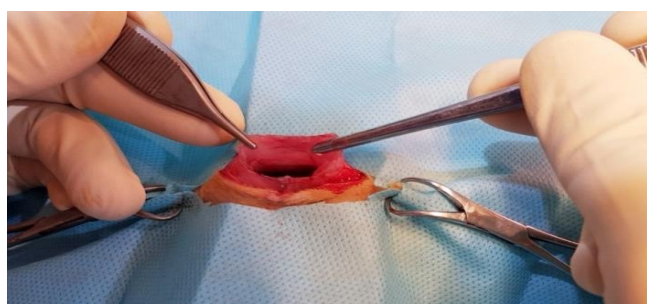


Figure 4: Macroscopic image of Nano-NAC (50 mg) group on day 14, with no adhesions.

Descriptive statistics of fibrosis index on day 14 post-operation shows that the lowest scores belonged to the Nano-NAC 50 mg (mean: 0.4000) and Nano-NAC 75 mg (mean: 1.600) groups and the highest to the control (Mean: 2.800) and Nano-NAC 150 mg (Mean: 2.200) groups (Table 5). There were significant differences between the Nano-NAC 50 mg and the control groups (mean diff: 2.400) and between the Nano-NAC 50 mg and the Nano-NAC 150 mg (1.800) (Table 5). In addition, on day 28 post-operation, the lowest scores were those of the Nano-NAC 50 mg (mean: 0.0) and the Nano-NAC 75 mg (mean: 0.6000) groups and the highest those of the control group (Mean: 2.000) and the Nano-NAC 150 mg (mean: 1.400) groups. Moreover, there were significant differences between the Nano-NAC 50 mg and the control groups (mean diff: 2.000) and between the Nano-

NAC 50 mg and the Nano-NAC 150 mg groups (1.400) (Table 6). Figure 7 presents the graph comparing the average scores for the studied groups.

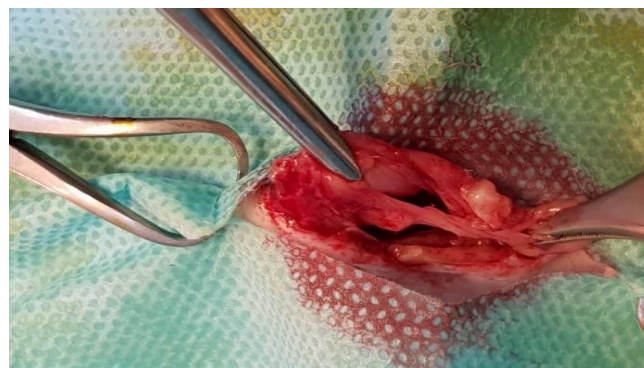

Figure 5: Macroscopic image of control group on day 14, with severe adhesions.

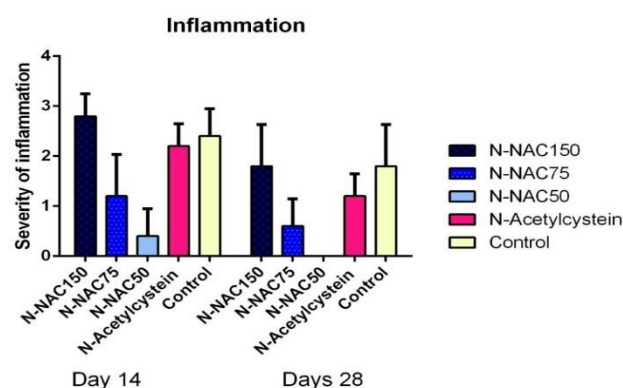


Figure 6: Graph presenting histopathological assessment according to severity of inflammation (mean statistical results) on days 14 and 28.

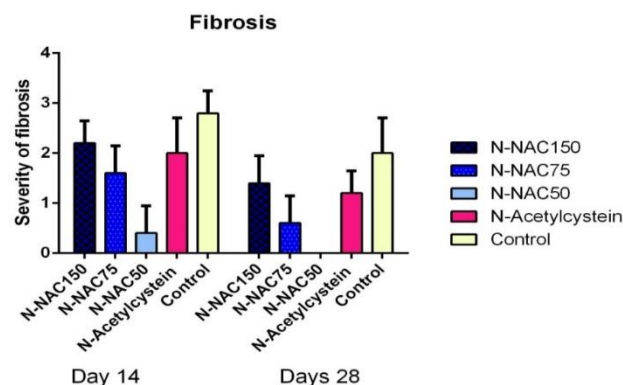


Figure 7: Graph presenting histopathological assessment according to fibrosis severity (mean statistical result) on days 14 and 28.

Table 3: Statistical comparison of inflammation indices between all groups on day 14

| Groups | Mean 1 | Mean 2 | Mean diff. | SE of diff. | N1 | N2 | Q | DF |
|------------|--------|--------|------------|-------------|----|----|--------|----|
| III vs. II | 2.800 | 1.200 | 1.600 | 0.3795 | 5 | 5 | 5.963 | 40 |
| III vs. I | 2.800 | 0.4000 | 2.400 | 0.3795 | 5 | 5 | 8.944 | 40 |
| III vs. IV | 2.800 | 2.200 | 0.6000 | 0.3795 | 5 | 5 | 2.236 | 40 |
| III vs. V | 2.800 | 2.400 | 0.4000 | 0.3795 | 5 | 5 | 1.491 | 40 |
| II vs. I | 1.200 | 0.4000 | 0.8000 | 0.3795 | 5 | 5 | 2.981 | 40 |
| II vs. IV | 1.200 | 2.200 | -1.000 | 0.3795 | 5 | 5 | 3.727 | 40 |
| II vs. V | 1.200 | 2.400 | 01.200 | 0.3795 | 5 | 5 | 4.472 | 40 |
| I vs. IV | 0.4000 | 2.200 | -1.800 | 0.3795 | 5 | 5 | 6.708 | 40 |
| I vs. V | 0.4000 | 2.400 | -2.000 | 0.3795 | 5 | 5 | 7.454 | 40 |
| IV vs. V | 2.200 | 2.400 | -0.2000 | 0.3795 | 5 | 5 | 0.7454 | 40 |

I: Nano-NAC 50 mg group. II: Nano-NAC 75 mg group. III: Nano-NAC 150 mg group. IV: N-Acetylcysteine group. V: control group.

Table 4: Statistical comparison of inflammation indices between all groups on day 28

| Groups | Mean 1 | Mean 2 | Mean diff. | SE of diff. | N1 | N2 | Q | DF |
|------------|--------|--------|------------|-------------|----|----|-------|----|
| III vs. II | 1.800 | 0.6000 | 1.200 | 0.3795 | 5 | 5 | 4.472 | 40 |
| III vs. I | 1.800 | 0.0 | 1.800 | 0.3795 | 5 | 5 | 6.708 | 40 |
| III vs. IV | 1.800 | 1.200 | 0.6000 | 0.3795 | 5 | 5 | 2.236 | 40 |
| III vs. V | 1.800 | 1.800 | 0.0 | 0.3795 | 5 | 5 | 0.0 | 40 |
| II vs. I | 0.6000 | 0.0 | 0.6000 | 0.3795 | 5 | 5 | 2.236 | 40 |
| II vs. IV | 0.6000 | 1.200 | -0.6000 | 0.3795 | 5 | 5 | 2.236 | 40 |
| II vs. V | 0.6000 | 1.800 | -1.200 | 0.3795 | 5 | 5 | 4.472 | 40 |
| I vs. IV | 0.0 | 1.200 | -1.200 | 0.3795 | 5 | 5 | 4.472 | 40 |
| I vs. V | 0.0 | 1.800 | -1.800 | 0.3795 | 5 | 5 | 6.708 | 40 |
| IV vs. V | 1.200 | 1.800 | -0.6000 | 0.3795 | 5 | 5 | 2.236 | 40 |

I: Nano-NAC 50 mg group. II: Nano-NAC 75 mg group. III: Nano-NAC 150 mg group. IV: N-Acetylcysteine group. V: control group.

Table 5: Statistical comparison of fibrosis indices between all the groups on day 14

| Groups | Mean 1 | Mean 2 | Mean diff. | SE of diff. | N1 | N2 | Q | DF |
|------------|--------|--------|------------|-------------|----|----|--------|----|
| III vs. II | 2.200 | 1.600 | 0.6000 | 0.3347 | 5 | 5 | 2.535 | 40 |
| III vs. I | 2.200 | 0.4000 | 1.800 | 0.3347 | 5 | 5 | 7.606 | 40 |
| III vs. IV | 2.200 | 2.000 | 0.2000 | 0.3347 | 5 | 5 | 0.8452 | 40 |
| III vs. V | 2.200 | 2.800 | -0.6000 | 0.3347 | 5 | 5 | 2.535 | 40 |
| II vs. I | 1.600 | 0.4000 | 1.200 | 0.3347 | 5 | 5 | 5.071 | 40 |
| II vs. IV | 1.600 | 2.000 | -0.4000 | 0.3347 | 5 | 5 | 1.690 | 40 |
| II vs. V | 1.600 | 2.800 | -1.200 | 0.3347 | 5 | 5 | 5.071 | 40 |
| I vs. IV | 0.4000 | 2.000 | -1.600 | 0.3347 | 5 | 5 | 6.761 | 40 |
| I vs. V | 0.4000 | 2.800 | -2.400 | 0.3347 | 5 | 5 | 10.14 | 40 |
| IV vs. V | 2.000 | 2.800 | -0.8000 | 0.3347 | 5 | 5 | 3.381 | 40 |

I: Nano-NAC 50 mg group. II: Nano-NAC 75 mg group. III: Nano-NAC 150 mg group. IV: N-Acetylcysteine group. V: control group.

In the microscopic sections from the abdominal wall on day 14 post-operation, the Nano-NAC 50 mg group exhibited mild fibrosis and no inflammation (Figure 8), whereas the control group showed severe inflammation, fibrosis and angiogenesis (Figure 9). In addition, on day 28 post-operation, the Nano-NAC 50 mg group showed no fibrosis, no inflammation and no angiogenesis (Figure 10),

whereas the control group exhibited severe fibrosis, moderate and severe angiogenesis (Figure 11). Severe inflammation in abdominal wall was seen in the Nano-NAC 150 on day 14 post-operation (Figure 12). Microscopic findings from the abdominal wall in the Nano-NAC 75 mg group showed the moderate inflammation, angiogenesis, and fibrosis on day 14 post-operation (Figure 13).

Table 6: Statistical comparison of fibrosis indices between all the groups on day 28

| Groups | Mean 1 | Mean 2 | Mean diff. | SE of diff. | N1 | N2 | Q | DF |
|------------|--------|--------|------------|-------------|----|----|--------|----|
| III vs. II | 1.400 | 0.6000 | 0.8000 | 0.3347 | 5 | 5 | 3.381 | 40 |
| III vs. I | 1.400 | 0.0 | 1.400 | 0.3347 | 5 | 5 | 5.916 | 40 |
| III vs. IV | 1.400 | 1.200 | 0.2000 | 0.3347 | 5 | 5 | 0.8452 | 40 |
| III vs. V | 1.400 | 2.000 | -0.6000 | 0.3347 | 5 | 5 | 2.535 | 40 |
| II vs. I | 0.6000 | 0.0 | 0.6000 | 0.3347 | 5 | 5 | 2.535 | 40 |
| II vs. IV | 0.6000 | 1.200 | -0.6000 | 0.3347 | 5 | 5 | 2.535 | 40 |
| II vs. V | 0.6000 | 2.000 | -1.400 | 0.3347 | 5 | 5 | 5.916 | 40 |
| I vs IV | 0.0 | 1.200 | -1.200 | 0.3347 | 5 | 5 | 5.071 | 40 |
| I vs. V | 0.0 | 2.000 | -2.000 | 0.3347 | 5 | 5 | 8.452 | 40 |
| IV vs. V | 1.200 | 2.000 | -0.8000 | 0.3347 | 5 | 5 | 3.381 | 40 |

I: Nano-NAC 50 mg group. II: Nano-NAC 75 mg group. III: Nano-NAC 150 mg group. IV: N-Acetylcysteine group. V: control group.

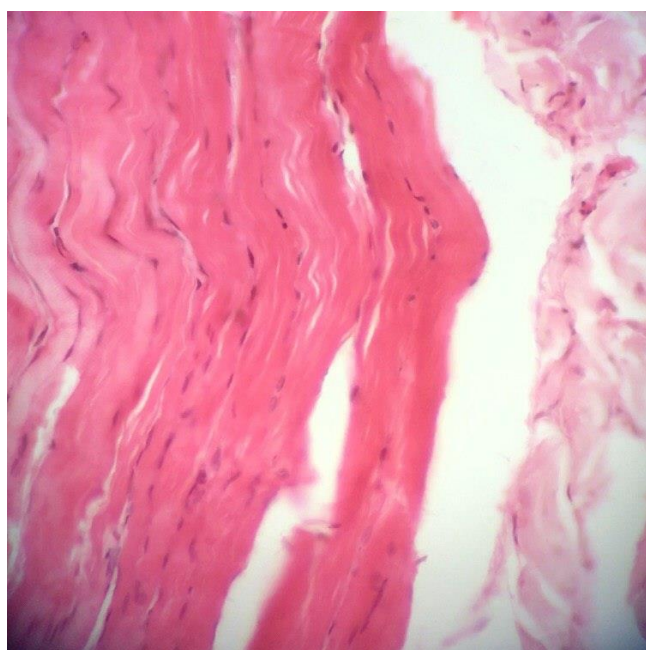

Figure 8: Microscopic section from the abdominal wall, on day 14 post-operation, in the Nano-NAC 50 mg group shows mild fibrosis and no inflammation (H&E, Staining x400).

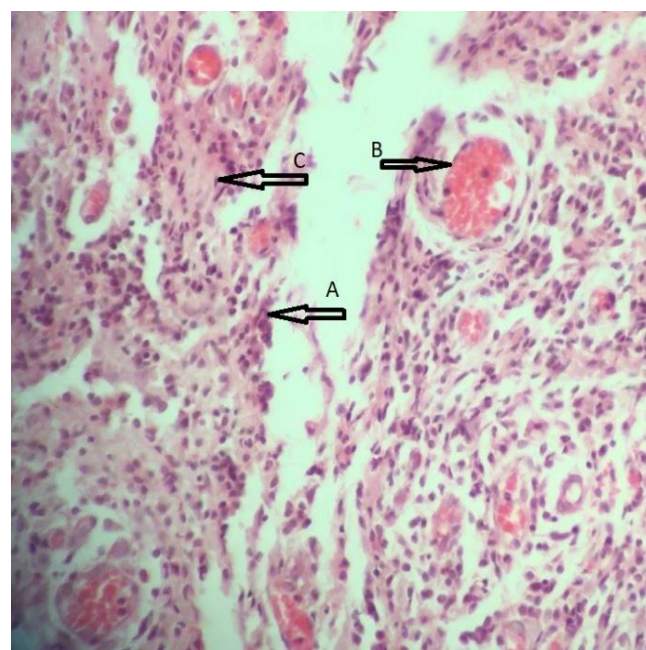


Figure 9: Microscopic section from the abdominal wall, on day 14 post-operation, in the control group shows severe inflammation (A), angiogenesis (B) and fibrosis (H&E, Staining x200).

Discussion

The primary aim of this study was to estimate the role of Nano n-acetylcysteine on macroscopic and microscopic changes post-surgical adhesions in an animal model. The obtained data from macroscopic evaluation showed that the highest and lowest mean adhesion scores were found in the control and Nano-NAC 50 mg/kg on both days 14 and 28 post-operation, respectively. Histopathological evaluation also revealed that the group treated with Nano-NAC 50 mg/kg had the lowest level of inflammation and fibrosis score on days 14 and 28 post-operation. However, gross

investigation showed that the necrotic lesions on the liver surface of all the members in the Nano-NAC 150 mg and 75 mg groups indicating toxicity of Nano-NAC at these high doses.

Postoperative peritoneal adhesions are one of the main problems after intra-abdominal surgery, lead to very serious life-threatening situations, and can also cause many problems that interfere with the normal flow through the gastrointestinal system such as severe stiffening and intestinal obstruction leading to abdominal and pelvic chronic pain (3,4,12). According to available statistics, about 60 to 90 percent of people undergoing abdominal surgery

develop intraperitoneal adhesions that often require second surgery for their removal (8). However, in recent years, many efforts have been made to prevent or treat this problem and various materials have been examined for this purpose such as glucocorticoids, heparin, dextran 70, normal saline, antibiotics, promethazine, antihistamines, antioxidants, prostaglandin synthesis inhibitor, lactated ringer's solution, calcium channel inhibitors, streptokinase as a fibrinolytic agent, rofecoxib as the inhibitor of cyclooxygenase, methyl blue, and octreotide. However, unfortunately, there is no substance that can effectively prevent peritoneal adhesions after intra-abdominal surgery (3,8).

Several factors may cause post-surgical adhesions including surgical injuries, tissue ischemia and foreign bodies, all of which damage the tissues and ultimately result in inflammation and release of cytokines and oxidative stress that initiate the processes of adhesion formation. Adhesion fibroblasts develop a myofibroblast phenotype, and it has been proved that these mesothelial cells respond to cytokines and extracellular matrix signaling and also promote the myofibroblasts phenotype (3,8).

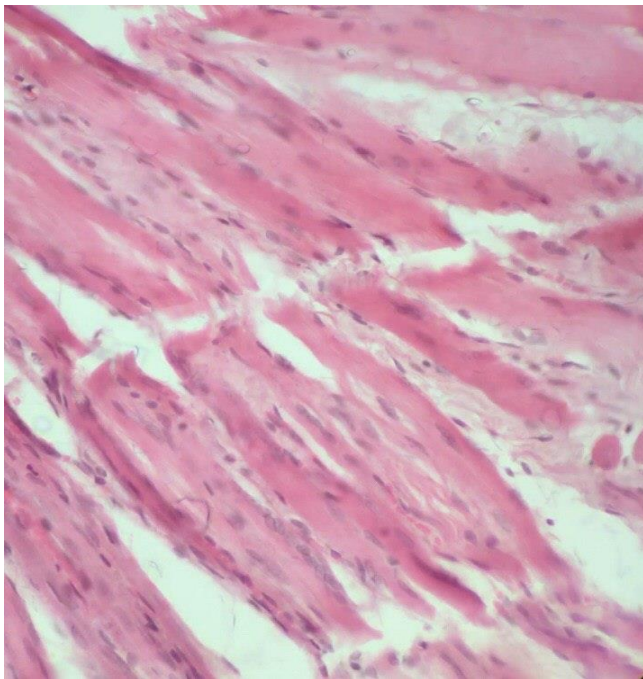


Figure 10: Microscopic section from the abdominal wall, on day 28 post-operation, in the Nano-NAC 50 mg group shows no fibrosis, no inflammation and no angiogenesis (H&E, Staining x400).

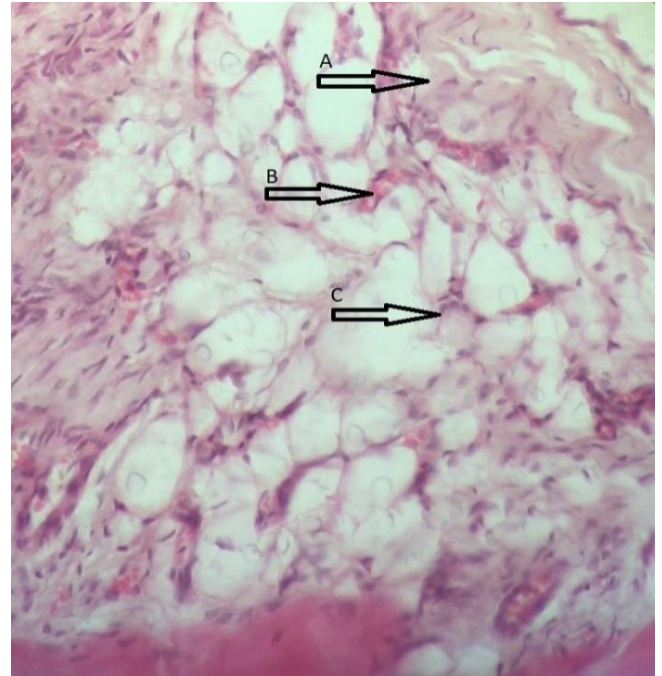


Figure 11: Microscopic section from the abdominal wall fat, on day 28 post-operation, in the control group shows severe fibrosis (A), moderate inflammation (C) and mild angiogenesis (B) (H&E, staining x400).

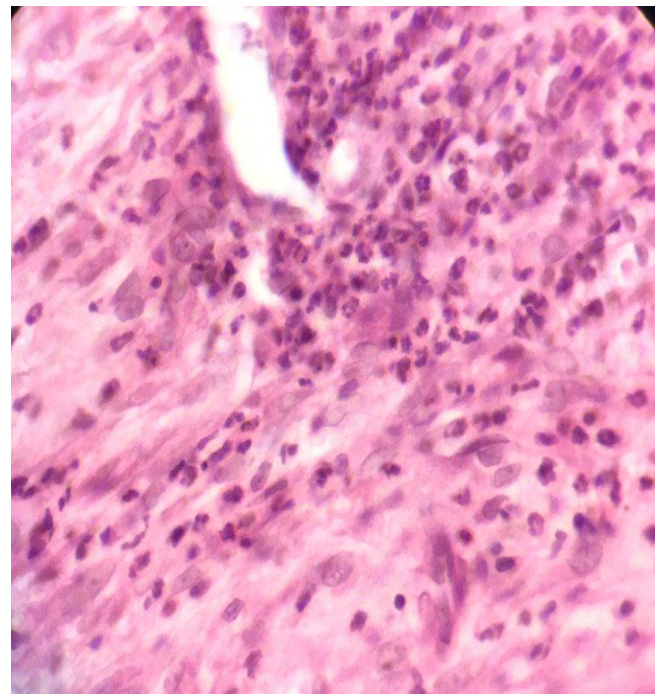


Figure 12: Microscopic section from the abdominal wall, on day 14 post-operation, in the Nano-NAC 150 mg group shows severe inflammation (H&E, Staining x400).

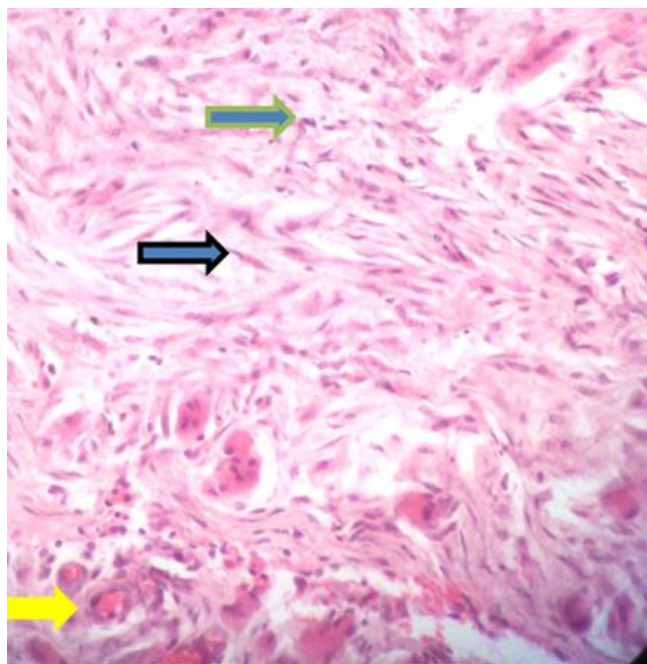


Figure 13: Microscopic section from the abdominal wall, on day 14 post-operation, in the Nano-NAC 75 mg group shows moderate inflammation (green arrow), angiogenesis (yellow arrow), and fibrosis (black arrow), (H&E, Staining x400).

Myofibroblasts and fibroblasts secrete very large amounts of extracellular matrix that includes hyaluronic acid, proteoglycan, fibronectin, and glycosaminoglycan. This process leads to the formation of a weak fiber bridge between the existing tissues that provides adhesive properties and then, with increased vascularization and collagen deposition, rigidity and stronger adhesion (13). These processes are associated with significant oxidative stress. Therefore, antioxidant therapies such as treatment with N-acetylcysteine (NAC) and Vitamin E can also inhibit inflammation, oxidative stress and adhesion formation (13,14).

N-acetylcysteine consists of L-cysteine and glutathione that reduce reactive oxygen species. Furthermore, N-acetylcysteine significantly decreases peritoneal oxidative stress by directly modifying membrane-associated oxidases. Chu *et al.* showed in their study that intraperitoneal administration of NAC reduced adhesion formation while upregulating peritoneal fibrinolytic activity and antioxidant defenses without changing normal anastomotic wound healing (15). In addition, the research by Moon *et al.* indicated that NAC was able to reduce the oxidative burst of neutrophils, RhoA activity, and myeloperoxidase activity all of which reduce oxidative stress and inflammation (16). The present study also demonstrated that after 14 days inflammation in the Nano-NAC 50 mg group was minimal, and the lowest, among the studied groups.

In another study that Pata *et al.* (17) carried out on the effectiveness of acetylcysteine at different doses in reducing intra-abdominal adhesion, intra-abdominal adhesion formation was much less in the group that received 15 mg/100g per day NAC IM compared to the other groups receiving high doses. In our study also, Nano-NAC at a lower dose 50 mg exhibited the best effect. Bulbuloglu *et al.* (18) evaluated the effect of NAC in rat laparoscopy-induced ischemia/reperfusion injury in the small intestine. In this study, a single dose of NAC was injected intraperitoneally. Results showed that N-acetylcysteine significantly reduced the side effects caused by endoscopy. Pourreza *et al.* (19) investigated effects of N-acetylcysteine on reducing intra-abdominal adhesions in sheep. They injected N-acetylcysteine at a dose of 150 mg intraperitoneally and then for up to 7 days intravenously. After 14 days, the histopathological results showed that the incidence of inflammation and fibrosis decreased significantly.

Aslan *et al.* (20) evaluated effects of local administration of NAC on intra-abdominal adhesion formation after laparotomy in rat models. Results indicated that tissue fibrosis and inflammatory cells decreased significantly after 10 days thereby preventing adhesion formation. We found similar results in our study, especially in the Nano- NAC group after 14 days. Due to the increasing use of modern technologies, especially in the production of recombinant drugs, nanoscience was used in the present study. Nanoparticles have unique biological and chemical properties in comparison to their larger counterparts (7). Nano-sized particles have more contact surfaces, can provide a more effective drug delivery system, and also enjoy many biomechanical, biological and chemical properties. Results of the present study showed that NAC in the form of nanoparticles, especially at low doses 50 mg, considerably decreased fibrosis and inflammation in abdominal wall over a period of 14 days compared to normal NAC and its effect continued 28 days after administration.

Conclusion

Local administration of Nano-NAC at low doses 50 and 75 mg prevented adhesion formation after laparotomy in rats through preventing fibrosis and inflammation. Nano-NAC is cheap, safe, available, and easy to administer. It has been widely used clinically in recent years for many purposes.

Conflicts of interest

The authors hereby state that they have no conflict of interests to declare regarding the content of this article.

Acknowledgments

This study was financially supported by Islamic Azad University, Science and Research Branch, Tehran, Iran. We

gratefully acknowledge the dedicated efforts of the investigators and the coordinators.

References

- Ward BC, Panitch A. Abdominal adhesions: Current and novel therapies. J Surg Res. 2011;165(1):91-111. DOI: [10.1016/j.jss.2009.09.015](https://doi.org/10.1016/j.jss.2009.09.015)
- Negahi AR, Hosseinpour P, Vaziri M, Vaseghi H, Darvish P, Bouzari B, Mousavie SH. Comparison of honey versus polylactide anti-adhesion barrier on peritoneal adhesion and healing of colon anastomosis in rabbits. Maced J Med Sci. 2019;28(4):23-28. DOI: [10.3889/oamjms.2019](https://doi.org/10.3889/oamjms.2019)
- Karimi M, Asadi Y, Parsaei P, Rafieian-Kopaei M, Ghaheiri H, Ezzati S. The effect of ethanol extract of rose (*Rosa damascena*) on intra-abdominal adhesions after laparotomy in rats. Wounds. 2016;28(5):167-174.
- Al-Qadhi AS, Al-Hasan AM. Comparison of two jejunal anastomosis techniques in dogs treated preoperatively with dexamethasone. Iraqi J Vet Sci. 2013;27(2):91-96. DOI: [10.33899/ijvs.2013.82805](https://doi.org/10.33899/ijvs.2013.82805)
- Nigwekar SU, Hix JK. The role of natriuretic peptide administration in cardiovascular surgery-associated renal dysfunction: A Systematic Review and meta-analysis of randomized controlled trials. J Cardiothorac Vasc Anesth. 2009;23(2):151-60. DOI: [10.1053/j.jvca.2008.11.007](https://doi.org/10.1053/j.jvca.2008.11.007)
- Arung W, Meurisse M, Detry O. Pathophysiology and prevention of postoperative peritoneal adhesions. World J Gastroenterol. 2011;17(41):45. DOI: [10.3748/wjg.v17.i41.4545](https://doi.org/10.3748/wjg.v17.i41.4545)
- Hala M, Khalef MHY, Awadh HA, Noomi BS, Jafar NA, Hadi KA. Evaluation the safety and synergistic effect of NiFe₂O₄ nanoparticles with antibiotic against *Pseudomonas aeruginosa*. Iraqi J Vet Sci. 2021;35(1):71-77. DOI: [10.33899/ijvs.2020.126298.1294](https://doi.org/10.33899/ijvs.2020.126298.1294)
- Parsaei P, Karimi M, Asadi SY, Rafieian-Kopaei M. Bioactive components and preventive effect of green tea (*Camellia sinensis*) extract on post-laparotomy intra-abdominal adhesion in rats. Int J Surg. 2013;11(9):811-5. DOI: [10.1016/j.ijssu.2013.08.014](https://doi.org/10.1016/j.ijssu.2013.08.014)
- Lorenz EP, Zühlke HV, Lange R, Savvas V. Pathophysiology and classification of adhesions. 1st ed. Berlin: Springer; 1997. 29 p. DOI: [10.1007/978-3-642-60433-1_4](https://doi.org/10.1007/978-3-642-60433-1_4)
- Rana KA, Abu-Raghib A. Comparative treatment of induced ulcerative colitis in male rat model by using cinnarizine and sulfasalazine. Iraqi J Vet Sci. 2020;34(2):465-472. DOI: [10.33899/ijvs.2019.126170.1254](https://doi.org/10.33899/ijvs.2019.126170.1254)
- Alabdaly YZ, Saeed MG, Al-hashemi HM. Effect of methotrexate and aspirin interaction and its relationship to oxidative stress in rats. Iraqi J Vet Sci. 2020;35(1):151-156. DOI: [10.33899/ijvs.2020.126490.1335](https://doi.org/10.33899/ijvs.2020.126490.1335)
- Karimi M, Parsaei P, Shafiei N, Rafieian-Kopaei M, Asadi SY. Effect of silymarin alcoholic extract on surgery-induced intraperitoneal adhesion in rats. Surg Pract. 2016;20(1):27-33. DOI: [10.1111/1744-1633.12157](https://doi.org/10.1111/1744-1633.12157)
- Boland GM, Weigel RJ. Formation and prevention of postoperative abdominal adhesions. J Surg Res. 2006;132(1):3-12. DOI: [10.1016/j.jss.2005.12.002](https://doi.org/10.1016/j.jss.2005.12.002)
- Al-Jammas S, Al-Saraj A. The histological changes induced by Cytarabine on rabbits livers (with and without vitamin E administration). Iraqi J Vet Sci. 2020;34:9-13. DOI: [10.33899/ijvs.2020.163564](https://doi.org/10.33899/ijvs.2020.163564)
- Chu DI, Lim R, Heydrick S, Gainsbury ML, Abdou R, D'addese L, Reed KL, Stucchi AF, Becker JM. N-acetyl-L-cysteine decreases intra-abdominal adhesion formation through the upregulation of peritoneal fibrinolytic activity and antioxidant defenses. Surg. 2011;149(6):801-12. DOI: [10.1016/j.surg.2011.02.015](https://doi.org/10.1016/j.surg.2011.02.015)
- Moon C, Lee YJ, Park HJ, Chong YH, Kang JL. N-acetylcysteine inhibits RhoA and promotes apoptotic cell clearance during intense lung inflammation. Am J Respir Crit Care Med. 2010;181(4):374-87. DOI: [10.1164/rccm.200907-1061OC](https://doi.org/10.1164/rccm.200907-1061OC)
- Pata O, Yazıcı G, Apa DD, Tok E, Oz U, Kaplanoğlu M, Aban M, Dilek S. The effect of inducible nitric oxide synthase on postoperative adhesion formation in rats. Eur J Obstet Gynecol Reprod Biol. 2004;117(1):64-9. DOI: [10.1016/j.ejogrb.2003.10.034](https://doi.org/10.1016/j.ejogrb.2003.10.034)
- Bulbuloglu E, Yildiz H, Senoglu N, Coskuner I, Yuzbasioglu MF, Kilinc M, Dogan Z, Deniz C, Oksuz H, Kantarçeken B, Atli Y. Protective effects of zinc, pentoxifylline, and N-acetylcysteine in an animal model of laparoscopy-induced ischemia/reperfusion injury of the small intestine. J Laparoendosc Ad Surg Tech. 2011;21(10):947-51. DOI: [10.1089/lap.2011.0194](https://doi.org/10.1089/lap.2011.0194)
- Pourreza B, Ghamsari SM, Sasani F, Mansoor Lakooraj H. Effects of n-acetyl-L-cysteine on postoperative intra-abdominal adhesion in a large animal model. Iranian J Vet Surg. 2015;10(2):1-0. DOI: [10.1164/rccm.200907-1061OC](https://doi.org/10.1164/rccm.200907-1061OC)
- Aslan GI, Otgun I, Acer T, Tepeoglu M, Hicsonmez A. The effect of intraperitoneal N-acetylcysteine on postoperative adhesions in rat models. Ann Ital Chir. 2017;88:258-62.

التقييم المرضي النسيجي لتأثير نانو-ان-أسيتيل سيسيتين على الالتصاق بعد الجراحة في الجرذان

س. شاهزamani^١، أ. جهانداده^{٢*}، غ. عدي^١، أ. اكبرزاده^{٢،٣}، س. هيساركي^٢ و ب. برسايلي^٤

قسم العلوم السريرية، كلية العلوم البيطرية المتخصصة، فرع العلوم والبحوث، جامعة آزاد الإسلامية، طهران، شبكة التعليم والبحث العلمي العالمية، تبريز، قسم الأمراض، كلية العلوم البيطرية المتخصصة، فرع العلوم والبحوث، جامعة آزاد الإسلامية، طهران، مركز أبحاث الأدوية التطبيقية، جامعة تبريز للعلوم الطبية، تبريز، قسم صحة الغذاء، كلية الطب البيطري، فرع شهرکرد، جامعة آزاد الإسلامية، شهرکرد، إيران

الخلاصة

الالتصاق البطني هو أحد المشاكل الرئيسية والمهمة بعد الجراحة، ووفقاً للدراسات المتاحة، فإن احتمال حدوثه بعد الجراحة أعلى من ٥٠٪. هدفت الدراسة الحالية إلى تقدير تأثير نانو-أسيتيل سيسيتين على الالتصاقات العيانية والمجهرية بعد الجراحة في نموذج حيواني. تم تقسيم خمسة وعشرين ذكور جرذان ويستار بالغة، ٢٠٠-٢٢٠ غم عشوائياً إلى خمس مجموعات متساوية وخضعت للتخدير العضلي عن طريق حقن الكيتامين ١٠٪ عند ٥٠ ملغم / كغم وحقن زيلازين ٢٪ بجرعة ٥ ملغم / كغم. تضمنت العلاجات ثلاث مجموعات من نانو-أسيتيل سيسيتين بجرعات مختلفة ٥٠ و ٧٥ و ١٥٠ ملغم / كغم، ومجموعة ن-أسيتيل سيسيتين ومجموعة السيطرة. في اليومين ١٤ و ٢٨ بعد الجراحة، أُعيد فتح بطون جميع الجرذان للتقييم العياني والمجهرى للالتصاقات. بناءً على نتائج التقييم العياني، كان لدى المجموعة التي تلقت ٥٠ ملغم / كغم نانو-أسيتيل سيسيتين أدنى درجات الالتصاق ومجموعة السيطرة أعلى درجات الالتصاق في اليومين ١٤ و ٢٨ بعد الجراحة. كما أظهر التقييم المرضي النسيجي أن المجموعة التي عولجت بـ ٥٠ ملغم / كغم نانو-أسيتيل سيسيتين كان لديها أدنى مستوى من الالتهاب والتليف بين المجموعات الخمس في اليومين ١٤ و ٢٨ بعد الجراحة. بالنظر إلى النتائج التي تم الحصول عليها في النموذج التجريبي والاستخدام المتزايد لتقنية النانو في تصنيع الأدوية الطبية الحيوية، يبدو أن استخدام نانو-أسيتيل سيسيتين بجرعات منخفضة ٥٠ و ٧٥ ملغم / كغم بعد فتح البطن منظارياً يمكن أن يقلل بشكل كبير من الالتصاقات.