



Evaluation the antihyperlipidemic effect of apigenin flavonoid in mice

Z.S. Hamed¹, A.Sh. Altaweel², K.A. Shaban³ and G.A. Taqa²

¹Department of Pharmacology and Toxicology, College of Pharmacy, ²Department of Dental Basic Sciences, College of Dentistry, ³Department of Physiology, Biochemistry and Pharmacology, College of Veterinary Medicine, University of Mosul, Mosul, Iraq

Article information

Article history:

Received May 12, 2021

Accepted July 11, 2021

Available online January 26, 2022

Keywords:

Antihyperlipidemic

Apigenin

Flavonoid

Lipid profile

Correspondence:

Z.S. Hamed

zenasattam@uomosul.edu.iq

Abstract

The study's aim was to examine the antihyperlipidemic effect of apigenin in mice as a model. Healthy adult albino mice of either sex were selected to use for this study. Four groups of animals were formed of 5 mice each. Animals Group 1 served as a negative control and fed the standard diet and tap water. Groups 2,3 and 4 were fed fatty diet and 1% water with H₂O₂ for 90 days to induce hyperlipidemia. After hyperlipidemic induction, group 2 served as a positive control, whereas group 3 was treated orally with apigenin 50 mg/kg/day for 14 constitutive days. Group 4 was treated by rosuvastatin (an antihyperlipidemic drug) orally at 7 mg/kg for 14 constitutive days. Blood samples were collected from all of the animals at the beginning of the study to measure the lipid profile. Then these were rechecked again after 12 weeks of feeding a high-fat diet, and then at the end of the experiment for the treated groups. The results demonstrated that the apigenin at 50mg/kg significantly reduced hyperlipidemia manifested by decreased TC, LDL-C, Triglyceride and elevation of HDL-C in comparison with the positive control group. The results, obtained by apigenin were the in accordance with those of the standard drug rosuvastatin for TC and LDL-C. This study concluded that apigenin lowered plasma cholesterol and triglycerides levels in mice.

DOI: [10.33899/ijvs.2021.130008.1718](https://doi.org/10.33899/ijvs.2021.130008.1718), ©Authors, 2022, College of Veterinary Medicine, University of Mosul.

This is an open access article under the CC BY 4.0 license (<http://creativecommons.org/licenses/by/4.0/>).

Introduction

Cardiovascular and cerebrovascular disorders are significant results that take place due to atherosclerosis (1). Based on epidemiological studies, hyperlipidemia and/or hypercholesterolemia are a serious independent risk factor among the causes of atherosclerosis. According to the American Health Association (AHA), hypercholesterolemia is described as an extremely large scale of plasma cholesterol that has arisen as a strong risk factor for atherosclerotic cardiovascular disease (ASCVD) (2). Synthetic hypocholesterolemic agents, statins, have been approved by clinical guidelines as the first option drug for the prevention and treatment of ASCVD (3). Nevertheless, a large proportion of the statin-treated patients are still at a high risk of cardiovascular events known as sediment risk

(4), due to statin adverse side effects such as liver damage and toxicity of the muscles. Therefore, in recent years, research has focused on the quest for natural compounds that can lower blood fat levels as these compounds have a wide range of potential uses and social advantages. (5). Flavonoid plants with antiatherosclerotic effects, decrease atherosclerotic risk in vitro and in vivo animal models of atherosclerosis. Flavonoids have been shown to have a wide variety of biological benefits, including antioxidant, anti-inflammatory, anti-tumor, anti-genotoxic, anti-allergic, neuroprotective, cardioprotective, and antimicrobial properties (6). Apigenin is a flavonoid that is usually spread in a variety of temperate and tropical vegetables and fruits. Celery and other medicinal plants have high amounts of it (7). Apigenin can also be used in certain plant-based beverages, such as tea, and in condiments (8). Previous tests

have demonstrated that in controlling cholesterol there is no significant effect of the flavonoids on the metabolism of blood lipids, Apigenin, on the other hand, is essential for regulating blood fat levels. In the serum of the high-fat model mouse, it can reduce animal body weight, triglyceride (TG) and the amount of total cholesterol (TC) (9). The current research used a mouse model of hyperlipidemia to test the effectiveness of apigenin in lowering cholesterol levels. Additionally, the histopathological effects of apigenin in many organs of the body were assessed.

Materials and methods

Animal source

Twenty of mature male and female albino Swiss mice were purchased from the Laboratory Animal House of the College of Veterinary Medicine University of Mosul, Iraq. In a clean animal, the mice were raised of the College of Dentistry, University of Mosul. Healthy adult albino Swiss mice weighing 20-30 g of either sex were chosen to use for this study. The animals were habituated in plastic cages at $22\pm 2^{\circ}\text{C}$, with a 12-hour light/12-hour dark cycle and free access to a standard diet and tap water.

Feeding, induction and assessment of hyperlipidemias

Negative control group were fed with standard diet and water ad libitum. The standard diet consisted of animal protein 10%, soybean cake 20%, forage yellow corn 55%, forage wheat 14%, salt 0.5%, lime 0.5%. The positive control and the experimental groups were fed for 90 days with fatty diet and water with 1% H_2O_2 to induce hyperlipidemia (10). The experimental two groups were continued fed with fatty diet to the end of the study. The fatty diet consisted of wheat flour 34%, barley flour 20%, corn flour 25%, fatty milk powder 10%, animal protein 10%, salt 1% and vegetable oil and water for knead (11).

Grouping

Animals were separated randomly into four groups of five mice each, as follows; Standard diet and water (Group I); Fatty diet and water with 1% H_2O_2 for 90 days (Group II); Hyperlipidemic group + Fatty diet + Apegnin (Yanhuang Industrial Park, Guanxian, Liaocheng, Shandong, China) 50 mg/kg for 2 weeks (Group III); Hyperlipidemic group + Fatty diet + Rosuvastatin (Al-Taqaddom/ Pharmaceutical Industries/ Amman-Jordan) 7 mg/kg for 2 weeks (Group V). Dimethyl sulfoxide (DMSO) (SIGMA-ALDRICH-Merck KGaA, Darmstadt, Germany) was used as a solvent for preparation of apegnin dose at 50 mg of apegnin dissolved in 5ml of DMSO and normal saline (NS) (Primeera Healthcare Private Limited /India) as a solvent for preparation of drug suspensions 20 mg of rosuvastatin tablet dissolved in 10ml of NS. Then the mice

were administered 0.2 ml of apigenin and rosuvastatin respectively by intragastric gavage once per day for 15 consecutive days.

Determination of blood lipid profile in serum

The lipid profile parameters were measured with a biochemical analyzer (FUJIFILM, DRI-CHEM NX500i, Tokyo, Japan). At the beginning of the study blood samples were collected from the eyes of all of the animals to measure these parameters. Then these were measured again after feeding on high-fat diet for 12 weeks and then when the experiment comes to an end.

Histopathological examinations

After the animals were sacrificed, liver, kidneys and brain were harvested from the mice and immediately fixed in 10% formalin. The tissues were excised and covered with normal physiological saline and washed of the fat and connective tissue attached. In 10% neutral buffered formalin, dehydrate with graded series of ethyl alcohol and embedded in paraffin. Blocks of tissues were instantly fixed. The digital camera attached to light microscope was used to take photomicrographs of the stained slides (12).

Statistical analysis

The differences between the three study groups were evaluated statistically using one-way analysis of variance ANOVA and the least significant difference test. The significance level was at $P < 0.05$ (13).

Results

Lipid profile testes

The result revealed that mice exposed to H_2O_2 in drinking water for 3 months had significantly elevated serum total cholesterol, triglyceride, serum LDL cholesterol and VLDL concentrations on day 60 of treatment (Table 1). Compared with control and the hypercholesterolemic the administration of apigenin flavonoid at 50 mg/kg, orally significantly suppressed the elevated lipid profile (Table 1). Significant increase in serum HDL-C concentrations 123.3 ± 8.0 and 106.3 ± 7.7 mg/dl were recorded in treated groups with apigenin and rosuvastatin statin respectively in comparison with positive control 35.3 ± 2.5 mg/dl and negative control 64 ± 3.6 mg/dl after two months of treatment. Histopathologic examinations showed that the severity of the lesions increased in liver and kidney in the group on H_2O_2 , which was characterized by congestion of blood vessels of the hepatic lobules and lymphocytic mass infiltration around the central vein. In the kidney, there was the presence of massive aggregation of lymphocytic and other inflammatory cells in the pelvis of the kidney and around renal tubules. Apigenin and rosuvastatin treatments prevented the deleterious histological changes induced by H_2O_2 in mice (Figures 1 and 2).

Table 1: lipid profile of the control and treated groups of mice

Groups	Mean \pm SD (n=5 mice/group)				
	Cholesterol (mg/dl)	HDL (mg/dl)	LDL (mg/dl)	VLDL (mg/dl)	Triglyceride mg/dl)
Control -ve	64.0 \pm 7.0 A	64 \pm 3.6 A	3.5 \pm 0.5A	12.5 \pm 1.5A	66 \pm 3 A
Control +ve	286.0 \pm 87.0 B	35.3 \pm 2.5 B	31.7 \pm 1.5B	45 \pm 4.B	197.6 \pm 35 B
Rosuvastatin+Fatty diet	69.0 \pm 6.5 A	106.3 \pm 7.7 C	17.0 \pm 2.5A	13.6 \pm 1.5A	82 \pm 12.1 A
Apigenin+Fatty diet	74.9 \pm 10.5 A	123.3 \pm 8.0 D	10.2 \pm 1.0A	12.1 \pm 2.2A	70 \pm 2 A

Different capital letters mean there are significant different in the same column at $P < 0.05$.

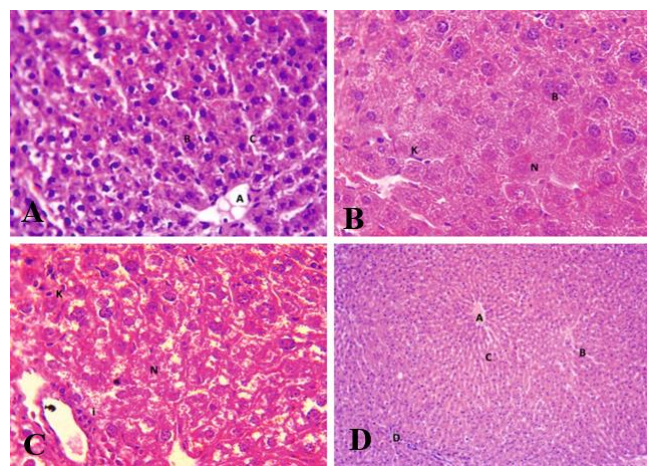


Figure 1: A: Photomicrograph of liver of negative control group (without treatment) showing normal architecture of liver tissue characterized by central vein (A), hepatocytes (B) and sinusoids (C). H&E stain, 400X. B: Positive control histological section of liver showing increased number of kuffer cells (K) coagulative necrosis of hepatocytes (N) and presence of binuclear hepatocytes (B). H&E stain, 400X. C: Rosuvastatin, Necrosis of hepatocytes (N), infiltration of inflammatory cells around portal area (i) and increased number of Kupffer cells (K). H&E stain, 400X. Histological section of liver showing hydropic degeneration(D) and coagulative necrosis of hepatocytes (N), infiltration of inflammatory cells as foci (i) and congestion of portal vein (C). H&E stain, 400X. D: Photomicrograph of mice liver of Apigenin group showing normal architecture of liver tissue representing by central vein (A), hepatocytes (B), sinusoids (C) and portal area (D). H&E stain, 100X.

Discussion

In the last few decades, the application of herbal ingredients in the healing and prevention of various illnesses as an alternative to traditional therapy has increased due to concerns about the side effects of traditional medicine (14). Hyperlipidemia in mice fed a high-fat diet was replicated in the present study. The mice's serum levels of LDL-C, TG and TC increased significantly at 12 week of high-fat diet exposure, suggesting that the hyperlipidemia model was successful. In this research, the

findings showed that administration of apigenin at a dosage of 50 mg/kg orally, significantly lowered serum LDL-C, TG and TC concentrations, and this decrease suggested that apigenin was shown to be effective at preventing blood lipid levels from increasing, enhanced cholesterol metabolism disorder, mitigated hepatic lipid accumulation, and recovered equilibrium (5).

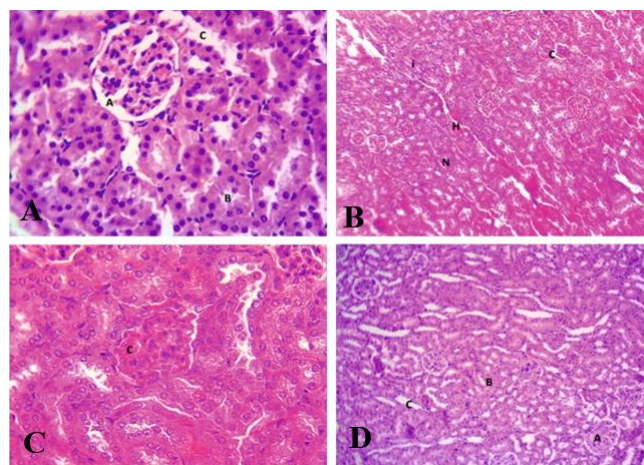


Figure 2: A: Photomicrograph of kidney of negative control group (without treatment) showing normal architecture of renal tissue characterized by glomeruli (A), proximal renal tubules (B) and distal renal tubules (C). H&E stain, 400X. B: Positive control, histological section of kidney showing of hyaline cast (H) necrosis of renal tubules (N), congestion of glomeruli (C) and infiltration of inflammatory cells (i). H&E stain, 100X. C: Rosuvastatin, histological section of kidney showing of congestion of glomeruli (C) with normal architecture of kidney. H&E stain, 100X. D: Photomicrograph of kidney of apigenin group showing normal architecture of renal tissue characterized by glomeruli (A), proximal renal tubules (B) and distal renal tubules (C). H&E stain, 100X.

LDL-R is an effective receptor mediating LDL-C uptake in the liver. After consuming a high-fat diet, it was observed to be lower than in the normal control group and apigenin administration can carry LDL-R expression levels back to approximate normal levels (15). Apigenin can also increase Superoxide Dismutase (SOD) activity, increase in

vivo anti-oxidative ability, decrease the amount of generated low-density oxidative lipoprotein, and prevent the production of atherosclerosis (16,17). Apigenin significantly lowered serum TC, TG, and LDL-C in mice with hyperlipidemia as well as liver TC and TG accumulation, according to the results apigenin can lower cholesterol levels by encouraging hepatic LDL-C absorption and increasing the transition of hepatic cholesterol into bile acid (18).

In the current study, apigenin lowered TC and TG, and this could be due to the fact that apigenin aids in the reduction of the function of both HMG-CoA reductase and acetylCoA cholesterol-oacetyl transferase (ACAT). Through phosphorylation of enzyme directly responsible for hypercholesterolemia and decrease activity of enzyme of cholesterolgenesis. This leads apigenin to regulate serum lipid profile (19) and it suppress lipid peroxidation level and rise significantly the antioxidant defense mechanisms of enzymes (20,21). Apigenin's free radicals scavenging activities can decrease LDL-C oxidation and minimize its transport to various tissues. Elevation in HDL-C concentration after apigenin, may be due to stabilizing effect of its polyphenols on plasma lipoprotein or due to systemic effect of flavonoids to modulate different enzymatic activity that can influence lipoprotein leading to augmentation of HDL-C. This rise in HDL-C is in line with previous reports (22), where HDL-C enhances the transfer of cholesterol from the serum to the liver, to be catabolized. Apigenin has been used for hypercholesterolemia that act on elevated TC, TG, level by activating lipoprotein lipase and clearance of LDL-C and increase in HDL-C (23). Therefore, in order to reduce oxidative stress and boost the metabolic process of these tyloxopol, antioxidants that are free radical scavengers such as apigenin mediate hyperlipidemic mice. Most flavonoids were effective in improving the metabolism of cholesterol in hypercholesterolemic animal models and in inhibiting the activity of hepatic HMG-COA reductase activity and cholesterol acyltransferase (ACAT) for cholesterol synthesis and esterfication. The supplementation of apigenin may have a beneficial impact on the plasma lipid profile and on the antioxidant protection system (24) as found in the present study. After its administration, apigenin remains in the plasma at high levels. In addition, this compound induces a large increase in plasma antioxidants through the hydroxyl groups that scavenge reactive oxygen species (ROS) and decrease the hepatoprotective activity of oxidant compounds (25).

Conclusion

The present study showed apigenin had lipid lowering effect, as it lowered serum TC, TG, LDL-C, and increased HDL-C. The findings of this study lay the groundwork for

future studies into the function of apigenin's role in cholesterol metabolism regulation.

Acknowledgment

We would like to thanks to all those who supplied us the possibility to finish this study, especially College of Pharmacy, Dentistry and Veterinary Medicine, University of Mosul.

Conflict of interests

The authors declare no conflict of interest

References

- Liu-Smith F, Meykens FL. Molecular mechanisms of flavonoids in melanin synthesis and the potential for the prevention and treatment of melanoma. *Mol Nutr Food Res*. 2016;60(6):1264-1274. DOI: [10.1002/mnfr.201500822](#)
- Hamdoun AA, Al-Khashab EM, Al-Hashemi HM. Effect of saponin extract of Glycyrrhiza glabra in activity of hepatic enzymes and some biochemical parameters in serum of adults ovariectomized female rats. *Iraqi J Vet Sci*. 2020;34(2):411-415. DOI: [10.33899/ijvs.2019.1239](#)
- Stone NJ, Robinson JG, Lichtenstein AH, Bairey Merz CN, Blum CB, Eckel RH, Sherro ST, Smith Jr SC, Watson K, Wilson PWF. 2013 ACC/AHA guideline on the treatment of blood cholesterol to reduce atherosclerotic cardiovascular risk in adults: a report of the American College of Cardiology/American Heart Association Task Force on Practice Guidelines. *Circ J*. 2014;129(25):S1-45. DOI: [10.1161/01.7a](#)
- Kataoka Y, St John J, Wolski K, Uno K, Puri R, Tuzcu EM, Nissen SE, Nicholls SJ. Atheroma progression in hyporesponders to statin therapy. *Arterioscler Thromb Vasc Biol*. 2015;35:990-995. DOI: [10.1161/ATVBAHA.114.304477](#)
- Zhang K, Song W, Li D, Jin X. Apigenin in the regulation of cholesterol metabolism and protection of blood vessels. *Exp Ther Med*. 2017;13(5):1719-1724. DOI: [10.3892/etm.2017.4165](#)
- Catarino DM, Alves-Silva JM, Pereira OR, Cardoso SM. Antioxidant Capacities of Flavones and Benefits in Oxidative-Stress Related Diseases. *Curr Top Med Chem*. 2015;15(2):105-119. DOI: [10.1017/S1568026615666141209144506](#)
- Wang M, Firrman J, Liu L, and Yam K. A Review on Flavonoid Apigenin: Dietary Intake, ADME, Antimicrobial Effects, and Interactions with Human Gut Microbiota. *Bio Med Res Inter*. 2019;7010467. DOI: [10.1155/2019/7010467](#)
- Salehi B, Venditti A, Sharifi-Rad M, Kregiel D, Sharifi-Blad J, Durazzo A, Lucarini M, Santini A, Souto EB, Novellino E, Antolak H, Azzini E, Setzer WN, and Martins N. The Therapeutic Potential of Apigenin. *Int J Mol Sci*. 2019;20(6):1305. DOI: [10.3390/ijms20061305](#)
- Nabavi SM, Habtemariam S, Daglia M, Nabavi SF. Apigenin and breast cancers: From chemistry to medicine. *Anticancer Agents Med Chem*. 2015;15(6):728-735. DOI: [10.2174/187152061150304120643](#)
- Khudiar KK. Effect of 1% Hydrogen peroxide (H2O2) in drinking water on some parameters in adult male rabbits. *Iraqi J Biotech*. 2010;9(2):202-210. [[available at](#)]
- Terry KK, Stedman DB, Bolon B and Welsch F. Effects of 2-methoxyethanol on mouse neuroanulation. *Teratol*. 1996;54(5):219-29. DOI: [10.1002/\(SICI\)1096-9926\(199611\)](#)
- Salah BA, Sadoon HS. Histopathological and some biochemical effects of platinum drug on the liver and kidney of pregnant mice *Mus musculus* and their embryos. *Iraqi J Vet Sci*. 2021;35(2):291-300. DOI: [10.33899/ijvs.2020.126793.1382](#)

13. Daniel WW, Cross CL. Biostatistics: Basic concepts and methodology for the health sciences. 10th ed. NY: International Student version; 2013. 960 p. [available at]
14. Ishida T, Ohta M, Masanori N, Kami M, Kami H, Uchiyama R, Kawano H, Notsu, Imada K, Shimano H. Distinct regulation of plasma LDL cholesterol by eicosapentaenoic acid and docosahexaenoic acid in high fat diet-fed hamsters: Participation of cholesterol ester transfer protein and LDL receptor. PLEFA. 2013;88(4):281-288. DOI: [10.1016/j.plefa.2013.01.001](https://doi.org/10.1016/j.plefa.2013.01.001)
15. Zargarani A, Borhani-Haghighi A, Faridi P, Daneshamouz S, Kordafshari G Mohagheghzadeh A. Potential effect and mechanism of action of topical chamomile (*Matricaria chamomilla* L.) oil on migraine headache: A medical hypothesis. Med Hypotheses. 2014;83:566-569. DOI: [10.1016/j.mehy.2014.08.023](https://doi.org/10.1016/j.mehy.2014.08.023)
16. Malekmohammad K, Sewell RDE, Mahmoud Rafieian-Kopaei M. Antioxidants and atherosclerosis: Mechanistic Aspects. Biomol. 2019;9(8): 301. DOI: [10.3390/biom9080301](https://doi.org/10.3390/biom9080301)
17. Ukwueze CS, Akpan ES, Ezeokkonko RC, Nwosuh CI, Anene BM. Haematological, oxidative stress and electrolyte alterations in puppies with canine parvoviral enteritis. Iraqi J Vet Sci. 2020;34(1):65-69. DOI: [10.33899/ijvs.2019.125582.1094](https://doi.org/10.33899/ijvs.2019.125582.1094)
18. Wong TY, Tan Y, Lin S, Leung L. Apigenin and luteolin display differential hypocholesterolemic mechanisms in mice fed a high-fat diet. Biomed Pharmacother. 2017;69:1000-1007. DOI: [10.1016/j.131](https://doi.org/10.1016/j.131)
19. Ren B, Qin W, Wu F, Wang S, Pan C, Wang L, Zeng B, Ma S, Liang J. Apigenin and naringenin regulate glucose and lipid metabolism, and ameliorate vascular dysfunction in type 2 diabetic rats. Eur J Pharmacol. 2016;773: 13-23. DOI: [10.1016/j.ejphar.2016.01.002](https://doi.org/10.1016/j.ejphar.2016.01.002)
20. Rašković A, Gigov S, Čapo I, Paut Kusturica M, Milijašević B, Kojić-Damjanov S, Martić N. Antioxidative and Protective Actions of Apigenin in a Paracetamol-Induced Hepatotoxicity Rat Model. Eur J Drug Metab Pharmacokinet. 2017;42(5):849-856. DOI: [10.1007/s13318-017-0407-0](https://doi.org/10.1007/s13318-017-0407-0)
21. Al-abdaly YZ, Saeed MG, Al-Hashemi HM. Effect of methotrexate and aspirin interaction and its relationship to oxidative stress in rats. Iraqi J Vet Sci. 2021;35(1):151-156. DOI: [10.33899/ijvs.2020.1335](https://doi.org/10.33899/ijvs.2020.1335)
22. Millar CL, Duclos Q, Blesso CN. Effects of dietary flavonoids on reverse cholesterol transport, HDL metabolism, and HDL function. Adv Nutr J. 2017;8(2):226-239. DOI: [10.3945/an.116.014050](https://doi.org/10.3945/an.116.014050)
23. Trajkovska KT, Topuzovska S. High-density lipoprotein metabolism and reverse cholesterol transport: Strategies for raising HDL cholesterol. Anatol J Cardiol. 2017;18(2):149-154. DOI: [10.14.7608](https://doi.org/10.14.7608)
24. Ibrahim RT, Mahmmod AM, Taqa GA. Synthesis of silver nano particles using catechin and apigenin and study their anti- oxidant effect on the laboratory rats. Coll Basic Edu Res J. 2020;16(3):919-943 DOI: [10.33899/berj.2020.166004](https://doi.org/10.33899/berj.2020.166004)
25. Ibrahim RT, Mahmmod AM, Taqa GA. The protective and antioxidant effect of catechin and apigenin on some biochemical parameters in blood serum of rats exposed to oxidative stress induced by H2O2. Coll Basic Edu Res J. 2020;16(3): 813-852. DOI: [10.33899/berj.2020.166002](https://doi.org/10.33899/berj.2020.166002)

تقييم التأثير الخافض لفلافونويد الأبيجينين على ارتفاع دهون الدم في الفئران

زينة سظام حمد^١، احمد شهاب الطويل^٢، خالد احمد شعبان^٣
و غادة عبد الرحمن طاقة^٢

^١ فرع الأدوية والسموم، كلية الصيدلة، ^٢ فرع علوم طب الأسنان الأساسية، كلية طب الأسنان، ^٣ فرع الفسلجة والكيمياء الحياتية والأدوية، كلية الطب البيطري، جامعة الموصل، الموصل، العراق

الخلاصة

الهدف من الدراسة هو فحص التأثير المضاد لفرط شحميات الدم الأبيجينين في الفئران كنموذج. فقد تم اختيار فئران بالغة صحية من كلا الجنسين لاستخدامها في هذه الدراسة. تم تقسيم الحيوانات إلى أربعة مجموعات كل مجموعة من خمسة حيوانات. استخدمت المجموعة الأولى كعنصر تحكم سلبي وأخذت نظامًا غذائيًا قياسيًا وماء الصنبور. المجموعة الثانية والثالثة والرابعة كانت تتغذى على نظام غذائي دهني و ١٪ ماء يحتوي على بيروكسيد الهيدروجين لمدة تسعون يومًا للحث على زيادة شحميات الدم. بعد تحريض فرط شحميات الدم، استخدمت المجموعة الثانية كعنصر تحكم إيجابي بينما عولجت المجموعة الثالثة عن طريق الفم بتناول الأبيجينين ٥٠ ملغم/كغم لمدة أربعة عشر يومًا. المجموعة الرابعة، تعالج بواسطة روسوفاستاتين فمويًا ٧ ملغم/كغم لمدة أربعة عشر يومًا. تم جمع عينات الدم من جميع الحيوانات في بداية الدراسة لقياس متغيرات ملف الدهون. ثم أعيد فحصها مرة أخرى بعد اثنا عشر أسبوعًا من إطعام نظام غذائي غني بالدهون ثم في نهاية التجربة للمجموعات المعالجة لتقييم قيمها. أظهرت النتائج أن الأبيجينين عند جرعة ٥٠ ملغم/كغم يقلل من فرط شحميات الدم والذي يتجلى في انخفاض الكوليسترول وكوليسترول البروتين الدهني منخفض الكثافة والشحوم الثلاثية وارتفاع كوليسترول البروتين الدهني العالي الكثافة مقارنة بمجموعة التحكم الإيجابية، الكوليسترول وكوليسترول البروتين الدهني منخفض الكثافة على التوالي. وكانت النتيجة التي حصل عليها الأبيجينين هي نفس النتيجة بواسطة عقار روسوفاستاتين القياسي للكوليسترول وكوليسترول البروتين الدهني منخفض الكثافة. خلصت هذه الدراسة إلى أن الأبيجينين قد ثبت أنه يخفض مستويات الكوليسترول والدهون الثلاثية في بلازما الفئران.

