



Morphological and phylogenetic characterization of *Oestrus ovis* larvae in sheep: Al-Qadisiyah province, Iraq

N.S. Alhayali¹, M.A. Alsaadawi², M.A. Alfatlawi³ and M.J. Ali³

¹Department of Microbiology, College of Veterinary Medicine, Mosul University, Mosul, ²Department of Parasitology, College of Veterinary Medicine, Al-Muthanna University, Al-Muthanna, ³Department of Veterinary Microbiology, College of Veterinary Medicine, University of Al-Qadisiyah, Al-Diwaniyah, Iraq

Article information

Article history:

Received February 10, 2021

Accepted March 21, 2021

Available online November 21, 2021

Keywords:

Bot fly

Oestrosis

Oestrus ovis

Nasal bots

Correspondence:

M.A. Alfatlawi

monyerr.abd@qu.edu.iq

Abstract

The fly larvae infect the nasal cavities and sinuses (frontal and maxillary) of sheep, goats, and a range of wild ruminants, forming a disease called oestrosis (Nasal myiasis or nasal bot). The disease is one of the significantly diseases for the Iraqi small ruminant industry that causes detrimental economic losses. The current work was carried out to morphologically- and molecularly-characterize *O. ovis* larvae collected from sheep in a slaughterhouse in Al-Qadisiyah province, Iraq. The study depended on collecting 20 larvae (at different stages) from 20 sheep from 15 October till 17 December 2020. The morphological examination was done using a stereomicroscope and relying on larval characteristic features, including the posterior end, spiracles, and cephalopharyngeal skeleton. The molecular characterization was performed utilizing polymerase chain reaction (PCR) and partial gene sequencing (PGS) methods of the cytochrome c oxidase subunit I (*coxI*) gene at 700bp and 300-bp regions. Morphologically, the first-stage larvae (L1) showed characteristic mouth hooks, while the second-stage larvae (L2) revealed clear terminal stigmas. For the third-stage larvae (L3), the color of body segments and their spines' were the most important features for this larval stage. The PCR showed amplification at both regions 700bp and 300bp, in 8 and 7 isolates, respectively. The PGS revealed 15 different local isolates in genetic level aligned with isolates from Kyrgyzstan, Italy, Spain, and Turkey. This study shows the important strain differences of *O. ovis* that infect the local sheep in Al-Qadisiyah province, Iraq.

DOI: [10.33899/ijvs.2021.129231.1636](https://doi.org/10.33899/ijvs.2021.129231.1636), ©Authors, 2022, College of Veterinary Medicine, University of Mosul.

This is an open access article under the CC BY 4.0 license (<http://creativecommons.org/licenses/by/4.0/>).

Introduction

Oestrus ovis parasites are well-studied larvae significantly spread around the world. The larvae can affect the nasal cavities and sinuses (frontal and maxillary) of sheep, goats and a known-range of wild ruminants, leading oestrosis, a disease caused by these larvae (1,2). The oviparous insect females move in huge groups around the animal head and place their several-dozen eggs in spots close to the nostrils and into the eyes' orbits (2,3). The ova hatch and the larvae migrate throughout the nasal cavity and sinuses, feeding on mucus and debris, in 2-10

months, the larvae complete their growing phase, migrate back to the nasal cavity, and are sneezed out (4,5). The infected sheep may have nasal discharge (seromucous or purulent), continuing sneezing, and dyspnea (6). Zoonosis is considered a health issue caused by *O. ovis*, which induces a clinical picture in humans who live close to infected ruminants in rural regions, leading to ophthalmomyiasis, respiratory and non-respiratory involvement (7-10). Oestrosis is found in various areas, and natures of the world are reported from regions, including Asian countries and European and African countries that sit on the Mediterranean coastlines (11). The parasitic

infestation was also detected in animals from sub-tropical humid areas to California and some regions that are close to Central America. Some climate factors, such as temperatures 25-28°C, sun radiation 116-838 Wm⁻², rainfall 900 mm, and relative humidity 65-85%, can help in encouraging infections by these worms (11). The disease is worldwide and specifically reported in Saudi Arabia, Egypt, Algeria, Benin, and Brazil (12-16). The disease is of significant importance for the Iraqi small ruminant industry that causes detrimental economic losses. The current work was carried out to morphologically- and molecularly-characterize *O. ovis* larvae collected from sheep in a slaughterhouse in Al-Qadisiyah province, Iraq.

Materials and methods

Samples and microscopic examination

The study depended on collecting 20 larvae (at different stages) from 20 local sheep. The samples were different stages of larvae from the nasal cavities of sheep after slaughtering. They were collected by using forceps gently and putting in tubes, washed using physiological saline, and moved directly to the parasitology laboratory in the College of Veterinary Medicine, University of Al-Qadisiyah, for morphological diagnosis. The morphological examination was done using a stereomicroscope and relying on larval characteristic features, including the posterior end, spiracles, and cephalopharyngeal skeleton. The examination was performed using criteria from Al-Amura *et al.* (17).

DNA extraction

Initially, approximately 20mg of the larval tissue was placed in individual Eppendorf tubes to be lysed and extracted using DNA extraction kit (ADDBIO, Korea). Per the instructions of the kit, 200µl/tube of lysis solution and 20µl/tube of proteinase k (20 mg/ml) added. Pestle-based homogenization was used to disrupt the tissues in the tubes, which then incubated at 56c for 3hrs for complete lysis. Then, the tubes were centrifuged at 5000rpm for 2mins. The rest steps of the kit were then done. The concentration and purity of the extracted DNA were measured using a NanoDrop.

Polymerase chain reaction

The molecular characterization was performed utilizing a Semi-nested PCR method of *cox1* gene at 700-bp and 300-bp regions. The protocol was adopted from Ipek and Altan (18) as a semi-nested PCR using, for the 700-bp-region, UEA7 (5' TACAGTTGGAATAGACGTTGATAC 3') as a forward oligo (0.5pmol/20µl) and UEA10 (5' TCCAATGCACTAATCTGCCATATTA 3') as a reverse oligo (0.5pmol/20µl). The master mix (ADDBIO, Korea) and the DNA sample were placed together. The thermocycler conditions were 95°C-5min initial denaturation, 34-cycles of (95°C-40s-denaturation, 57.7°C-

30s-annealing, and 72°C-40s-extension), and 72°C-5min-final extension. For the second-round amplification, an internal forward primer (UEA9) (5' GTA AAC CTA ACA TTT TTT CCT CAA CA 3') was employed utilizing the same exact conditions of round-1; however, the annealing step was 60°C applied on 1µl DNA sample from round-1 amplicons.

Partial *cox1* Gene Sequencing

PGS method of the *cox1* gene at 700-bp and 300-bp regions was performed using the PCR products purified from the agarose gel.

Results

Morphological outcomes

Morphologically, the first-stage larvae (L1) showed characteristic mouth hooks (Figure 1a). While the second-stage larvae (L2) revealed clear terminal stigmas (Figure 1b). For the third-stage larvae (L3), the color of body segments and their spines' were the most important features for this larval stage (Figure 2).

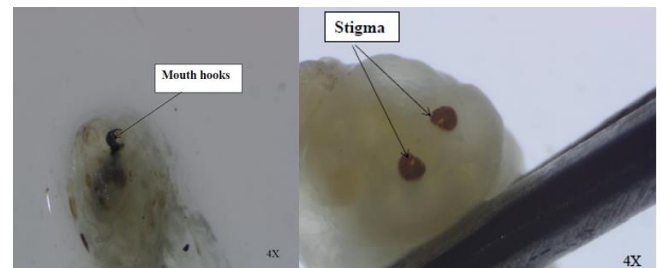


Figure 1: (a) Ventral view of the first stage larvae (L1) of *Oestrus ovis*, note the mouth hooks, (b) dorsal view of second stage larvae (L2) of *Oestrus ovis*, note the terminal stigmas indicated by the arrows, 40x.




Figure 2. Dorsal view of the third-stage larvae (L3) of *Oestrus ovis*, note the color of the body segments and spines covering it.

Molecular outcomes: PCR

The PCR showed amplification at both regions 700bp and 300bp, in 8 and 7 isolates, respectively (Figure 3).

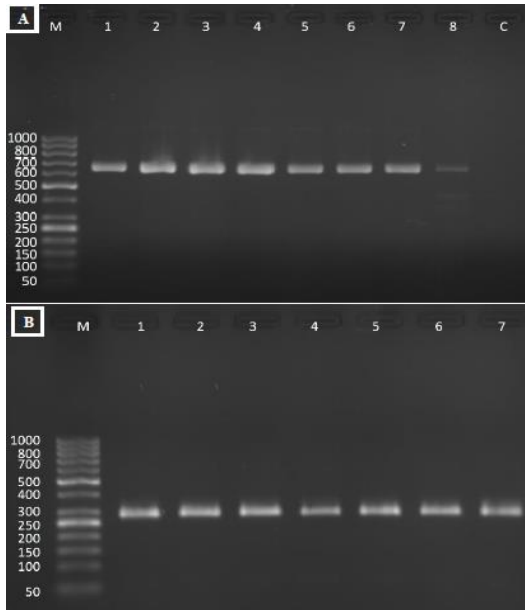


Figure 3: Gel electrophoresis image (1 % agarose) of *Oestrus ovis* targeting *cox1* gene. It shows; A. Amplicons at (about 700 bp) generated from the PCR-round-1. One to 8 are positive samples while C is the negative control. B. Amplicons at (about 300 bp) from the PCR-round-2. One to 7 are the positive samples. M is a molecular marker (Intron, Korea).

PGS

The PGS revealed 15 different local isolates that were genetically aligned with isolates from Kyrgyzstan, Italy, Spain, and Turkey (Figure 4).

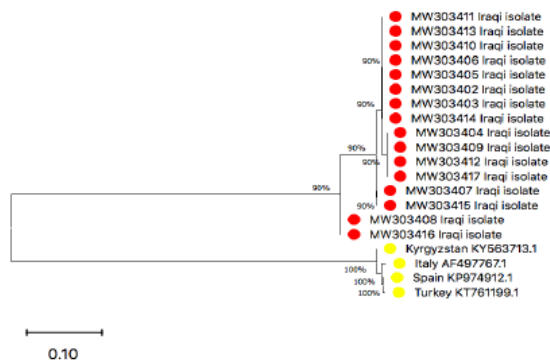


Figure 4: *cox1*-based phylogenetic tree of *Oestrus ovis* (red-circled current local and yellow-circled global-NCBI isolates). All these strains are genetically aligned with isolates from Kyrgyzstan, Italy, Spain, and Turkey.

Discussion

Oestrosis in sheep, is caused by the nasal bot larvae (*Oestrus ovis*), which is obligatory myiasis of sheep and goat nasal cavities. The larva is of a major-world prevalence (16); in many geographical regions, oestrosis highly prevalent, factors that contribute to the prevalence estimate of this larvae need to be emphasized in any survey to estimate the true prevalence of this infection, and to improve the health, welfare status and to reduce the burden of oestrosis in sheep and goat, this need for immunization or implementation of other preventive measures (16). Sneezing and nasal discharge are the major clinical signs in infected sheep with trauma due to mechanical action of spine and hooks during larval movement on mucosal membranes, allergic reaction provoke by larval secretion which recognized by sheep immune system, humoral response usually reaches seroconversion 2-4 weeks post first infection (19). Mohammed *et al.* (4) found that the nasal waste, nasal entries, muco - purulent myiasis of frontal sinuses, thinning visit sniffing and dyspnea are the clinical side effects of the movement of hatching in the nasal sinus gaps, during they study the prevalence of *O. ovis* in sheep in Misan city, Iraq. However, less is understood about the current prevalence and larval evolution in Iraq including Al-Qadisiyah Province.

The identification of the larvae can be made using the morphological characteristics expressed by these worms. Here, the current study was able to recognize them using these features. The study matches this capability with the results of other studies. The results are close to those from Saudi Arabia that identified the larvae in sheep in the Jazan region (20). The author revealed the larvae's identity and species using the morphological and PCR techniques, respectively, targeting a 606bp-region that belongs to the cytochrome oxidase subunit I gene (20). Bosly (20) also performed a partial gene sequencing to the same region of the gene and found 97%-close similarity with an NCBI-GeneBank isolate. The risk of *O. ovis* larvae according to the abundance in Jazan region and the impact of climate on the infestation, and the importance of controlling the sheep infestation which should be in the beginning of the winter season and for complete prevention, a seasonal treatment in April, is suggested, and every effort should be made to control them by sanitary measures and tools for the pest management (13). İpek and Altan (18) morphologically-noticed the larvae's presence in 38.5% of goats and 84.2% of sheep in Turkey. They also used semi-nested PCR for ~700bp and ~300bp regions of the *cox1* gene. İpek and Altan (18) found that the sequences from their sample larvae were 99% close in similarity to Italian NCBI isolates of the *O. ovis*, generally they refer to the 2 - step PCR assay described here achieved 100% diagnostic sensitivity and specificity for oestrosis, and the semi-nested PCR and rhinoscopic examination for oestrosis are novel and

promising approaches for ante-mortem diagnosis and for future field studies of this parasite.

In results of İpek and Altan (18), the two-round PCR technique revealed a full sensitivity and specificity for the larval diagnosis. They reported higher diagnostic degrees than those recorded by other studies that used the same PCR method. The current study also has the same full-diagnostic power reported by İpek and Altan (18). The similarity of the current isolates from the present work with the isolates from Kyrgyzstan, Italy, Spain, and Turkey can be explained to some degree due to the moving animals and the flies between countries. It's necessary to know when the parasitic period occurs in order to prevent the clinical signs and economic losses caused by *O. ovis* infection, this knowledge will be a valuable tool to help in choosing the right treatment at the right period (21-25).

Conclusion

This study shows the important strain differences of *O. ovis* that infect the local sheep in Al-Qadisiyah province, Iraq.

Acknowledgments

The authors thank College of Veterinary Medicine, University of Al-Qadisiyah, Iraq, for technical assistance.

Conflict of interests

The authors have not received any funding or benefits from industry, agency of financing, or elsewhere to conduct this study.

References

- Alani ABJ, Al-Kennany ER, Al-Ubeidi NH. Rearing and measurements of *Oestrus ovis* larvae and pupae (Diptera: Oestridae) from slaughtered sheep heads in Mosul abattoir -Iraq. Iraqi J Vet Sci. 2018;32(1):21-25. DOI: [10.33899/ijvs.2018.153789](https://doi.org/10.33899/ijvs.2018.153789)
- Allaie IM, Wani ZA, Malik AH, Shahardar RA, Zulhuma M. *Oestrus ovis* larvae in nasal cavity of sheep: a case report. J Parasit Dis. 2016;40(4):1221-2. DOI: [10.1007/s12639-015-0655-3](https://doi.org/10.1007/s12639-015-0655-3)
- Gomez-Puerta LA, Alroy KA, Ticona DS, Lopez-Urbina MT, Gonzalez AE. A case of nasal myiasis due to *Oestrus ovis* (Diptera: Oestridae) in a llama (*Lama glama*). Rev Bras Parasitol Vet. 2013;22(4):608-10. DOI: [10.1590/S1984-29612013000400026](https://doi.org/10.1590/S1984-29612013000400026)
- Mohammed RG, Josef SS, Abed KJ. Prevalence of *Oestrus ovis* larvae in slaughtered sheep of Misan City, Iraq. Sys Rev Pharm. 2020;11(4):652-655. DOI: [10.31838/srp.2020.4.96](https://doi.org/10.31838/srp.2020.4.96)
- Fonseca O, Moya VM, Montano D de las N, Centelles Y, Percedo MI, Alfonso P. Spatial modeling of oestrosis in sheep in Guantánamo province, Cuba. Small Rumin Res. 2018;164(5):32-8. DOI: [10.1016/j.smallrumres.2018.05.001](https://doi.org/10.1016/j.smallrumres.2018.05.001)
- Madhu DN, Sudhakar NR, Maurya PS, Manjunathachar H V, Sahu S, Pawde AM. Nasal oestrosis in a jamunapari goat. J Parasit Dis. 2014;38(4):396-8. DOI: [10.1007/s12639-013-0265-x](https://doi.org/10.1007/s12639-013-0265-x)
- Sucilathangam G, Meenakshisundaram A, Hariramasubramanian S, Anandhi D, Palaniappan N, Anna T. External ophthalmomyiasis which was caused by sheep botfly (*Oestrus ovis*) larva: A report of 10 cases. J Clin Diagnostic Res. 2013;7(3):539-42. DOI: [10.7860/JCDR/2013/4749.2817](https://doi.org/10.7860/JCDR/2013/4749.2817)
- Hoyer P, Williams RR, Lopez M, Cabada MM. Human nasal myiasis caused by *Oestrus ovis* in the Highlands of Cusco, Peru: Report of a Case and Review of the Literature. Case Rep Infect Dis. 2016;1(12):1-4. DOI: [10.1155/2016/2456735](https://doi.org/10.1155/2016/2456735)
- Fasih N, Qaiser KN, Bokhari SA, Jamil B, Beg MA. Human ophthalmomyiasis externa caused by the sheep botfly *Oestrus ovis*: A case report from Karachi, Pakistan. Asian Pac J Trop Biomed. 2014;4(10):835-7. DOI: [10.12980/APJTB.4.2014C901](https://doi.org/10.12980/APJTB.4.2014C901)
- Sánchez A, Caparrós N, Ostrowski S, Sarasa M, Pérez JM. Oestrosis in Asiatic ibex (*Capra sibirica*): a case report and molecular characterization of larvae. Vet Parasitol. 2017;236(3):55-7. DOI: [10.1016/j.vetpar.2017.02.003](https://doi.org/10.1016/j.vetpar.2017.02.003)
- Ortega-Muñoz G, Luzuriaga-Neira N, Salazar-Silva R, Rodríguez-Hidalgo R. *Oestrus ovis* in Ecuador: Importance in the Andean sheep farming. Vet World. 2019;12(4):522-6. DOI: [10.14202/vetworld.2019.522-526](https://doi.org/10.14202/vetworld.2019.522-526)
- Silva BF da, Machado GP, Izidoro TB, Amarante AFT do. Prevalence of *Oestrus ovis* (Diptera: Oestridae) in sheep from the São Paulo Central region, Brazil. Rev Bras Parasitol Veterinária. 2013;22(1):18-21. DOI: [10.1590/S1984-29612013005000011](https://doi.org/10.1590/S1984-29612013005000011)
- Bosly AH. Seasonal prevalence of *Oestrus ovis* L. (Diptera: Oestridae) larvae in inested sheep in Jazan Region, Saudi Arabia. J of Parasitol and Vec Biol. 2013;5(5):66-71. DOI: [10.5897/JPVB2013.0112](https://doi.org/10.5897/JPVB2013.0112)
- Papadopoulos E, Prevot F, Jacquet P, Duranton C, Bergeaud JP, Kalaitzakis E, Dorchie P. Seasonal variation of *Oestrus ovis* -specific antibodies in sheep and goats mixed flocks in Greece. Vet Parasitol. 2001;95(1):73-7. DOI: [10.1016/s0304-4017\(00\)00414-3](https://doi.org/10.1016/s0304-4017(00)00414-3)
- Benakha A, Sedraoui S, Benouareth DE, Cabaret J, Boulard C. Epidemiology of sheep infection by *Oestrus ovis* in Algeria. Parasite. 2004;11(2):235-8. DOI: [10.1051/parasite/2004112235](https://doi.org/10.1051/parasite/2004112235)
- Ahaduzzaman M. The global and regional prevalence of oestrosis in sheep and goats: A systematic review of articles and meta-analysis. Parasit Vect. 2019;12(7):346. DOI: [10.1186/s13071-019-3597-2](https://doi.org/10.1186/s13071-019-3597-2)
- AL-Amura M. Polymorphism larval stages of *Oestrus ovis* isolated from frontal sinuses and horn cavities of sheep's head Slay in Basrah abattoir. Al-Qadisiya J Vet Med Sci. 2010;13(2):104-11. DOI: [10.29079/vol9iss3art129](https://doi.org/10.29079/vol9iss3art129)
- İpek DNS, Altan S. Use of semi-nested PCR and rhinoscopy for the diagnosis of oestrosis. Small Rumin Res. 2017;150(5):76-9. DOI: [10.1016/j.smallrumres.2017.03.006](https://doi.org/10.1016/j.smallrumres.2017.03.006)
- Angulo-Valadez CE, Ascencio F, Jacquet P, Dorchie P and Cepeda-Palacios R. Sheep and goat immune responses to nose bot infestation: a review. Med and Vet Entomol. 2010;25(2):117-125. DOI: [10.1111/j.1365-2915.2010.00911.x](https://doi.org/10.1111/j.1365-2915.2010.00911.x)
- Bosly AH. Molecular identification studies on *Oestrus ovis* L. (Diptera: Oestridae) larvae infested sheep in jazan region, Saudi Arabia. Indian J Anim Res. 2018;52(1):105-10. DOI: [10.18805/ijar.v0i0F.8487](https://doi.org/10.18805/ijar.v0i0F.8487)
- Tabouret G, Jacquet P, Scholl P and Dorchie P. *Oestrus ovis* in sheep: relative third-instar populations, risks of infection and parasitic control. Vet Res. 2001;32(6):525-31. DOI: [10.1051/vetres:2001144](https://doi.org/10.1051/vetres:2001144)
- Ali MJ, Karawan AC, Al-Fetly DR, ALfatlawi MAA. Synergizing the deltamethrin larvicidal activity against *Aedes albopictus* larvae using cinnamaldehyde in Diwaniyah, Iraq. Iraqi J Vet Sci. 2020; 34(2): 317-320. DOI: [10.33899/ijvs.2019.126026.1212](https://doi.org/10.33899/ijvs.2019.126026.1212)
- Alfatlawi MA, Ismail YK, Ali MJ, Karawan AC, Ibadi IN. Molecular differentiation of *Thysaniezia* (*Helictometra*) *giardi* and *Moniezia* species based on 18s rRNA gene in small ruminants. Iraqi J Vet Sci. 2021; 35(1): 105-108. DOI: [10.33899/ijvs.2020.126407.1313](https://doi.org/10.33899/ijvs.2020.126407.1313)
- ALfatlawi MAA, Ali M, Naser H. Molecular identification of allelic genotypes of pyrethroid-insecticide resistance in housefly, Iraq. Iraqi J Vet Sci. 2019; 33(2): 209-212. DOI: [10.33899/ijvs.2019.125538.1060](https://doi.org/10.33899/ijvs.2019.125538.1060)
- Alfatlawi MA, Jasim AA, Jarad NE, Khlaif SF. Clinical and molecular identification of ruling *Theileria annulata* strains in cattle calves in Al-Diwaniyah province, Iraq. Iraqi J Vet Sci. 2021; 35(1): 115-119. DOI: [10.33899/ijvs.2020.126429.1319](https://doi.org/10.33899/ijvs.2020.126429.1319)

مظهرياً وجزيئياً والتي تم جمعها من الأغنام في مسلخ في محافظة القادسية، العراق. اعتمدت الدراسة على جمع ٢٠ يرقة (في مراحل يرقية مختلفة) من ٢٠ خروفا للفترة من ١٥ تشرين الأول ولغاية ١٧ كانون الأول لعام ٢٠٢٠. تم إجراء الفحص المظهري باستخدام المجهر وبالاعتماد على خصائص اليرقات المميزة، بما في ذلك النهاية الخلفية، الفتحات التنفسية، والهيكلي العنقي البلعومي. تم إجراء التوصيف الجزيئي باستخدام طرق تفاعل البلمرة المتسلسل ودراسة تعاقب القواعد النيتروجينية للجين *cox1* والتي استهدفت مضاعفة نسخ الجين في قطع طولها ٧٠٠ زوج قواعد و ٣٠٠ زوج قواعد. من الناحية المظهرية، أظهرت يرقات المرحلة الأولى خطافات فموية مميزة بينما أظهرت يرقات المرحلة الثانية وصمات نهائية واضحة. بالنسبة ليرقات المرحلة الثالثة كان لون أجزاء الجسم ووجود أشواكها من أهم سمات هذه المرحلة اليرقية. أظهر تفاعل السلسلة المتبلرة تضخيماً في كلا المنطقتين ٧٠٠ و ٣٠٠ زوج قواعد في ٨ و ٧ عزلات على التوالي. كشفت دراسة التسلسل الجيني الجزيئي عن ١٥ عزلة محلية مختلفة كانت متوافقة وراثياً مع عزلات من قيرغيزستان وإيطاليا وإسبانيا وتركيا. توضح هذه الدراسة الفروق المهمة لسلاسل النغف البقري التي تؤثر على الأغنام المحلية في محافظة القادسية، العراق.

الصفات الشكلية والجينية ليرقة نغف الأنف في الأغنام في محافظة القادسية العراق

نادية سلطان الحياي^١، مهند عبد الحمزة حسين السعداوي^٢، منير عبد الأمير عبد الفتاوي^٣ و منصور جدعان علي^٢

^١ فرع الأحياء المجهرية، كلية الطب البيطري، جامعة الموصل، الموصل، ^٢ فرع الطفيليات، كلية الطب البيطري، جامعة المثنى، المثنى، ^٣ فرع الأحياء المجهرية البيطرية، كلية الطب البيطري، جامعة القادسية، الديوانية، العراق.

الخلاصة

تصيب يرقات الذباب التجاويف الأنفية والجيوب الأنفية (الأمامية والفكية) للأغنام والماعز ومجموعة من الحيوانات المجترة البرية، وتسبب مرضاً يسمى نغف الأنف ولهذا المرض أهمية كبيرة بالنسبة لتربية المجترات الصغيرة في العراق الذي يتسبب في خسائر اقتصادية كبيرة. تم تنفيذ العمل الحالي لتوصيف يرقات طفيلي النغف البقري

