

A TRAINING PROGRAM FOR UPPER LIMB INJURIES FOR HANDBALL PLAYERS

Dr. Nassr Khalid Abdulrazzaq
Al Anbar University

ABSTRACT

To concentrate the handball player's upper appendage injuries and investigate potential reasons for injuries as it identifies with the handball players. A review of the handball players is portrayed as far as its capability to bring about the as often as possible noted injuries. Most injuries happen at effect when the handball players play sport. This paper presumes that more research into handball player's upper appendage injuries is required to build up an intensive comprehension of how injuries happen. Sorts of research incorporate the study of disease transmission considers, kinematic swing examination and electromyographic investigations of the upper appendage amid handball. By directing such research, precaution measures perhaps created to decrease handball related injuries.

Keywords: Electromyographic, Handball Players, Upper Limb Injuries.

INTRODUCTION:

The handball players grumbled of extreme agony in the correct upper appendage. The correct upper appendage, proximal piece of the correct arm, and the privilege distal lower arm were swollen and delicate with a discernable crepitus. There was a 3-cm gash over the front part of the correct upper appendage. The hand was very much perfused (red and warm). Distal neurovascular status was ordinary. Heartbeats could be felt at outspread and ulnar nerves. Development of fingers and thumb was exact. Roentgenograms exhibited a dislodged break at the proximal humeral metaphyseal-diaphyseal intersection, with an augmentation) supracondylar humeral fracture with a Salter-Harris sort II physeal harm of the distal lower arm. All injuries were found in the correct upper appendage. His furthest point was propped utilizing a Cramer wire brace amplifying appropriate from the tip of the shoulder to the fingertips, and a sleeve and neckline gauze was connected.

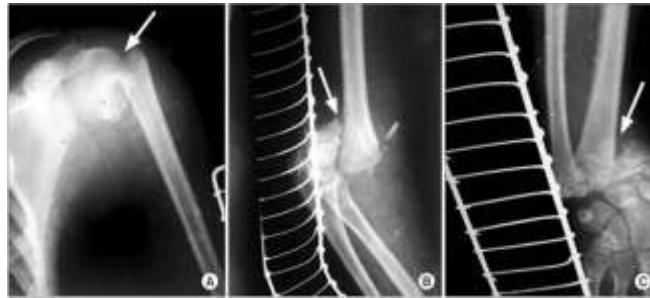


Figure 1: Floating upper limb.

Under general anesthesia, debridement of the Gustilo-Anderson sort II open supracondylar break of the humerus was done, and it was bounteously watered with typical saline. Open decrease of the break was finished. Decrease was balanced out utilizing 2 horizontal Kirschner wires. Next, under fluoroscopic control, shut decrease of the proximal humeral facture was done utilizing a brief Kirschner wire. The Kirschner wire was driven from horizontal to average in the humeral shaft and utilized as a joystick. Lessening was balanced out utilizing 2 Kirschner wires. Finally, shut diminishment of the distal lower arm injuries was done, and the spiral physeal harm was balanced out utilizing 2 horizontal Kirschner wires. All the Kirschner wires were left distending from the skin and secured with a sterile dressing. After finishing of the surgical method, a long mortar of Paris support amplifying appropriate from the tip of the shoulder to the fingertips was connected, and an arm pocket was given.

The injury over the upper appendage mended uneventfully and deferred essential conclusion was finished. The Kirschner wires were evacuated 4 weeks after radiological affirmation of recuperating or gathering. It took right around a month and a half for gathering to be watched. A brace was given to bolster the hand and lower arm development, which was trailed by scope of movement activities that began 1 week after the utilization of the prop bolster. A 6-month follow-up was planned. The patient accomplished a full wrist, upper appendage augmentation/flexion of 0° – 130° and pronation/supination, and typical shoulder scope of movement when measured with a hand-held goniometer, and had no practical shortages.

Wrist/Hand injuries

The wrist is a standout amongst the most widely recognized locales of harm in handball players. The wrist represents 13–20% of all injuries in beginners and 20–27% of all injuries in professionals in handball players harm the study of disease transmission thinks about. Amid the handball swing, the wrist is the grapple point between the club and the body. This outcomes in the wrist showing an expansive scope of movement. Wrist injuries generally happen at the effect purpose of the handball swing and may come about because of hitting a question other than the ball. The harm is the aftereffect of the sudden change in load connected to the club, and therefore the handballer, bringing about tissue disturbance to the hands and wrist. This usually happens in beginners because of hitting the ball "fat" (i.e., hitting the ground before the ball). Professionals additionally support wrist injuries however these injuries more often than not happen in somewhat extraordinary conditions.

The expert (or novice) may hit a clouded shake while playing from 'the harsh' (longer grass that outskirts the shorter grass of the fairway, the focal territory that is desirable over hit from). In many real competitions, especially "joins" courses generally found in the United Kingdom, the unpleasant has a tendency to be thick. While endeavoring to remove the ball, the long strands of grass tend to wrap themselves around the hosel (that piece of the club that joins the pole to the club head) and shaft of the club. This outcomes in a comparative deceleration of the club head amid the downswing as hitting the ground, which fits harm. Harm might be either intense where enough constrain is created to bring about inordinate delicate tissue lengthening in a solitary swing, or by method for dreary microtrauma if rehashed commonly in a short time span. injuries of this nature have a tendency to happen at the hand and wrist yet can likewise happen at the upper appendage. Solid strains (especially the flexor carpi ulnaris [FCU]) and ligamentous strains are normal, however factures of the snare of hamate may likewise happen because of this component.

Abuse injuries to the wrist are likewise normal and are expected fundamentally to redundant wrist development amid practice or from modification to the swing that outcomes in worry to unaccustomed territories. As indicated by an investigation of the Spain National Insurance Scheme for sportsmen, 10% of handball injuries happen in the wrist. This is in opposition to the measurements created in handball the study of disease transmission considers. An explanation behind this distinction could contrast meanings of what a injuries is in each review. The Spanish review found that

abuse or sudden changes in swing were the basic injuries instruments, and the FCU was the most widely recognized site of harm.

At least tendonopathy particularly tendonosis has supplanted tendonitis as the clinical descriptor of the abuse disorder. The essential purpose behind this change is because of the dominant part of abuse tendonopathies showing collagen degeneration and fiber confusion. Nonetheless they don't show the nearness of incendiary cells, subsequently the "itis" is erroneous. The harm component is either a sudden increment in the volume of practice or adjustment of the grasp (bringing about expanded stacking on an unaccustomed piece of the wrist), and after that resulting practice. Onset of the torment is continuous. It has a tendency to have a steady nature until any irritating factor(s) are altered or sufficient repair (mending) time passes.

The FCU of the correct wrist in right-gave handball players is powerless against injuries from microtrauma because of the huge powers created by the swing only preceding effect. This is especially genuine when handball players take divots. As the club hits the ground, a sudden resistance happens that heaps the flexor ligament. On the off chance that the strengths are sufficiently extraordinary microtrauma can happen, which consolidated with reiteration through practice may prompt injuries. injuries to the FCU brings about agony at the proximal outskirt of the trapezium and is expanded with wrist flexion.

Within the sight of a broken swing style, the learner is likewise powerless to extensor carpi ulnaris (ECU) injuries. Generally, the amateur "throws" the club in the early downswing (the early uncocking of the wrist amid the downswing and a wellspring of lost power and control), which stacks the ECU. Amateurs are regularly overenthusiastic in their practice in an attempt to enhance their diversion. This may bring about tedious stacking, microtrauma and injuries to the ECU. An indication of ECU harm incorporates ulnar wrist torment with delicacy of the dorsal base of the ulnar styloid where the ECU goes through the 6th dorsal compartment. There is regularly torment on opposed supination and on ulnar deviation in this example.

An extraordinary harm found in handball players is a break to the snare of hamate. Hamate factures might be intense in nature because of the impingement of the hamate between the hand and the butt end of the club, prompting a break in the main hand . The writing records intense hamate factures in handball players as right on time as 1972. Stretch breaks of the hamate may likewise happen because of a sudden change in grasp situating or quality with going with over the top practice. The ulnar fringe of the wrist is the site of torment for hamate breaks, with hamate delicacy and positive percussion being a sign for imaging. Mind must be taken, be that as it may, as x-beams may at first not uncover the break. Bone outputs or MR imaging will demonstrate the facture.

Other irregular handball-related injuries to the wrist and encompassing structures have likewise been accounted for in the writing. These incorporate an instance of a novice handball player with a pressure neuropathy of the middle nerve in the correct palm because of mechanical pressure of the middle nerve in the correct palm by the leader of the primary metacarpal bone of the left hand. Extensor carpi ulnaris (ECU) ligament separation over the ulnar dorsal edge of the ulnar head exasperated by intemperate practice has likewise been accounted for. This case was settled by extensor retinaculum discharge and incomplete ulnar head resection after preservationist treatment fizzled. The irregular "hypothenar pound disorder" has likewise been accounted for in a handball player because of the monotonous hitting of practice balls with a "flawed" hold bringing on rehashed weight on the ulnar course hidden the hypothenar distinction. This practice brought about thrombus development in the ulnar supply route. While bizarre, putting grasp changes have brought about torment to the volar outspread wrist because of a flexor carpi radialis strain. It was accounted for this was highlighted by palpation and that an arrival to the first hold with manual treatment settled the condition.

Upper limb injuries

Upper appendage injuries are basic in handball players, particularly in beginners and especially in females. This is thought to be because of the expanded conveying edge found in the female populace. Upper appendage injuries represent 25–33% of all injuries in beginners and 7–10% of all injuries in professionals. Amusingly, sidelong upper appendage injuries are more typical, at a rate of 5:1 when contrasted with average upper appendage injuries.

Average upper appendage injuries are thought to come about because of footing based affront to the upper appendage, for the most part to the trailing arm (right upper appendage in the privilege gave handball player). It is the wrist/hand flexors and lower arm pronators that are harmed at their addition into the average epicondyle. These injuries are more often than not of a traumatic sort and happen at the season of effect. The component is a sudden deceleration of the club head, prompting an expanded stacking of the average upper appendage. This can be because of hitting darkened shakes and tree roots, and in professionals attempting to hit more than once out of long and thick unpleasant. With beginners, the hitting of a "fat" shot is the more probable instrument. Indications of average epicondylitis (Handball player's upper appendage) incorporate agony and delicacy to palpation of the average epicondyle. Agony is regularly exasperated by opposed lower arm flexion and lower arm pronation. There might be trigger point referral along the spiral fringe of the lower arm into the dorsum of the hand.

injuries of the sidelong part of the upper appendage, the inclusion of the wrist/hand extensors into the horizontal epicondyle, will probably be because of abuse. Holding the club too firmly amid the swing (bringing about related extensor flighty constriction) or changes to the grasp with consequent practice (frequently weariness based) may bring about changes in lower arm musculature constrains and are conceivably a wellspring of parallel epicondylitis. Indications of parallel epicondylitis incorporate torment and delicacy to palpation of the sidelong epicondyle. Agony is frequently bothered by opposed lower arm augmentation and on events grasping items or shaking hands. There might be trigger point referral along the ulnar outskirts of the lower arm into the palmar part of the hand.

Unnecessary practice may likewise bring about harm to the sidelong upper appendage. The vast increment in flexor action only before effect, the 'flexor burst' joined by the quick wrist development in the meantime puts a huge weight on the upper appendage joint and may bring about harm because of gathering infinitesimal injuries.

Despite the fact that the upper appendage is a typical injuries site in handball players, little research has been led here. The vast majority of the upper appendage injuries components and administration arrangements depend on racquet sports related injuries. Examine concentrating on the mechanics of the upper appendage and related musculature would take into consideration the exact etiology of handball-related upper appendage injuries to be resolved. Seeing how these injuries happen in handball players would guarantee the improvement of fitting administration methodologies focusing on handball particular harm components.

Shoulder injuries

Sholder painin handball players is a generally normal event contrasted with different locales of the body, representing around 8–18% of all handball injuries. The shoulder experiences a vast ROM amid the handball swing including an extensive level of left shoulder flat adduction and right shoulder outside revolution in the backswing. In the complete, there is a vast level of left shoulder outside pivot and flat snatching and right shoulder even adduction. Thus, extreme practice can create issues of the shoulder because of abuse.

injuries to the shoulder in handball players are basically limited to the lead bear, the left shoulder in right-gave handball players. Contemplates have found that shoulder torment might be restricted to the acromioclavicular (AC) joint, with the potential for either osteoarthritis or distal clavicle osteolysis (which suggests flat plane pressure stacking of the joint). A moment concentrate found that back unsteadiness and subacromial impingement were basic discoveries in handball players with shoulder torment. This agony and unsteadiness were repeated at the highest point of the backswing (maximal flat adduction). Already, Bell found that maximal strengths about the AC joint happened in even kidnapping and adduction. Comparable positions are achieved by the arm at the highest point of the back swing (left arm level adduction) and toward the finish of the complete (left arm even kidnapping), which accentuates the potential for harm to the AC joint by unnecessary practice of the handball swing.

The practitioner ought to learn the period of the handball swing that creates the patients bear torment; this may encourage the analysis. Back shoulder torment in the left shoulder of a privilege gave handball player at the highest point of the backswing ought to caution the clinician to snugness of the rotator sleeve musculature, snugness of the back case, or back capsulitis. Foremost joint line torment at the highest point of the backswing suggests

impingement of the humeral head and front labrum, while torment restricted to the AC joint demonstrates conceivable degeneration or impingement of the ACL joint.

The complete period of the swing may create back shoulder torment because of impingement of either the back labrum or the underside of the rotator sleeve muscles. Bear torment that is summed up and happens all through the swing might be because of scapular slack, which modifies the mechanics of the shoulder amid the swing.

An investigation of handball players who experienced shoulder arthroplasty and could come back to handball, found that the correct shoulder was worked on more every now and again (14 out of 26). Nonetheless, this review made no say of the reason for the patients bear torment. The review additionally got some information about their supposition of the patient coming back to handball after arthroplasty. Out of 44 respondents, 91% urged an arrival to play. This overview demonstrated that shoulder arthroplasty does not really disallow an arrival to handball .

It is significant that an absence of trunk pivot may require the considerably littler shoulder rotators to wind up noticeably exorbitantly dynamic to keep up the force of the handball swing. Such a situation would likely outcome in the shoulder brokenness as often as possible noted in handball players, especially insecurity in professionals. It is additionally qualified to note that those with back issues may possibly instigate a shoulder issue in their endeavor to diminish the heaps on a difficult back. Baulbian noted comparative perceptions in his examination on an adjusted handball swing where the back swing is abbreviated. This exploration revealed that the powers produced in the lower back were decreased by this swing, however the strengths created in the shoulder were more noteworthy. This outcomes in the potential for this swing to deliver bear injuries that possibly the aftereffect of impingement, insecurity or rotator sleeve tendonopathy. Torment area and shoulder orthopedic testing separates between each clinical substance, however MRI is required to give an authoritative analysis.

PARTICIPANT

We enlisted all participants between March 2016 and March 2017 and finished all subsequent evaluations by June 2016. The stream of participants through the trial, demonstrates benchmark qualities of the review test by gathering. The participants were very much coordinated for statistic and clinical attributes.

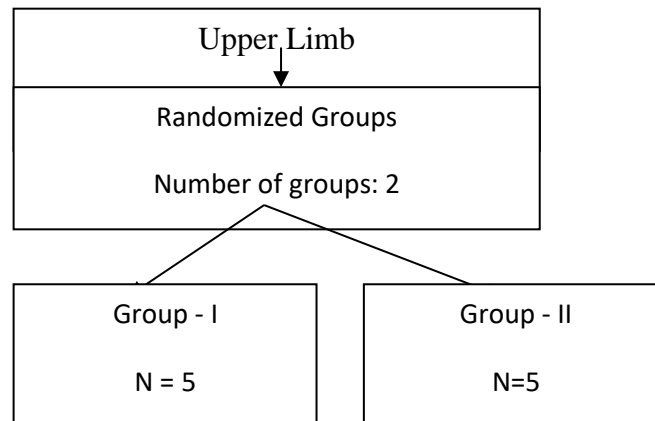


Figure 2: Participants Flow Diagram

RESULT ANALYSIS:

Table 4.1: Baseline qualities for the keep a watch out, corticosteroid, and physiotherapy bunches practices and the aggregate review populace. Qualities are numbers (rates) unless expressed generally.

Characteristics	Group-I (n=5)	Group-II (n=5)	Total (n=10)
Mean (SD) age (years)	27.3	27.9	27.6
Median (interquartile range) duration (weeks)	26	16	22
Dominant upper limb affected	42	42	133
Previous episodes of lateral upper limb pain	22	14	55
Overuse, usual activities	4	2	8
Overuse, unusual activities	8	18	38
Other (such as sport, unexpected movement)	16	12	39
Mean (SD) pain-free grip force ratio	48.0	42.4 (20.8)	42.9
Mean (SD) assessor rating of severity (/100)	51.9	51.6 (19.3)	53.8
Mean (SD) pain severity in previous week (/100)	61.3	57.5 (25.0)	57.5
Mean (SD) pain free function questionnaire (/100)	76.7	75.4	77.6

- * Affected side/unaffected side x100.

PRIMARY END POINTS

Participants' characteristics, (for example, sex and term of indications) and result measures taken at benchmark did not essentially impact the dichotomous and nonstop measures after some time; we hence show unadjusted information. Critical time by gathering connections for all result measures happened in the omnibus examination.

Table 4.2 demonstrates the result information, and table 4.3 demonstrates the total occasion rates, relative hazard diminishments, and numbers expected to treat.

We discovered noteworthy contrasts for all essential result measures at a month and a half that favored infusion over keep a watch out; 51/65 (78%) participants revealed accomplishment with infusions contrasted and 16/60 (27%) with sit back and watch (relative hazard decrease 0.7, 99% certainty interim 0.4 to 0.9), speaking to a number expected to treat of 2. Infusion was likewise better than physiotherapy on all result measures aside from worldwide change (0.4, -0.2 to 0.9); 41/63 (65%) participants detailed accomplishment at a month and a half with physiotherapy (fig 4.2, table 4.3). At 52 weeks' development, the infusion bunch participants were essentially more awful on all results contrasted and the physiotherapy gather (0.3, 0.1 to 0.5; number expected to treat = 4) and on two out of three measures contrasted and sit back and watch (0.3, 0.04 to 0.4; 4).

Table 4.2: Mean (SD) scores and area under the curve (AUC) for continuous outcome measures and mean difference (99% confidence intervals) between groups at 3, 6, 12, 26, and 52 weeks

DURATION	Group – I (n=5)	Group – II (n=5)
3 weeks	46.2 (22.1)	54.5 (24.4)
6 weeks	51.8 (23.0)	70.2 (25.4)
12 weeks	72.1 (23.0)	80.8 (22.6)
26 weeks	86.5 (20.2)	96.3 (29.9)
52 weeks	96.5 (18.5)	100.9 (30.9)
AUC	1743 (960)	2278 (1269)
3 weeks	52.9 (17.9)	42.2 (19.2)
6 weeks	44.1 (16.7)	28.1 (19.9)
12 weeks	27.4 (16.5)	17.8 (16.8)
26 weeks	17.0 (14.3)	8.3 (11.7)
52 weeks	10.3 (13.2)	5.1 (9.6)
AUC	1179 (500)	732 (544)
Global improvement (success): AUC	36.4 (12.4)	41.6 (12.8)
3 weeks	61.3 (25.3)	46.8 (26.7)
6 weeks	51.0 (26.5)	33.8 (28.2)
12 weeks	30.4 (29.4)	18.5 (21.3)
26 weeks	19.8 (24.0)	14.0 (22.1)
52 weeks	13.9 (22.6)	6.6 (14.6)
Pain free function questionnaire (/100):		
3 weeks	71.3 (25.2)	63.9 (21.0)
6 weeks	63.8 (25.4)	46.8 (29.7)
12 weeks	53.6 (31.2)	34.9 (27.5)
26 weeks	32.8 (30.2)	26.5 (28.1)
52 weeks	24.6 (29.6)	12.9(29.9)

* Positive score favours reference group (that is, first group listed in comparison).

Group – I, II performed altogether superior to anything sit back and watch at a month and a half for all result measures (for instance, achievement: 0.6, 0.2 to 0.9; number expected to treat = 3). Notwithstanding, by 52 weeks no distinction existed on any essential result measure, as most participants had either abundantly enhanced or totally recuperated (sit back and watch 56/62; physiotherapy 59/63).

Benefits

Area under the bend investigation uncovered a huge preferred standpoint for physiotherapy over infusion for all essential result measures, over sit back and watch for torment free grasp (mean contrast = 534, 99% certainty interim 3 to 1065) and assessor seriousness (447, 137 to 758), and additionally for keep a watch out over infusion for worldwide change (–8.3, –15.0 to –1.5) and assessor seriousness (–337, –642 to –32) (table 4.2, fig 4.2).

Recurrences

The corticosteroid infusion bunch had most detailed repeats; 47/65 (72%) participants crumbled following three or a month and a half. Repeats after infusion were fundamentally more noteworthy than repeats after physiotherapy (5/66, 8%; relative hazard lessening 0.9, 0.6 to 1.1) or keep a watch out (6/67, 9%; 0.9, 0.6 to 1.1), which were not essentially not quite the same as each other (relative hazard diminishment 0.2, –1.4 to 1.7).

Protocol Treatment

Wait and watch out participants (34/62, 55%) looked for fundamentally more not per convention treatment than physiotherapy participants (13/63, 21%; relative hazard lessening 0.6, 0.2 to 1.0), however close to corticosteroid infusion participants (32/65, 49%; 0.1, –0.3 to 0.5) (table 4.4). Infusion participants looked for altogether more not per convention treatment than physiotherapy participants (relative hazard lessening 0.6, 0.1 to 1.0).

Table 4.4: Additional not per protocol treatments

Additional treatment	Yogic (n=10)	Mechine(n=10)
None	28	50
GP/specialist	2	1
yesPhysiotherapy	3	1
Corticosteroid injection	1	0
Upper limb support/brace	11	2
Analgesic or NSAID	22	9
Acupuncture	2	2
Complementary medicine	13	3

- GP=general practitioner;
- NSAID=non-steroidal anti-inflammatory drug.
- * Some participants had more than one type of additional treatment.

Success of Blinding

At 52 weeks, the blinded assessor effectively speculated the distributed treatment in 101/198 (51%) cases, on the premise of the course of upper appendage protests and four participants who coincidentally uncovered their gathering portion. The assessor speculated accurately for 39/67 (58%) participants in the keep a watch out gathering, 27/65 (42%) in the infusion bunch, and 35/66 (53%) in the physiotherapy assemble. As this extent was more prominent than anticipated by possibility, we did a post hoc subgroup examination to survey the effect of the loss of blinding on result measures. We recognized no noteworthy contrast in results between the participants whose treatment assignment the assessor speculated effectively and those for whom the assessor stayed blinded.

Symptoms

A sum of 10 participants encountered an unfriendly occasion from medicines. A large portion of these were gentle, and torment after treatment was the most regularly announced reaction (5 infusion; 5 physiotherapy). Just a single member in each gathering revealed torment enduring seven days or more. Two participants revealed loss of skin shade, and one additionally had decay of subcutaneous tissue in the wake of getting the corticosteroid infusion.

CONCLUSION

The handball swing is a mind boggling body development including a vast ROM of the upper appendage that goes about as a connection between the golf club and the body. injuries to the upper appendage represent the larger part of handball-related injuries. Numerous injuries happen as the club impacts the ball and are muscle-related. A comprehension of how the body moves and the muscle action accomplished amid the handball sport assists the wellbeing expert with understanding why these injuries happen. Additionally ponder into the diverse sorts of handball game and the distinctive aptitude levels of handball players is required to completely comprehend the upper appendage work in the handball game. Such understanding may empower the advancement of administration and avoidance projects to decrease the upper appendage injuries brought on by handball.

Reference:

1. Myklebust, G., Engebretsen, L., Brækken, I. H., Skjølberg, A., Olsen, O. E., & Bahr, R. (2003). Prevention of anterior cruciate ligament injuries in female team handball players: a prospective intervention study over three seasons. *Clinical Journal of Sport Medicine*, 13(2), 71-78.
2. Olsen, O. E., Myklebust, G., Engebretsen, L., Holme, I., & Bahr, R. (2005). Exercises to prevent lower limb injuries in youth sports: cluster randomised controlled trial. *Bmj*, 330(7489), 449.
3. Olsen, O. E., Myklebust, G., Engebretsen, L., & Bahr, R. (2004). Injury mechanisms for anterior cruciate ligament injuries in team handball a systematic video analysis. *The American journal of sports medicine*, 32(4), 1002-1012.
4. Wedderkopp, N., Kaltoft, M., Lundgaard, B., Rosendahl, M., & Froberg, K. (1999). Prevention of injuries in young female players in European team handball. A prospective intervention study. *Scandinavian journal of medicine & science in sports*, 9(1), 41-47.
5. Hootman, J. M., Dick, R., & Agel, J. (2007). Epidemiology of collegiate injuries for 15 sports: summary and recommendations for injury prevention initiatives. *Journal of athletic training*, 42(2), 311.
6. Langevoort, G., Myklebust, G., Dvorak, J., & Junge, A. (2007). Handball injuries during major international tournaments. *Scandinavian journal of medicine & science in sports*, 17(4), 400-407.
7. Lo, A. C., Guarino, P. D., Richards, L. G., Haselkorn, J. K., Wittenberg, G. F., Federman, D. G., ... & Bever Jr, C. T. (2010). Robot-assisted therapy for long-term upper-limb impairment after stroke. *New England Journal of Medicine*, 362(19), 1772-1783.
8. Keating, J., Hooper, G., & Robb, J. (2012). UPPER LIMB INJURIES. *Textbook of Orthopaedics, Trauma and Rheumatology*, 140.
9. Togawa, S., Yamami, N., Nakayama, H., Mano, Y., Ikegami, K., & Ozeki, S. (2005). The validity of the mangled extremity severity score in the assessment of upper limb injuries. *Bone & Joint Journal*, 87(11), 1516-1519.
10. Bollen, S. R. (1990). Upper limb injuries in elite rock climbers. *Journal of the Royal College of Surgeons of Edinburgh*, 35(6 Suppl), S18-20.