

The Potential Effect of Simvastatin on Regulatory T cells in Experimentally Induced Autoimmune Thyroiditis in Female Rats

Yaqeen Talib Mohammed*, Nadia Hameed Mohammed**, Inam Sameh Arif*

* *Department of Pharmacology and Toxicology, College of Pharmacy, University of Mustansiriyah, Iraq.*

** *Department of Microbiology and Immunology, College of Medicine, University of Mustansiriyah, Iraq.*

Article Info:

Received Mar 2022

Accepted Apr 2023

Corresponding Author email:

dr.nadia@uomustansiriyah.edu.iq

orcid: <https://orcid.org/0000-0001-9234-3198>

DOI: <https://doi.org/10.32947/ajps.v23i4.1098>

Abstract:

Autoimmune thyroiditis also named Hashimoto's thyroiditis: is an inflammatory disorder of the thyroid gland. It is characterized by circulating antibodies to thyroid antigens, and enlargement of the gland with lymphocytic infiltration.

Regulatory T cells (Tregs), a particular subset of CD4+ T cells that express CD25 at a markedly increased level. they can regulate immune response in order to preserve homeostasis and self-tolerance. T cell expansion and cytokine production are restricted by Tregs. The development of this autoimmune disease is influenced by TGF- β 1 shortage. Management of HT is usually a symptomatic therapy that concentrates on HT's symptoms rather than its underlying cause. Statins, the lipid lowering medications have pleotropic effects. they can alter immunological reactions. Twenty-four female rats were used for this experiment divided into four groups (n=6), the disease was induced in all groups except group1 (control) where rats only received phosphate buffer saline, group 2 (induction group), group 3 received Prednisolone 2mg/kg orally for 30 days and group 4 received Simvastatin (4mg/kg) orally for 30 days too. Hashimoto's thyroiditis was induced experimentally by subcutaneous injection of porcine thyroglobulin in Freund's adjuvant emulsion (4mg/ml). Results showed an increase in Tregs and serum TGF- β level in rats treated with simvastatin.

In conclusion, simvastatin improves the number of functioning Tregs and increases TGF- β signaling to suppress the autoimmune reaction. Therefore, simvastatin can be a promising approach in the treatment of this disease.

Keywords: Autoimmune thyroiditis; Hashimoto's Thyroiditis; Statins; pleotropic effects; simvastatin; Tregs; TGF- β

تأثير عقار السمفاستاتين على الخلايا التائية المنظمة في مرض التهاب الغدة الدرقية المناعي الذاتي
المحفز في اناث الجرذان

*يقين طالب محمد، **نادية حميد محمد، *انعام سامح عارف
*كلية الصيدلة، الجامعة المستنصرية، فرع الادوية والسموم، العراق
**كلية الطب، الجامعة المستنصرية، فرع الاحياء المجهرية والمناعة، العراق

الخلاصة:

التهاب الغدة الدرقية المناعي الذاتي المسمى أيضاً التهاب الغدة الدرقية هاشيموتو. اضطراب التهابي في الغدة الدرقية. يتميز بتدفق الأجسام المضادة إلى مستضدات الغدة الدرقية، وتضخم الغدة مع تسلل الخلايا الليمفاوية. الخلايا التائية التنظيمية ذات كتلة التمايز ٢٥ هي مجموعة تنظيمية من الخلايا الليمفاوية التائية ذات كتلة التمايز ٤. هذه الخلايا التنظيمية يمكنها تنظيم

الاستجابة المناعية من أجل الحفاظ على التوازن والتسامح الذاتي حيث يتم تقييد توسع الخلايا التائية وإنتاج السيتوكينات بواسطتها. يتأثر تطور مرض المناعة الذاتية هذا بنقص عامل النمو المحول-بيتا. إن علاج هذا المرض يعتمد على إدارة الأعراض وتخفيفها بدلا من علاج المرض والتخلص من المسبب. الستاتينات هي عقاقير المخفضة للكوليسترول، لها تأثيرات متعددة الاتجاه. يمكنها تغيير التفاعلات المناعية. تم استخدام أربع وعشرين أنثى من الجرذان لهذه التجربة مقسمة إلى أربع مجموعات. تم إعطاء عقار سمفاساتين للجرذان في مجموعة العلاج وبجرعة ٤ ملغ/كج لمدة ثلاثين يوما. أظهرت النتائج أن سمفاساتين ساهم في زيادة الخلايا التائية التنظيمية وكذلك زيادة مستوى عامل النمو المحول-بيتا في مصل الدم. ختاماً، يحسن سمفاساتين عدد الخلايا التائية التنظيمية ويزيد من إشارات عامل النمو المحول- بيتا لقمع تفاعلات المناعة الذاتية. لذلك، يمكن أن يكون سمفاساتين نهجاً واعداً في علاج هذا المرض.

الكلمات المفتاحية: التهاب الغدة الدرقية المناعي الذاتي، هاشيموتو، تأثير متعدد الاتجاه، الستاتينات، سمفاساتين، الخلايا التائية التنظيمية، عامل النمو المحول-بيتا

Introduction

Autoimmune thyroiditis also named Hashimoto's thyroiditis (HT) is an inflammatory disorder of the thyroid gland that is characterized by circulating antibodies to thyroid antigens, enlargement of the gland with lymphocytic infiltration, and varying degrees of thyroid dysregulation. At the beginning, MHC class II-positive antigen-presenting cells (dendritic cells and other subclasses of macrophages), cluster in the thyroid. These cells expose naive CD4⁺ T lymphocytes to thyroid-specific autoantigens, which causes the latter to become activated and clonally expanded ⁽¹⁾. T helper type 1 (TH1) cells are specifically involved in cell mediated cytotoxicity by secreting regulatory cytokines as interleukin-12, interferon, and tumor necrosis factor α ⁽²⁾. Thyroid autoantibodies are produced as a result of interactions between antigen presenting cells, autoreactive T cells (that persist as a result of immunological tolerance breakdown or dysregulation), and B cells. Through the proliferation of lymphocyte clones and lymphoid tissue within the thyroid gland, antigen-producing B lymphocytes, cytotoxic T cells, and macrophages invade and cluster in the thyroid. Eventually, a significant loss of thyrocytes occurs ⁽³⁾.

A large number of cells have immunosuppressive properties. Among them, regulatory T cells (Tregs), a

particular subset of CD4⁺ T cells that express CD25 at a markedly increased level. They represent just 5–10% of Th lymphocytes. Tregs are able to regulate immune response in order to preserve homeostasis and self-tolerance ⁽⁴⁾.

T cell expansion and cytokine production are restricted by Tregs. By releasing immunosuppressive cytokines like IL-10 and TGF- β , they suppress the immunological response. The development of autoimmune disease is influenced by TGF- β 1 shortage. There is a strong correlation between the development of autoimmune thyroiditis and the decrease in the number or dysfunction of regulatory T cells. The reduced proportions of CD4⁺CD25⁺ T cells in autoimmune thyroiditis may be responsible for the autoimmune process and lack of immunological tolerance ⁽³⁾ TGF- β , a pleiotropic cytokine, is probably involved in a variety of physiological processes, including cell growth, differentiation, cell death, and migration ⁽⁵⁾.

This cytokine plays a variable role in the pathogenesis of Hashimoto's thyroiditis, it regulates the interaction between Th cells and thyroid-specific autoantibodies. TGF- β 1 is thought to convert CD4⁺ CD25⁻ T cells to CD4⁺ CD25⁺ forkhead box P3⁺ (FoxP3⁺) regulatory T (T_{reg}) cells. TGF- β 1 deficiency, hinders the suppressive action of Treg and this leads to autoimmunity ⁽⁶⁾.

TGF- β 1 deficit (or likely decreased production) also affects T-cell activation,

differentiation, and apoptosis, and the expression of cytokines, MHC, and cell adhesion molecules, which all have a role in the development of autoimmune illness⁽⁵⁾. Multiple ways exist through which TGF- β 1 may inhibit the activation/expansion of autoreactive cells. For instance, TGF- β 1 can inhibit the differentiation of naive CD4⁺ T-cells into their Th1 or Th2 effector cells by blocking key transcription factors necessary for polarization, namely T-bet and GATA-3. TGF- β 1 can also inhibit autoaggressive T-cell responses by preventing the maturation of antigen presenting cells.

Management of Hashimoto's thyroiditis is usually limited to reducing the symptoms of hypothyroidism and restoring normal TSH, T4 and T3 levels by levothyroxine. It is therefore a symptomatic therapy that concentrates on Hashimoto's disease symptoms rather than its underlying cause⁽⁷⁾.

Statins, lipid lowering agents. are potent HMG-CoA reductase (3-hydroxy-3-methylglutaryl coenzyme A) inhibitors. This enzyme catalyzes the process of turning mevalonate from HMG-CoA^(8,9). Since Mevalonate, a byproduct of the HMG CoA reductase activity, serves as a precursor for several other nonsteroidal isoprenoids in addition to cholesterol, inhibiting this crucial enzyme may have pleiotropic consequences⁽¹⁰⁾. There is a fair amount of evidence that statins can alter immunological reactions. These include impacts on a variety of immune cells' intimal recruitment, differentiation, proliferation, and secretory activities, primarily T cells and monocyte/macrophages⁽¹¹⁾.

Materials and methods

Table 1 shows the chemicals and medications used for this study, their companies and origin.

Table 1: chemicals and medications used for this study, their companies and origin.

Chemicals and medications	Company	Origin
Freund's Complete adjuvant	Santa Cruz biotech. Inc.	USA
Freund's incomplete adjuvant	Sigma-Aldrich	USA
Porcine thyroglobulin powder	Sigma-Aldrich	USA
Simvastatin	Baoji Guokang Biotech	China
prednisolone	Baoji Guokang Biotech	China

Reagents

Cluster of differentiation CD4 Monoclonal antibody (Elabscience. USA), CD25 (cloud-clone. China), TGF- β (Elabscience. USA)

Methods

Induction of Hashimoto's thyroiditis:

On day 0, healthy Wistar rats were subcutaneously injected with 0.4 milliliters of porcine thyroglobulin (pTg) emulsion (4 mg/ml) at various locations on their hind legs. To make the emulsion, Porcine thyroglobulin powder was dissolved in

phosphate buffer saline (2 mg/ml) Porcine thyroglobulin in phosphate buffer saline solution was emulsified with an equal volume of complete Freund's adjuvant (CFA) (1:1), it was then mixed by vortex for ten minutes until a proper emulsion was formed.

A booster dose was given on days 7, 14, and 21 following the initial immunization, using the same dosage but emulsifying the pTg solution with in incomplete Freund's adjuvant (IFA) rather than CFA^(12,13).

Animal grouping:

Twenty-four female Wistar rats weighing between 200 and 250 g and aging between 12 and 16 weeks were used. Rats were purchased from the Iraqi Center for Cancer Research and Medical Genetics and housed in suitable cages with free access to food and water at the College of Pharmacy, Mustansiriyah University. In addition to excluding pregnant rats, they were permitted to adapt for 14 days in a cycle of 12 hours of light and darkness. Animal Ethics Committee at Mustansiriyah University College of Pharmacy regulations were followed during this investigation.

Experimental autoimmune thyroiditis was induced in all the groups except (control group).

- I. Group 1 (n=6): Control group, rats received only phosphate buffer saline.
- II. Group 2 (n=6): Induction group, rats received subcutaneous porcine thyroglobulin emulsion to induce the disease.
- III. Group 3 (n=6): treatment of 30 days of oral prednisolone suspension at a dose of 2 mg/kg per day (in distilled water and 0.5 percent carboxymethyl cellulose CMC).
- IV. Group 4 (n=6): treatment group of Simvastatin was administered orally as a suspension in distilled water with 0.5 percent CMC at a dose of 4 mg/kg every day for 30 days.

Biochemical assessment:

Rats were given an intra-peritoneal injection of 50mg/kg ketamine and 10 mg/kg Xylazine at the end of the investigation to make them fully unconscious ⁽¹⁴⁾. Rat cardiac blood was drawn and allowed to stand at room temperature for 20 minutes, then placed in tubes that promote clotting and centrifuged for 15 minutes at a speed of 3000x to collect serum for the ELISA procedure to measure TGF- β . Thyroid of each rats was

extracted and kept in buffered formalin 10% for histopathological study and immunohistopathological procedure.

Histopathological assessment

In this study, “the paraffin embedded method” was used to prepare thyroid tissue for microscopic examination ⁽¹⁵⁾. This procedure required the following steps:

A. fixation of tissue samples: All samples were immediately fixed in neutral buffered formalin at 10%. At room temperature, the fixing time was about 24 hours.

B. dehydration: after fixation, samples were soaked in Ethyl alcohol in the following order:

C. Embedding: liquid paraffin is used for embedding thyroid gland tissue as blocks.

D. sectioning: paraffin blocks were sliced into 4 μ m thick sections using a microtome, then the sliced section is added to a water bath (40-45) °C

E. Staining: sections were then stained with hematoxylin and eosin after being heated at 65°C for 30 minutes. Hematoxylin is added for about (3-5) minutes then washed with distilled water. Then Eosin 1% stain is added for (1-2) minutes then washed with distilled water.

Immunohistochemical (IHC) staining for CD4 and CD25

A. Staining procedure: following the stages outlined above for histopathology block preparation, the steps listed below were carried out in accordance with the manufacturer's leaflet to prepare the blocks of samples ⁽¹⁷⁾:

- 1- Semi-automated microtome was used to cut the block into sections that were 30–40 μ m thick. Sections were then maintained in a container with 1-2 ml of 0.1M PBS.
- 2- Antigen retrieval was carried out in accordance with manufacturer recommendations.
- 3- All samples were completed with step two, and then peroxidase was added

- and incubated for 15 minutes with only simple agitation.
- 4- washing three times for 15 minutes with PBS.
- 5- A second incubation with a blocking buffer (1 % bovine serum albumin [BSA] and 10% normal serum) in Tris buffered saline [TBS]) was carried out at room temperature for 2 hours with mild agitation.
- 6- Repeating step 4.
- 7- The primary antibody was added, and it was incubated at 4 °C for an overnight duration.
- 8- Repeating step 4.
- 9- A second wash is performed using a TBS solution with 0.3 percent peroxidase for 15 minutes.
- 10- After adding the secondary antibody, the sections were incubated for an hour at room temperature.
- 11- Repeating step 4.
- 12- Another incubation was done using hematoxylin as the counterstain.
- 13- With tap water, the slides were cleaned.
- 14- The slides were covered and kept secure for subsequent examination.

B. Assessment of the staining signal: to achieve this, a light microscope equipped with a digital camera was utilized to repeatedly take random shots of slides at a 400x magnification. The following equation was used to evaluate the outcome using the IHC staining score system:

$$(Number\ of\ positive\ stained\ cells / total\ number\ of\ cells) * 100$$

C. Immunostaining Score (IS): the immunostaining was scored, according to the percentages of positive cells, as the following:

- 0, no staining
- 1, $\leq 10\%$
- 2, 10-50%
- 3, $> 50\%$

While the intensity reads were as the followings:

- 1, weak
- 2, moderate
- 3, strong, and they were multiplied to get an immunostaining score (IS).

Results

Table 2 shows the mean serum TGF- β level of the four groups measured by ELISA technique

Table 2: The effects of simvastatin on serum TGF- β level in experimental autoimmune thyroiditis induced in female rats.

Group	TGF- β (pg/ml)
Group 1	0.344 \pm 0.031a
Group 2	0.216 \pm 0.020b
Group 3	0.288 \pm 0.027ab
Group 4	0.285 \pm 0.024ab

The data is expressed as mean \pm SD. Results with small, non-identical letters (a and b) differ significantly ($p < 0.05$).

Results revealed that group 2 was decreased significantly as compared with group 1 (control group). However, mean serum level of TGF- β was increased in

group 3 and 4. There was non-significant difference between group 3 and 4 as seen in figure 1.

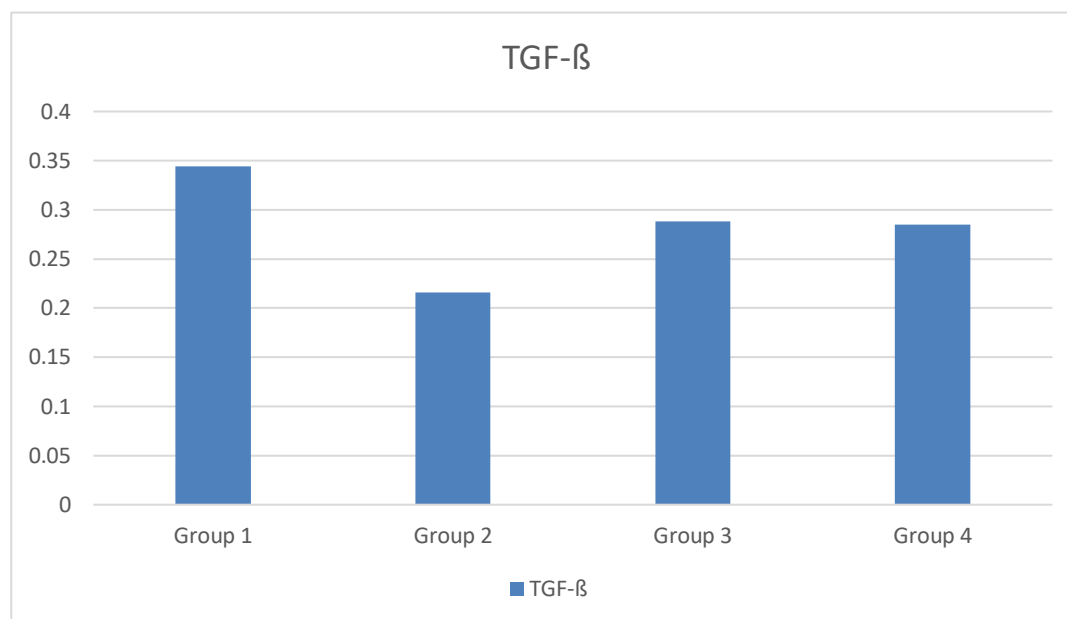


Figure 1: The effects of simvastatin on serum TGF- β level in experimental autoimmune thyroiditis induced in female rats.

Histopathological assessment

A transverse segment of the thyroid gland from group 1 (the negative control group) shows a healthy histological structure. Here, there was a noticeable range in the size of the follicles, which is often observed in the normal

functioning thyroid. These follicles store thyroglobulin in the form of colloid. Most of the follicles also showed peripheral vacuolation. Simple cuboidal cells called follicular cells line each thyroid follicle.

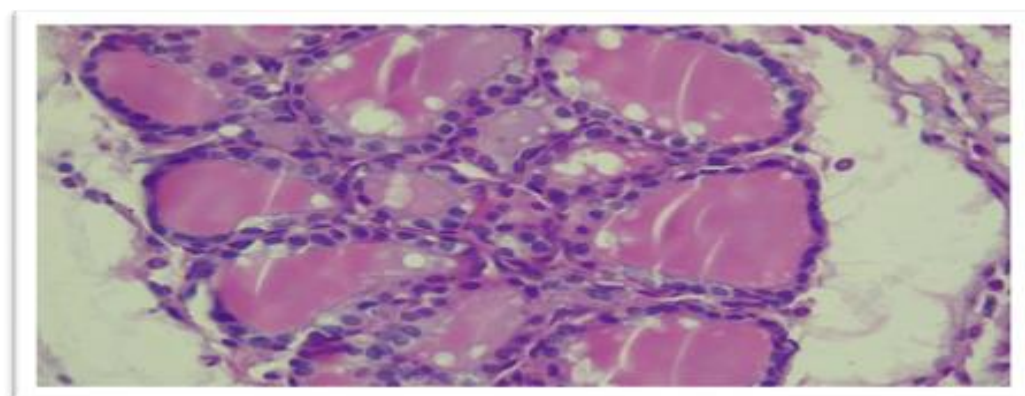


Figure 2: photomicrograph for a transverse section for group 1. Displaying thyroid follicles of various sizes, some of which had little follicular vacuoles (400 X)

a segment showing an apparent decrease in follicle size and number from group 2 (the

induction group). The majority of the follicles had peripheral vacuo

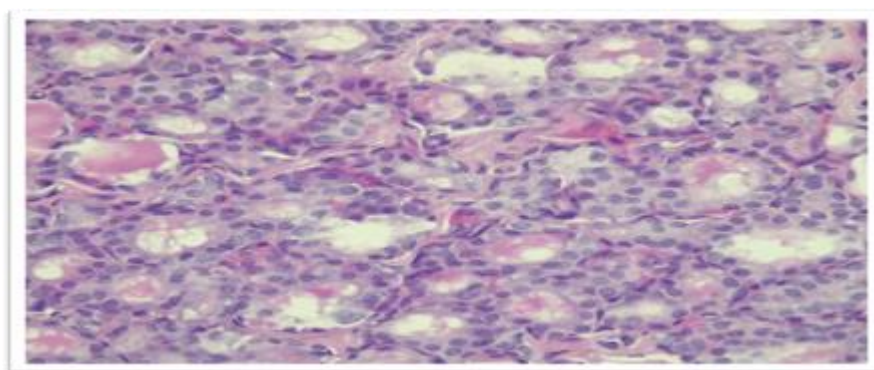


Figure 3: photomicrograph for a transverse section for group 2. Displaying decrease of the thyroid follicles and the replacement with lymphocytes in the parenchymal tissue (400 X)

As for group 3 in which female Wistar rats were treated with prednisolone, less lymphocytic infiltration was seen compared to group 2. Yet, most of the thyroid follicles are

smaller in size and contain less colloid as compared to control group. More congested blood vessels in the interstitial connective tissue were noticed.

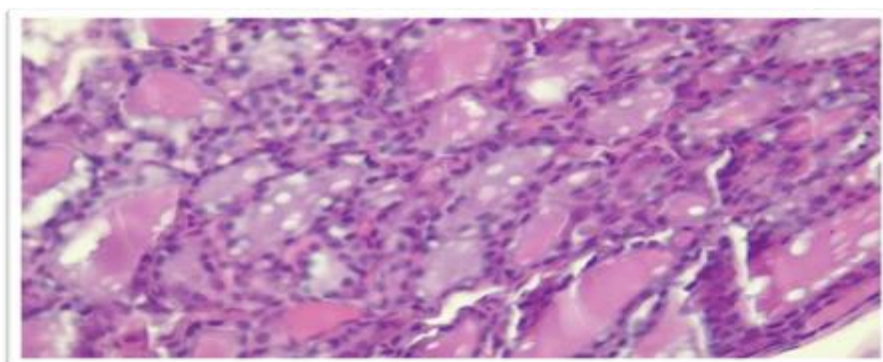


Figure 4: photomicrograph for a transverse section for group 3. Displaying the decrease in the colloid. H.&E. (400x)

In group 4, where rats received simvastatin treatment, different histological alterations were seen. Thyroid follicles resemble those in group 1 in appearance. However,

there were fewer follicles overall. Although, as can be seen in the picture below, there was a little decline in the number of thyroid follicles.

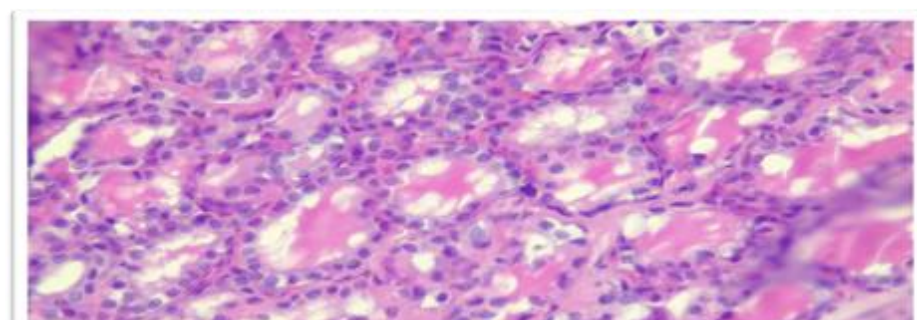


Figure 5: Photomicrograph of the thyroid gland from group 4. a decrease in the number of thyroid follicles, and mild lymphocytic infiltrate.

Immunohistochemistry staining for CD4, CD25

The following results are aligned as marker/antibody-based.

Expression of CD25: different expressional patterns were noticed, as summarized in the table below.

Table 3: Immunostaining scores for CD25 expression in thyroid tissue of female rat.

Groups	% Of positively stained cells	Intensity of staining	Immunostaining score
Group 1	0	0	0
Group 2	0-1	1	1
Group 3	2	1	2
Group 4	2	2	4

Very low expression of CD25 was seen among group 2. Prednisolone (group 3) and Simvastatin group (group 4) both showed an elevation of the expression according to the score mentioned.

Examining a transverse section of the thyroid gland from the four groups stained with CD25 monoclonal Antibody, showed different expressional patterns.

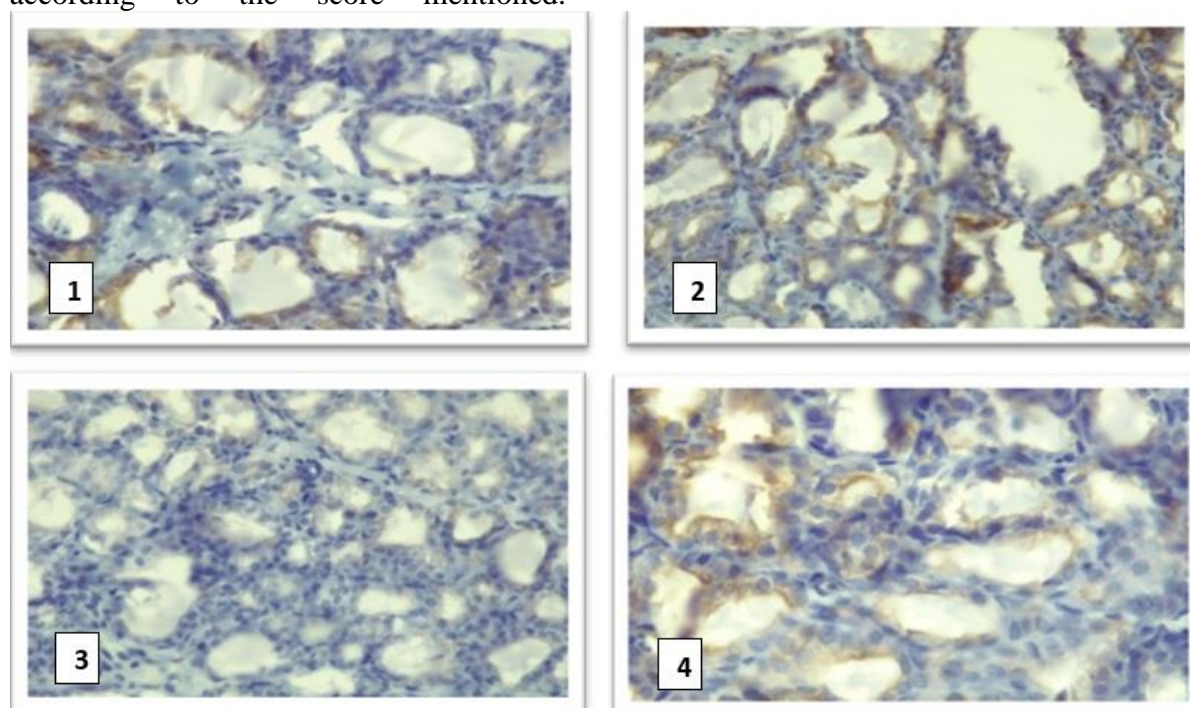


Figure 6: The immunohistochemical staining pattern for CD25 at the cytoplasmic membrane evaluated both quantitatively and qualitatively. CD25 normally demonstrates staining at the cytoplasmic membrane. 1; group1, 2; group2, 3; group 3, 4; group 4.

Expression of CD4: different expressional patterns were noticed, as summarized in the table below:

Table 4: Immunostaining scores for CD4 expression in thyroid tissue of female rats.

Groups	% Of positively stained cells	Intensity of staining	Immunostaining score
Group 1	1	1	1
Group 2	3	3	9
Group 3	2	2	4
Group 4	2	1	2

In the group 1, a small number of CD4 cells with weak cytoplasmic intensity were seen. In contrast, a very high number of positive CD4 cells with strong intensity

were noticed among group 2 (induction group), which started to reduce to moderate in Group 3 then lowered to moderate in group 4 as seen in Figure 7.

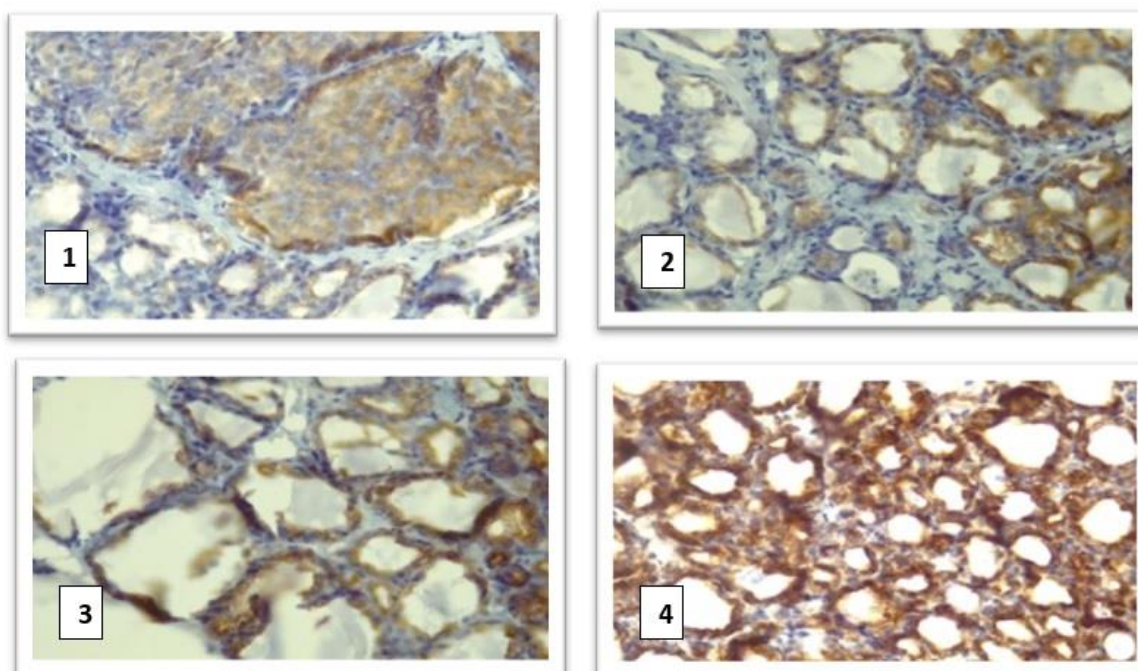


Figure 7: The immunohistochemical staining pattern for CD4 at the cytoplasmic membrane was evaluated both quantitatively and qualitatively. CD4 normally demonstrates staining at the cytoplasm. 1; group1, 2; group2, 3; group 3, 4; group 4.

Discussion

Experimental autoimmune thyroiditis was induced in female rats by using an emulsion of porcine thyroglobulin in Freund's adjuvant. Autoantibodies against thyroid antigen were detected by ELISA technique.

CD4+ cells are known to perform the most significant role in the pathogenesis of Hashimoto thyroiditis (16). In our current study, group 2 (the induction group) had a very high number of strongly positive CD4 cells, which began to decline to a moderate level in group 3 and group 4. As seen in figure 7.

The development of autoimmune disease is influenced by TGF- β 1 shortage (or possibly decreased synthesis), which affects T-cell activation, differentiation, and apoptosis, regulatory T-cell activity, and the expression of cytokines, MHC, and cell adhesion molecules ⁽⁵⁾. Statins also inhibit the activation of Smad6 and Smad7, which releases and amplifies TGF- β 1 signaling ⁽⁶⁾. As a result, treatment with simvastatin led to decreased level of CD4 since amplification of TGF- β 1 led to shifting of differentiation towards Tregs (explains the increment in CD25 expression in rats treated with Simvastatin). Rats in group 2 (the induction group) displayed decreased CD25 expression in a transverse segment of the thyroid gland, as depicted in figure 6. Elevation noticed in both the expression and intensity of CD25 in Simvastatin treated group (group 4) as seen in figure 6. By altering transcription factors necessary for Treg production, statins can improve Treg differentiation and maintenance. Simvastatin is thought to be able to control the foxp3 promoter's methylation, and as mentioned above this statin also inhibits the activation of Smad6 and Smad7 (the main signal transducers for receptors of TGF- β 1), which releases and amplifies TGF- β 1 signaling. Simvastatin therefore facilitates the induction of foxp3 expression in T cells. Simvastatin medication therefore decreased CD4 expression while increasing CD25 expression in this experiment.

Conclusion

- Simvastatin has an immunomodulatory effect.
- It suppresses autoimmune response in Hashimoto's thyroiditis.
- It increases Tregs and also rises serum level of TGF- β .

References

- 1- Frommer L, Kahaly GJ. Type 1 Diabetes and Autoimmune Thyroid Disease—The Genetic Link. Vol. 12, *Front Endocrinol (Lausanne)*. 2021;12:618213.
- 2- Cao Y, Jin X, Sun Y, Wen W. Therapeutic effect of mesenchymal stem cell on Hashimoto's thyroiditis in a rat model by modulating Th17/Treg cell balance. *Autoimmunity* [Internet]. 2020;53(1):35–45.
- 3- Weetman AP. An update on the pathogenesis of Hashimoto's thyroiditis. *J Endocrinol Invest* [Internet]. 2021;44:883–90.
- 4- Hu Y, Zhang L, Chen H, Liu X, Zheng X, Shi H, et al. Analysis of Regulatory T Cell Subsets and Their Expression of Helios and PD-1 in Patients with Hashimoto Thyroiditis. 2019 May 13;2019.
- 5- Ralli M, Angeletti D, Fiore M, et al. Hashimoto's thyroiditis: An update on pathogenic mechanisms, diagnostic protocols, therapeutic strategies, and potential malignant transformation. *Autoimmun Rev*. 2020;19(10):102649.
- 6- Sanjabi S, Oh SA, Li MO. Regulation of the immune response by TGF- β : From conception to autoimmunity and infection. *Cold Spring Harb Perspect Biol*. 2017 Jun 1;9(6).
- 7- Martinez Quintero B, Yazbeck C, Sweeney LB. Thyroiditis: Evaluation and Treatment. *Am Fam Physician*. 2021;104(6):609-617.
- 8- Morofuji Y, Nakagawa S, Ujifuku K, Fujimoto T, Otsuka K, Niwa M, Tsutsumi K. Beyond Lipid-Lowering: Effects of Statins on Cardiovascular and Cerebrovascular Diseases and Cancer. *Pharmaceuticals (Basel)*. 2022 Jan 26;15(2):151.
- 9- Evaluation of anti-proliferative activity of simvastatin and atorvastatin on MCF7 cell line compared with doxorubicin using MTT test. *Al*

- Mustansiriyah Journal of Pharmaceutical Sciences. 2018 Dec 15;163–9.
- 10- Göbel A, Rauner M, Hofbauer LC, Rachner TD. Cholesterol and beyond - The role of the mevalonate pathway in cancer biology. *Biochim Biophys Acta Rev Cancer*. 2020;1873(2):188351.
- 11- Sorathia N, George' S, Al-Rubaye H, Zal B. Citation. *European Cardiology Review* [Internet]. 2019;14(2):123–32.
- 12- Song XH, Zan RZ, Yu CH, Wang F. Effects of modified Haizao Yuhu Decoction in experimental autoimmune thyroiditis rats. *J Ethnopharmacol*. 2011 May 17;135(2):321–4.
- 13- Li Y, Zuo X, Hua C, Zhao Y, Pei X, Tian M. Effects of Selenium Supplement on B Lymphocyte Activity in Experimental Autoimmune Thyroiditis Rats. *Int J Endocrinol*. 2021 Aug 10;2021:9439344.
- 14- Saadoon AS, Ghazi Alabbassi M, Hameed Mohammed N. *Cuscuta Chinensis* potentiate the effect of methotrexate in Rheumatoid Arthritis Induced Rats. *Al Mustansiriyah Journal of Pharmaceutical Sciences*. 2020 April 20(4).
- 15- Pyzik A, Grywalska E, Matyjaszek-Matuszek B, Roliński J. Immune disorders in Hashimoto's thyroiditis: what do we know so far?. *J Immunol Res*. 2015;2015:979167.
- 16- Miyazawa K, Miyazono K. Regulation of TGF- β family signaling by inhibitory smads. *Cold Spring Harb Perspect Biol*. 2017 Mar 1;9(3).
- 17- Kim SW, Roh J, Park CS. Immunohistochemistry for Pathologists: Protocols, Pitfalls, and Tips. *J Pathol Transl Med*. 2016 Nov;50(6):411–418.