

Effect of Hyper and Hypothyroidism on Lipid Profile and Liver Function of Male Rats

*Ferial A. Al-Manaf Al-Mahdawi**

*Abeer Uthman Moosa**

Received 15, July, 2008
Accepted 3, January, 2011

Abstract:

This study was designed to investigate the effect of thyroid hormone disturbance on lipids profiles and liver functions.

Eighteen mature male rats *Rattus norvegicus* were divided into three groups. The first and the second groups were injected subcutaneously with thyroxine (T₄) and carbimazol (both at 600 µg/kg BW) respectively on alternate days, to produce recurrent periods of hyper and hypothyroidism. The control group which is the third group was injected with physiological saline. The process continued 4 weeks, after that, injection, blood specimens were collected to estimate serum levels of T₃ and T₄, Total cholesterol (TC), Triglycerides (TG), High density lipoprotein cholesterol (HDL-C), Low density lipoprotein cholesterol (LDL-C) and Very low density lipoprotein cholesterol (VLDL-C) were determined in the serum. In addition to that, we measure GOT, GPT and CPK enzymes activity.

The results showed no significant difference in body weight and a significant increase (P<0.01) in liver weight of Thyroxine injected group, while Carbimazol injected group showed significant increase (P<0.05) in body and in liver weight.

There was a significant decrease in TC concentration and there was no significant decrease in TG, HDL-C, LDL-C and VLDL-C concentration in the serum of Thyroxine injected group, while the Carbimazol injected group showed significant increase in serum TC, LDL-C, TG, HDL-C and VLDL-C concentration.

The results also pointed to a significant increase in GOT and GPT activity, and no significant decrease in CPK activity in the serum of thyroxine injected group, in addition to a significant increase in GPT activity and a significant increase in GOT activity without any significant differences in CPK activity noticed in the liver homogenate of the same group. The results also pointed to a significant increase in GOT and GPT activity, and significant increase in CPK activity in the serum of Carbimazol injected group, with significant decrease in GOT activity, significant decrease in GPT activity and significant increase in CPK activity in the liver homogenate of the same group.

Results of the liver histological study showed changes in the liver histological structure in both groups. An increasing in T₃ and T₄ levels led to a little expansion in the sinusoids and this might be due to accumulation of glycoprotein, also there was a centrilobular hepatocytes necrosis and congestion with RBCs in the sinusoids of central area due to hypoxia especially in perivenular hepatocytes area. In addition to extravasations of RBCs between the hepatocytes which are severely atrophied and some are necrosed.

It was noticed that there is a direct relationship between low levels of T₄ and T₃ and the hepatic dysfunction which led to sinusoids expansion, granular and hydropic degeneration due to hepatocytes immunological or toxically damaged which gave the hepatocytes edema appearance.

Key words: Hypothyroidism , Hyperthyroidism , Lipid profiles

*Biology Dept. / College of Science / University of Baghdad

Introduction:

Thyroid gland is one of the most important endocrine glands found in the body. It plays an important role in maintaining body metabolism and effects on central nervous system, anterior pituitary gland, circulation and regulates all the physiological activities of different organs and tissues such as the heart and liver [1].

Thyroid hormone has both direct and indirect actions on the cardiovascular system [2]. The heart is a main target organ for thyroid hormone action, and marked changes occur in cardiac function in patients with hypo- or hyperthyroidism [3]. Thyroid hormones have significant effects on the synthesis, mobilization and metabolism of lipids, so any disturbance in Thyroid hormones leads to dyslipidemia [4]. Elevated in the levels of TC, LDL-C, and TG in case of hypothyroidism increase the risk of cardiovascular disease such as coronary artery diseases and atherosclerosis [5]. While in case of hyperthyroidism, decreasing in the levels of TC, LDL-C, and TG, and stimulating the oxidation of LDL-C will lead to increase the risk of heart disease [6].

The studies have shown that there is a relationship between thyroid gland and the liver [7]. Thyroid hormones have an important rule in maintaining the natural liver function and bilirubin metabolism, so there is a relationship between the thyroid diseases and liver disorders [8].

The aim of this study was to determine how the thyroid hormones' disturbance may leads to lipid level disorders which considered as a risk factor of coronary artery diseases and also may produce alteration in liver functions.

Materials and Methods:

Eighteen Five-months-old rats *Rattus norvegicus*, weighing 115-125 g, were housed under a controlled lighting schedule (14-h light/10-h dark), and fed commercial diet and water *ad libitum*. were used in this study. They were divided in to 3 equal groups. The first one was injected with 600 µg/Kg of Thyroxine to induce a hyperthyroidism state, and the second one was injected with 600 µg/Kg of Carbimazol to induce a hypothyroidism state, While the third one was treated with normal physiological saline (0.9% NaCl). Following 4 weeks of injecting on alternate days, the animals' weight was measured and blood was collected by cardiac puncture by using syringe (5 ml capacity). Then it centrifuged (5000 rpm for 15 min.) which to obtain the serum in freezer under -20 until it used to measure the T₃, T₄ levels by using Radioimmuno Assay (RIA) [9] and TC, TG, HDL-C, LDL-C, VLDL-C levels and GOT, GPT, CPK activity by using spectrophotometer [10, 11]. Then rats were killed by cervical dislocation and the liver was excised under sterile conditions and 2gm of it was homogenized to determine GOT, GPT, and CPK activity.

Results and Discussion:**1-Effect of Thyroxine and Carbimazol in T3 and T4 levels of rats:**

The results showed significant increase ($P < 0.01$) in serum level of T₃ and T₄ in the Thyroxine injected group and significant decrease ($P < 0.01$) in serum level of T₃ and T₄ in the Carbimazol injected group (table-1). Carbimazol may close the T₃ and T₄ production pathways [12], or due to reduce binding rate of T₃ and T₄ with the carrier proteins such as TBPA and TBG. [13].

2-Effect of Thyroxine and Carbimazol in body and liver weight of rats:

The results showed (table-1) no significant decrease ($P>0.05$) in body weight and a significant increase ($P<0.01$) in liver weight of Thyroxine injected group, while the Carbimazol injected group showed significant increase in the body and liver weight. This is because of the maximal lipolytic response and sensitivity to catecholamines were increase in adipocytes [14]. while the increase in liver weight of both rats injected with T4 and carbimazol was explained by the recent research which used tri-iodothyronine as a hepatic growth factor and showed that T3 might be a primary mitogen for the liver in animal models (i.e. it induces hepatocyte proliferation and increases liver mass when administered at high doses in the absence of hepatic injury) [15].

3-Effect of Thyroxine and Carbimazol on Lipids levels in the serum:

Rats injected with T4 showed decreasing in TC, TG, and Lipoproteins (HDL-C, LDL-C, and VLDL-C) concentration due to the rapid clearing of chylomicron remnants from blood stimulating cholesteryl ester transfer which in turn stimulate lipoprotein lipase. , while the Carbimazol injected group showed significant increase in TC and LDL-C concentration (table-2), and significant increase in TG, HDL-C and VLDL-C concentration. The primary mechanism for hypercholesterolemia in Rats injected with carbimazol is accumulation of LDL -C due to a reduction in the number of cell surface receptors for LDL, resulting in decrease catabolism of LDL and diminished secretion of cholesterol in to bile and reduced cholesteryl ester transfer and reduced lipoprotein lipase

is responsible for the development of hypertriglyceridemia [10 , 16].

4-Effect of Thyroxine and Carbimazol in GOT, GPT, CPK activity:

The results also pointed to significant increase ($P<0.01$) in GOT and GPT enzyme activity, and no significant decrease in CPK activity in the serum of Thyroxine injected group, in addition to a significant increase ($P<0.01$) in GPT activity and significant increase in GOT activity without any significant differences in CPK activity noticed in the liver homogenate of the same group. The results also pointed to a significant increase ($P<0.05$) in GOT and GPT activity, and significant increase ($P<0.01$) in CPK activity in the serum of Carbimazol injected group, while a significant decrease ($P<0.01$) in GOT activity, significant decrease ($P<0.05$) in GPT activity and significant increase ($P<0.01$) in CPK activity noticed in the liver homogenate of the same group (table-3).

An elevation in the GOT and GPT activity in serum of rats injected with thyroxine may be due to metabolism increasing in hepatocytes which lead in turn to increase GOT & GPT [7], or due to the damage which may happen in the hepatocytes leading to leakage of enzymes from the cells [17]. As well as, the increasing of GOT, GPT and CPK activity in serum of rats injected with carbimazol due to increase in rates of enzymes leakage from the hepatocytes and reduce enzymes clearance from blood. [11 , 18].

while the increase in GOT & GPT activity in the liver homogenate of rats injected with T4 might be resulted from the breaking down of hepatocytes' membranes due to homogenizing process which led to enzyme releasing from the cells [19].

Inversely the decreasing of GOT, GPT and CPK activity in the liver homogenate of rats injected with carbimazol might be increased from

increased rates of enzymes leakage from the cells to the blood due to membrane permeability [17].

Table (1) The changes in T3 and T4 hormones and body and liver weights of rats injected with 600 µg/Kg of thyroxin and 600 µg/Kg carbimazol.

Measurements	T ₄ nm/L	T ₃ nm/L	Body weight gm		Liver weight gm/100gm of body weight
			before injection	after injection	
Control	96 ± 3.93	1.29 ± 0.09	115.5 ± 10.32	127.9 ± 20.50	3.42 ± 0.27
Rats injected with Thyroxin	**114.38 ± 5.37	** 2.8 ± 0.09	123.81 ± 0.83	125.78 ± 1.41	** 4.67 ± 0.82
Rats injected with Carbimazol	**80.36 ± 6.85	** 0.85 ± 0.03	125.98 ± 1.30	* 141.3 ± 1.11	* 4.55 ± 0.63

Values represented Mean ± SD (Standard Deviation)

*Significant differences (P<0.05) ** Significant differences (P<0.01)

Table (2) The changes in lipids levels in rats injected with 600 µg/Kg of thyroxin and 600 µg/Kg carbimazol.

Measurements	Total Cholesterol mg/dL	Triglyceride mg/dL	HDL-C mg/dL	LDL-C mg/dL	VLDL-C mg/dL
Control	61.26 ± 3.34	39.11 ± 3.21	11.91 ± 1.35	41.4 ± 5.04	7.82 ± 0.63
Rats injected with Thyroxin	* 48.63 ± 3.86	33.67 ± 1.50	9.62 ± 1.70	35.08 ± 4.41	6.73 ± 0.18
Rats injected with Carbimazol	** 83.87 ± 1.33	*47.49 ± 5.69	* 16.85 ± 0.54	** 57.01 ± 5.20	* 9.40 ± 1.09

Values represented Mean ± SD (Standard Deviation)

*Significant differences (P<0.05) ** Significant differences (P<0.01)

Table (3) The changes in serum and liver homogenate enzymes activity in rats injected with 600 µg/Kg of thyroxine and 600 µg/Kg carbimazol.

	GOT unit/L		GPT unit/L		CPK unit/L	
	Serum	Liver Homogenate	Serum	Liver Homogenate	Serum	Liver Homogenate
Control	14.62 ± 1.51	332.60 ± 4.27	8.42 ± 1.67	108.4 2± 5.89	77.56 ± 3.02	214.66 ± 16.38
Rats injected with Thyroxin	** 120.5±19.70	*358.21 ± 42.52	**26 ± 7.17	** 141.3 ± 13.5	72.40 ± 1.62	236.60 ± 25.14
Rats injected with Carbimazol	*33.25 ± 3.26	**110.6 ± 3.46	*15.52± 2.06	* 63.4 ± 6.82	** 119.85 ± 9.19	** 718 ± 46.30

Values represented Mean ± SD (Standard Deviation)

*Significant differences (P<0.05) ** Significant differences (P<0.01)

5-Histological changes:

An increasing in T3 and T4 levels led to a little expansion in the sinusoids and this might be due to accumulation of glycoprotein, Fig. (1), also there was a centrilobular hepatocytes necrosis and congestion with RBCs in the sinusoids of central area due to

hypoxia especially in perivenular hepatocytes area, Fig. (2) [8]. In addition to extravasations of RBCs between the hepatocytes which are severely atrophied and some are necrosed Fig. (3) comparing with control Fig. (4).

The results also showed an increasing ($P < 0.01$) in hepatocytes diameter mean might be explained by the Recent work investigating the use of tri-iodothyronine as a hepatic growth factor has shown it to be a primary mitogen for the liver in animal models (i.e. it induces hepatocyte proliferation and increases liver mass when administered at high doses in the absence of hepatic injury) [15] Fig. (5). It was noticed that there is a directly relationship between low levels of T4 and T3 and the hepatic dysfunction [20] which led to sinusoids expansion and bloody congestion Fig.(6) granular and hydropic degeneration due to hepatocytes immunological or toxically damaged which gave the hepatocytes edema appearance [21] Fig. (7).

An increasing in hepatocytes diameter mean rats injected with carbimazol might be due to glycogen accumulation in hepatocytes [22].

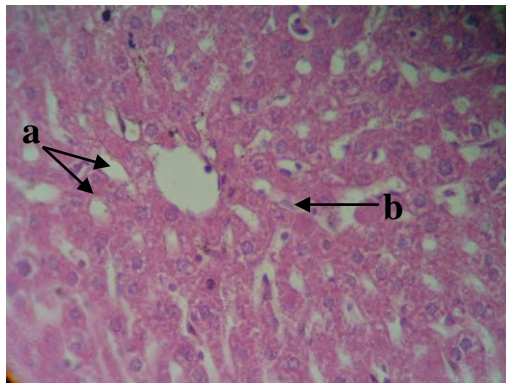


Fig. (1) Section in liver of rats injected with 600 µg/Kg of carbimazol showing: a-sinusoids expanse, b-hyperplasia of kuffer cells. . (H&E) stain (10X).

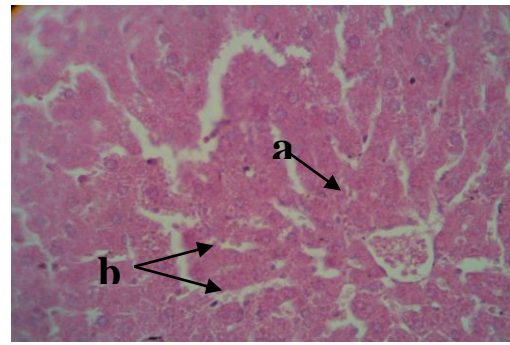


Fig. (2) : Section in liver of rats injected with 600 µg/Kg of thyroxine showing: a-centrilobular hepatocytes necrosis, b-sinusoids engorged with RBCs.

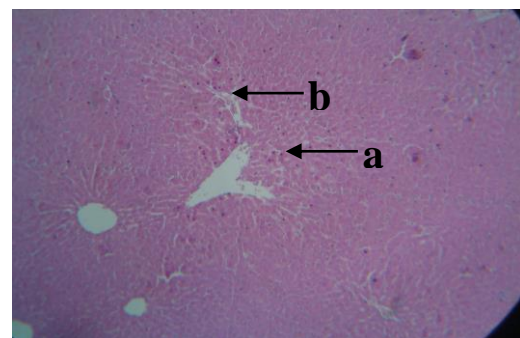


Fig. (3): Section in liver of rats injected with 600 µg/Kg of thyroxine showing: a- cloudy degeneration, b- venous congestion.

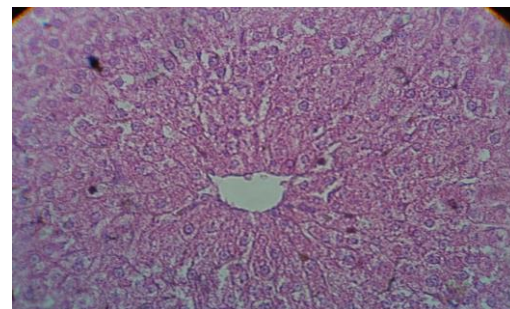


Fig. (4) : Section in control liver lobule consists of normal hepatocytes, arranged in cords with the sinusoids in between around the central vein.

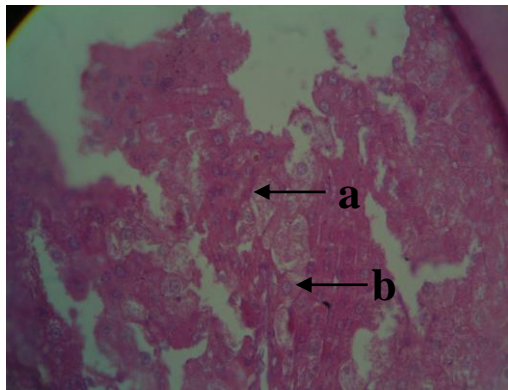


Fig. (5) : Section in liver of rats injected with 600 µg/Kg of thyroxine showing: a- hydropic degeneration of some hepatocytes, b-.others show signs of congestion and atrophy.

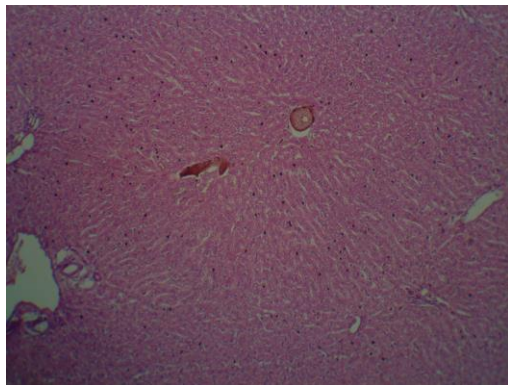


Fig. (6) Section in liver of rats injected with 600 µg/Kg of carbimazol showing: sinusoids expanse and bloody congestion. (H&E) stain (10X)

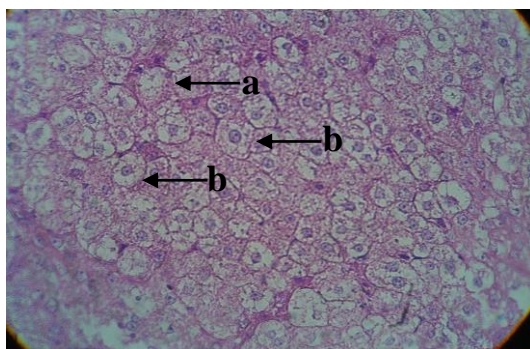


Fig. (7): Section in liver of rats injected with 600 µg/Kg of carbimazol showing: a-marked hydropic degeneration, b-prominent of cells & nuclei membranes.

References:

1. Ganong, W.F.2003. Review of Medical Physiology. McGraw – Hill Companies; Inc. 21th ed. Pp 296-311.
2. Klein, I. and Ojamaa K. 2001. Thyroid Hormone and the Cardiovascular System. NEJM. 344(7):501-509.
3. Kahaly,G.J. and Dillmann W.H. 2005. Thyroid Hormone Action in The Heart. Endo. Rev. 26(5):704-728.
4. Walsh, J. P.; Bremner, A. P.; Bulsara, M. K. ; O'Leary P.; Leedman, P. J.; Feddema, P. and Michelangeli,V. 2005. Thyroid dysfunction and serum lipids: a community-based study. Clin. Endocrinol.63 (3):670-675.
5. Cappola, A.R. and Ladenson P.W. 2003. Hypothyroidism and Atherosclerosis. J. Clin. Endo. & Met. 88(6): 2438-2444.
6. Reaven, P.D. and Witzum J.L. 1995. The Role of Oxidation of LDL in Atherogenesis. Endocrinologist. 5:44–54.
7. Malik, R; Mellor N.; Selden C. and Hodgson H. 2000. Characterizing the Effects of Thyroid Hormone on the Liver. Gut. 34 (1):77-78.
8. Huang, M.J. and Liaw Y.F. 1995. Clinical Associations between Thyroid and Liver Diseases. J.Gastroenterol. Hepatol., 10(3): 344-350.
9. Manna, P.R.; Kero J.; Tena-Sempere M.; Pakarinen P.; Stocco D. M. and Huhtaniemi I. T. 2001. Assessment of Mechanisms of Thyroid Hormone Action in Mouse Leydig Cells: Regulation of the Steroidogenic Acute Regulatory Protein, Steroidogenesis, and Luteinizing Hormone Receptor Function. Endocrinology. 142 (1): 319-331.

10. Ross, D.S. 1999. Lipid Abnormalities in Thyroid Disease. *Thyroid*.6:155-156.
11. Saha, B. and Maity C. 2002. Alteration of Serum Enzymes in Primary Hypothyroidism. *Clin. Chem. Lab Med.* 40(6):609-611.
12. Woeber, K.A.2000. Up Date on the Management of Hyperthyroidism and Hypothyroidism. *Arch. Fam.Med.* 9:743-747.
13. Pruett, H.E.; Thompson D.L.; Cartmill J.A.; Williams C.C. and Gentry L.R. 2003. Thyrotropin Releasing Hormone Interaction with Growth Hormone Secretion in Horse's. *J.Anim.Sci*, 81(9):2343-2351.
14. Germack,R.; Starzec A. and Perret G.Y. . 2000. Regulation of β_1 - and β_3 -adrenergic agonist-stimulated lipolytic response in hyperthyroid and hypothyroid rat white adipocytes. *Brit. J. Pharm.* 129: 448-456.
15. Malik, R. and Hodgson H. 2002. The Relationship between The Thyroid Gland and The Liver. *QJ Med* 95(9):559-569.
16. Langer, P; Kocan A.; TajTakova M.; and *et al.*2003. Thyroid Function and Cholesterol Level: Paradoxical Findings in Large Groups of Population with High Cholesterol Food Intake. *Endo. Reg.*3:175-180.
17. Khan,M.; Coovadia X.M.; Karvas J.A.; Connolly C.. And Sturm A.W. 1999. Clinical Significance of Hepatic Dysfunction With Jaundice in Thyroid- Fever. *Dig. Dis. and Sci.* 44:590-591.
18. Dahlstedt, A. J.; Wieringa, A. B. and Hakanwesterbiad 2000. Is creatine kinase responsible for fatigue? studies of isolated skeletal muscle deficient in creatine kinase. *FASEB J.*14:982-990.
19. Burnett, J.R.; Crooke M.J.; Delahunt J.W. and Feek C.M. 1994. Serum Enzymes in Hypothyroidism. *NZ Med J.*14:355-356.
20. Novis, M.; Vaisman M. and Coelho H.S. 2002. Positive Relationship between the Low Serum Levels of T3 and Elevated Serum Levels of rT3 and IrT3/T3 with the Degree of Hepatic Dysfunction. *Hbv Res. arch.* 8(54):24-25.
21. Kumar,V; Cortan R. and Robbins S. 2003. Robbins Basic Pathology. 7th ed, saunders. An imprint of Elsevier. Pp 592-607.
22. Al-Habeeb, O. A. 1991. The Animal Physiology. Dar Al- Kutub for printing and reported. Al-Mosel. Pp 413-417.

تأثير فرط وقصور الدرقية في الدهون ووظائف الكبد في ذكور الجرذان

فريال عبد المناف المهداوي* عبير عثمان موسى*

* قسم علوم الحياة / كلية العلوم / جامعة بغداد

الخلاصة:

سعت الدراسة الحالية لمعرفة تأثيرات اضطراب الغدة الدرقية في مستويات الدهون في مصل الدم، والتي تعد عامل خطورة للأصابة بأمراض القلب التاجية وكذلك تأثير هذا الاضطراب في وظيفة الكبد فسلجياً ونسجياً. استخدم في البحث (18) جرذاً أبيضاً من الذكور البالغة من نوع *Rattus norvegicus*، قسمت الى ثلاث مجاميع متساوية، حقنت المجموعة الأولى بـ 600 مايكروغرام/كغم من مادة الثايروكسين لأستحداث حالة فرط الدرقية. وحقنت المجموعة الثانية بـ 600 مايكروغرام/كغم من مادة الكاربيمازول لأستحداث حالة قصور الدرقية، والمجموعة الثالثة هي مجموعة السيطرة التي حقنت بالمحلول الفسيولوجي (0.9% NaCl) وبجرعة واحدة كل 48 ساعة. واستمرت المعاملة لمدة 4 أسابيع، بعدها تم تسجيل وزن الجسم لكل مجموعة، وقياس مستوى هرموني T3 وT4، وكذلك مستويات الدهون التي تشمل الكوليسترول الكلي TC و الكليسيريدات الثلاثية TG وكوليسترول البروتين الدهني عالي الكثافة HDL-C وكوليسترول البروتين الدهني واطيء الكثافة LDL-C وكوليسترول البروتين الدهني واطيء الكثافة جداً VLDL-C في مصل الدم. كما تم قياس فعالية أنزيمات الـGOT وGPT وCPK في مصل الدم ومجانس الكبد. شرحت الجرذان وأستئصل الكبد لغرض تحضير المقاطع النسجية بعد وزنه وتثبيتته بمحلول بون.

وأظهرت نتائج التحليل الأحصائي حصول إنخفاض غير معنوي ($P > 0.05$) في معدل وزن الحيوانات المعاملة بالثايروكسين وحصول إرتفاع معنوي ($P < 0.01$) في معدل وزن الكبد للمجموعة نفسها، في حين لوحظ حصول إرتفاع معنوي ($P < 0.05$) في معدل وزن الحيوانات ووزن الكبد في المجموعة المعاملة بالكاربيمازول مقارنة بمجموعة السيطرة. فضلاً عن حصول إرتفاع معنوي ($P < 0.01$) في مستوى هرموني T3 وT4 في مصل دم المجموعة المعاملة بالثايروكسين، كما لوحظ حصول إنخفاض معنوي ($P < 0.01$) في مستوى هرموني T3 وT4 في مصل دم المجموعة المعاملة بالكاربيمازول. كما أشارت نتائج الدراسة الى حصول إنخفاض معنوي ($P < 0.05$) في معدل تركيز TC وانخفاض غير معنوي ($P > 0.05$) في معدل تركيز كل من TG و HDL-C و LDL-C و VLDL-C في مصل دم المجموعة المعاملة بالثايروكسين. فضلاً عن حصول إرتفاع معنوي ($P < 0.01$) في معدل تركيز TC و LDL-C وحصول إرتفاع معنوي ($P < 0.05$) أيضاً في معدل تركيز كل من TG و HDL-C و VLDL-C في مصل دم المجموعة المعاملة بالكاربيمازول مقارنة بمجموعة السيطرة. وأظهرت نتائج التحليل الأحصائي أيضاً حصول إرتفاع معنوي ($P < 0.01$) في مستوى فعالية أنزيمي GOT وGPT وحصول إنخفاض غير معنوي ($P > 0.05$) في فعالية أنزيم CPK في مصل دم المجموعة المعاملة بالثايروكسين، كما لوحظ حصول إرتفاع معنوي ($P < 0.01$) في فعالية أنزيم GPT، و إرتفاع معنوي ($P < 0.05$) أيضاً في فعالية الـGOT في مجانس الكبد، وانعدام الفروق المعنوية ($P > 0.05$) في مستوى فعالية الـCPK في مجانس كبد المجموعة المعاملة بالثايروكسين مقارنة بمجموعة السيطرة. كما لوحظ حصول إرتفاع معنوي ($P < 0.05$) في فعالية أنزيمي GOT وGPT، وإرتفاع معنوي ($P < 0.01$) أيضاً في فعالية أنزيم CPK في مصل دم المجموعة المعاملة بالكاربيمازول. في حين لوحظ حصول إنخفاض معنوي ($P < 0.01$) في مستوى فعالية أنزيم GOT و إنخفاض معنوي ($P < 0.05$) في مستوى فعالية أنزيم GPT في مجانس الكبد، و إرتفاع معنوي ($P < 0.01$) في مستوى فعالية أنزيم CPK في مجانس كبد المجموعة المعاملة بالكاربيمازول.

أظهرت نتائج الفحص المجهرى لمقاطع نسيج الكبد المحضرة بأستخدام صبغة الهيماتوكسيلين-إيوسين حصول تغيرات نسيجية في كلتا المجموعتين المعاملة بالثايروكسين و الكاربيمازول. إذ أدى إرتفاع هرموني الـT3 و T4 الى حصول توسع قليل في الجيبانيات وتخر في الخلايا الكبدية في المنطقة حول الفصيص المركزي، حصول احتقان الجيبانيات بالدم ويعزى سببه الى نقص الاوكسجين خصوصاً في المناطق المحيطة بالوريد المركزي الذي يؤدي الى تحرر انزيمات الجسيمات الحالة ونواتج افرازية اخرى الى الدم. في حين أدى إنخفاض تركيز T3 و T4 الى معدل تنكس حبيبي و آخر استسقائي في خلايا الكبد فضلاً عن توسع الجيبانيات ويعزى سببه الى حدوث تلف لخلايا الكبد نتيجة لاسباب مناعية او سمية يجعل الخلايا تبدو بمظهر ودمي منتفخ.