

# Effect of ethinylestradiol on testis of albino rats (*Ratus narwegecus*)

Treefa Farouq Ismail & Suhayla Wasman Qadir

Department of Biology, College of Education, Universiti of Salahaddin, Hawler, Erbil, Iraq

## Abstract:

The present study was conducted to clarify the histological effect of ethinylestradiol, on albino rat testis. The albino rats were administered three oral dose of ethinylestradiol 1,2and3 mg/kg b.w./day for 4 weeks. After that the testis were fixed for histological studies. Histological changes were observed in the testis, manifested by (degenerative changes in spermatogenesis, disruption in normal epithelial organization, decreased number of elongated sperm, depletion in germinal layer, dilatation of interstitial space ,existing vacuoles in certain regions of interstitial spaces and present of giant multinucleated cell. Also results indicated that ethinylestradiol has affected on the body and testis weight. We attribute the testis toxicity during ethinylestradiol exposure to the suppression of testicular testosterone levels.

## Introduction:

Ethinylestradiol (19-17  $\alpha$ -pregna-1,3,5 (10)-trien-20-yne-3,17-diol), a synthetic steroidal estrogen, has long been used as a component of oral contraceptive and for the treatment of prostatic hypertrophy and cancer. There have been numerous reports dealing with toxicities attributed to ethenylestradiol in experimental animals, teratogenic effects on mouse fetus [1], anemia, edematous swelling of liver cells, hypertrophy of the adrenal gland and pituitary, and depression of gonadal organs in rats [2].

Concerning the hepatocarcinogenesis in rats and humans [3 and 4].regarding to the testicular toxicity in rats, ethinylestradiol has been reported to evoke sterility as a result of decreased testicular sperm counts, and atrophy of seminiferous tubules [5].

Furthermore, sperm motion parameters such as the percentage of motile sperm, velocity, and amplitude of the lateral head displacement, were decreased when administrated ethenylestradiol at 10 mg/kg to rats for 1 week [6].

In the present study we try to investigate the histological alternation in albino rat testis in response to ethinylestradiol administration.

## Materials and methods:

### Animals and experimental design:

Adult male (*Ratus narwegecus*) rats, weighing (320-350) gm, were obtained from the animal house of Science Education College/Salahaddin University. The animals were housed five per cage under controlled conditions of temperature (22C ) and light(12h light:12h dark cycle). They received standard diet and water *ad libitum*. Ethinylestradiol (19-17  $\alpha$ -pregna-1,3,5 (10)-trien-20-yne-3,17-diol) was dissolved in distilled water. The rats were divided into four groups (n=5 per group), the first group was considered as control and received only distilled water, while the remaining three groups received 1,2and3 mg of the drug respectively by gavages for (30) day.

## Histological studies:

On the day after the final administration, all animals were weighed and killed by exsanguinations under chloroform anesthesia, and the testis were weighed then prepared for histological examination.

The testis fixed in a formalin fixative (10 % formalin with 90%distilled water),for at least 24 hours. The fixed testis were dehydrated in ascending serious of alcohol, cleared in xylene and embedded in paraffin and consecutive sections (5-8)  $\mu$ m thick were obtained by a rotary microtome (Erma), and stained with (H and E) Harris Haematoxylin and Eosin, [7].

## Results and discussion:

Testicular section showed normal spermatogenesis in control groups Fig(1). However, after ethenylestradiol treatment, different degrees of degenerative changes in spermatogenesis were observed. The damage that occurred was variable. At the lowest dose of ethinylestradiol (1mg/kg/day) spermatogenesis was qualitatively normal, although some tubules appeared atrophied Fig(3a) and showed disruption in normal epithelial organization. Moreover, tubular damage increased with the increasing dose of ethinylestradiol. At the highest dose of ethinylestradiol testicular changes were characterized by decrease in the number of elongated spermatid, degenerated germ cell Fig(2).

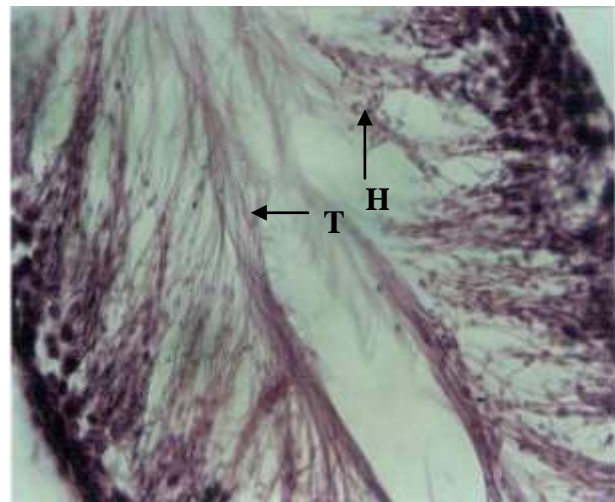
There were also vacuoles in certain region of interstitial spaces Fig(5), suppression of spermatozoa, depletion in germinal layer, dilatation of interstitial space Fig(3b and c) and appearance of giant multinucleated of cells Fig (4).

Histological data indicated that ethinylestradiol treatment inhibits spermatogenesis in certain areas of the seminiferous epithelium. Semilar results were reported by [8] who suggested that the absence of the multiple steps of germ cell development resulted in the ability to distinguish complet stage profiles normally associated with the seminiferous epithelial cycles. The results of [9] showed testicular damage of rats when treated with different doses of oestradiol. Also [10] cleared that ethenylestradiol induced testicular damage when exposed to rat by increasing testicular testosterone level, in which is thought to suppress testosterone production in ledig cells which was histologically reflected as atrophy. The mechanism by which ethenylestradiol induced testicular testosterone cleared by [11] who expected that ethenylestradiol decreased serum testosterone below the minimum detectable levels and testicular testosterone levels declined about 2.5% of the control level. A serum testosterone level is maintained by an endocrine control system characterized by the negative feedback in the hypothalamus-pituitary-testis-axis. The gonadotropen releasing hormone (GnRH) secret pulsative from the hypothalamus and reaches the anterior pituitary through the pituitary portal vein. Then luteinizing hormone (LH)

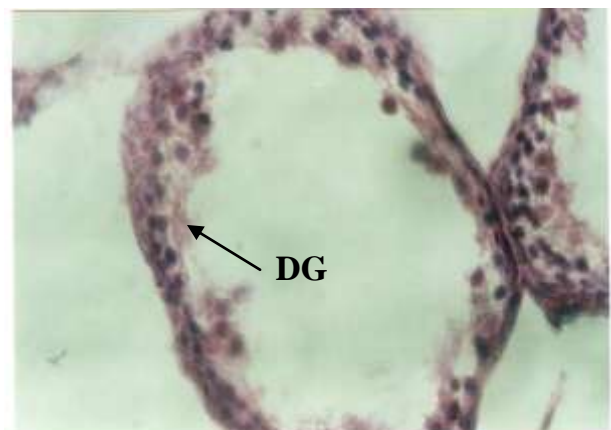
and follicle stimulated hormone (FSH) are synthesized in and secreted from gonadotropic cells of the pituitary. LH combines with the receptors cAMP and subsequently testosterone. Testosterone is secreted from leydig cells into blood testosterone level, and by paracrine action reaches germ cells in seminiferous tubules causing stimulation of spermatogenesis. Blood testosterone is metabolized to stradiol 17B in brain. Increased serum estradiol 17B level inhibits the hypothalamus to produce GnRH by the feedback system leading to decrease blood testosterone level. Ethenylestradiol has the same action as that of estradiol 17B and LH, FSH, and testosterone [12] as the case with other synthetic estrogen, hexaestrol, diethylstilbistrol, fosfestrol, allylestrenol, and mestranol [13,14and15] this could be due to the suppression of GnRH secretion from the hypothalamus by the negative feedback, and eventually decreased testosterone production in testicular leydig cells could induce hypospermatogenesis. As another factor contributing to ethinylestradiol testicular toxicity, severe decreases in body weight were seen depending on concentration in all animal treated. The data in Table (1) revealed that the weight of body and testis of rats affected significantly ( $p \geq 0.01$ ) by different concentration of ethinylestradiol. The mean values of data showed that the highest weight of ( body: 33.40 gm and testis: 1.87) were recorded from control, whereas the lowest weight (266.20 and 1.04) of above parameters produced in case of high concentration. In previous studies, suppression of body weight gain and food intake have been reported, and estrogen explained to diminish efficiency of ingested protein and depress growth hormone secretion from the pituitary gland. Also [16] reported that ethinylestradiol affected on body weight. Depending on blood testosterone level, weight has been reduced in rats received 0.2, 0.3, 1mg/kg/day of ethinylestradiol. On the other hands, [17] cleared that malnutrition itself could induce hypospermatogenesis. Restricted feeding has also been recognized to induce hypospermatogenesis when body weight of rats were reduced to approximately 50% those of the control rats. Histologically degeneration of pacheten spermatocytes in stage VII was observed [18].

**Table (1):** Mean values for the effect of ethinylestradiol treatment body and testes weights in rats.

Treatments	Testes weight gm	body weight gm
C0	1.87	331.40
C1	1.87	320.60
C2	1.59	300.40
C3	1.04	266.20
LSD(0.01)	0.21	12.58

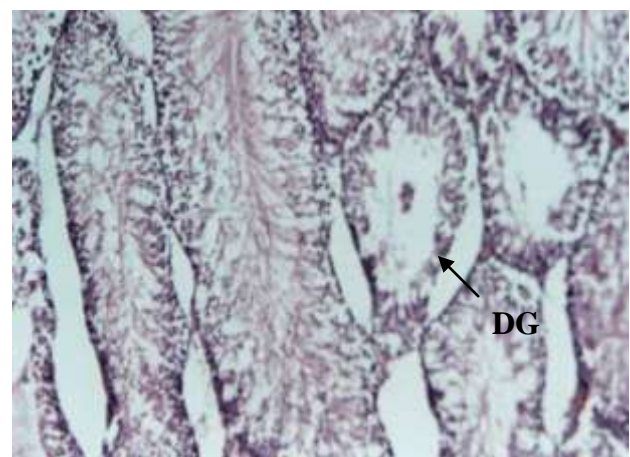

**Fig (1):** Section from normal rat testis showing normal seminiferous tubules contained spermatozoa, the tails (T) directed toward lumen and the heads (H) towards aggregation of spermatids X20.



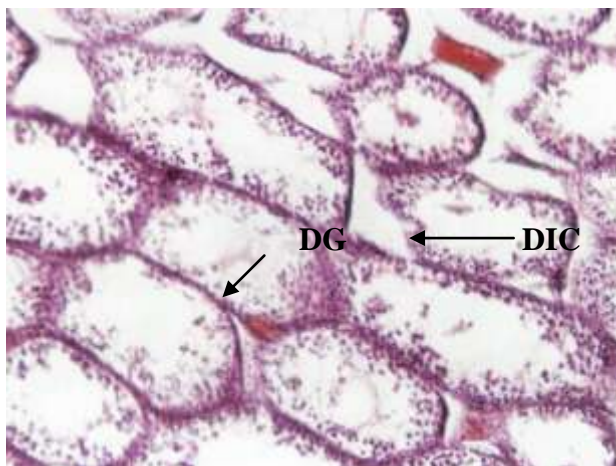**Fig (2):** Section from treated rat testis with (3mg) ethinylestradiol showing

- 1- degenerated germ cell (DG)
- 2- suppression of sperm (SS) X20.

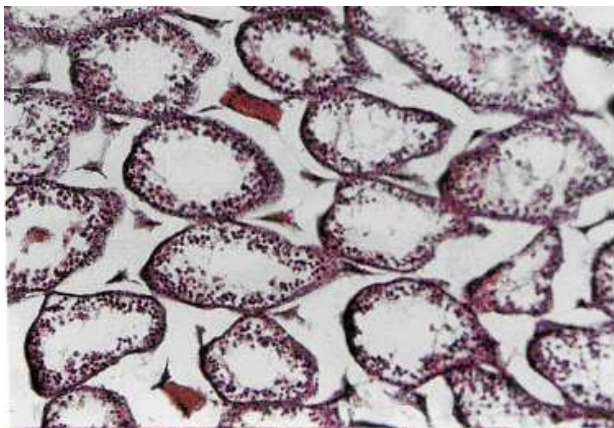


(a)



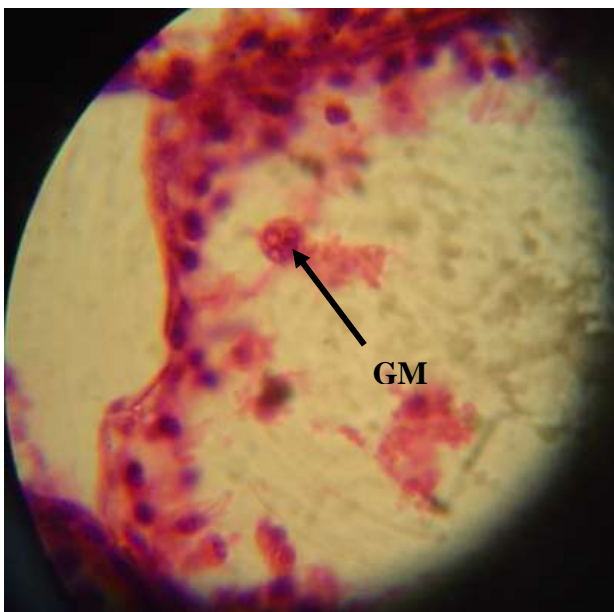


(b)

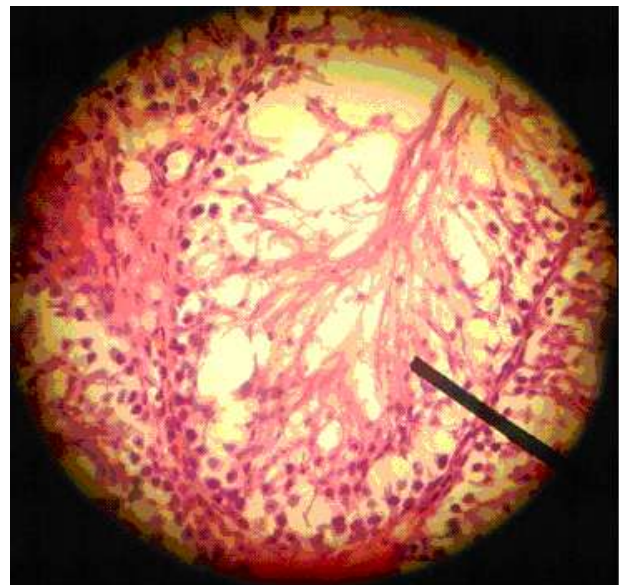


C

**Fig (3):** Section from treated rat testis showing 1- depletion in germinal layer (DG) 2- dilatation of interstitial space(DIC) (a) after exposed to (1mg) ethinylestradiol,(b )after (2mg) ethinylestradiol, (c) after (3mg) ethinylestradiol X10.



**Fig (4):** Section in rat testis showing giant multinucleated cell (GM) after (2mg) ethinylestradiol X40.



**Fig (5):** Section in rat testis showing vacuolated germ cells(V) with (2mg) ethinylestradiol X20.

#### References:

- 1- Yasuda Y., Kihara T., Nishimura H. Effect of ethinylestradiol on development of mouse fetuses. *Teratology* 23:233-239(1981).
- 2- Nakayama T., Usui T., Horiuchi T., Makino M., Suzuki M. Subcutaneous toxicity studies of ethinylestradiol and hexestrol in male rats. *Jpn Pharmacol Ther* 7:3340-3354 (1971).
- 3- Sbaum JK, Bookstein JJ, Holts F, Kiein EW. Possible association between benign hepatomas and oral contraceptives. *Lancet* 37835:7926-9(1973).
- 4- Mayol X., Neal G., Davies R., Romero A., Domingo J. Ethinylestradiol induced cellproliferation in rat liver involvement of specific populations of hepatocytes. *Carcinogenesis* 13:2381-1388 (1992).
- 5- Iwase T., Sano F., Murakame T., Inazawa K. Male reproductive toxicity of ethinylestradiol associated with 4 weeks daily dosing prior to mating in rats. *J Toxicol Sci* 20:265-279 (1995).
- 6- Kaneto M., Kanamori S., Hishikawa A., Kishi K. Epididymal sperm motion as a parameter of male reproductive toxicity. *Reprod Toxicol* 13:279-289(1999).
- 7- Bancroft, J. and Stevens A. Theory and practice of histology techniques. Churchill living stones Eding, Burgh, London and New York (1977).
- 8- Sarkar R., Mohanakumar K., Chowdhury M. Effect of an organophosphate pesticide, quinalphos, on the hypothalamo- pituitary- gonadal axis in adult male rats. *Reproduction and Fertility* 118:29-38(2000).
- 9- Sharp R., Doogan D., Cooper I. Factors determining whether the direct effects of an LHRH agonist on leydig cell function *in vivo* are stimulatory or inhibitory. *Molecular and Cellular Endocrinology* 32:57-71(1983).
- 10- Turner T., Jones C., Howards S., Ewing I., Zegeye B., Gunsalus G. Androgen microenvironment of maturing spermatozoa. *Endocrinology* 115:1925-1932 (1984).

- 11- Shimomura K., Shimada M., Hagiwara M., Harada S., Kato M., Furuhashi K. Insights into testicular damage induced by ethinylestradiol in rat. *Reproductive Toxicology* 20: 157-163 (2005).
- 12- Salman M. and George M. Synthetic estrogen 17 $\alpha$ -ethinylestradiol induces pattern of uterine gene expression similar to endogenous estrogen 17  $\beta$ -estradiol. *Pharmacology And Experimental Therapeutics*. 290:740-770 (1999).
- 13- Takeyoshi M., Anai S., Shinoda K. Hepatic alpha (24) – globulin mRNA levels and diethylbestrol – associated testicular atrophy in rats. *Reprod Toxicol*. 14: 355 – 357 (2000).
- 14-Varma S., Bloch E. Effect of prenatal administration of mestranol and two progestin's on testosterone. Synthesis and reproductive treat development in male rats. *Acta Endocrinal* 116: 193 – 199(1987).
- 15-Schardein J. Studies of the components of an oral contraceptive agent in albino rats. *Toxicol Environ Health* 6:885-894(1980).
- 16- Cook J., Ohnson I., Biegel I., Krams C. Effect of dietary 17 $\beta$ -estradiol exposure on serum hormone concentrations and testicular parameters in male CrI:CD BR rats. *Toxicol Sci* 44:155-167(1998).
- 17-Andrews P., Freberger A., Hartmann E., Eiben R., Loof I. Sensitive detection of the endocrine effects of the estrogen analogue ethinylestradiol using a modified enhanced sub cute study protocol. *Arch Toxicol* 76:194-202(2002).
- 18- Shimada M., Shikanai Y., HaradaS. Effects of food restriction on spermatogenesis in rats. *Reprod Dev* 42: 69-75(1996).

## **Ratus narwegecus تأثير ايثنايل استراديول على الجرذان البيض**

تريفة فاروق اسماعيل و سهيلة سمان قادر

قسم علوم الحياة، كلية التربية، جامعة صلاح الدين، اربيل، جمهورية العراق

### **الملخص:**

المُنوي، نقص في عدد الطبقات الجرثومية، توسع في المساحات البينية، ظهور فجوات في المساحات البينية وظهور خلايا عملاقة متعددة النوى). أشارت النتائج ان ل Ethinyl estradiol تأثير في وزن الخصى ووزن الجسم. وقد يعزى التسمم الخصوي أثناء التعرض ل Ethinyl estradiol الى كبت مستويات الشحمون الخصوي.

تضمنت الدراسة الحالية تقييم التأثير النسيجي لمادة Ethinyl estradiol في خصى ذكور الجرذ الابيض حيث جرعت الحيوانات بمادة Ethinyl estradiol وبثلاث جرع ١ و ٢ و ٣ ملغم/وزن الجسم/يوم عن طريق الفم ولمدة أربعة أسابيع. تم تثبيت مقاطع الخصى للدراسة النسيجية حيث أظهرت تغيرات نسيجية واضحة في الخصى مثل (تغيرات في عملية تكوين النطف، تمزق في الخلايا الطلائية الطبيعية، نقص في عدد الحيوان