

Histopathological changes of chronic cestodes infection in local domesticated ducks (*Anas platyrhynchos*) in Baghdad city.

*Haider Mohammed Ali Al-Rubaie, Mohammed Thabit Salih Al-Zubaidi and Nasir Sadiq

Department of Parasitology, College of Veterinary Medicine, University of Baghdad, Iraq.

E-mail: dr.haider_alrubaie@yahoo.com

Received: 3/5/2018

Accepted: 19/8/2018

Publishing: 31/ 1/2019

Summary

This study was conducted to investigate the histopathological changes of cestodes chronic intestinal infections in ten local domesticated ducks (*Anas platyrhynchos*) during the period 1/9/2016- 1/10/2017 in Baghdad city. Results showed severe destruction in the intestinal mucosa, sloughing and desquamation of the epithelia and severe destruction with distortion or complete loss of the intestinal villi, complete loss of the mucosal and submucosa layers with destruction of intestinal glands and there is a severe infiltration of inflammatory cells mainly mononuclear cells in the lamina propria, and a focal necrosis in the intestinal mucosa. The submucosa showed an infiltration of macrophages and few lymphocytes, severe necrosis, calcification in some mucosal glands or with a cystic dilation with cellular debris in their lumen surrounded by inflammatory cells infiltration mainly mononuclear and plasma cells. The conclusion of the present study was that the cestodes chronic infection cause severe inflammatory response mainly lymphocytes and monocytes in mucosa and sub mucosa and destruction of some intestinal glands of the intestine.

Keywords: Duck, cestodes, intestinal villi, lamina propria.

Introduction

The order Anseriformes consists of about 150 bird species classified in two extant families: Anhimidae (Screamers) and Anatidae; the latter family includes over 140 species of waterfowl, including ducks, geese and swans (1). Domestic ducks (*Anas platyrhynchos*) play a major role in rural economy in the form of meat and eggs. Geographical location, subtropical climatic condition, water lodged and low areas of the country are suitable for duck habitat but these factors also favor growth, multiplication, development, survival and spread of parasites (2), and the parasitic infections cause diseases in ducks and affect their productivity and growth (3).

Internal and external parasites of poultry are common in the tropics because of the favorable climatic conditions for their development and the poor standards of poultry husbandry (4). Their rearing is part of an integrated farming system for rural communities predominantly the indigenous domestic duck (*Anas platyrhynchos*) (5) which used rural duck farming for eggs and meat (6

and 7). Helminth infections are thought to be an important challenge to the production potential of duck and geese rearing programs by reducing the eggs and meat production (3 and 8). The highest prevalence of parasitic infections in domesticated indigenous ducks was 55% (5) or low prevalence (~5%) was reported in native and white pekin ducks (9). Also, the prevalence of parasitic infection was higher in indigenous domestic ducks during summer than winter. Variations in the frequency of parasitic infection between the seasons could be attributed to the seasonal availability of intermediate hosts to ducks (5).

The prevalence and intensity of infection of parasites in ducks may be a problem for household duck farming by affecting the total protein content of the domestic birds and may affect flying performance (10). Multiple parasitic infections have been previously reported (11 and 12) and causes anemia and reduce body mass, and survival (13). Due to the importance of cestodes infections in the birds include ducks; this study was conducted to investigate the intestinal histopathological

changes of cestodes infections in the intestinal layers of domesticated ducks *Anas platyrhynchos*.

Materials and Methods

Ten positive cestodes Ducks (*Anas platyrhynchos*) obtained from local market of Baghdad city were brought to the parasitology laboratory / Veterinary Medicine College for laboratory examination during the period 1/9/2016- 1/10/2017. Birds were slaughtered, the gastrointestinal tracts were eviscerated, and dissected longitudinally. The examination for intestinal cestodes infections was undertaken using gross examination of the intestine content (14 and 15) and identification of parasites was done by using the helminthological keys (16 and 17). Intestinal cestodes infections (*Sobolevicanthus sp.*, *Diploposthe sp.* and *Cotognia sp.*) were examined by using a bout 4 – 6 cm around the intestinal infected sites and fixed in 10% neutral buffered formaline in a plastic containers were processed by ascending of ethyl alcohol concentrations and prepare a tiny blocks in paraffin wax and tissue sections were taken 5-6 μ thickness and stained tissues with hematoxylin and eosin (18).

Results and Discussion

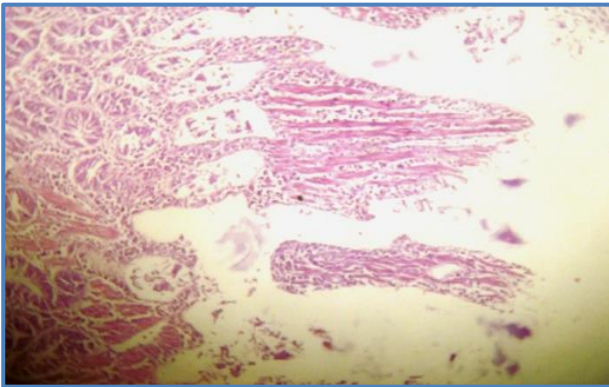
There were severe destruction in the intestinal mucosa, sloughing and desquamation of the epithelia and severe destruction with distortion of the intestinal villi (Fig.1). Other sections showed complete loss of the intestinal villi and atrophy of the intestinal mucosa (Fig.2), complete loss of the mucosal and sub mucosa layers with destruction of intestinal glands (Fig.3), and other sections showed a parasite in the lumen of the intestine (Fig.4). Also there was severe infiltration of inflammatory cells mainly mononuclear cells in the lamina propria, and few sections showed mild infiltration of fibrous connective tissue in the lamina propria.

The submucosa showed infiltration of macrophages and few lymphocytes. Also, other sections showed fibrous connective tissue in the sub mucosa. There was severe necrosis and calcification in the mucosal glands with infiltration of mononuclear cells (Fig.5), with cystic dilation of mucosal glands and cellular debris in the lumen surrounded by

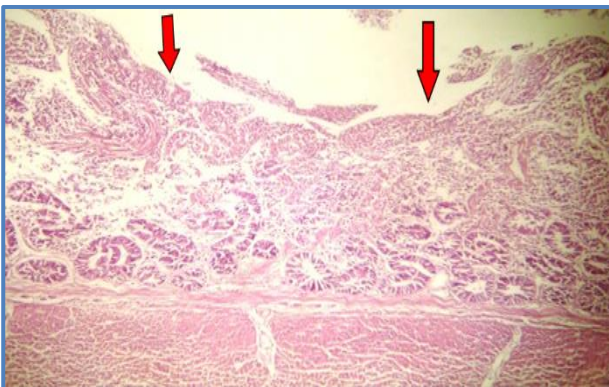
inflammatory cells mainly mononuclear cells (Fig.6), and many sections showed focal necrosis in the intestinal mucosa (Fig.7) with necrosis, eosinophilic structure and inflammatory cells infiltration (Fig.8).

Cestodes can be cause a severe histopathological changes in the intestinal mucosa of the infected host, that was recorded in the previous studies in different birds, (19) found in the infection. The histopathological changes in the intestine showed epithelial mucosal sloughing and cellular infiltration mainly the mononuclear cells (macrophages and lymphocytes) and heterophils, sloughing of epithelial mucosal villi with mononuclear cells infiltration in sub epithelial layer with superficial intestinal necrosis, cellular infiltration mainly in submucosa and lamina propria consist mainly of heterophils and mononuclear cells associated with slight congestion. While the histopathological changes include shortening, atrophy and necrosis of villi with inflammatory cells infiltration and increase acini in base of intestinal villi (20). Also, it has been found small nodules on the external surface of the intestine, ulceration of mucosa, inflammatory infiltration, edematous changes and hyperplasia in the intestine (21) that was agreement with the results of the present study.

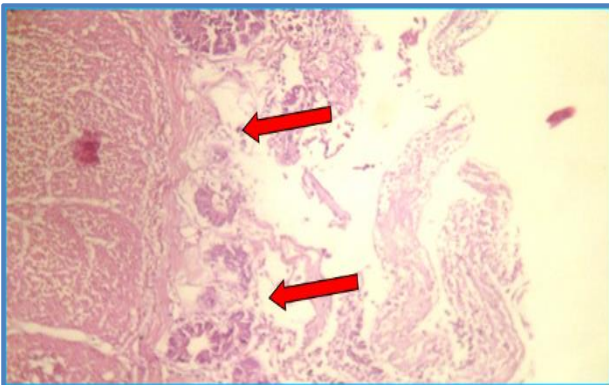
There were severe destruction in the intestinal mucosa, sloughing and desquamation of the epithelia and severe destruction with distortion or complete loss of the intestinal villi, complete loss of the mucosal and sub mucosa layers with destruction of intestinal glands. Also there is a severe an infiltration of inflammatory cells mainly mononuclear cells in the lamina propria, and a mild infiltration of fibrous connective tissue in the lamina propria. Also, a general inflammation in different areas of the gastrointestinal tract were recorded (22 and 23).



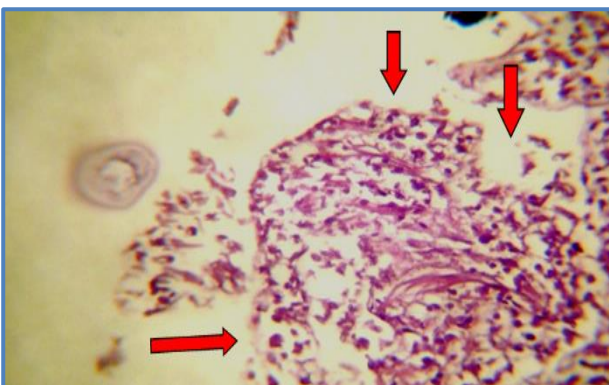
Figure, 1: Section in the intestine shows severe distortion of the villi (H and E, 10X).



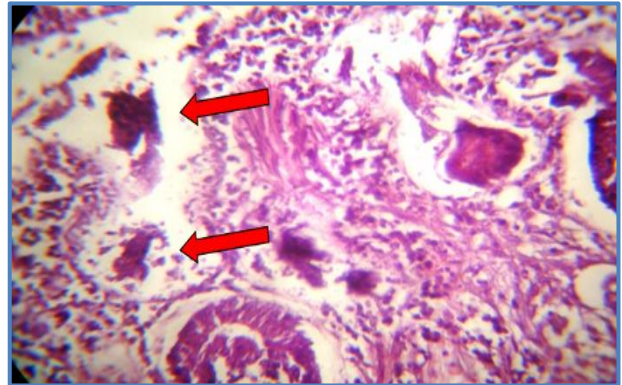
Figure, 2: Section in the intestine shows sloughing and atrophy of the intestinal mucosa (H and E, 10X).



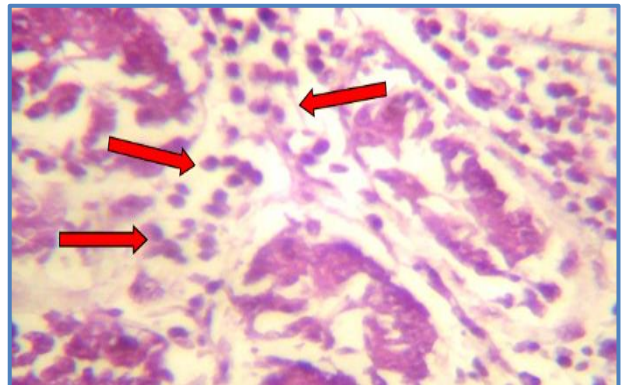
Figure, 3: Shows complete destruction of the mucosal and submucosal layers with destruction of intestinal glands (H and E, 10X).



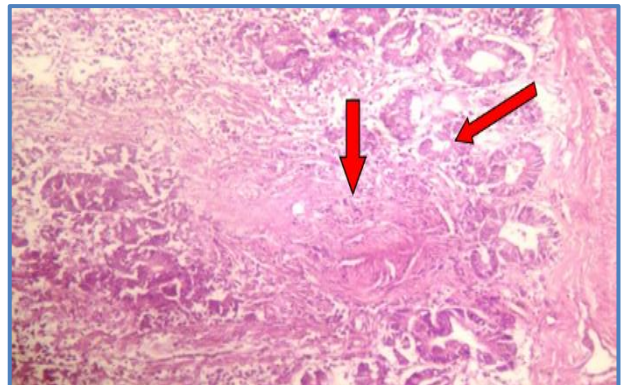
Figure, 4: Shows atrophy of the villi that recover forms of focal ulcer (H and E; 20X).



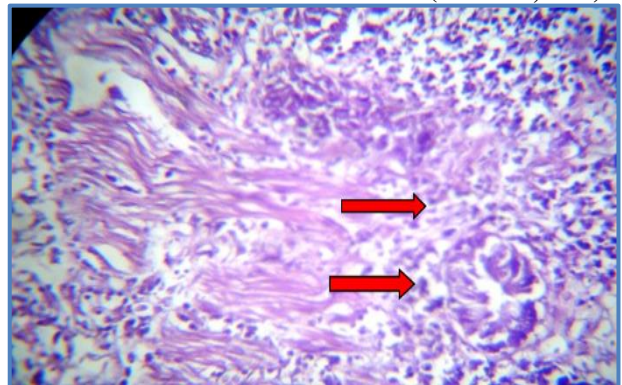
Figure, 5: Shows severe necrosis and calcification in the mucosal glands (H and E. 20X).



Figure, 6: Shows infiltration of plasma cells in the intestinal mucosa (H and E; 40X).



Figure, 7: Shows atrophy of some intestinal glands with focal necrosis in the submucosa (H and E; 10X).



Figure, 8: Shows necrosis, eosinophilic structure and inflammatory cells infiltration (H and E; 20X).

References

1. Howard, R. and Moore, A. (1980). A complete checklist of the birds in the world. Oxford. Oxford University Press: 701.
2. Musa, Sh.; Rahman, T. and Khanum, H. (2012). Prevalence and intensity of parasites in domestic ducks. Dhaka Univ. J. Biol. Sci ; 21(2): 197-199.
3. Farzana, T.; Islam, K.R. and Mondal, M.M.H. (2008). Population density of helminths in ducks: effects of host's age, sex, breed and season. Bangl. J. Vet. Med; 6 (1): 45–51.
4. Abebe, W., Asfaw, T.; Genete, B.; Kassa, B. and Dorchie, P.H. (1997): Comparative studies of external parasites and gastro-intestinal helminthes of chickens kept under different management systems in and around Addis Ababa (Ethiopia). Rev. Méd. Vét; 148: 497-500.
5. Hoque, M.A.; Hassan, M.M.; Haque, E.; Shaikat, A.H.; Khan, Sh.A.; Alim, A.; Skerratt, L.F.; Debnath, N.Ch. and Yamage, M. (2014). A survey of gastro-intestinal parasitic infection in domestic and wild birds in Chittagong and Greater Sylhet, Bangladesh. Pre. Vet. Med; 117 : 305–312.
6. Bhuiyan, M.M.; Khan, M.H.; Khan, M.A.H.; Das, B.C.; Lucky, N.S. and Uddin, M.B. (2005). A study on the comparative performance of different breeds of broiler ducks under farmer's condition at farming system research and development (FSRD) site, Sylhet, Bangladesh. Int. J. Poult. Sci ; 4(8): 596–599 .
7. Pingel, H. (2011). Waterfowl production for food security. Lohmann Inf; 46(2): 32–42.
8. Buckland, R. and Guy, G. (2002). Goose Production. FAO Animal Production and Health FAO, Rome. PP: 154.
9. Aboulaila, M.; El-Bahy, N.; Hilali, M.; Yokoyama, N. and Igarashi, I. (2011). Prevalence of the enteric parasites of ducks from Behera governorate, Egypt. J. Protozool. Res; 21: 36–44.
10. Tarello, W. (2007). Trematodosis in falcons from Kuwait. Rev. Med. Vet; 158: 493–495.
11. Patel, P.V.; Patel, A.I.; Sahu, R.K. and Vyas, R. (2000). Prevalence of gastro-intestinal parasites in captive birds of Gujarat zoos. Zoos. Print. J; 15: 295–296.
12. Cordon, G.P.; Prados, A.H.; Romero, D.; Moreno, M.S.; Pontes, A.; Osuna, A. and Rosales, M.J. (2009). Intestinal and hematic parasitism in the birds of the Almunecar (Granada Spain) ornithological garden. Vet. Parasitol; 165 (3–4): 361–366.
13. Hoque, M.A.; Skerratt, L.F.; Rahman, M.A.; Alim, M.A.; Grace, D.; Gum-mow, B.; Rabiul Alam Beg, A.B.M. and Debnath, N.C. (2011). Monitoring the health and production of household Jinding ducks on Hatia Island of Bangladesh. Trop. Anim. Health Prod; 43: 431–440.
14. Garcia, L.S. and Ash, L. R. (1979). Diagnostic parasitology clinical laboratory manual. 2nd ed. C.V. Mosby Co. St. Louis PP: 174.
15. Yacob, H. T.; Ziad, D. S. and Basu, A.K. (2009). Ectoparasites and gastrointestinal helminthes of chicken of three agro-climatic zones in Oromia Region, Ethiopia. Animal. Biol; 59: 289-297.
16. Soulsby E.J. (1982). Helminths, Arthropods and Protozoa of Domesticated Animals. 7th edn., Bailliere Tindall, London.
17. Urquhart, G.M., Armour, J., Duncan, J.L., Jennings, F.W. (Eds.) (2003). Veterinary Parasitology (2nd ed.). Bookpower with Blackwell Science, UK. Pp: 69.
18. Luna, L.G. (1968). Manual of Histological Staining Methods of the Armed Forces Institute of Pathology. 3rd ed. McGraw Hill, New York PP: 34.
19. Al-Saffar, N. S. J. (2014). Some epidemiological and histopathological study of Retinometra serrata in wild pigeons and ring doves in Baghdad province. 2nd Sci. Conf. Facult. Vet. Med. Univ. Al-Kufa: 78-82.
20. Mezhir, A. H. (2002). Diagnostic and histopathological study of gastrointestinal parasitic helminths of some waterfowl birds in Al-Najaf sea. MSc. thesis, College of Girls Education, University of Al-Kuffa.
21. Jassim, A.N. and Kitan, A.A. (2004). Pathological changes of elementary system of Anas platyrhynchos in Baghdad and Al-Kut – Iraq, resulted by cestodes and nematodes infection. J. Om Salama Sci., 1 (2): 190-194.
22. Chapplle, L.H. (1979). Physiology of parasites. Thomson Litho Ltd, London PP: 497.
23. Dorrestein, G.M. and Hage, M.V. (1997). Marine birds necropsy finding, Bull. Soc. Roy. Dis. Sci., 66(1) : 151-166.

التغيرات النسجية في البط المستأنس المحلي (*Anas platyrhynchos*) المصاب بالديدان الشريطية المزمنة في مدينة بغداد

حيدر محمد علي الربيعي ، محمد ثابت صالح الزبيدي و نصير صادق جعفر

فرع الطفيليات ، كلية الطب البيطري، جامعة بغداد، العراق.

E-mail: dr.haider_alrubaie@yahoo.com

الخلاصة

أُجريت هذه الدراسة للتحري عن التغيرات النسجية المرضية للإصابات المعوية المزمنة بالديدان الشريطية لعشرة من البط المستأنس المحلي للفترة من 2016/9/1 ولغاية 2017 /10/1. أظهرت النتائج حدوث تحطم شديد في الغشاء المخاطي للأمعاء مع انسلاخ وتوسف للخلايا الطلائية مع فقدان شامل لزغابات الامعاء وفقدان كامل للطبقة المخاطية وتحت المخاطية ، فضلا عن تدمير الغدد المعوية وارتشاح كثيف للخلايا الالتهابية ، وخاصة وحيدة الخلية منها في الصفيحة الوسطى للأمعاء مع نخر في الطبقة المخاطية للأمعاء .وأظهرت الطبقة تحت المخاطية ارتشاح للخلايا البلعمية وقليل من الخلايا اللمفاوية ونخر شديد مع تكلس في بعض الغدد المعوية مع توسع كيسي وحطام خلوي في تجويفها محاط بارتشاح للخلايا الالتهابية وحيدة الخلية وبلازما. نستنتج من الدراسة الحالية أن الإصابة بالديدان الشريطية المزمنة تولد ارتشاح للخلايا الالتهابية من الخلايا اللمفاوية ووحيدة الخلية مع تحطم لبعض الغدد المعوية.

الكلمات المفتاحية: البط ، الديدان الشريطية ، زغابات الامعاء ، الصفيحة الوسطى