

Effects Of Topical Petroleum Ether and Ethyl Acetate Fractions from Grape Seed Extract on Imiquimod-Induced Psoriasis Like Skin Inflammation in Mice

Mohammed Fareed Hameed*, Ayah F. Al-Qrimli**

*Department of pharmacology and toxicology - College of pharmacy, Al- Nahrain University.

**Department of pharmacognosy-College of pharmacy, Al- Nahrain University.

Article Info:

DOI: <https://doi.org/10.32947/ajps.v24i2.1062>

Abstract:

Received Aug 2023

Revised Sept 2023

Accepted Sept 2023

Corresponding Author email:

dr.mohammed.fared@nahrainuniv.edu.iq

Orcid: <https://orcid.org/0000-0001-9305-9906>

Background: Grape seed is a natural herb with many suggested pharmacological effects related to many biologically active compounds in its extract and fractions. Grape seed pharmacological effect is investigated in mice psoriasis like model.

Methods: A thirty male albino mice, six weeks' age used in this research and were divided into five groups. Group I apparently healthy. Group II induction group, imiquimod 5% cream once daily used at the back skin of the animal for five days. Group III, IV and V treatments groups. Group III clobetasol ointment 0.05%, group IV Grape seed extract and group V Grape seed petroleum ether fraction for five days. **Results:** A high significant increase was found between the apparently healthy and imiquimod induced group for all of the investigated parameters except munro abscess was significant increase. For the grape seed extract group, it was found A significant difference in immunohistochemistry score of IL17, also significant decrease in vascular endothelial growth factor (VEGF) with high significant decrease of other immunohistopathology measurement like parakeratosis. **Conclusion:** Grape seed extract may have a role in imiquimod-induced psoriasis like skin inflammation in mice treatment which make it a future candidate therapy for psoriasis.

Keywords: psoriasis, vitis vinifera, grape, imiquimod.

تأثير أجزاء الأثير البترولي والاثيل اسيتيت المستخلص من بذور العنب على التهاب الجلد المشابه للصدفية في الفئران المحفزة بالايميكيومود.

محمد فريد حميد*, آيه فاضل القرمللي**

*فرع الادوية والسموم، كلية الصيدلة، جامعة النهرين، بغداد، العراق.

**فرع العقاقير، كلية الصيدلة، جامعة النهرين، بغداد، العراق.

الخلاصة:

تعد بذور العنب من الاعشاب الطبيعية المصاحبة للكثير من التأثيرات الدوائية الممكنة والتي تعود الى العديد من المركبات الفعالة حيويًا في مستخلص واجزاء النبات. تم بحث استعمالها في الالتهاب المشابه للصدفية في الفئران باستعمال مختلف القراءات. حيث تم في هذا البحث استخدام ثلاثون فأر أمهق ذكر بعمر ستة اسابيع وتم تقسيمهم الى خمسة مجاميع في هذا البحث. المجموعة الاولى طبيعية. المجموعة الثانية محفزة باستخدام الايميكيومود 5% مرة يومياً يوضع على جلد ظهر الفار لمدة 5 ايام متتالية. المجموعة الثالثة والرابعة والخامسة يستخدم نفس المحفز وجرعته وبعد 3 ساعات يستخدم العلاج. المجموعة 3 كلوبيتازول مرهم 0.05% والمجموعة 4 مستخلص بذور العنب والمجموعة الخامسة جزء الاثير البترولي من بذور العنب لمدة 5 ايام متتالية. بينت الدراسة زيادة معنوية بين المجموعة الطبيعية والمجموعة الثانية المحفزة لكل القراءات والتحليل. وجدت الدراسة ان مجموعة مستخلص بذور العنب نقصان معنوي في قراءات الكيمياء الهستولوجية المناعية



لانتروكين 17 , اضافة الى نقصان معنوي في عامل النمو البطاني الوعائي مع نقصان كبير معنوي في قراءات الهستوباثولوجيا الاخرى مثل نظير التقرن. تستنتج الدراسة ان مستخلص بذور العنب له دور علاجي في التهاب الجلد المشابه للصدفية في الفئران المحفزة بالايبيكويمود مما قد يجعله مرشح مستقبلي لعلاج الصدفية.

الكلمات المفتاحية: الصدفية، العنب، الايبيكويمود

Introduction:

Vitis vinifera is the mostly used herbal product¹. It is well known that many topical side effects occurred due to the use of corticosteroids. Those side effects were shown to be common and occur concomitantly with the beneficial effect of corticosteroids. Atrophy of the skin, perturbed cicatrization and stretch marks mostly occur. Hypertrichosis, perioral dermatitis, steroid acne, telangiectasia and erythema may occur². Vitis vinifera compose of different phytochemical constituents in the root, cane, stem, leaf, fruit, seed, skin, and pomace. The important compounds are phenolic, flavonoids, aromatic acids, stilbenoids, and proanthocyanidins^{3,4,5}. Research revealed that grape seed extract had antioxidant, anticancer, anti-inflammatory, anti-apoptotic, anti-necrotic, and anti-carcinogenic activity^{6,7,8}. Grape seed extract also have various skin regenerating properties which helped to reduce skin ageing, improve skin appearance, and facilitate wound healing^{9,10}.

Psoriasis is an inflammatory cutaneous disease developed with a chronic scale, and stiff erythematous skin. Psoriasis histologically characterized by proliferation of cutis blood vessels, epidermal hyperplasia and leukocytes inflammatory infiltration that mainly occur in dermis¹¹.

The onset of the psoriasis starts with unknown gene defect or antigen that causes activation of T lymphocyte which depend on the binding of it with antigen presenting cell. T cells will express the T cell receptor (TCR) that recognize the previously presented antigen. The antigen will stimulate the activation causes the naïve T-cells transforming to antigen specific cell.

Antigen specific cell can develop to a memory cell that pass around the body. Increase Th-1 immunity response, neutrophil migration, adhesion molecule up-regulation, keratinocyte reproduction, epidermal hyperplasia, and angiogenesis occur due to the effect of cytokines that secreted from the activated T cells like TNF- α , IL-1, IL-6, IL-17, IL-23, EGF and others¹².

This research is done to investigate the pharmacological effect of grape seed extract and fractions on imiquimod induced psoriasis like inflammation in mice.

Material and Methods

Study Design:

A Randomized, prospective animal study, placebo-controlled research done in the section of pharmacology and toxicology, college of pharmacy, Al-Nahrain University. Thirty albino male, six weeks' age mice were divided randomly into five groups (each of six animals). Group I apparently healthy. Group II induction group, Imiquimod 5% cream (Glenmark) once daily was applied at the back skin of the animal for five days¹³. Group III, IV and V are treatment groups that used the same inducer and dose then after three hours used treatment application. Group III clobetasol ointment 0.05%¹⁴(SDI), group IV Grape seed extract, dose 50mg/kg once daily¹⁵ and group V Grape seed petroleum ether fraction, dose 30mg/kg once daily¹⁶ were used after three hours of using imiquimod 5% cream for five days. The protocols of the study authorized by AL- Nahrain University- college of pharmacy ethical committee (Number 1210, date of approval 18-November-2021).



Preparation of grape extract and fraction:

Vitis vinifera, grapes were collected from local market, and seeds were detached from the flesh manually. The seeds were air dried for 1 week. Two hundred fifty grams of the dried seeds were pulverized into course powder using mechanical grinder¹⁷.

The course powder was extracted with 85% ethanol using soxhlet apparatus for 8hrs. The alcoholic extract was then filtered, and the solvent was evaporated via rotary evaporator. Part of the crude extract was partitioned with petroleum ether (40-60) and ethyl acetate for solvent extraction. The crude and petroleum ether fraction were selected for this study due to high yield^{17,18,19}. Each of them mixed with vaseline to make the required above dose.

Immunohistochemical Evaluation:

Immunohistochemistry (IHC) is done using IHC kit of interleukin -17 (IL-17), Vascular endothelial growth factor (VEGF), and Transforming growth factor (TGF beta 1) catalog number ab193955 (Abcam, USA), ab1316 (Abcam, USA), and SL0086R (Sunlong Biotech, China) respectively. The procedure of IHC was initially evaluated and established by the department of

pathology, consultant center, college of medicine, AL – Nahrain University. The procedure is done according to the catalog's protocols.

Histopathological Evaluation:

At the end of the research, mice were sacrificed using chloroform as inhalant anesthetic. Tissue of the skin was collected from the back of the animal and buffered formaldehyde used for storage²⁰. Scoring system was used for mouse model evaluation histopathology (Munro abscess (1.5), hyperkeratosis (0.5), parakeratosis (1), lengthening of rete ridges (0.5-1.5), acanthosis (1), papillary papillae congestion (1), and dermis lymphocytic infiltrate (0.5-1.5)) each given number according to scale by Baker²¹.

Statistical Analysis:

Statistics used to analyze data by use of SPSS version 26 to find median and range in addition to Mann Whitney test and Kruskal Wallis and take into consideration it is significant result if probability value (p) was less or equal to 0.05. High significant if p value was less or equal to 0.001²².

Results:

Table (1): Comparison of Immunohistochemistry parameters in mice skin

Parameter		Healthy group N=7	Psoriasis group N=6	Clobetasol group N=6	Grape extract group N=6	Grape petroleum ether group N=6
IL-17	Median (Range)	0 (0-1)	3 (1-3)	2 (1-2)	1 (1-2)	1 (1-2)
	P value _a		0.002	0.008	0.035	0.035
	P value _b			0.041	0.026	0.026
	P value _c				0.394	0.394
	P value _d					1.000
	P value _e			0.427		
VEGF	Median (Range)	1 (1-1)	2.5 (2-3)	2 (2-3)	1.5 (1-2)	1 (1-1)



	P value _a		0.001	0.001	0.138	1.000
	P value _b			0.699	0.026	0.002
	P value _c				0.065	0.002
	P value _d					0.180
	P value _e			0.003		
TGF B	Median (Range)	1 (1-1)	3 (2-3)	2 (1-2)	2.5 (2-3)	2.5 (2-3)
	P value _a		0.001	0.051	0.001	0.001
	P value _b			0.026	0.699	0.699
	P value _c				0.065	0.065
	P value _d					1.000
	P value _e			0.041		

a: p value by comparison healthy group with each other group by Mann Whitney test

b: p value by comparison induced group with each treatment group by Mann Whitney test

c: p value by clobetasol with each grape group by Mann Whitney test

d: p value by comparison between two grape groups by Mann Whitney test

e: p value by comparison among treatment groups by Kruskal Wallis test

Data are presented as median (Range), (N) number of animals.

Significant change when P value ≤ 0.05

Highly significant change when P value ≤ 0.001

Table (2): Comparison of histopathological parameters in mice skin

Parameter		Healthy group N=7	Psoriasis group N=6	Clobetasol group N=6	Grape extract group N=6	Grape petroleum ether group N=6
Munro abscess	Median (Range)	0 (0-0)	2 (0-2)	0 (0-0)	0 (0-0)	0 (0-0)
	P value _a		0.008	1.000	1.000	1.000
	P value _b			0.015	0.015	0.015
	P value _c				1.000	1.000
	P value _d					1.000
	P value _e			1.000		
Hyperkeratosis	Median (Range)	0 (0-0)	0.5 (0.5-0.5)	0 (0-0)	0.5 (0.5-0.5)	0.25 (0-0.5)



	P value _a		0.001	1.000	0.001	0.138
	P value _b			0.002	1.000	0.180
	P value _c				0.002	0.180
	P value _d					0.180
	P value _e			0.003		
Parakeratosis	Median (Range)	0 (0-0)	1 (1-1)	0 (0-1)	0 (0-1)	0 (0-0)
	P value _a		0.001	0.366	1.000	1.000
	P value _b			0.065	0.002	0.002
	P value _c				0.394	0.394
	P value _d					1.000
	P value _e			0.119		
Lengthening of rete ridges	Median (Range)	0 (0-0)	1.5 (1.5-1.5)	1.5 (0-1.5)	1.5 (0-1.5)	0 (0-1.5)
	P value _a		0.001	0.051	0.051	0.628
	P value _b			0.394	0.394	0.015
	P value _c				1.000	0.180
	P value _d					0.180
	P value _e			0.151		
Acanthosis	Median (Range)	0 (0-0)	0.5 (0.5-0.5)	0.5 (0.5-0.5)	0.5 (0.5-0.5)	0.5 (0.5-0.5)
	P value _a		0.001	0.001	0.008	0.001
	P value _b			1.000	0.699	1.000
	P value _c				0.699	1.000
	P value _d					0.699
	P value _e			0.368		
Papillary congestion	Median (Range)	0 (0-0)	0.5 (0.5-0.5)	0.5 (0.5-0.5)	0.5 (0.5-0.5)	0.5 (0.5-0.5)
	P value _a		0.001	0.001	0.001	0.001
	P value _b			1.000	1.000	1.000



	P value _c				1.000	1.000
	P value _d					1.000
	P value _e			1.000		
Dermis lymphocytic infiltrate	Median (Range)	0 (0-0)	2 (2-2)	0.75 (0.5-1)	0.5 (0-0.5)	0.25 (0-0.5)
	P value _a		0.001	0.001	0.008	0.138
	P value _b			0.002	0.002	0.002
	P value _c				0.093	0.026
	P value _d					0.394
	P value _e			0.023		

a: p value by comparison healthy group with each other group by Mann Whitney test

b: p value by comparison induced group with each treatment group by Mann Whitney test

c: p value by clobetasol with each grape group by Mann Whitney test

d: p value by comparison between two grape groups by Mann Whitney test

e: p value by comparison among treatment groups by Krustal Wallis test

Data are presented as median (Range), (N) number of animals.

Significant change when P value ≤ 0.05

Highly significant change when P value ≤ 0.001



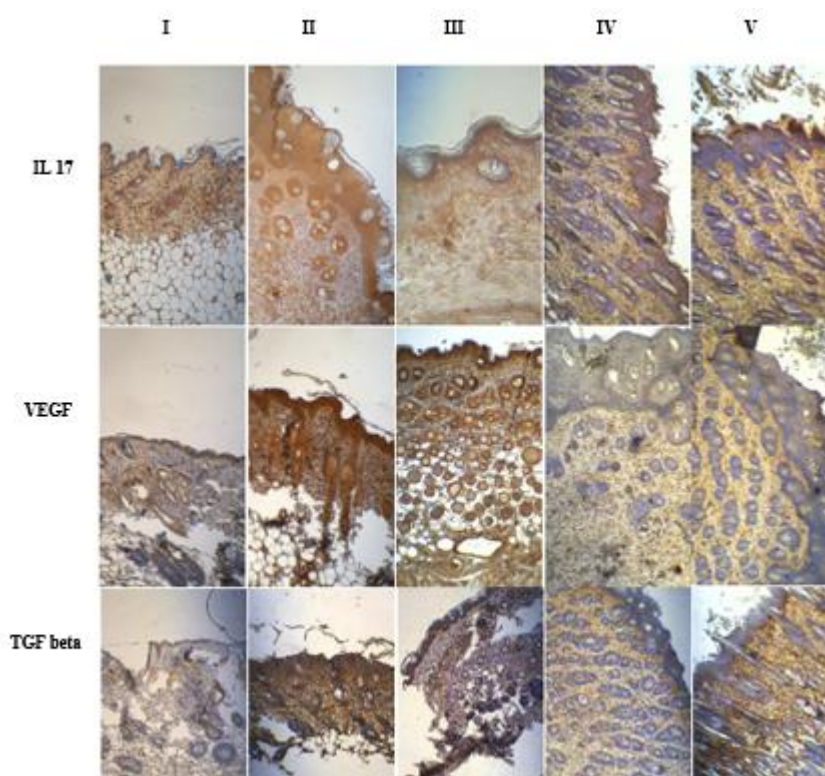


Figure 1: Immunohistochemistry of IL 17, VEGF, and TGF beta of mice skin groups. Group I: Healthy, group II: Psoriasis induction group, group III: Clobetasol group, group IV: Grape extract, and group V: Grape petroleum ether. Group II show more intense brown color indicate positive reactions for IL-17, VEGF, and TGF- beta. Less intensity in color of IL-17 is seen in groups III, IV, and V. Less intensity in color of VEGF is seen in group IV and V. Less intensity in color of TGF-beta is seen only in group III. Olympus microscope lens power 10. Skin samples taken on day five.

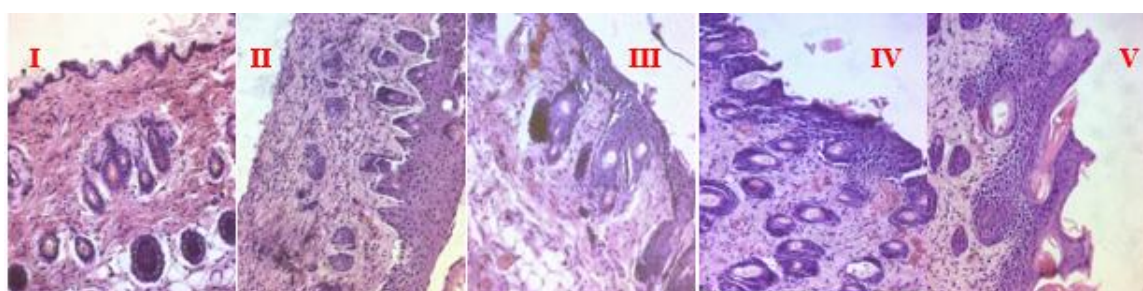


Figure 2: Histopathology sections of mice skin groups. Group I: Healthy, group II: Psoriasis induction group show all histopathology changes of psoriasis like munro abscess, hyperkeratosis, parakeratosis, lengthening of rete ridges, acanthosis, papillary papillae congestion, and dermis lymphocytic infiltrate. Group III: Clobetasol group, group IV: Grape extract, and group V: Grape petroleum ether. Groups III, IV, and V showed better munro abscess and less dermis lymphocytic infiltrate. Group IV and V showed improvement of parakeratosis. Group V showed decrease in lengthening of rete ridges. Stain of H&E of the back mice skin used. Olympus microscope lens power 10. Samples taken on day five.

Discussion

Previous studies were revealed that grape seed extract was known to be rich in proanthocyanidins which are potent anti-inflammatory agents that prevent oxidative stress and it was found that they are soothing psoriasis symptoms by inhibiting the inflammatory response and reducing oxidative damage²³.

Highly significant increase was found in IHC score of VEGF, and TGF-beta1 while significant increase in IL-17, A high significant increase in all of the histopathology parameters and significant increase in munro abcess was found between the healthy and psoriasis group. This indicate that all those are suitable parameters to be use for the evaluation of the grape as a treatment therapy for psoriasis. A previous study published in 2019 had been shown that imiquimod can induce psoriasis in mice were IL-17 target keratinocyte mainly and control infiltration of neutrophil¹³. Vascular endothelial growth Factor-A is originated from activated keratinocytes essentially in psoriasis skin patient²⁴. The microvascular psoriatic lesion proliferation is related to the effect of both VEGF-A and Ang-Tie2 system and the decrease in those mediators may improve psoriasis symptoms of the lesion where they may play a major role in plaque psoriasis vascular proliferation^{25,26}. In relation to IL 17A, imiquimod increase it signaling by increase the epidermal IL17A expression as a result of mobilization of Th 17 cells. The imiquimod induced psoriasis method resemble several human features of inflammatory skin psoriasis²⁷.

More over when comparing the grape extract with psoriasis induced groups, it was found that there were a significant decrease in IL-17 and VEGF. A previous study stated that the psoriatic typical inflammatory marker VEGF inhibited by Vitis vinifera²⁸. Yang et al, in 2022 stated that proanthocyanidins which is found in grape, can decrease the concentration of proteins

and their mRNAs of IL-17, VEGF and others. This indicates the anti-inflammatory effect of Vitis vinifera²³. Also one study use Vitis vinifera seed extract showed the anti-inflammatory role of the extract may be comparable to that of diclofenac sodium with less side effect²⁹. Moreover, Proanthocyanidins are natural extracts that have anti-inflammatory, immunomodulatory, anti-angiogenic and other effects³⁰, where proanthocyanidins inhibit endothelial migration of cells, VEGF expression, and vascularization that made it with good anti- angiogenic properties³¹. One of the main compounds that present in Vitis vinifera is Resveratrol which consider as the main stilbene in grapes ³², Both resveratrol stilbene and pterostilbene have a measured antioxidant activity in 1,1-diphenyl-2-picrylhydrazyl assay ³³. Resveratrol have activated SIRT1³⁴ where the polymorphism of rs7069102 gene related to SIRT1 is one of the psoriasis early onset associations and is responsible for keratinocyte proliferation³⁵. Regarding the histopathology reading scores like munro abscess, parakeratosis, and dermis lymphocytic infiltrate when compared with psoriasis induction group were found significant. The histopathology study of proanthocynidin experiment were found a decrease inflammatory cell infiltration in skin lesions²³.

The petroleum ether group, when compared with psoriasis group, it was found that the immunohistochemistry scores of IL-17 and VEGF were significantly decrease. This indicates better shift toward normal angiogenesis balance due to decrease VEGF. It had been previously being proven the vascular endothelial cell and epidermal keratinocytes are secreted growth factors and cytokines through upregulation of adhesion molecules signaling which induce inflammation of psoriasis⁴³. This led to disturbed the normal balance between the angiogenic mediators (VEGF, TGF- β -transforming growth factor, FGF2-



fibroblast growth factor, and angiopoietin) with anti-angiogenic mediators (Thrombospondins and angiostatin)³⁷. Also, it showed in this petroleum ether fraction group, the histopathology scores of munro abscess, parakeratosis, lengthening of rete ridges, and dermis lymphocytic infiltrate were significantly decreased. This significant change gives an idea about the response to treatment against imiquimod psoriasis like effect. That to say, one of the typical pictures of psoriasis is altered epidermal differentiation where the parakeratosis shows as skin scaling and the imiquimod compound will start the induction of keratinocyte proliferation increasing parakeratosis as showed by the change of nuclei position toward stratum corneum with other changes of plaque psoriasis²⁷.

When the clobetasol group compared to psoriasis induction group, significant decrease was found in IL 17 and TGF-beta1. The benefit of steroid for better psoriasis symptoms occurs partly due to inhibition of Th17 immune signaling and strong antioxidant effect of steroids with other mechanisms³⁸. Also, munro abscess, hyperkeratosis, and dermis lymphocytic infiltrate are significant decrease. A study stated that clobetasol treatment in mice can cause a decrease inflammatory cell infiltrate in the epidermis and dermis with thickening of stratum corneum³⁹. Regarding VEGF both treatment groups of grab extract and petroleum ether show better result than the clobetasol. This indicate better anti-angiogenic properties. Many histopathology measurements had no difference with the clobetasol group indicate good improvement of those measures like munro abscess. No difference was found between the two groups of grapes (group IV and V). When the all-treatment groups were compared, it was found a difference regarding VEGF and TGF -beta in addition to a difference in

hyperkeratosis and dermis lymphocytic infiltration.

Conclusion

Grape seed extract (*Vitis vinifera*) and its petroleum ether fraction have anti-inflammatory and anti-angiogenesis effect via thier depressive effect on IL 17 and VEGF respectively in addition to other histopathological chaneges improvment of munro abscess and less dermis lymphocytic infiltration which may indicate a promise future therapy for psoriasis. More extra-research is needed with larger number and other species of animal to confirm the pharmacological action of grape seed.

Declaration of competing interest

No known personal or competing financial interest's completion.

References:

- 1- Donno D, Turrini F, Boggia R, Guido M, Gamba G, Mellano MG, et al. *Vitis vinifera* L. pruning Waste for Bud-Preparations as Source of Phenolic Compounds- Traditional and Innovative Extraction Techniques to Produce New Natural Products. *Plants*. 2021 Oct 20;10(11):2233.
- 2- Schacke H, Wolf Dietrich D, Khusru A. Mechanisms involved in the side effects of glucocorticoids. *Pharmacology & Therapeutics*. 2002 Oct;96(1):23–43. <https://linkinghub.elsevier.com/retrieve/pii/S0163725802002978>
- 3- Filocamo A, Bisignano C, Mandalari G, Navarra M. In Vitro Antimicrobial Activity and Effect on Biofilm Production of a White Grape Juice (*Vitis vinifera*) Extract. *Evidence-Based Complementary and Alternative Medicine*. 2015; 2015:1–5. <http://www.hindawi.com/journals/ecam/2015/856243/>
- 4- Radulescu C, Buruleanu LC, Nicolescu CM, Olteanu RL, Bumbac M, Holban



- GC, et al. Phytochemical Profiles, Antioxidant and Antibacterial Activities of Grape (*Vitis vinifera* L.) Seeds and Skin from Organic and Conventional Vineyards. *Plants*. 2020 Oct 30;9(11):1470.
<https://www.mdpi.com/2223-7747/9/11/1470>
- 5- Goufo P, Singh RK, Cortez I. A Reference List of Phenolic Compounds (Including Stilbenes) in Grapevine (*Vitis vinifera* L.) Roots, Woods, Canes, Stems, and Leaves. *Antioxidants*. 2020 May 8;9(5):398.
<https://www.mdpi.com/2076-3921/9/5/398>
- 6- Ma Z, Zhang H. Phytochemical Constituents, Health Benefits, and Industrial Applications of Grape Seeds: A Mini-Review. *Antioxidants*. 2017 Sep 15;6(3):71.
<http://www.mdpi.com/2076-3921/6/3/71>
- 7- Yilmaz Y, Toledo RT. Health aspects of functional grape seed constituents. *Trends in Food Science & Technology*. 2004 Sep;15(9):422–33.
<https://linkinghub.elsevier.com/retrieve/pii/S0924224404001128>
- 8- Varzakas T, Zakynthinos G, Verpoort F. Plant Food Residues as a Source of Nutraceuticals and Functional Foods. *Foods*. 2016 Dec 10;5(4):88.
<http://www.mdpi.com/2304-8158/5/4/88>
- 9- Sharif A, Akhtar N, Khan MS, Menaa A, Menaa B, Khan BA, et al. Formulation and evaluation on human skin of a water-in-oil emulsion containing Muscat hamburg black grape seed extract. *Int J Cosmet Sci*. 2015 Apr ;37(2) :253–8.
<https://onlinelibrary.wiley.com/doi/10.1111/ics.12184>
- 10- Gupta M, Dey S, Marbaniang D, Pal P, Ray S, Mazumder B. Grape seed extract: having a potential health benefit. *J Food Sci Technol*. 2020 Apr;57(4):1205–15.
<http://link.springer.com/10.1007/s13197-019-04113-w>
- 11- Tokuyama M, Mabuchi T. New Treatment Addressing the Pathogenesis of Psoriasis. *IJMS*. 2020 Oct 11;21(20):7488.
<https://www.mdpi.com/1422-0067/21/20/7488>
- 12- Jain A, Ramesh V, Das R. Current concepts in the pathogenesis of psoriasis. *Indian J Dermatol*. 2009;54(1):7. <http://www.e-ijid.org/text.asp?2009/54/1/7/48977>
- 13- Moos S, Mohebiany AN, Waisman A, Kurschus FC. Imiquimod-Induced Psoriasis in Mice Depends on the IL-17 Signaling of Keratinocytes. *Journal of Investigative Dermatology*. 2019 May;139(5):1110–7.
<https://linkinghub.elsevier.com/retrieve/pii/S0022202X19300223>
- 14- Pukale SS, Sharma S, Dalela M, Singh AK, Mohanty S, Mittal A, et al. multi-component clobetasol-loaded monolithic lipid-polymer hybrid nanoparticles ameliorate imiquimod-induced psoriasis-like skin inflammation in Swiss albino mice. *Acta Biomaterialia*. 2020 Oct; 115:393–409.
<https://linkinghub.elsevier.com/retrieve/pii/S1742706120304803>
- 15- Albrahim T, Robert A. Renal protective effects of grape seed extract treatment against Eltroxin-induced hyperthyroidism, kidney damage, and oxidative stress in male mice. *Environ Sci Pollut Res*. 2020 May ;27(15) :17963–71.
<https://link.springer.com/10.1007/s11356-020-08210-8>
- 16- Hwang IK, Kim DW, Park JH, Lim SS, Yoo KY, Kwon DY, et al. Effects of grape seed extract and its ethylacetate/ethanol fraction on blood glucose levels in a model of type 2 diabetes: ANTIDIABETIC EFFECT



- OF GRAPE SEED EXTRACT. *Phytother Res.* 2009 Aug;23(8):1182–5. <https://onlinelibrary.wiley.com/doi/10.1002/ptr.2779>
- 17- Al Juhaimi F, Özcan MM. Effect of cold press and soxhlet extraction systems on fatty acid, tocopherol contents, and phenolic compounds of various grape seed oils. *J Food Process Preserv.* 2018 Jan;42(1): e13417. <https://onlinelibrary.wiley.com/doi/10.1111/jfpp.13417>
- 18- Baydar NG, Özkan G, Sağdıç O. Total phenolic contents and antibacterial activities of grape (*Vitis vinifera* L.) extracts. *Food Control.* 2004 Jul;15(5):335–9. <https://linkinghub.elsevier.com/retrieve/pii/S0956713503000835>
- 19- Shaukat UA, Anwar F, Akhtar MT, Qadir R, Zahoor S, Saba I, et al. Variations in Physico-Chemical and Antioxidant Attributes of Grape Seed Oil as Function of Extraction Techniques. *JSM.* 2022 Jul 31;51(7):2087–96. http://www.ukm.my/jsm/pdf_files/SM-PDF-51-7-2022/12.pdf
- 20- Verma SK, Lindsay DS, Grigg ME, Dubey JP. Isolation, Culture and Cryopreservation of *Sarcocystis* species. *Current Protocols in Microbiology* [Internet]. 2017 May [cited 2023 May 17];45(1). Available from: <https://onlinelibrary.wiley.com/doi/10.1002/cpmc.32>
- 21- Baker BS, Brent L, Valdimarsson H, Powles AV, Al-Imara L, Walker M, et al. Is epidermal cell proliferation in psoriatic skin grafts on nude mice driven by T-cell derived cytokines? *Br J Dermatol.* 1992 Feb;126(2):105–10. <https://academic.oup.com/bjd/article/126/2/105/6686113>
- 22- Peacock J, Peacock PJ. *Oxford handbook of medical statistics.* Oxford: Oxford University Press; 2011.
- 23- Yang Y, Zhao Y, Lai R, Xian L, Lei Q, Xu J, et al. An Emerging Role of Proanthocyanidins on Psoriasis: Evidence from a Psoriasis-Like Mouse Model. *Arcanjo DDR, editor. Oxidative Medicine and Cellular Longevity.* 2022 Jun 8; 2022:1–13. <https://www.hindawi.com/journals/omc/1/2022/5800586/>
- 24- Socha M, Kicinski P, Feldo M, Zubilewicz T, Pietrzak A. Assessment of selected angiogenesis markers in the serum of middle-aged male patients with plaque psoriasis. *Dermatologic Therapy* [Internet]. 2021 Jan [cited 2023 May 17];34(1). Available from: <https://onlinelibrary.wiley.com/doi/10.1111/dth.14727>
- 25- Nofal A, Al-Makhzangy I, Attwa E, Nassar A, Abdalmoati A. Vascular endothelial growth factor in psoriasis: an indicator of disease severity and control. *Journal of the European Academy of Dermatology and Venereology.* 2009 Jul;23(7):803–6. <https://onlinelibrary.wiley.com/doi/10.1111/j.1468-3083.2009.03181.x>
- 26- Xue Y, Liu Y, Bian X, Zhang Y, Li Y, Zhang Q, et al. miR-205-5p inhibits psoriasis-associated proliferation and angiogenesis: Wnt/ β -catenin and mitogen-activated protein kinase signaling pathway are involved. *J Dermatol.* 2020 Aug;47(8):882–92. <https://onlinelibrary.wiley.com/doi/10.1111/1346-8138.15370>
- 27- Van Der Fits L, Mourits S, Voerman JSA, Kant M, Boon L, Laman JD, et al. Imiquimod-Induced Psoriasis-Like Skin Inflammation in Mice Is Mediated via the IL-23/IL-17 Axis. *The Journal of Immunology.* 2009 May 1;182(9):5836–45. <https://journals.aai.org/jimmunol/article/182/9/5836/104045/Imiquimod-Induced-Psoriasis-Like-Skin-Inflammation>



- 28- Sangiovanni E, Di Lorenzo C, Piazza S, Manzoni Y, Brunelli C, Fumagalli M, et al. Vitis vinifera L. Leaf Extract Inhibits In Vitro Mediators of Inflammation and Oxidative Stress Involved in Inflammatory-Based Skin Diseases. *Antioxidants*. 2019 May 16;8(5):134. <https://www.mdpi.com/2076-3921/8/5/134>
- 29- Chopra A, Geetha RV. In vitro anti-inflammatory activity of vitis vinifera seed extract using albumin denaturation assay. *plant cell biotechnology and molecular biology*. 2020 Nov 3;21(49–50):33–7.
- 30- Lai R, Xian D, Xiong X, Yang L, Song J, Zhong J. Proanthocyanidins: novel treatment for psoriasis that reduces oxidative stress and modulates Th17 and Treg cells. *Redox Report*. 2018 Jan 1;23(1):130–5. <https://www.tandfonline.com/doi/full/10.1080/13510002.2018.1462027>
- 31- Li Q, Wang X, Dai T, Liu C, Li T, McClements DJ, et al. Proanthocyanidins, Isolated from Choerospondias axillaris Fruit Peels, Exhibit Potent Antioxidant Activities in Vitro and a Novel Anti-angiogenic Property in Vitro and in Vivo. *J Agric Food Chem*. 2016 May 11;64(18):3546–56. <https://pubs.acs.org/doi/10.1021/acs.jafc.6b00236>
- 32- Ali K, Maltese F, Choi YH, Verpoorte R. Metabolic constituents of grapevine and grape-derived products. *Phytochem Rev*. 2010 Sep;9(3):357–78. <http://link.springer.com/10.1007/s11101-009-9158-0>
- 33- Mohammed Ridha Jawad, Ghaith Ali Jasim. Biochemical and Histopathological evaluation of prostatic tissue under effect of Pterostilbene in benign prostatic hyperplasia rat model. *Al Mustansiriyah J Pharm Sci*. 2023 May 23;23(2):196–213. <https://ajps.uomustansiriyah.edu.iq/index.php/AJPS/article/view/1022>
- 34- Joudah MS, Al-Sudani BT, Arif IS. SIRT1 activators as novel therapy for cancer. *Al Mustansiriyah J Pharm Sci*. 2019 Aug 1;19(3):28–41. <https://ajps.uomustansiriyah.edu.iq/index.php/AJPS/article/view/572>
- 35- Pektas SD, Dogan G, Edgunlu TG, Karakas-Celik S, Ermis E, Tekin NS. The Role of Forkhead Box Class O3A and SIRT1 Gene Variants in Early-Onset Psoriasis. *Indian J Dermatol*. 2018;63(3):208–14.
- 36- Danilenko DM. Review Paper: Preclinical Models of Psoriasis. *Vet Pathol*. 2008 Jul;45(4):563–75. <http://journals.sagepub.com/doi/10.1354/vp.45-4-563>
- 37- Goodwin AM. In vitro assays of angiogenesis for assessment of angiogenic and anti-angiogenic agents. *Microvascular Research*. 2007 Sep;74(2–3):172–83. <https://linkinghub.elsevier.com/retrieve/pii/S0026286207000611>
- 38- Omala A, Bale S, Godugu C. Protective effects of nanoceria in imiquimod induced psoriasis by inhibiting the inflammatory responses. *Nanomedicine*. 2020 Jan;15(1):5–22. <https://www.futuremedicine.com/doi/10.2217/nnm-2018-0515>
- 39- Artym J, Kocięba M, Zaczyńska E, Kochanowska I, Zimecki M, Kałas W, et al. Topically applied azaphenothiazines inhibit experimental psoriasis in mice. *International Immunopharmacology*. 2018 Jun; 59:276–86. <https://linkinghub.elsevier.com/retrieve/pii/S1567576918301310>

