

HISTOLOGICAL STUDY OF EARLY EVENTS DURING WOUND HEALING IN RABBITS

Abdalbari A. Alfars

Department of internal, preventive medicine, surgery and obstetrics.College of Veterinary of
Medicine , University of Basrah.Basrah-iraq

(Received 25 March 2009 ,Accepted 4 June 2009)

Key words: wound healing, inflammatory cells, wound.

ABSTRACT

An attempt was made to have a better understanding of wound healing in skin of adult rabbits. Stages of healing showed in during microscopic changes in epidermal and dermal regions. The ratio of changes was rapid up during 48 hours. The epithelium invaded actively underlying connective tissue. There was a closely packed mass of cells immediately subjacent to the epithelium, also there was an appearance of collagen fibers laying between the cells. Close contact between dermal and epidermal cells was happened at the time when epithelial invasion and basement membrane was reformed close to the epithelium.

INTRODUCTION

The wound healing is a complicated, interactive integrative process that commences right after injury invading cellular and chemotaxis activity (1, 2).

The wound is a physical bodily injury and characterized by disruption of the normal continuity of body structures. Wounding may cause injury in superficial cutaneous structures and reach to structures underlying the skin (3).

The tolerance of injury was a varies with tissue type. Therapeutic considerations are based on the type of skin wound and often determine the amount of tissue damage (4, 5).

The aim of present research is to study and emphasize on the results which ,achieved by the previous studies determined the early changes of wound healing by evaluated histologically. This experiment was approved by hyaluronic acid for wound healing.

MATERIALS AND METHODS

Eighteen male, 5-7 month- old rabbits weighing about 1.5-2 kg. were acclimatization during one week period and randomly divided into three groups of six animals of each group. The animals were fed a standard laboratory diet and had access to drinking water.

A combination of Acepromazine meleate (40 mg/ kg. B.W.), ketamine (10 mg/kg B.W.)and xylazine (5 mg/kg B.W.) was intramuscularly injected to anesthesia the animals.

3.5 cm long parallel full thickness skin incisions were performed under aseptic conditions on the left and right side of the experimental rabbits and then put of hyaluronic acid on incision immediately after prepared from source and then suturing by 4 simple sutures.

The rabbits were scarified by ether inhalation, and removed of skin wound from the body after 72 hr. (group I), 120 hrs. (Group II) and 168 hrs. (Group III). The tissue specimens were processed routinely for light microscope.

The rabbits were evaluated in each group; we were interested in the following morphological changes-epithelization, keratinization of dermis, presence of inflammatory cells, ulceration, collagen fibers.

RESULTS

During the post surgery period, the animals remained healthy, without clinical evidence of infection. The microscopic observation also confirmed the aseptic conditions during the wounding in all groups.

In group I the inflammatory reaction was dominant. On the skin surface, necrosis of skin tissue was saturated as a consequence of mechanical damage . This stage was observed also under the tissue necrosis. The demarcation line consisted of polymorphonuclear (PMN), the epidermis was thickened at its cut edges (Fig. 1)

In group II it was possible to observe that necrotic on the surface was almost removed and the scab was forming, thickened edges of epidermis –keratinocytes migrated beneath the scab (Fig. 2) We also recorded the epithelization from hair follicles. They were almost always present in wounds during three days of the healing process.

The healing period five days after surgery was characterized by almost total regression of inflammatory process. This reaction was confirmed by the number polymorphonuclear leukocytes (PMNL). The major marker of acute inflammation if those cells were present, they were found epithelial layers (Fig. 3).

After seven days the histological section shows a completely finished reepithelization process. The thickness of epidermis was similar to intact epidermis and this period showed a typical histological picture of proliferative phase with found of layer of fibroblast and new vessels (Fig-4).

In summary, after early stages of healing. All animals exhibited completely finished reepithelization, disappearance of acute inflammatory signs and reorganization of granulation tissue devoid of cutaneous attachments as well as the presence of regenerating myofibers.

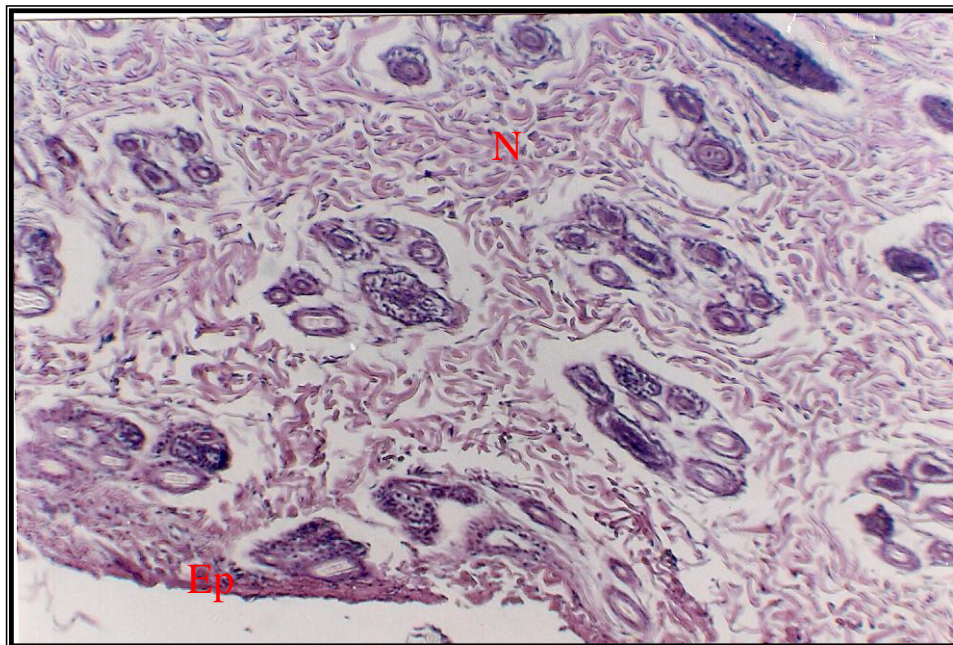


Fig. (1): In wound show the epidermis (Ep) was thickened at its cut edges & inflammatory reaction (N) (400X, H&E)

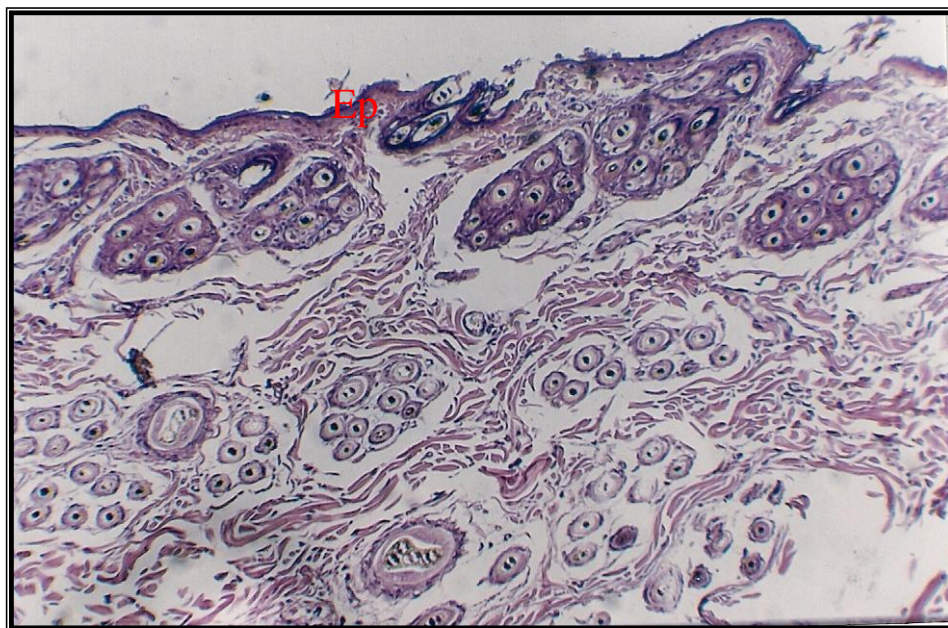


Fig.(2): show the epidermis (Ep) was thickened at its cut edges& tissue necrosis and erosion (400X . H&E)

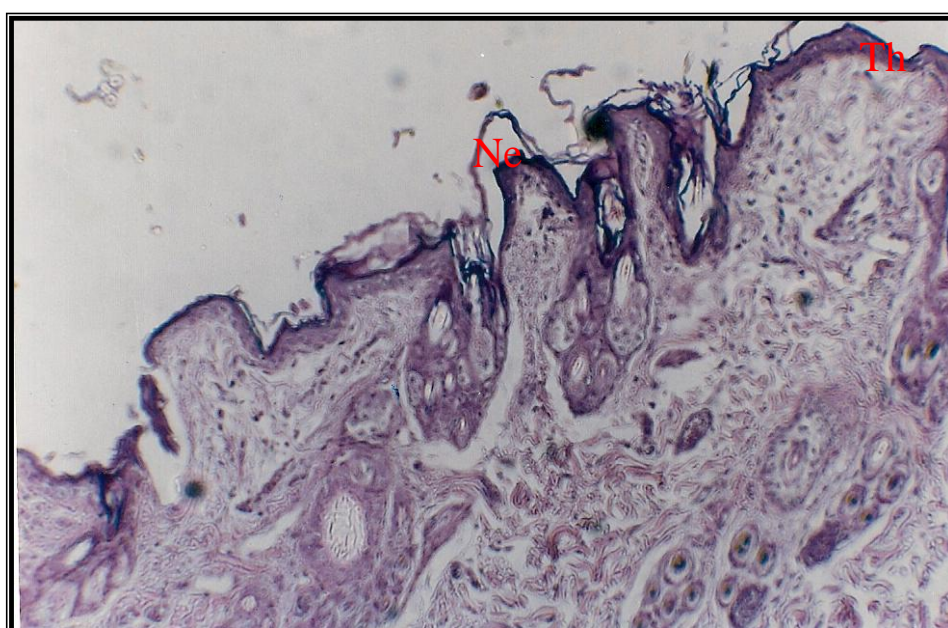


Fig.(3): observe that necrotic (Ne) on the surface was almost removed and the scab was forming, thickened (Th) edges of epidermis –keratinocytes migrated beneath the scab (400X , H&E)

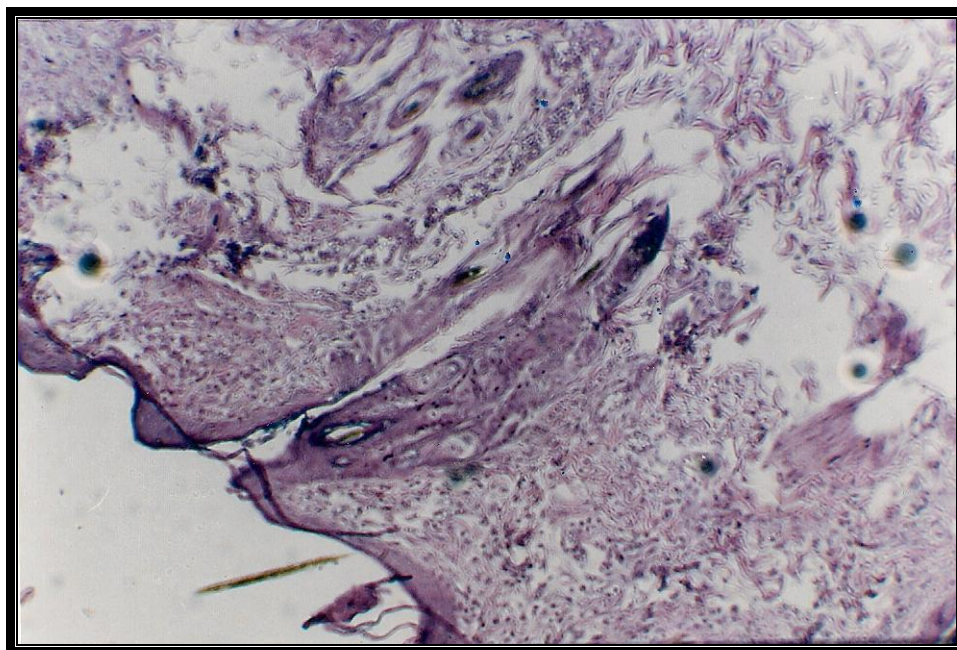


Fig.(4): The major marker of acute inflammation if those cells were present, they were found epithelial layers (400X , H&E)

DISCUSSION

The inflammatory response is initiated very soon after the trauma on wound event, Its the first phase of the wound healing. During this response the wound and surrounding tissues become inflamed and cells, particularly neutrophils and monocytes are mobilized to infiltrate the clot and start the processes involved in granulation tissue synthesis (6).

In addition, the cell surface binding edges of wound have to myofibril contraction, also present of fibroblasts other cells. A fibrin or fibrinogen was showed to interact specifically with platelets (7). Based on these precedents it is reasonable to propose that fibrin specific interact.

A core premise of the present study is that interaction between the cell surface/ cytoskeleton and the extracellular matrix is interdependent and dynamic (8).

The wound healing process of rabbit's skin was histologically and chronologically determined during in the early stages period. Other studies evaluated the histologically only certain time intervals as in 72, 120 and 168 hours (9, 10 and 11).

The healing process of three groups was studied. The complete regeneration of the rabbit's epidermis was finished on the six day after the surgery, which is comparable to humans (12, 13, 14 and 15).

The wound healing is complex and not fully understood however, sufficient evidence supports its role in accelerating healing (16, 17 and 18).

In conclusion, the healing process of the epidermis, dermis in rabbits is faster, composition with to the healing of human skin and striated muscle. Therefore, results of this work can serve as an experimental model for further research using external factors by which the wound healing can be favorably influenced.

دراسة نسجية للأحداث المبكرة لألتئام الجروح في الأرانب

عبدالباري عباس الفارس

فرع الطب الباطني والجراحة والتوليد، كلية الطب البيطري-جامعة البصرة البصرة -العراق

الخلاصة

تم القيام بهذه المحاولة لغرض الحصول على فهم أفضل لشفاء الجروح في جلد الأرانب البالغة، وقد أوضحت عملية الشفاء هذه تغيرات مجهريه تم اثباتها في مناطق الادمة وتحت الأدمة ، وكانت نسبة التغيرات سريعة لغاية ثمان وأربعون ساعة ، وغطت الخلايا الطائنية بشكل فعال النسيج الرابط الموجود . وكانت مجموعه من الخلايا مترابطة بشكل دقيق وملاصق بشكل مباشر في منطقة تحت الأدمة مع وجود ألياف غراوية بين الخلايا . ووجد ترابطا دقيقا" بين خلايا الادمة عندما تشكل الغشاء القاعدي والاكتنساء أطلاني .

REFERENCES

- 1- Probst, C.W. (1993). Wound healing and specific tissue regeneration. In: Text book of small animal surgery by Slatter, D., Ch. 4 (1, 2) ed. W.B. Saunders Company. Pp.: 53-63.
- 2- Slatter, D. (1995). Wound healing and specific tissue regeneration. Experimental Biology and Molicine.; 228: 724-729.

- 3- Wiancko, K.B.; King, S. and Mackenzie, W.C. (1961). Wound healing incisions and suturing. Canada. Med.Asso.J.; 84: 945-960.
- 4- Romo, T. (2003). Wound healing skin. Medicine Com.Inc. 1-11.
- 5- Rosin, E.; Dow, S.W.; Daly, W.R. and Patersen, S.W. (1993). Surgical wound infection and use of antibiotics. Ann.plast.surg.; 18:47-50.
- 6- Irvin, T.T. (1995). Surgical wound healing in rats. J.biol.Chem.; 290: 14854-14860.
- 7- Marguerie, G.A. (2000). Human platelets possess an inducible and saturable receptor specific for fibrogen. J.biol.chem.; 290: 14867-14870.
- 8- Toole, F. (1990). Wound tissue can utilize a polymeric templae to synthesize a functional of skin. Science.; 215: 174.
- 9- Milaram, J.; Shara, L. and Kass, P. (2004). The effect of short intensity magnetic field pulses on healing of skin wounds in rats. Bioelectromagnetics.; 271-277.
- 10- Menetery, J. and Boschp, V. (2003). Progressive effects of diabetes mellitus on the healing and its biological action upon myofibroblasts. Laser surgery Med.; 32:239-244.
- 11- Tao, A.; Aslan, L. and Ceylan, E. (2003). The effect of growth factor in early phase in wound healing in dogs. Acta.Vet.Brno.; 72:273-277.
- 12- Rajabi, A.M. and Rajabi, F. (2007). The effect of estrogen on wound healing in rats. Pakistan J. Med.Scie.; 23(3): 349-352.
- 13- Dirk, A.; Thomas, S. and Windolf, J. (2000). A new approach to the treatment of recalcitrant wounds. Wound: 12(5): 111-117.
- 14- Hall, G. and Phillips, T. (2005). The effect of estrogen and hormone replacement therapy on the skin. J.Am.Acad. Dermatol.; 53(4): 555-68.
- 15- Jos, A.; Bosch, C. and Engelaud, G. (2007). Depressive symptoms predict mucosal wound healing. Am.Psychosomatic Society; 69: 597-605.
- 16- Fisher, S.E.; Frame, J.W.; Browne, R.M. and Tranter, R.M. (1983). A comparative histological study of wound healing following Co₂ caser and conventional surgical excision of canine buccal mucosa. Arch.Oral.Biol.; 28(4): 287-91.
- 17- Horne, R.S. and Jurley, J.V. (2007). Wound healing in foetal sheep: a histological and electron microscope study. British J. of plastic surgery; 45(5): 333-344.

- 18- Brown, M. and Kate, M. (1988). Electrical stimulation effects on cutaneous wound healing in rabbits. Phys. Ther.; 68(6): 955-960.