

Toxicologic Pathology Study of uranyl acetate by oral intubation on Sprague - Dawelly Rats.

Saleh K. Majeed*

Inam B. Falih**

Basam F.AL-Shammary***

PhD

PhD

PhD

Summary:

Background: Uranyl acetate (UA) mostly a kidney poison or chemical toxic and not nearly so much radiological also is not accumulative toxic, so it is not concentrated in the food chain nor would it cause pathological condition due to increase levels from expomers. Therefore, the study aimed to detect the target organ as most of the lethal dose (LD50) male rats died within 24 hours.

Methods: Study was done on (120) male rats of 2 months old, at varying dosage level of uranyl acetate ranging from LD 50 of 2.5 and 1.5gm/kg and varying dosage level, by oral intubation. There were (40) rats for LD 50 were given single oral dose from 2.5 to 1.5 gm /kg every day. Eighty rats for the main study, (20) rats each group as intermediate, low and high dose. After LD 50, the trail was done on groups of rats, starting as high dose as 150 mg / kg day by day then followed by intermediate dose 100 mg / kg and low dose level 75 mg / kg b.w every other day respectively with control untreated group. Duration of the study (55 day) on all rats were killed and followed by histopathological examination.

Results: The histopathological changes ranged from sever necrosis of the proximal convoluted tubules result in renal failure and that was mainly at the LD 50 and maximum level dose, rats either died after few hours or live for few days. Showing arched back and killed in poor condition, while rats treated with intermediate and low dose level showed less sever changes, mostly as dilated cortical tubules and / or cortical tubular basophilia, , only with occasional cortical tubular necrosis .

Conclusion: The Present study showed that the kidney, proximal convoluted tubules, the target for toxicological pathology of heavy metal and the main cause of death was renal failure in sever morbid cases.

Keywords: Uranyl acetate -kidney -rat dilated cortical tubules - renal failure.

Fac Med Baghdad
2010; Vol. 52, No. 1
Received May 2009
Accepted July 2009

Introduction:

Uranium (U) is heavy metal used in the nuclear fuel cycle, antitank weapons, tank armor and also a pigment to color ceramics and glasses (1). U compounds are toxic and their toxicity is mediated either by their radioactivity or their chemical properties. Both mammalian kidney and bones are the main organs affected by U toxicity (2). Natural U consist of a mixture of three radioactive isotopes which are identified mass numbers U-238 (99.27% by mass), U-235 (0.724%) and U-234 (0.0054 %) (3). About 98% of the U entering the body via ingestion is not absorbed but is eliminated in the urine and feces, and the rate of excretion depending, even in human, in part on the PH of tubular urine, under alkaline conditions most of uranyl hydrogen carbonate complex is soluble and is excreted in the urine if the PH is acidic, in the tubular wall which may then impair tubular function (4,5). Although the

most characteristic response to depleted uranium (DU) either short or long term is renal dysfunction, U also localized within the central nervous system, Testes, L.N. and spleen suggesting the potential for U to cause health problems at these sites (6). Also U induces significant oxidative stress in rat lung epithelial cell followed by concomitant decrease in the antioxidant potential of the cells (7). Uranyl acetate (UA) was introduced by Straggle 1954 to stain DNA for electron microscopy, uranyl ion forms a 1:1 complex with vitamin C that catalyzed hydrolysis of DNA (strand breaks) in a concentration of vitamin C to U (8). U exposure is weakly associated proximal tubules function without a clear threshold which suggest that even low concentration in drinking water can causes nephrotoxic effects and the concentration of U in drinking water may be with the range of the proper of 2-30 µg / L (9).

The nephrotoxicity of U was recognized in the 19th century. Hodge gives a good reviews of the history of U poisoning, other reviews of U toxicity in the decades following world II when the nuclear industry grew in these countries with nuclear capabilities (10, 11). Acute U poisoning (14.4 mg/kg subcutaneously) in rats exhibited enlargement of the sub/

*Research Center for toxicological pathology. Basra University

** Dept. of Pathology College of Vet Medicine, Baghdad University.

*** Dept. of Anatomy - College of Vet Medicine, DIALA University.

basilar compartment in proximal, distal and collecting tubules. There was apical swelling and vacuolization in the first two days after treatment with U, at the time of polyuria is developing. Necrotic debris appears in the tubular lumen, which appears to be due to tubular resorption of the lumen material. Necrosis was extensive in the proximal tubes following loss of microvillus of brush border membrane and swelling of mitochondria and endoplasmic reticulum (11, 12). A chronic ingestion of DU leads mainly to kidney deterioration that responsible for decreasing of RBC count in rats, spleen erythropiosis and molecules involved in erythrocyte degradation within renal anemia (13). Previous studies have demonstrated that prior exposures to U can produce acquired resistance to U nephrotoxicity (14), but observations by Tolson et al suggested that heat shock proteins are elevated in acquired resistance to UA in vivo, they are not responsible for diminished U nephrotoxicity but are an epiphenomenon of tubular epithelial regeneration (15). Vitamin C and E, and allopurinol respectively, while the systolic and diastolic blood pressures were not significantly reduced (0.52%, 2.25%, and 0.68%), (1.8%, 1.59%, and 1.82%) after 14 day therapy with methyldopa only, or supplementation with vitamin C, and vitamin E respectively as compared to the baseline systolic and diastolic blood pressure ($p > 0.05$). Table (2).

Materials and Methods:

120 males of Sprague Dawley white rats were used in present study started at about 2 months old; animals left for two weeks for accubinate, 40 rats were used for LD50. Dose level of uranyl acetate started from 2.5 gm / kg. b.w., then the dose choused as 1.5 gm / kg body weight as there LD50 dose. After that, three doses level were chosen as intermediate, low and high dose, and those were the low dose was 1/20 of the LD50, which was 1.5 gm/kg. b.w, the intermediate dose was 1/15 of the LD50 dose and the high toxic dose was 1/10 of the LD50, those doses are as 75 mg/kg the low dose level, 100 mg/kg the intermediate dose level and 150 mg/kg the high dose level. For high dose (150 mg/kg) 20 rats, treatment day by day, none of treated rates reached day 55 of treatment. The other doses, low and intermediate used every other day. Uranyl acetate was dissolved in normal saline and given to the rats by oral intubations treated rats with high dose (150 mg/kg) started to die on day 6 of treatment, none of them survived beyond day 55. Specimen from the kidney were managed to be taken from 8 rats of the LD50 at 2 gm /kg and 8 rats of 2.5 gm/kg. Also during the study samples of the kidneys were taken from rats killed from low and /or intermediate dose levels. Samples were processed, and sections were cut out at 4-7 micrometers thickness then stained with hematoxylin and eosin (16).

Results:

Clinical observation: Rats, especially those of LD50 Trial, showed breathing difficulties before death, they appeared clinically similar to human patients suffering from emphysema or sever asthma attack. Those which survived for few days showed sever loss of weight at a rate of 10-12 gram a

day, those in morbid condition, showed, piloerection, rough hair, half closed eyes, dirty hunched back (arched back), they suffered attacks of convulsion movements before they die, hemorrhagic macroscopic areas of the lungs and stomach, which probably due to faulty dosing. Macroscopic Examination: Rats killed or died showed dark stained kidneys and hemorrhage in lungs and /or stomach probably due to faulty dosing procedures. Other visceral organ did not showed significant macroscopic changes, except small spleen which appear with enlargement of adrenal glands. Histopathological changes of the Kidneys: Rats killed in extremis from 2.5 gm/kg LD50 histopathological examination of those kidneys, showed complete necrosis of proximal convoluted tubules, such rats definite the case of the moribund condition was the renal toxic changes which could lead to renal failure fig. (1). While those of the intermediate & low dose levels showed less sever renal changes, as the extents of necrosis of proximal convoluted tubules was far less than the one with 2.5 gm/kg LD50, they were only present as scattered necrotic tubules fig(2) but majority of the proximal convoluted tubules showed varing degrees of dilatation fig(3). Some of the convoluted tubules which filled with eosinophilic portentous casts fig(4) those dilated tubules is intermingled with areas of proximal convoluted tubules showing regenerative cortical tubular basophilic fig (5). Such tubules would take more of the hematoxylin stain showing basophilic .Glomerulus's showed high cellularity & thickened Bowman's capsule fig (6). The massive necrosis of proximal convoluted tubules, of those rats of LD50, beside the massive areas of necrosis proximal tubules there was evidences of interstitial fibrosis and mononuclear cells infiltration fig.(6) the lesions demonstrated that the toxic effects that was so sever did not give time for the cortical tubules to react by showing dilated cortical tubules or cortical tubules basophilic or presence of portentous casts in the proximal tubules the lesion definite to be shown that the present toxic material was characterized by having the kidney as the target organ . While the control untreated group does not showed any significant clinical, macroscopical and microscopical changes.

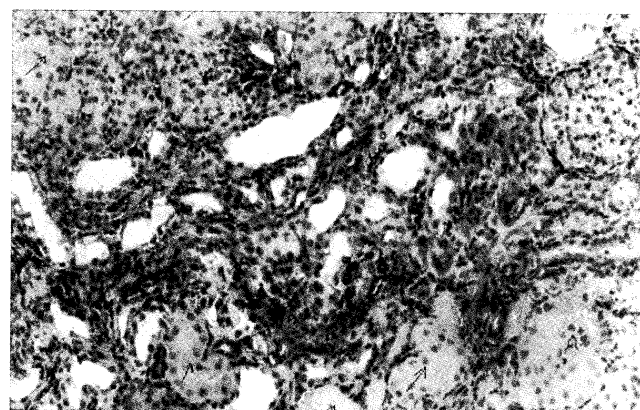


Fig (1) Section of Kidney in rat (from 2.5gm/kg LD50) Show massive necrosis of proximal convoluted tubules (H&E 20 X)

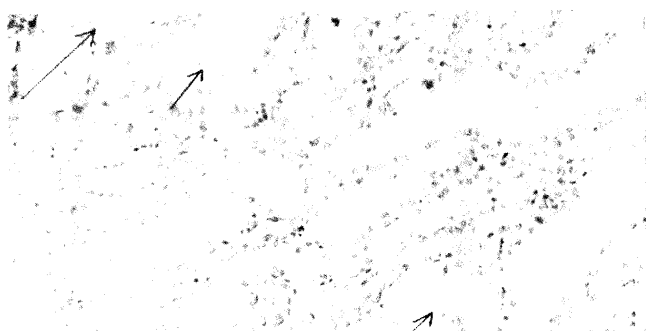


Fig (2) Section of Kidney in rat (from intermediate and low dose) Show scattered necrotic tubules (H&E 20 X)

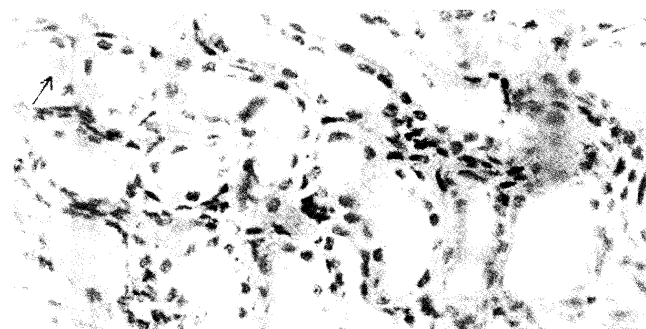


Fig (3) Section of Kidney in rat (from intermediate and low dose) Show varing degrees of tubular dilation (H&E 40 X).

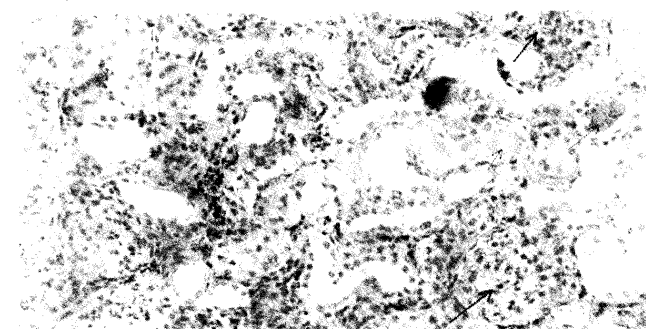


Fig (4) Section of Kidney in rat (from intermediate and low dose) Show tubular dilation with eosinophilic portentous cast and glomerular hypercellularity (H&E 20 X)

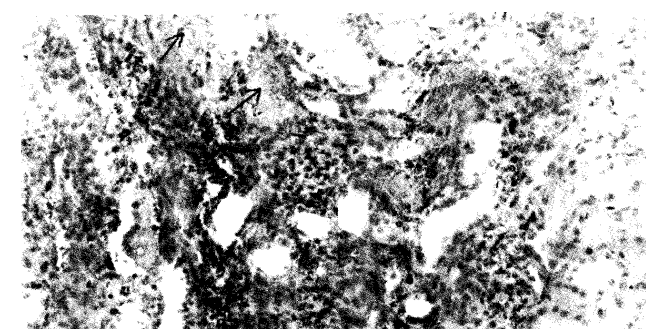


Fig (5) Section of Kidney in rat (from intermediate and low dose) Show cortical tubules basophilic (H & E 20X).

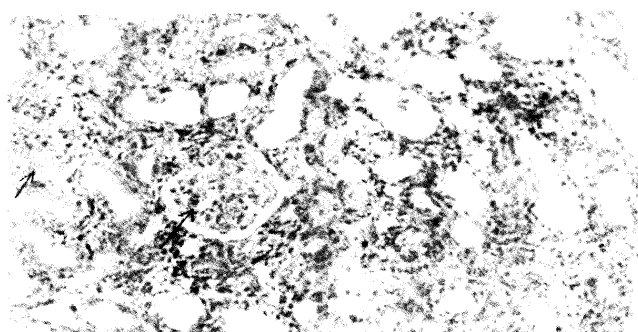


Fig (6) Section of Kidney in rat (from intermediate and low dose) Show glomerular hypercellularity with interstitial fibrosis (H & E 20X).

Discussion:

Since the Gulf War exposure to DU (1991), a known as nephrotoxic agent, there is renewed interest in the toxic effect of U in general and its mechanism of nephrotoxicity which is still unknown in particular. (11)

The present work of toxicity of U on rats showed that all male rats, which died during LD 50 and at termination, the cause of death was renal failure that probably results either from altered renal hemodynamic (17) or from disturbances in electrolyte transport (18). Histopathological investigation showed that the main site of potential damage from chemical toxicity of U was the kidney, the proximal tubules (Which is the main filtering component of kidney) (3) and the changes varied according to severity of these changes due to high toxic dose level, as in animals which died during 24 hours LD 50 showed massive necrotic areas of cortical tubules with or without intraluminal portentous casts, while those which received minimal or moderate dosage level and survived for several days died or killed showed some areas of regenerative cortical tubular basophilic, but more presence of dilated tubules, some intraluminal portentous cast, the degenerative changes in the proximal convoluted tubules especially in case of wide spared necrosis of the tubules was due to direct cytotoxic effect of uranyl acetate on the tubules there was no evidence of renal ischemia produced by uranyl acetate to play a role in the degeneration necrotic effects of the compound, these results agreed with that published before (10) would suggest a direct action of U on tubular cells (i.e. cytotoxic effect on renal tubules impaired function more than glomerular function. The result also showed glomerular hypercellularity with thickened Bowman's capsule, and this agreed with Taylor et al (19) as uranyl nitrate (24 or 600 mg/L) in drinking water for (91) days caused a dosage dependent increase in glomerular basement membrane thickness. Other investigation reported that the radioactive minerals, their target organs for toxicological pathology was the kidney, before urinary bladder or ureter. (20) The results of present work also agree with the results published before (21) as they reported that the U chemical toxicity over showed any associated radiation hazard as they stressed that after parenteral administration, U accumulates in the renal cortex

and is excreted via the kidney and that acute or in tense exposure may cause nephrotoxic lobular lesions which may present either with acute renal failure or as specific abnormalities of tubular function with impairment of renal concentrating ability and acid excretion with possibility of chronic renal exposure in man with prolonged high dosage in animals as led granular contracted kidneys with cortical narrowing. In conclusion the heavy metal such as U showed a toxicological pathology effect and considered as the main cause of death in sever morbid cases.

References:

1. Domingo, J.L. (2001). Reproductive and developmental toxicity of uranium. *Toxicol. Ectotoxicol. News.* 2(3): 74-78.
2. Priest, N.D. (2001). Toxicity of depleted uranium. *Lancet* 357: 244-246.
3. WHO / World Health Organization (2003). Depleted Uranium-media center. fact sheet. N257. January.
4. Murray V.S.G., Bailey, M.R. and Spratt, B. G.(2002). Depleted Uranium : anew battle field hazard. *Lancet* 360 (Suppl): 531- 532.
5. McClain, D.E., Benson, K.A. Dalton, T.K., Ejik, J., Emond, C.A. and Hodge, S.J. (2001). Biological effects of embedded depleted Uranium : Summary of the Armed Forces Radiology Research institute research. *Sci. Total. Environ.* 274: 115-118.
6. Thiebault, C. Carriere, M., Milgram, S., Simon, A. Avoscan, L. and Gouget, B. (2007). Uranium induces Apoptosis and is Genotoxic to Normal Rat kidney (NRK- 52E) Proximal cell. *Toxicol. Sci.* 98(2): 479-487.
7. Periya karuppan, A., Kumar, F., Sarkar, S., Sharma, C.S. and Ramesh, G.T. (2006). Uranium induces oxidative Stress in lung epithelial cell. *Arch. Toxicol.* 81(6): 389-395.
8. Yazzie, M., Gamble S.L., Civitello, E.R. and Stearns, D.M. (2003). Uranyl acetate causes DNA single strand breaks invitro in the presence of ascorbat (Vit c). *Chem. Res. Toxicol* 10, 524-530.
9. Kurtio, P., Auvinen, A., Salonen, L., Saha, H., Juha, P.M., Uusinen, S.B., Penttinen, I.M. and Komulainen, H. (2002). Renal effects of uranium in drinking water. *Environ. Health. Perspect.* 110(4): 337-342.
10. Hodge, H.C., Stannard, J. N. and Hursh, J.B. (1973). A history of uranium poisoning (1824-1942). H. C. Hodge in *Hand book of Experimental pharmacology*, New Series xxxvi, Uranium, Plutonium, Transplutonic Elements. Springer-Verlag, New York. PP. 569.
11. Lawrence, G.D. (2004). Uranium Toxicity Literature. Department of Chemistry and Biochemistry, Long Island University. Brooklyn NY 11201, USA.
12. Goldman, M., Yaari, A., Doshnitski, Z., Luria, R.C. and Moran, A. (2006). Nephrotoxicity of uranyl acetate: effect on rat kidney brush border membrane vesicles. *Arch. Toxicol.* 80(7): 387-393.
13. Berradi, H., Bertho, J.M., Dudoignon, N., Mazur, A., Grandcolas, L., Baudelin, C., Grison, S., Visin, P., Gourmelon, P. and Dublaineau, I. (2008). Renal anemia induced by chronic ingestion of Depleted Uranium in Rats. *Toxicol. Sci.* 103(2): 397-408.
14. Wan, B., Fleming, J.T., Schultz, T.W. and Sayler, G. S. (2006) Toxic genomics. *In Vitro Immune Toxicity of Depleted Uranium : Effects on Murine Macrophages CD+4 T cell and Gene Expression profiles.* *Environ. Health. Perspect.* 114(1).
15. Tolson, J.K., Roberts, S.M., B., Romeroy, M. and Barber, D.S. (2005). Heat shock proteins and acquired resistance to uranium nephrotoxicity. *Toxicol.* 206(1,5) 59-73.
16. Vacca, L., (1985). *Laboratory manual of histochemistry* 1st. ed. Ravens Press. New York PP: 139-328.
17. Avasthi, P.S., Evan, A.P., Itay, D. (1980). Glomerular endothelial cells in uranyl nitrate- induced acute renal failure in rats. *J. Clin. Invest.* 65: 121- 127.
18. Tyrakowski, T., Knapowski, J. and Baczyk, K. (1976). Disturbances in electrolyte transport before the onset of uranyl acetate - induced renal failure. *Kidney International.* 10, 514-515.
19. Taylor, M., Bhatnagar, M.K., Gilman, A., Syagminas, A. and Singh, A. (1992). Uranyl nitrate induced glomerular basement membrane alterations in Rabbits. *A quantitative analysis- Bull. Environ. Contamin. Toxicol.* 48, 367-373.
20. Ballantyne, B., Marris, T. and Turner, P. (1994). *General and Applied Toxicology -Vol. 2* PP. 1406. Mostackton press.
21. Paul, B., Beeson, W., Dermott, M. C. and James B. (1979). *Text book of medicine Renal disease* Wyn Gaa rden cecil 15th ed PP. 1928 W. B. Saunders Company - Philadelphia, London, Toronto.