

Pretreatment Clinical Variables Associated With the Response to Intravitreal Bevacisumab (Avastin) Injection In Patients With Persistent Diabetic Macular Edema

Fareed A. Warid AL-Laftah
Maha Elshafie
Dr. Mustafa Alhashimi
Aant Pai

MD, ARAB BOARD, FRCS-Ed
MD, FRCSI
MD,
MD, DNB, FRCS (Glasg)

Summary:

Background: The purpose of the study is to determine whether the pre-treatment clinical systemic variables and optical coherence tomographic (OCT) findings are associated with the subsequent response to the intravitreal Bevacisumab (IVB) in eyes with diabetic macular edema (DME).

Patients and Methods: 38 patients (45 eyes) with refractory diabetic macular edema. : 16 females, 22 males and mean age was 57.5 year. All patients had DME not responded to other treatments. Complete eye examination; BCVA* (represented as LOGMAR for adequate statistical analysis), slit-lamp exam, intraocular pressure measurement, stereoscopic biomicroscopy of the macula, and morphologic patterns of diabetic macular edema demonstrated by OCT. All patients had intravitreal injection of 0.05mL =1.25 mg Bevacizumab (Avastin; Genentech, Inc., San Francisco, CA), and followed up for 3 months. The pre and post-operative follow-up data were analyzed by Student-t test and Mann-Whitney test for two main outcome measures; visual acuity (LOGMAR) & central foveal thickness (CFT) changes over a period of three months, and data include demographic factors, type, duration and control of diabetes mellitus (HbA1C%), grade of diabetic retinopathy, renal function (serum creatinine level), serum cholesterol, blood pressure control and previous treatment by focal laser and/or intravitreal triamcinolone injection.

Results: The visual acuity and CRT improved in 30/45 eyes (67%) and 32/45 eyes (72%) respectively during a mean follow-up time of three months. The mean LogMAR visual acuities were 0.64 (SD \pm 0.34), 0.61 (SD \pm 0.31) and 0.60 (SD \pm 0.32) at pre-injection, at 1 month post-injection and at 3 months post-injection respectively; but this mean increase in vision was statistically not significant (P value = 0.099). The mean foveal thicknesses were 444.95 μ (SD \pm 127.36), 394.95 μ (SD \pm 138.03) and 378.32 μ (SD \pm 112.01) at pre-injection, 1 month post-injection and 3 months post-injection respectively, this decrease in the foveal thickness was statistically significant (P value < 0.001). The LogMAR and CFT values before and after IVB injection showed significant statistical correlations (p < 0.05) in relationship to variables of diabetic duration, diabetic control (HbA1c), and OCT pattern of macular edema, serum creatinine and cholesterol.

Conclusions: chronicity and inadequate control of diabetes mellitus, nephropathy, hyperlipidemia and presence of vitreomacular attachment (VMA) are factors associated with poor vision progress after intravitreal Bevacisumab injection.

Key words: CSME, Bevacisumab (Avastin), Systemic factors and OCT,
BCVA= BEST CORRECTED VISUAL ACUITY.

Fac Med Baghdad
2010; Vol. 52, No. 2
Received Dec., 2009
Accepted Feb., 2010

Introduction:

Macular edema is a major cause of central vision impairment in patients with diabetic retinopathy (1) Bevacizumab (Avastin; Genentech, Inc., San Francisco, CA) is a full-length recombinant humanized monoclonal antibody against the receptors of the vascular endothelial growth factor (VEGF) molecule in the endothelial cells. (2)

* Department of Cardiology, Baghdad Teaching Hospital.

Intravitreal bevacisumab (IVB) has increasingly been used as a treatment for intraocular proliferative, edematous, and neovascular diseases, such as central retinal vein occlusion, neovascular glaucoma, exudative age-related macular degeneration, proliferative diabetic retinopathy, and recently, IVB has been frequently applied to eyes with diabetic Macular edema leading to an increase in visual acuity in some cases (3,4,5). Refractory clinically

significant diabetic macular edema (CSME) that did not resolve with several sittings of focal laser photocoagulation (FLP) and intravitreal injections may result in an increased risk of vision loss. Systemic factors, such as poor glycemic, cholesterol, blood pressure and control, may be contributing to the persistence of the macular edema. Up to date there is no existing published study assessed the correlation between Bevacicsumab (Avastin) treatment response of refractory CSME and co-morbidity systemic factors. The purpose of our study is to determine whether the pre-treatment systemic and ocular variables are associated with the subsequent response to the IVB in eyes with DME.

Patients and Methods:

This is a prospective, consecutive, non-comparative case series of 38 patients (45 eyes) 16 females, 22 males, the mean age was 57.5 years.

Inclusion criteria include refractory diabetic macular edema which was not responded to previous treatments as focal laser and /or intravitreal triamcinolone injection, CFT on serial OCT showed reduction not more than 100µm, and also visual acuity increased by not more than one line on snellen chart from previous treatments, the ocular media in all patients were clear enough to document DME by OCT, and no macular ischemia by Fluorescein Angiography (FFA), however FFA was not done (contraindicated) in 3eyes/2patients and confirmed no significant ischemic changes in the macula of (43 eyes) 36 patients.

Exclusion criteria include treated DME within 3 months prior to IVB injection, previous vitrectomy and or gas injection and vitreous hemorrhage. Every patient had been well-informed about the quality of the treatment and acknowledged comprehensively about risk/benefit ratio of IVB injection and an informed consent was obtained from each patient.

The injection procedure for all patients was performed in the operating theatre so as to minimize the risk of intraocular infection. Sterilization accomplished by topical 5% povidone-iodine, 0.05mL=1.25 mg of IVB injected into mid-vitreous by 30 gauge needle, 3-4 mm posterior to inferotemporal limbus, postoperative topical antibiotics instilled for 5 days, and all patients followed up for 12 weeks.

At each visit (pre and post injection) patients underwent complete eye examination; BCVA (represented as LOGMAR for adequate statistical analysis), slit-lamp exam, intraocular pressure measurement, stereoscopic biomicroscopy of the macula, and morphologic patterns of (DME) demonstrated by (OCT) (6). OCT assessment for central foveal thickness (CFT) changes and vitreomacular attachment (VMA). The baseline pre and post-operative follow-up data were analyzed and compared for two main

outcome measures VA (LOGMAR) and CFT changes over the period of three months. Data studied and analyzed for variables for demographic factors, type and duration of DM, diabetic control (HbA1c %), grade of diabetic retinopathy, serum creatinine level, serum cholesterol, blood pressure, previous treatments (not < 6 months) either by focal laser and/or intravitreal triamcinolone injection.

Statistical analysis:

The correlations between the Pre and Post treatment variables were studied by using Student-t test and Mann-Whitney test, The level $p < 0.05$ was considered as the cut-off value for the significance.

Results:

Forty five eyes of 38 patients who completed 3 months of follow-up were included for analysis. 31 patients had injection in one eye and 7 patients had injection in both eyes at an interval of 1 to 2 weeks (mean: 1.4 weeks). The visual acuity changes presented in LOGMAR and the macular anatomical changes by OCT indicated by CFT= central foveal thickness, see tables 2 and 3. The visual acuity improved (? 2 lines in Snellen chart) in 30/45 eyes (67%) and CRT reduced by (? 100 µm) in 32/45 eyes (72%) over three months period of follow up. All eyes had DME which was refractory to treatment with conventional macular laser photocoagulation and or intravitreal triamcinolone injection which was carried out ? 6 months prior to the IVB injection, 23 eyes had non-proliferative stage of diabetic retinopathy and 22 eyes had proliferative stage of diabetic retinopathy. One case was of diabetes type I (1 eye) and other 37 (44 eyes) were type II, all eyes with proliferative diabetic retinopathy were stabilized by the prior panretinal photocoagulation performed at least ? 6 months earlier, the post-injection outcome (Visual Acuity and CFT) was different in relationship with each studied variable and showed diverse statistical correlation (tables 2 and 3). Five out of nine studied variables proved to be statistically correlated with post-injection VA ($p < 0.05$), include ; duration of diabetes, Diabetic control (HbA1C %), pattern of macular edema, serum level of creatinine and cholesterol, and two variables showed significant correlation with CFT ($p < 0.05$) include ; serum cholesterol and creatinine as shown in (table 4).

Table 1.

Demographic characteristics
Gender : (M/F) 22/16
Age : 57.5 SD 14
Diabetes onset age : 48 SD ± 10 years
Diabetes evolution time : 16 SD ± 9 years

17




Fig.1 VA (clinical changes) over 3 months

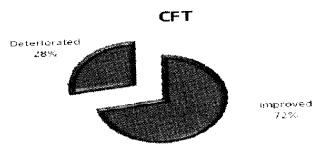


Fig.2 OCT (clinical changes) over 3 months

Table 2: Central Foveal Thickness (CFT) correlation with variables

Variable		CFT		Total	P value
		Improved	Not improved		
HbA1c	≤ 7%	5 (15%)	5 (42%)	10 (22%)	0.1
	> 7%	28 (85%)	7 (58%)	35 (78%)	
Duration of DM	< 10 years	20 (60.6%)	7 (58%)	30 (67%)	0.2
	≥ 10 years	13 (39.4%)	5 (42%)	15 (33%)	
DM Grade	NPDR	16 (49%)	7 (58%)	23 (51%)	0.5
	PDR	17 (51%)	5 (42%)	22 (59%)	
Hypertension	No HTN / Controlled to Age	12 (36%)	58 (67%)	20 (45%)	0.07
	Uncontrolled to Age	21 (64%)	4 (33%)	25 (55%)	
Cholesterol	≤ 5.17 mmol	26 (79%)	6 (50%)	32 (71%)	0.045
	> 5.17 mmol	7 (21%)	6 (50%)	13 (29%)	
Serum creatinine	< 62 mmol	11 (33.3)	4 (33.3)	15 (33.3)	0.04
	62-124 mmol	20 (60.6)	7 (58.3)	27 (60.0)	
	> 124 mmol	2 (6.1)	1 (8.3)	3 (6.7)	
OCT Pattern	Diffuse	10 (30.3%)	5 (42%)	15 (33%)	0.47
	Diffuse + CME	15 (45.5%)	6 (50%)	21 (47%)	
	Diffuse CME + VMA	8 (24.2)	1 (8%)	9 (20%)	
Focal Laser	No	2 (6%)	0	2 (4%)	0.1
	One	25 (76%)	8 (67%)	33 (73%)	
	≥ Two	6 (18%)	4 (33%)	10 (23%)	
IVTA	NO	23 (70%)	7 (58%)	30 (67%)	0.496
	YES	10 (30%)	5 (42%)	15 (33%)	

*IVTA=intravitrealtriamcinolone

Table 3 (VA) LOGMAR correlation with variables

Factor		LOGMAR		Total	P value
		Improved	Not improved		
HbA1c	≤ 7%	7 (47%)	3 (10%)	10 (22%)	0.009
	> 7%	8 (53%)	27 (90%)	35 (78%)	
Duration of DM	< 10 years	6 (60%)	22 (73 %)	28 (65%)	0.01
	≥ 10 years	5 (40%)	12 (27%)	17 (35%)	
DM Grade	NPDR	10 (67%)	13 (43%)	23 (51%)	0.14
	PDR	5 (33%)	17 (57%)	22 (49%)	
Hypertension	No HTN or Controlled to Age	7 (47%)	13 (43%)	20 (44.5%)	0.30
	Uncontrolled to Age	8 (53%)	17 (57%)	25 (55.5%)	
Cholesterol	≤ 5.17 mmol	12 (80%)	20 (67%)	32 (71%)	0.04
	> 5.17 mmol	3 (20%)	10 (33%)	13 (29%)	
Serum creatinine	< 62 mmol	9 (60%)	6 (20%)	15 (33.3%)	0.04
	62-124 mmol	6 (40%)	21 (70%)	27 (60 %)	
	> 124 mmol	0	3 (10%)	3 (6.66%)	
OCT Pattern	Diffuse	8 (53%)	7 (23.3%)	15 (33.3%)	0.02
	Diffuse + CME	7 (47%)	14 (46.7%)	21 (46.7%)	
	Diffuse + CME + VMA	0	9 (30%)	9 (20%)	
Focal Laser	No	0	2 (7%)	2 (4.5%)	0.2
	One	13 (87%)	20 (67%)	33 (73.3%)	
	≥ Two	2 (13 %)	8 (26%)	10 (22.2%)	
IVTA	NO	8 (53.3%)	22 (73.3%)	30 (66.7%)	0.496
	YES	7 (45.7%)	8 (26.7%)	15 (33.3%)	

*IVTA=intravitrealtriamcinolone

Table 4: clinical variables correlated with statistical changes in (LOGMAR and CFT).

VARIABLE	LOGMAR	CFT
Chronicity of DM	+ve	-ve
DM control (Hb A1C)	+ve	-ve
OCT Type of DME	+ve	-ve
S.Creatinine	+ve	+ve
S.Cholesterol	+ve	+ve

Discussion:

Diabetes mellitus is a chronic disease affecting the metabolism of the carbohydrates which damage microvasculature in kidneys, blood vessels, peripheral nerves and eyes, causing complicated disorders which subsequently produce more complications such as retinopathy and triggering the break of the blood-retina barrier and increase permeability in diabetic retinopathy (7). Control of diabetes can be checked by several methods, and the most practical sensitive way is HbA1c %, and reduction in progression and severity of retinopathy seen when HbA1c is reduced to 7% (8). we used in our study HbA1c 7 % as an indicator for control of diabetes. 2/3rd of our patients were poorly controlled diabetics HbA1c \geq 7% and exhibit poor post-injection VA ($P=0.009$), never the less CFT unchanged significantly ($P=0.01$) and it is contrary to other studies where they confirmed that patients with HbA1c of ≥ 8 had decrease in foveal thickness (9). Several studies have proven that elevated serum lipid levels may be an additional risk factor for CSME (10, 11, 12, 13), and this agrees with our study in which we found that hypercholesteremic patients > 5.17 mmol are having less chance for improvement of both VA and CFT after IVB (P value = 0.04, 0.045 respectively). High systolic blood pressure increases prevalence and severity of retinopathy in diabetes (15, 16) It also had been proven that antihypertensive medication (Furosemide) may be beneficial in treating macular edema in hypertensive diabetic patients (17). In accordance with previous studies, our study confirms that those who having high uncontrolled blood pressure ($> 50\%$ patients) will have progressed macular edema after IVB (P value = 0.07). Our findings were in agreement with the well established statement that the severity of retinopathy and maculopathy are strongly associated with the duration of diabetes. (1, 18) and in our study the shorter diabetes duration (< 10 years) the better the macular responses to IVB (P value = 0.02). In our patients, poor responders to IVB were having renal dysfunction (creatinine > 124 mmol) and It is reported that diabetic macular edema is significantly resolved after hemodialysis (19). The vast majority of authors use OCT as the best indicator of therapeutic benefit. The amount of information given by OCT demonstrates that macular edema is a complex clinical entity with various morphology (20), and DME exhibits five different morphologic patterns on OCT (21,22); diffuse retinal thickening, cystoid macular edema, vitreomacular attachment (VMA), serous retinal detachment, and traction retinal detachment. Three patterns only have been shown in our patients; diffuse pattern with or without cystoids changes and VMA. We noticed a relatively good improvement in post-injection VA particularly for those with diffuse pattern without cystoids or VMA component (P value = 0.02), but no comparable achievement has been

noticed in the post-injection CFT (P value = 0.47). According to the history of FLP, we classify the patients into 3 groups; no FLP, one FLP and two FLP, however the majority of our patients had one FLP and 25/33 (76%) of this group showed flattening of macula by OCT (positive anatomical response), and 20/33 (61%) showed reduction in vision (negative functional response) post-injection, and this result is supported by finding of Vivienne C. Greenstein et al who suggest that focal treatment produces changes in retinal function, and these changes are not restricted to the treated macular area. (23). The IVB injection outcome was not significantly different whether the patient in the non-proliferative stage or regressed proliferative stage (all patients had completed PRP). In our patients 15 (33%) had history of IVTA 6 months earlier to IVB and 30 (67%) did not, there was no significant difference between the two groups. The beneficial effects of IVTA are transient may last up to 6 months (24, 25). The limitations of our study are short term follow up, uncontrolled study and a single reading for systemic variables is not a sufficient indicator for systemic control (i.e. need serial measurements).

Conclusion:

More chronicity and poorly controlled diabetes mellitus, nephropathy, hyperlipidemia and presence of VMA or macular cysts are associated with a poor response of DME after IVB injection.

References:

1. Early Treatment Diabetic Retinopathy Study Research Group. Photocoagulation for diabetic macular edema. Early treatment Diabetic Retinopathy Study Report number 1. *Arch Ophthalmol* 1985; 103:1796-806.
2. Ates Yanyali, Banu Aytug et al. Bevacizumab (Avastin) for Diabetic Macular Edema in Previously Vitrectomized Eyes. *AM J Ophthalmol*. VOL. 144, NO. 1, pp.124-125, July, 2007.
3. Rosenfeld PJ, Moshfeghi AA, Puliafito CA. Optical Coherence Tomography findings after an intravitreal injection of bevacizumab for neovascular age-related macular degeneration. *Ophthalmic Surg Lasers Imaging* 2005; 36:331-335.
4. Rosenfeld PJ, Moshfeghi AA, Puliafito CA. Optical Coherence Tomography findings after an intravitreal injection of bevacizumab for macular edema from central retinal vein occlusion. *Ophthalmic Surg Lasers Imaging* 2005; 36:336-339.
5. Iuvralde D, Spaide RF, Myerle CB, et al. Intravitreal bevacizumab (Avastin) treatment of macular edema in central retinal vein occlusion: a short-term study. *Retina* 2006; 26:279-284.
6. Kim BY, Smith SD, Kaiser PK et al. Optical coherence tomographic patterns of diabetic macular edema. *Am J*

Pretreatment Clinical Variables Associated With The Response To Intravitreal Bevacisumab (Avastin) Injection In Patients With Persistent Diabetic Macular Edema

Ophthalmol. 2006 Sep; 142(3):405-12.

7. Wang PH, Lau J, Chalmers TC (1993) Meta-analysis of effects of intensive blood glucose control on late complications of type I diabetes. *Lancet* 341: 1306-1309.
8. The Diabetes Control and Complications Trial Research Group: The effect of intensive treatment of diabetes on the development and progression of long-term complications in insulin-dependent diabetes mellitus. *N Engl J Med* 329: 977-986.1993.
9. C.-H. Lai, T.-H. Chou, P.-C. Wu and C.-N. Kuo .Relationship of Diabetic Macular Edema with Glycosylated Hemoglobin (HbA1c). *Invest Ophthalmol Vis Sci* 2008; 49: E-Abstract 2730.2730-A511.
10. Chew EY, Klein ML, Ferris FL 3rd, Remaley NA, Murphy RP, Chantry K, Hoogwerf BJ, Miller D: Association of elevated serum lipid levels with retinal hard exudate in diabetic retinopathy: Early Treatment Diabetic Retinopathy Study (ETDRS) report 22. *Arch Ophthalmol* 114 :1079 - 1084,1996.
11. Ferris FL 3rd, Chew EY, Hoogwerf BJ: Serum lipids and diabetic retinopathy: Early Treatment Diabetic Retinopathy Study Research Group. *Diabetes Care* 19 :1291 -1293,1996
12. Roy MS, Klein R: Macular edema and retinal hard exudates in African Americans with type I diabetes: the New Jersey 725. *Arch Ophthalmol* 119 :251 -259,2001.
13. Klein BE, Moss SE, Klein R, Surawicz TS: The Wisconsin Epidemiologic Study of Diabetic Retinopathy. XIII. Relationship of serum cholesterol to retinopathy and hard exudate. *Ophthalmology* 98 :1261 -1265,1991
14. David A. Calhoun, MD, FAHA et al. Resistant Hypertension: Diagnosis, Evaluation, and Treatment Circulation. 2008; 117:510-526.
15. Cignarelli M, De Cicco ML, Damato A, et al. NIDDM patients. *Diabetes Care* 1992; 15:1002-1008.
16. Stratton IM, Kohner EM, Aldington SJ, Turner RC, et al. UKPDS 50: Risk factors for incidence and progression of retinopathy in type II over 6. *Diabetologia* 2001; 44:156-163.
17. A. P. Ciardella, G. K. Athappilly, A. Shah, N. Faberowski and L. Ryman. Diabetic Macular Edema Responsive to Systemic Furosemide (Lasix) Therapy: An OCT Study .*Invest Ophthalmol Vis Sci* 2007;48: E-Abstract 5006.5006-B154.
18. Liu DP, Molyneaux L, Chua E, Wang YZ, Wu CR, Jing H, et al. Retinopathy in a Chinese population with type 2 diabetes: factors affecting the presence of this complication at diagnosis of diabetes. *Diabetes Res Clin Pract* 2002; 56:125-131.
19. L. Akduman, P. Chiranandl and C. Smith. Diabetic Macular Edema Decrease by OCT after Dialysis. *Invest Ophthalmol Vis Sci* 2008; 49: E-Abstract 3463.3463-A552.
20. Ate Yanyali, Banu Aytuig et al, Bevacisumab (Avastin) for Diabetic Macular Edema in Previously Vitrectomized Eyes.

Am J Ophthalmol, July/2007, Vol.144, No.1, 124-26.

21. Panozzo G, Parolini B, Gusson E, Mercanti et al. Diabetic macular edema: an OCT-based classification *Semin Ophthalmol*. 2004 Mar-Jun; 19(1-2):13-20.
22. Kim BY, Smith SD, Kaiser PK. Optical coherence tomographic patterns of diabetic macular edema. *Am J Ophthalmol*. 2006 Sep; 142(3):405-12.
23. Vivienne C. Greenstein, Haifan Chen, Donald C. Hood, Karen Holopigian et al. Retinal Function in Diabetic Macular Edema after Focal Laser Photocoagulation .*Investigative Ophthalmology and Visual Science*. 2000; 41:3655-3664.
24. Beer PM, Bakri SJ, Singh RJ, et al. Intraocular concentration and pharmacokinetics of triamcinolone acetonide after a single intravitreal injection. *Ophthalmology* 2003; 110:681-6.
25. Jonas JB, Degenring RF, Kamppe BA, et al. Duration of the effect of intravitreal triamcinolone acetonide as treatment for diffuse diabetic macular edema. *Am J Ophthalmol* 2004; 138:158-60.