

Metric study on depth of the sigmoid sinus plate in relation to suprameatal (Macewen's) triangle

Mohammad O. Selman *MBChB, FIBMS*

Dept. Human Anatomy College of medicine, Al-Nahrain University

Abstract

Background	The lateral wall of the mastoid antrum, which offers the usual surgical approach to the tympanic cavity, is formed by the postmeatal process of the squamous part of the temporal bone. Since the suprameatal triangle covers the lateral wall of the mastoid air system, it is of importance to otologic surgeons during mastoidectomy.
Objectives	To examine the relationships of the surgical landmarks on the lateral surface of the mastoid bone with the landmarks in a deeper location. Morphometric measurements were performed between the surgical landmarks (Macewen's triangle) and the sigmoid sinus plate.
Methods	30 dry human adult skulls were investigated. Three marks were allocated on the left and right sides of the norma lateralis of these skulls namely the tip of the mastoid process, the asterion, and the region of the suprameatal triangle (posterior border).
Results	The measurements of (D1+D2), (D1+D3) and (D2+D3) showed statistical significant differences. The correlations of D1, D2 and D3 on the right and left sides showed statistical significant differences
Conclusion	The assessment of the depth of sigmoid sinus plate may be used as a mark that possibly point toward avoidance of the bleeding possibility during mastoidectomy. The suprameatal approach eliminates the need for mastoidectomy and avoids the damage of sigmoid sinus plate. If the depth can be assessed by measuring D1 and D2 on lateral X-rays of the heads as this study prove that we can avoid the dangerous complications which occur in the normal mastoidectomy.
Keywords	Suprameatal triangle, mastoidectomy

Introduction

Mastoiditis results from a middle ear infection that causes inflammation of the mastoid air cell. This dangerous condition may spread from the antrum to surrounding structures and cause life-threatening infection. In particular the infection may spread through the tegmen tympani to the dura mater of the middle cranial fossa, to cause an extradural collection ⁽¹⁾.

The lateral wall of the mastoid antrum, which offers the usual surgical approach to the tympanic cavity, is formed by the postmeatal process of the squamous part

of the temporal bone. The mastoid antrum is located 15 mm deep to the lateral surface of the mastoid bone.

In adults, the lateral wall of the antrum corresponds to the suprameatal triangle on the outer surface of the skull ⁽²⁾.

The superior side of the suprameatal triangle, the supramastoid crest, is level with the floor of the middle cranial fossa. The anteroinferior side, which forms the posterosuperior margin of the external acoustic meatus, indicates approximately the position of the descending part of the facial nerve canal ⁽³⁾. The suprameatal approach eliminates the need for

mastoidectomy and posterior tympanotomy⁽⁴⁾. The area is entered through a retroauricular tympanotomy flap, and the electrode is introduced via a tunnel drilled in the suprameatal region superior to Henle's spine. The suprameatal approach is a simple and safe technique that does not endanger the facial nerve or the chorda tympani⁽⁵⁾.

Since the suprameatal triangle covers the lateral wall of the mastoid air system, the suprameatal triangle is of importance to otologic surgeons during mastoidectomy⁽⁶⁾. The anatomical landmarks especially suprameatal crests on the outer surface of the squamous part of the temporal bone are of clinical importance as they are accepted as landmarks for some surgical approaches⁽⁷⁾.

In vivo, identification of suprameatal triangle is by doing postural incision 0.5cm behind the retroauricular sulcus which is the exact site for operation on living patients in mastoidectomy. By removing the mastoid cortex with electric drill, the exact depth of the sinus plate is clarified. Drilling from suprameatal triangle was done in line of superior border of suprameatal

triangle⁽⁸⁾. The surface marking of the mastoid antrum is the suprameatal triangle (Macewen's triangle) Figure 1⁽⁸⁾.

The boundaries of the triangle are:

Anteriorly: The post-superior border of the bony external auditory canal along with the suprameatal spine of Henle. This spine is prominent landmark for the suprameatal triangle.

a) Superiorly: The supramastoid crest.

b) Posteriorly: a vertical line drawn tangential to the posterior margin of the external canal.

In adult this triangle lies 1.5 cm lateral to the mastoid antrum which the largest air cell in the mastoid bone⁽⁹⁾.

Aim of this study

To measure the depth of the sinus plate that is an indicator for the distance between the site of the mastoidectomy and sigmoid sinus. The assessment of this plate may be used as a mark that possibly point toward avoidance of the bleeding possibility during the surgical mastoidectomy. This study was designed to assess the profitability of using simple parameters that could be obtained from the plan x-ray of the skull.

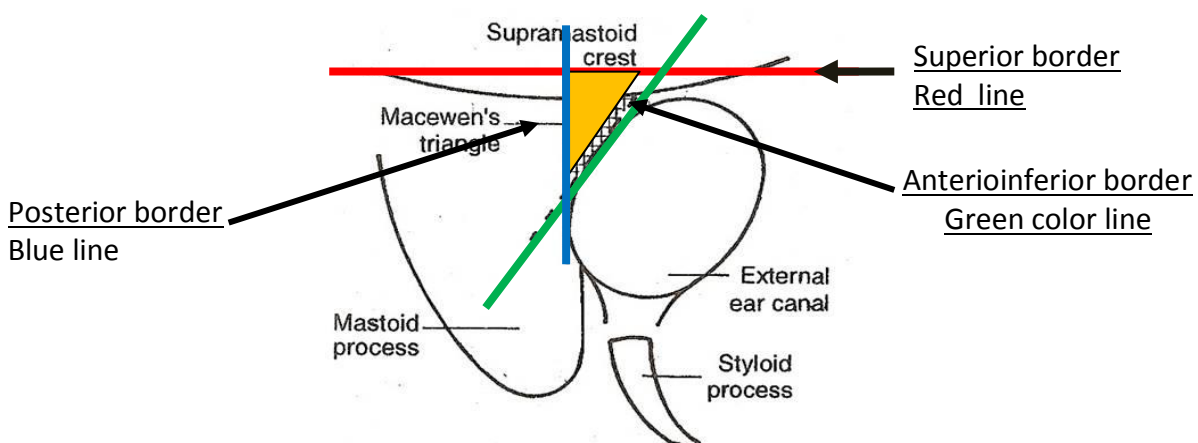


Figure 1: Diagrammatic illustration of suprameatal triangle (Macewen's) triangle⁽³⁾.

Methods

Thirty dry adult human skulls were investigated. All the skulls were obtained from collection of the museum of anatomy in the College of Medicine Al-Nahrian University. Three marks were allocated on the left and right sides of the norma lateralis of these skulls namely the tip of the mastoid process, the asterion, and the region of the suprameatal triangle (posterior border). Three imaginary lines were considered in this study representing the connections of these three pointed landmarks. The lines were designated as following (figure 2):

D1= the distance between 'asterion' and the tip of mastoid process in the direction of posterior border of mastoid process.

D2 = the distance between asterion and the suprameatal triangle (posterior border).

D3 = Mediolateral mass of the mastoid. "The depth of the sigmoid sinus".

To measure the distance between surface of suprameatal triangle and the sigmoid sinus plate, the skull was oriented in the Frankfurt plane and the drilling was done between surface of suprameatal triangle and the sigmoid sinus plate in line of direction of maxillary process of temporal bone (its upper) border. Line D1 was considered as the representative for evaluation of the anteroposterior growth for the mastoid process.

Line D2 was considered as the representative for evaluation for the region of the suprameatal triangle.

Line D3 was considered as the representative for the evaluation of the

depth of the sigmoid sinus plate from the surface of suprameatal triangle.

Measurements of D1 & D2 were done manually using Helios milimetric vernier (Inox). The anatomical landmarks were first defined and located, and then relevant measurements were done. D3 was estimated by measuring the length of a broom's bristle after passing it through the canal drilled into the suprameatal triangle.

The drilling was performed by using an electrical drill machine (Mizuho ika, kogyo co. Model No. m65-2c No. 79099 with drill size 2.8 mm).

Each of the artificial foramens which formed in the dry skulls was closed using the white cement powder to keep the normal skull morphology for teaching purposes.

The length of the three lines is demonstrated in 60 regions (right & left sides) of 30 human skulls. Statistical analysis was done using the statistical software package SPSS 16. The analysis was performed by using the chi square test for interpretation the results obtained.

The association between two categorical variables was assessed for statistical significance by chi-square test. P-values less than 0.05 were considered as statistically significant. The linear correlation between variables was measured by spearman's rank correlation coefficient. P values less than the 0.05 level of significance was considered statistically significant⁽¹⁰⁾.

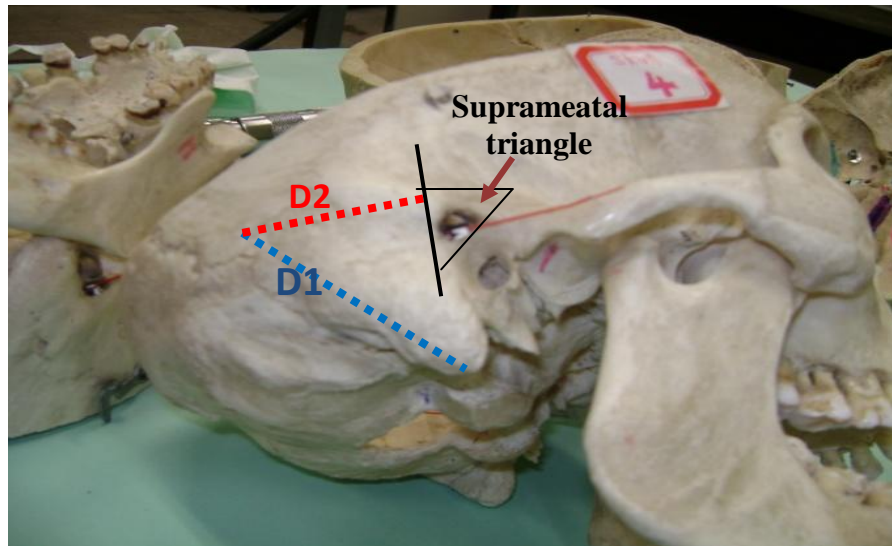


Figure2: Lateral view of a dry skull showing D1, D2 and the suprameatal triangle.
D1: from asterion to the tip of mastoid tubercle, D2: transverse line perpendicular on posterior border of the suprameatal triangle.

Results

The values of D1, D2 and D3 was calculated in centimeters. The average of D1 (4.635 ± 0.38), D2 (4.018 ± 0.25) and D3 (1.189 ± 0.16) of all skulls on both sides. The average of D1, D2 & D3 on right sides only are 4.610 (0.45), 4.050 (0.29) & 1.182 (0.17) respectively. The average of D1, D2 and D3 on left sides are 4.660 (0.32), 3.985 (0.20) and 1.196 (0.16) respectively as shown in table 1.

The measurements of (D1+D2), (D1+D3) and (D2+D3) on right side showed statistical significant differences. The probability ($p < 0.05$) of high significant ($p = 0.00001$) as shown in table 2.

The correlations of D1, D2 and D3 on the right and left sides showed statistical significant differences. The probability (p

< 0.05) of high significant for D1 ($P = 0.007$), and significant for D2 ($P = 0.029$) and significant for D3 ($P = 0.012$) as shown in table 3.

Data were analyzed using SPSS16 (statistical Package of Social Science, version 16 computer software). According to these results we can find the value of D1, D2 and D3 from following equations:

$$D3 = -0.548 + 0.375 D1$$

$$D3 = -0.856 + 0.509 D2$$

$$D2 = 1.534 + 0.536 D1$$

From these equations if we find D1 or D2 radiologically, can calculate the approximate depth of sigmoid plate (D3) value.

Table 1: The variants of D1, D2 and D3 of adult skulls (Total no. 30)
[average / (SD) on right and left sides]

	Adult skulls (Total no.=30)		
	Right side Average(SD)	Left side Average(SD)	All skulls Average(SD)
D1	4.610 (0.45)	4.660 (0.32)	4.635 (0.38)
D2	4.050 (0.29)	3.985 (0.20)	4.018(0.25)
D3	1.182 (0.17)	1.196(0.16)	1.189(0.16)

Table 2: Statistical Correlations and the probability (p values) of D1, D2 and D3 on the right side and its significance

	Correlation	p-value	significance
D1+D2(R)	0.824636598	P=0.00001	High-sign
D1+D3(R)	0.911606408	P=0.00001	High-sign
D2+D3 (R)	0.804874981	P=0.00001	High-sign

Table 3: Statistical Correlations and the probability (p values) of D1, D2 and D3 on the right and left sides and its significance

	Correlation	p-value	significance
D1 (R&L)	0.786915	P=0.007	High-sign.
D2 (R&L)	0.683902	P=0.029	Significant
D3 (R&L)	0.753688	P=0.012	Significant

Discussion

The measurements of (D1+D2), (D1+D3) and (D2+D3) showed statistical significant differences. By finding D1 or D2 radiologically, we can calculate the approximate depth of sigmoid plate (D3) value.

The complication of perforating the sigmoid venous sinus during surgical mastoidectomy may possibly be avoided by a preoperative assessment for the depth of the sinus plate.

It is very important to know the exact site of sigmoid sinus (depth of the sinus plate). If we irrigate or perform modified or radical mastoidectomy this may accidentally damage the bone of the sinus plate leading to severe venous bleeding. If the depth (D3) can be assessed by measuring D1 and D2 on lateral X-rays of the heads, we may avoid this dangerous complication.

This study was designed to assess the profitability of using simple parameters that could be obtained from the plain x-ray of the skull as an indicator for the depth of the sinus plate. The statistical analysis demonstrates correlation between the depth of the sinus plate (D3) and the two other parameters namely D1 and D2 (pearson correlation). It was shown that the depth of the sinus plate could be

speculated from the measurement of D1 and D2.

This is achieved by radiological assessment of Macewen's triangle as a surgical landmark ⁽⁹⁾. Many morphometric measurements were performed between surgical landmarks especially in the mastoidectomy ⁽⁷⁾.

The suprameatal approach is a simple and safe technique that does not endanger the facial nerve nor the chorda tympani ⁽⁵⁾.

If the depth can be assessed by measuring D1 and D2 on lateral X-rays of the heads as this study prove that we can avoid the dangerous complications which occur in the normal mastoidectomy.

Another point: the reason of using D1 and D2 to estimate D3, in other words, we built our hypothesis that measuring the first two lines might be an indicator to the third line, because many studies were done to clarify the topographic anatomy and clinical significance of the suprameatal triangle but no one mention the use of these criteria to know the depth of sigmoid sinus plate ^(2, 7, 11).

References

1. Williams PL and Warwick R. Gray's Anatomy. The Anatomical Basis of Clinical Practice. 36th ed. Churchill Livingstone. Edinburgh, 2008; pp. 483-572

2. Aslan A, Mutlu C, Celik O, Govsa F, Ozgur T, Egrilmez M. Surgical implications of anatomical landmarks on the lateral surface of the mastoid bone. *Surg Radiol Anat*, 2004Aug; 26(4): 263-7.
3. McMinn RMH. *Last's anatomy: Regional and applied*. 9th ed. Churchill Livingstone. Edinburgh. 1998; pp.530
4. Baily CM. Surgical anatomy of the skull base. In: *Scott Brown's Otolaryngology*. 6th ed. Vol. 1. Kerr GA. Butterworth Heinemann, London.1997; pp. 1-15.
5. Kronenberg J, Baumgartner W, Migirov L, Dagan T, Hildesheimer M. The suprameatal approach: an alternative surgical approach to cochlear implantation. *Otol Neurotol*, 2004 Jan; 25(1): 41-4.
6. Peker TV, Pelin C, Turgut HB, Anil A, Sevim A. Various types of suprameatal spines and depressions in the human temporal bone. *Eur Arch Otorhinolaryngol*, 1998; 255(8): 391-5.
7. Turgut HB, Anil A, Peker T, Pelin C, Gulekon IN. Supra-articular, supramastoid and suprameatal crests on the outer surface of the temporal bone and the relation between them. *Surg Radiol Anat*, 2003 Nov-Dec; 25(5-6): 400-7.
8. Bhargava KB, Bhargava SK, and Shah TM. *A short textbook of ENT diseases for students and practitioners*. 7th ed, 2005; pp. 78.
9. Milton CM, Cousins VC. A radiological assessment of the usefulness of Macewen's triangle as a surgical landmark. *J Laryngol Otol*, 1986 Nov; 100(11): 1225-34.
10. Daniel WW; Hypothesis testing. In: *Daniel WW. Biostatistics: A Foundation for Analysis in the Health Sciences*, 8th ed., John Wiley & Sons, Inc. 2005; p. 222.
11. Luiz AS de Pavia; Marco Segre. Sexing the human skull through the mastoid process. *Rev Hosp Clin Fac Med São Paulo*, 2003; Jan-Feb 58(1):15-20.

Correspondence to: Dr. Mohammad O. Selman,
E- mail: mohammadoda@yahoo.com

Received: 25th July 2010, Accepted: 9th Dec. 2010.