

The Use of Three Different Suturing Techniques for Wound Closure of Mucoperiosteal Flaps After Surgical Removal of Impacted Lower Wisdom Teeth (Comparative Study)

Ziad H Delemi

(BDS, FIBMS MF) (Lec)

Department of Oral and Maxillofacial Surgery

College of Dentistry, University of Mosul

الخلاصة

الأهداف: تهدف الدراسة الى تحديد تأثير تغيير طريقة خياطة الأنسجة الفموية بعد قلع أضراس العقل المطمورة السفلية ، و تحديد الطريقة المثلى في الخياطة بأقل ما يمكن من المضاعفات عقب العمليات. **المواد وطرائق العمل:** تشمل العينة ستون مريضاً تم اختيارهم عشوائياً من دون مشاكل صحية و تتراوح أعمارهم بين ١٦ – ٤٢ سنة و من كلا الجنسين. يتم تقسيمهم إلى ثلاث مجاميع بواقع ٢٠ مريضاً لكل مجموعة، جميعهم يحتاجون إلى قلع ضرس العقل السفلي المطمور جراحياً، يتم استخدام طريقة الخياطة المنفصلة البسيطة في المجموعة الأولى، و طريقة خياطة الفراش العمودية في المجموعة الثانية، و طريقة المرساة في المجموعة الثالثة. يتم مقارنة الجروح بالملاحظة البصرية والتقييم السريري و تحديد المضاعفات الناتجة بعد العملية من ناحية الألم و الورم. **النتائج:** في كل المجاميع وصل الألم على مقياس الرؤية البصرية اعلى قيمة له في اليوم الاول و استمر بالتلاشي الى اليوم السابع و كذلك وصلت الودمة الى اعلى قيمة لها في اليوم الاول و تدريجياً انخفضت وصولاً الى اليوم السابع و قد اظهرت طريقة خياطة المرساة اعلى قيمة للودمة في اليوم الثالث. **الاستنتاجات:** تغيير طريقة الخياطة بعد عمليات قلع ضرس العقل جراحياً لا تؤثر بشكل مباشر على الألم و الودمة.

ABSTRACT

Aims: The aim of the study is to determine the effects of different suturing techniques on post-operative complications (pain and swelling) following the removal of impacted lower wisdom teeth. **Materials and Methods:** Sixty medically fit patients were randomly selected with an age range between 16–42 years of both sexes. They were divided into 3 groups. These patients had impacted lower third molars indicated for surgical extraction. The first group comprised of twenty patients, the flap would be closed by simple interrupted suturing technique, and in the second group (20 patients) by vertical mattress suturing technique, and anchoring suture techniques for the third group (20 patients). All groups will be compared by clinical assessment to determine post-operative complications including pain and swelling. **Results:** In all treatment groups, pain (on VAS) reached its peak on the first post-operative day then faded away. In all groups, swelling was most severe in the first post-operative day and gradually decreased, with the anchor suturing technique showing significant difference of swelling at day three **Conclusions:** Changing the method of suturing appear to have no effect on the degree of pain, swelling following surgical removal of impacted mandibular third molars.

Key words: suturing techniques, third molar.

Delemi ZH. The Use of Three Different Suturing Techniques for Wound Closure of Mucoperiosteal Flaps After Surgical Removal of Impacted Lower Wisdom Teeth (Comparative Study). *Al-Rafidain Dent J*. 2017(1):98-107.

Received: 27/2/2014

Sent to Referees: 15/3/2014

Accepted for Publication: 7/5/2014

INTRODUCTION

The surgical removal of impacted third molars is a common procedure associated with a diversity of technique and anecdotal

opinion. Most surgeons agree that surgical time, surgical trauma, and difficulty of impaction are important factors in postoperative complications.⁽¹⁻⁵⁾ An

impacted tooth is one that fails to erupt into the dental arch within the expected time. ⁽⁶⁾

The surgical removal of third molar teeth may result in a number of complications including pain, swelling, bleeding, alveolar osteitis (dry socket) or nerve dysfunction. ⁽⁷⁾

The factors that usually contribute to such problems are numerous and include the patient factors, tooth-related factors and the surgeon's operative experience and skills. ⁽⁸⁾

Different incisions and flap techniques have been proposed in these third molar surgeries

to offer a better surgical field, to prevent periodontal problems, and to minimize postoperative discomfort for the patient. ^(9,10)

. It is known that primary closure of the flap avoids suture dehiscence and improves wound healing. The simple loop suture (interrupted interdental button or single button) is a very widely used suturing technique usually preferred by surgeons evaluating the effect of third molar removal on the periodontal health of the adjacent second molar as shown in Figure (1). ⁽¹¹⁾

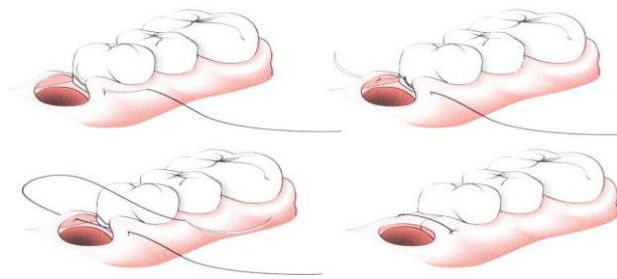


Figure.(1):- Simple loop suturing technique ⁽¹⁶⁾

The interrupted vertical mattress suture techniques are most commonly used skin closure methods. This technique provide many advantages, including the

closure of wounds under tension when wound edges must be brought together over a distance. Mattress sutures are often performed as the anchoring stitch for skin flap closure as shown in Figure (2). ⁽¹²⁻¹⁵⁾

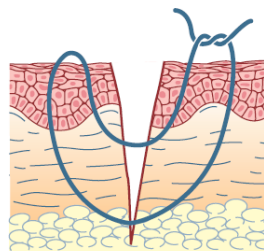


Figure.(2):- Vertical mattress suturing technique ⁽¹⁵⁾

The anchor suture is another suturing technique to close a flap located in an edentulous area mesial or distal to a tooth. It is best used in mesial or distal wedge

procedures. This suture closes the facial and lingual flaps and adapts them tightly against the tooth as shown in Figure (3).⁽¹⁶⁾

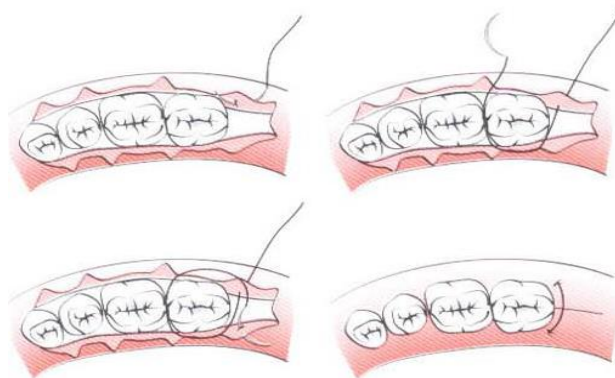


Figure.(3):- Anchor suturing technique⁽¹⁶⁾

The aim of the study is to determine the effect of changing the method of suturing on post-operative complications following the removal of impacted lower wisdom teeth, and to determine the best method of suturing technique associated with less complication.

MATERIALES AND METHODS

This study was carried out at the College of Dentistry, University of Mosul in Oral and Maxillofacial Surgery Department. A case sheet specially designed for this study was filled for each patient. Sixty medically fit patients were randomly selected with an age range between 16–42 years of both sexes. Women patients were excluded if they were pregnant or lactating. These patients had fully soft tissue impacted

lower third molars and indicated for surgical extraction. The diagnosis of third molar impaction was based on clinical and standard intraoral periapical and panoramic radiographs. All the cases were performed by the same surgeon, all of the impacted teeth were surgically extracted under local anaesthesia obtained by inferior alveolar, lingual and long buccal nerve block injections using 3.6 ml of 2% xylocaine with 1:80 000 adrenaline. The surgical removal of the impacted teeth was performed following the standard procedure including modified flaps. The socket was irrigated with chlorhexidin 0.2%. Following extraction, suturing of the flap was done. The patients were randomly allocated to three treatment groups; group I included twenty patients; the flap would be closed by simple interrupted

suture technique, and group II closed by vertical mattress suturing technique, and group III anchoring techniques, by using black silk suture 3:0 multifilament three knots of each type, on completion of surgery all patients were given Amoxicillin 500mg capsule (SDI, Iraq) three times daily for three days and Diclofenac sodium 50mg tab (Novartis, UK) three times daily for three days. All groups will be compared in regard to healing by clinical assessment to determine the complications. Post operative pain was assessed subjectively using the visual analogue scale (VAS). The visual analogue scale consists of a 10 cm line anchored at one end by the label 'No pain' and at the other end 'Worst possible pain'. The patient marks on the line the spot for the pain intensity which is then measured.⁽¹⁷⁾ Assessment of swelling was also subjectively assessed and as follows:

Grade 0= No swelling.

Grade 1= Edema of alveolar mucosa

buccally and /or lingually(intraorally).

Grade 2= Edema of alveolar mucosa buccally and /or lingually and involve the cheek (extraorally) to the lower border of the mandible.

Grade 3= Edema of alveolar mucosa buccally and /or lingually and involve the cheek (extraorally) below the lower border of the mandible.^(18,19)

Data for pain and swelling recorded for day one, three, seven post operatively.

Statistical analysis of the data was performed using Krusal-Wallis test and Mann-Whitney test and Wilcoxon Signed Ranks nonparametric test. Analysis were performed using SPSS program version 19 windowse A highly significant difference was considered at $p < 0.01$.

RESULTS

The demographic sex distribution and the mean age of all patients included in the present study are shown in Table (1).

Table (1): Sex distribution and mean age of patients

Group	Type of Suturing Technique	<u>Sex</u>		Total	Age Range (years)	Mean Age (years)
		Male	Female			
I	Simple	10	10	20	17-42	29.5
II	Vertical mattress	9	11	20	17-41	29
III	Anchor	6	14	20	16-40	28

Pain: By using the three types of suturing techniques, the range was nearly equal and decreasing steadily for the following post-operative days.

Swelling: Concerning post-operative swelling, the anchor suturing technique was associated with overt swelling specially at day one and day three. The results are shown in Table (2).

Table (2): Complications distribution in relation to treatment groups

Group	Type of Suturing Technique	Pain (mean)			Swelling(mean)		
		1	3	7	1	3	7
I	Day Simple	4.05	1.15	0.25	1.6	0.95	0.15
II	Vertical mattress	4.2	1.2	0.4	1.8	1.1	0.15
III	Anchor	4.05	1.45	0.4	2.1	1.65	0.25

Statistical analysis showed a highly significant difference of swelling at day three, in addition to causing significant

swelling at day one and as shown in Tables (3-5).

Table (3): Mann-Whitney Test Simple suturing versus Vertical suturing

	Pain Score Day 1	Pain Score Day 3	Pain Score Day 7	Swelling Grade Day 1	Swelling Grade Day 3	Swelling Grade Day 7
Mann-Whitney U	182.500	186.000	170.000	184.000	173.000	200.000
Wilcoxon W	392.500	396.000	380.000	394.000	383.000	410.000
Z	-.490	-.409	-1.000	-.500	-1.104	.000
P-value	.624	.683	.317	.617	.269	1.000

P- value is significant at < 0.01

Table (4): Mann-Whitney Test Simple suturing versus Anchor suturing

	Pain Score Day 1	Pain Score Day 3	Pain Score Day 7	Swelling Grade Day 1	Swelling Grade Day 3	Swelling Grade Day 7
Mann-Whitney U	198.000	162.000	170.000	133.000	79.500	180.000
Wilcoxon W	408.000	372.000	380.000	343.000	289.500	390.000
Z	-.056	-1.099	-1.000	-2.147	-3.688	-.781
P-value	.955	.272	.317	.032	.000 *	.435

*P- value is significant at < 0.01

Table (5): Mann-Whitney Test Vertical suturing versus Anchor suturing

	Pain Score Day 1	Pain Score Day 3	Pain Score Day 7	Swelling Grade Day 1	Swelling Grade Day 3	Swelling Grade Day 7
Mann-Whitney U	182.000	176.000	200.000	150.000	90.000	180.000
Wilcoxon W	392.000	386.000	410.000	360.000	300.000	390.000
Z	-.503	-.686	.000	-1.600	-3.547	-.781
P-value	.615	.493	1.000	.110	.000 *	.435

*P- value is significant at <0.01

DISCUSSION

In the present study three types of suturing techniques were used to close mucoperiosteal flaps after lower third molar removal and assessing the pain and swelling post operatively, as the two of most common problems encountered by patients after third molar surgery are pain and swelling, ⁽²⁰⁾ this was the main focus of this study.

Simple interrupted suturing is the most common technique used in which both sides

of incision require same amount of tension, anchor suturing allows the facial and lingual flaps to be positioned independently from each other, so reducing the time spent for tying knots but need time for removal. ⁽²¹⁾

There was no significant difference among the three types of techniques but in other study shows anchor suturing after third molar removal seems to provide better periodontal healing as we disagree with that study probably due to shorter period of follow up. ⁽²²⁾ Other study too has same

outcome disagree with us ⁽²³⁾. While other study shows better results when using a sliding sutured triangular flap than when using a mucogingival flap. According to these authors, primary closure of the flap avoids suture dehiscence and improves wound healing.⁽²⁴⁾ . However, in the opinion of other investigators, healing by second intention, where wound drainage is facilitated, causes less patient discomfort.^(25,26)

Other investigation showed hermetic primary closure of the surgical wound causes more postoperative pain and swelling than simple closure with approximation of the margins.⁽²⁷⁾ . Apparently, the flap design and suture technique even with an exposed area distal to the second molar did not result in a periodontal defect if properly carried out. This is an important point because in the suture-less flap technique attached gingiva is not pulled up tightly behind the second molar. On another hand results of other researches indicate that less edema and reduced pain.⁽²⁸⁾. This study agreed with our results. In general Halsted's surgical principles of wound healing applies but there are often exceptions . It seems that tight closure over a large bony socket or defect does not facilitate drainage and oral hygiene.⁽²⁹⁾

Pain and swelling after surgical removal of impacted third molars are related to inflammation consequence upon surgical

trauma. Previous studies show that pain and swelling are influenced by the reflection of a mucoperiosteal flap and the method of wound closure.⁽³⁰⁾

CONCLUSIONS

Changing the method of suturing technique appear to have no effect on the post-operative complications following surgical removal of impacted mandibular third molars at day one, three and seven.

REFERENCES

1. Alexander RE: Dental extraction wound management: A case against medicating post extraction sockets. J Oral Maxillofac Surg, 2000 58:538.
2. Birn H: Etiology and pathogenesis of fibrinolytic alveolitis („dry socket“). Int J Oral Surg 1973 ,2:215.
3. Brekke JH, Bresner M, Reitman MJ: Effect of surgical trauma and polylactate cubes and granules on the incidence of alveolar osteitis in mandibular third molar extraction wounds. J Can Dent Assoc 1986, 52:315.
4. Colby RC: The general practitioner's perspective of the etiology, prevention, and treatment of dry socket. Gen Dent 1997, 9:461.
5. Blum IR: Contemporary views of dry socket (alveolar osteitis). A clinical appraisal of standardization, actiopathogenesis, and management: A

- critical view. *Int J Oral Maxillofac Surg* 2002, 31: 309.
6. Larry J. Peterson .Peterson`s Contemporary Oral and Maxillofacial Surgery ; Mosby, Fourth edition; 2003; 184.
 7. Benediktsdottir IS, Wenzel A, Petersen JK, Hintze H: Mandibular third molar removal: risk indicators for extended operation time, postoperative pain, and complications. *Oral Surg Oral Med Oral Pathol Oral Radiol Endod* 2004, 97:438-446.
 8. Berge TI, Boe OE: Predictor evaluation of postoperative morbidity after surgical removal of mandibular third molars. *Acta Odontol Scand* 1994, 52:162-169.
 9. I.D. Schofield, S.L. Kogon and A. Donner, Long-term comparison of two surgical flap designs for third molar surgery on the health of the periodontal tissue of the second molar tooth, *J Can Dent Assoc* 54 1988 , pp. 689–691.
 10. C.C. Alling 3rd and G.A. Catone, Management of impacted teeth, *J Oral Maxillofac Surg* 51 1993 , pp. 3–6.
 11. N. Jakse, V. Bankaoglu, G. Wimmer, A. Eskici and C. Pertl, Primary wound healing after lower third molar surgery: evaluation of 2 different flap designs, *Oral Surg Oral Med Oral Pathol Oral Radiol Endod* 2002 , pp. 7–12.
 12. Zuber TJ. Skin biopsy, excision, and repair techniques. In: Soft tissue surgery for the family physician(illustrated manuals, videotapes, and CDROMs of soft tissue surgery techniques). Kansas City, Mo.: American Academy of Family Physicians, 1998:100-6.
 13. Stasko T. Advanced suturing techniques and layered closures. In: Wheeland RG, ed. Cutaneous surgery. Philadelphia: Saunders, 1994:304-17.
 14. Stegman SJ, Tromovitch TA, Glogau RG. Basics of dermatologic surgery. Chicago: Year Book Medical, 1982:42-5.
 15. Lars A, Karl-Erik K, M. Anthony P, Oral and Maxillofacial Surgery, Wiley-Blackwell., 1st edition, 2010, ch.9-151.
 16. H.H. Takei and F.A. Carranza, The periodontal flap. In: M.G. Newman, H.H. Takei, P.R. Klokkevold and F.A. Carranza, Editors, Carranza's clinical periodontology (10th ed.), Saunders Elsevier, St Louis 2007 , pp. 926–936.

17. Grossi GB, Maiorana C, Garramone RA, Borgonovo A, Beretta M, Farronato D, Santoro F, effect of sub mucosal injection of dexamethasone on post-operative discomfort after third molar surgery: a prospective study *J oral maxillofacial surg.* 2007 ,65:2218-2226.
18. Sabur JJ . Clinical evaluation of the dexamethasone and piroxicam for the control of swelling , trismus and pain following the removal of impacted lower third molar, MSc thesis .College of dentistry .University of Baghdad 1993.
19. Suliman MS, Clinical evaluation of the effect of four flap designs on the post-operative sequel (pain, swelling and trismus) following lower third molar surgery, *Al-Rafidain Dental Journal*, , 2005, vol. 5, no. 1: 24-32.
20. Shevel E, Koepp, WG, Biitow KW, A subjective assessment of pain and swelling following the surgical removal of impacted third molar teeth using different surgical techniques. *SADJ*, 2001, vol. 56, no.5,: 238.
21. Robert BO, Charles DA, Suturing materials and techniques, current opinion in periodontology. 1997, 4:89-95.
22. Burcu OC, Mahmut S, Ferda T , Elif OS Ferhat M, Influence of different suturing techniques on periodontal health of the adjacent second molars after extraction of impacted mandibular third molars, , August 2009, Pages 156-161.
23. Muthenna Sh. R, Jabbar J. k, Kadhim J, Raed A., Impact of Suturing Techniques on the Periodontal Health Status of Mandibular Second Molar After Extraction of Fully Impacted Third Molars, *Tikrit Journal for Dental Sciences* 2(2012)154-160.
24. Jakse N, Bankaoglu V, Wimmer G, Eskici A, Pertl C. Primary wound healing after lower third molar surgery: evaluation of 2 different flap designs. *Oral Surg Oral Med Oral Pathol Oral Radiol Endod.* 2002 Jan;93(1):7-12.
25. Clauser C, Barone R. Effect of incision and flap reflection on postoperative pain after the removal of partially impacted mandibular third molars. *Quintessence Int.* 1994 Dec;25(12):845-9.
26. De Brabander EC, Cattaneo G. The effect of surgical drain together with a secondary closure technique on postoperative trismus, swelling and pain after mandibular third molar

- surgery. *Int J Oral Maxillofac Surg.* 1988 Apr;17(2):119-21.
27. Pasqualini D, Cocero N, Castella A, Mela L, Bracco P. Primary and secondary closure of the surgical wound after removal of impacted mandibular third molars: a comparative study. *Int J Oral Maxillofac Surg.* 2005 Jan;34(1):52-7.
28. Szymd L, Hester WR: Crevicular depth of the second molar in impacted third molar surgery. *J Oral Surg Anesth Hosp Dent Serv* 1963;21:185.
29. Cohen IK, Diegelmann RF, Lindblad WJ: *Wound Healing-Biochemical and Clinical Aspects.* Philadelphia, WB Saunders, 1992.
30. Du Bois DD, Pizer ME, Chinnis RJ. Comparison of primary and secondary closure techniques after removal of impacted mandibular third molars. *Journal of Oral and Maxillofacial Surgery* 1982; 4ot 631-634.