

ULTRASONOGRAPHIC EXAMINATION OF LIVER OF CATTLE IN MOSUL, IRAQ

Osamah Muwaffag Al-Iraqi*, Medhat Khalid, Younis Masoud

*Department of Internal & preventive medicine, College of Veterinary Medicine, University of Mosul, Iraq.

Corresponding author: osamamuwafag@uomosul.edu.iq

Keywords: Ultrasound, liver, cattle, Mosul, Iraq

ABSTRACT

The objective of the study was to examine the normal liver using ultrasound technique for measuring liver thickness, portal and hepatic veins diameter in clinically normal cattle, furthermore to determine some liver lesions. Ultrasonography was used to evaluate the liver in 20 local cattle breeds of different ages 10 of them have exhibited clinical signs of chronic emaciation, icteric mucous membranes and decrease in milk production moreover, the other 10 cows were clinically normal. Liver position, diameter and texture were explored from the right side of the abdominal wall in standing position, without anesthesia by using 3.5 MHz transducer, after hair moistening by alcohol. The largest liver thickness was measured at the 10 and 12 intercostal space and it was decreased gradually forward. Normal liver has an echogenic appearance of equally distributed white dots and had a uniform mild echogenicity, there were an anechoic round and tubular vascular structures, representing hepatic and portal veins while abnormal liver has multi-hypoechoic circles. It has been concluded that, Sonography of normal liver can be utilized as a good diagnostic references in animals with liver diseases.

INTRODUCTION

Ultrasonography is an active technique, which need interaction between the veterinary sonologist, the animal, the ultrasound machine and the transducer to obtain best ultrasound images. Transducer send a series of ultrasound waves to the tissues that reflect and processed by the ultrasound unite into sequences of dots that form the image on the screen (1, 2). Ultrasonography of the liver have been done in human, rabbits, goats, sheep, cattle and buffaloes and consider the first step in diagnosis of chronic liver diseases (3, 4, 5, 6, 7, 8). In veterinary medicine there are many diagnostic tools have

been used however, ultrasound still one of the best imaging methods used in the diagnosis and follow-up of patient with liver diseases (9, 10, 11). Ultrasonography considers as a very important technique in the diagnosis of liver diseases in cattle, as a noninvasive technique provides excellent image for liver parenchyma and vessels without damaging the tissue (11, 12 13). A different in ultrasound velocities in different tissues make a different density of spikes on the screen and this helpful in the discrimination of internal alive normal or diseased organs (14). Ultrasonography has markedly enhanced the diagnosis of various hepatic diseases such as hepatic abscess, hepatic lipidosis, fascioliasis and caudal vena cava (CVC) thrombosis, Hematomas, cysts, neoplasms, nodules and abscess although these disorders do not have specific signs they can be diagnosed through ultrasonography and ultrasound-guided liver biopsy (3, 9 10, 11, 12 13). Studies in cattle have demonstrated that the presence of ultrasonographic features of hepatic fatty infiltration is a reliable indicator of hepatic lipidosis (9, 15, 16, 17). (18) Showed that hepatic ultrasonography is a more sensitive and specific method than biochemical analysis for diagnosis of diseased liver in the cattle. Hydatid cysts and liver fluke were recorded in local Iraqi cattle (19, 20). This study was planned to find out the usefulness of ultrasound in the liver examination and to diagnosis some liver lesions furthermore to demonstrating liver thickness and portal and hepatic veins diameter in clinically normal local cattle breed in Mosul, Iraq.

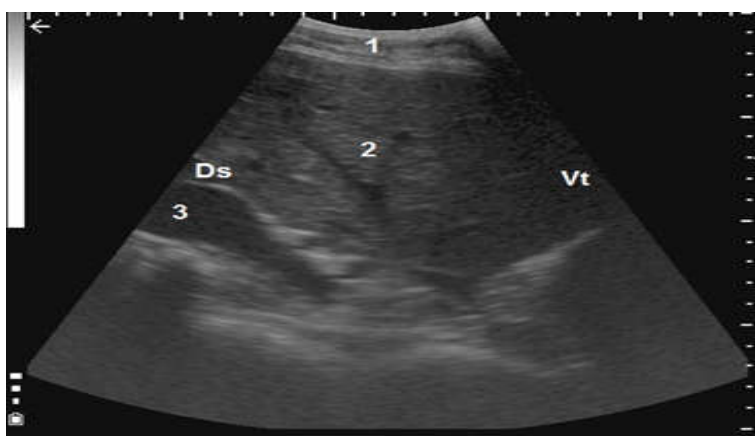
MATERIALS AND METHODS

Animals: Study included twenty local cattle breeds 2-9 years old, divided into two groups: first group included 10 clinically normal cows and other 10 diseased cows suffered from a chronic debility, icteric mucous membranes and decrease in milk production at local farms in Mosul city, Iraq. All animals submit to clinical examinations according to (21), whereas postmortem examination of the liver was done for 2 hopeless cows after slaughtered by their owner.

Ultrasonographic examination: The examination was done in standing position, without sedation. Sites were prepared by spraying alcohol then applying ultrasound gel on the 15-20 cm long areas caudal to costal arch and on the 12th, 11th, 10th and 9th intercostal spaces of the right flank according to (10, 22, 23) 3.5 MHz convex transducer was applied on the exploring area using B-mode grey-scale equipment (KX5100Vet, KeeboMed, USA) ultrasound machine. Several hepatic B-mode ultrasonograms were recorded as static images on the memory equipped on the instrument.

RESULTS

Ultrasonographical examination showed that liver was situated under the skin and muscles layer about 5 centimeter from the right lateral abdominal wall, and can be evaluated in the upper third of the 10th, 11th and 12th ICS while it could not be seen in the 9th ICS (figure 1). It appeared as homogenous equally scattered mild echoic dots, liver thickness was 105, 134, 141 mm in the 12th, 11th and 10th ICS respectively (table 1). A variable sizes hpoechoic circle, oval and triangle shape represented the portal vein, caudal vena cava (cvc) and hepatic vessels respectively. The cvc appeared as triangle shape in the dorsal part of the liver and it was largest diameter 20.33 mm in the 11th ICS and the smallest 19.1 mm in the 10th ICS and could not be imaged in the 9th ICS, while the portal vein appeared as circle shape in the ventral part of liver and it was largest diameter 24.08 mm appeared in the 11th ICS and the smallest 22.3 mm in the 10th ICS and could be seen in only in one cow in the 9th ICS (table 1).



Figure, 1: Ultrasonogram of normal liver of cattle imaged from the eleventh intercostal space. The abdominal wall (1), liver parenchyma (2), caudal vena cava (3), Ds, dorsal; Vt, ventral.

Table 1: Results of ultrasonographic examination of the liver thickness, caudal vena cava and the portal vein diameter of healthy cows

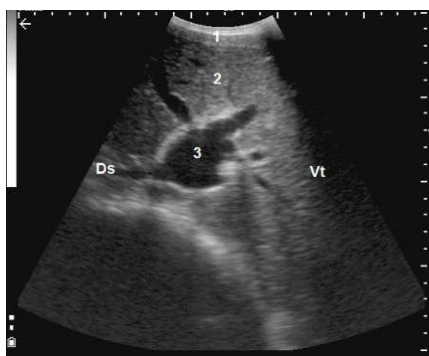
Variable		ICS (mm)	No. animals
1	Liver thickness	12 (105)	10
		11 (134)	10
		10 (141)	9
		9 (0)	0
2	CVC diameter	12 (19.6)	4
		11 (20.33)	4
		10 (19.1)	3
		9 (0)	0
3	PO. Vein diameter	12 (23.92)	4
		11 (24.08)	8
		10 (22.3)	5
		9 (21.4)	1

From results the portal and hepatic veins could be seen within the liver, and their diameter increases toward the portal vein and the caudal vena cava. The portal vein is site ventrally and laterally to the caudal vena cava and is usually visible in the twelfth to eighth intercostal spaces. On cross-section the portal vein, appear circular with stellate ramifications inside liver parenchyma (figure, 2). The diameter of the portal vein in the twelfth and eleventh intercostal spaces is between 21.4 – 26.3 mm and decreases cranially (table, 1),

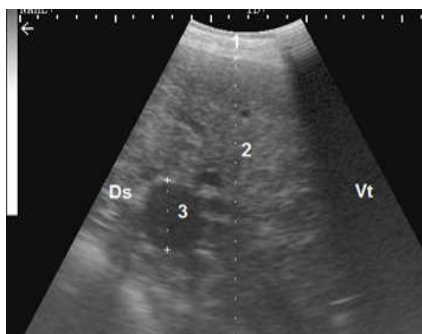
The caudal vena cava is site more dorsally and medially than the portal vein and usually denote in the twelfth, eleventh and tenth intercostal spaces (Figure 3).

The caudal vena cava rarely visualized in the tenth intercostal space and never in the cranial intercostal spaces, because the lungs hide it. The caudal vena cava embedded in the sulcus of the liver, so appear as a characteristic triangular shape on cross-section. The diameter of the caudal vena cava

does not change from the twelfth intercostal space to the tenth intercostal space and measures from 19.1 to 20.33 mm, toward the liver, hepatic veins are seen joining the caudal vena cava (table, 1).



Figure, 2: Ultrasonogram of liver thickness and portal vein diameter imaged from the twelfth intercostal space. The abdominal wall (1), liver (2), portal vein (3) Ds, dorsal; Vt, ventral.



Figure, 3: Ultrasonogram of liver thickness and caudal vena cava diameter imaged from the eleventh intercostal space. The abdominal wall (1), liver (2), caudal vena cava (3).

From clinical examination, all diseased cows showed chronic debility, jaundice and decrease in milk production with body temperature, respiratory and heart rate within normal range, at ultrasonographic imaging, liver appeared have irregular edge with many abnormality within parenchyma include multi-hypoechoic circles in 6 cows (figure 4), multiple small abscesses with calcified bile duct in 4 cows (figure 5).

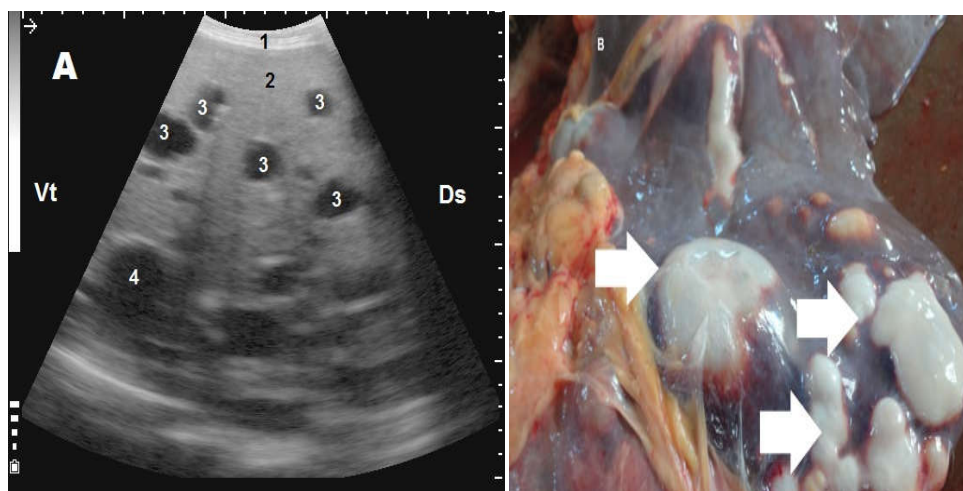


Figure 4: Ultrasonogram and postmortem of liver of diseased cow with multi-hypoechoic circles. skin 1, liver 2, multi cysts 3, CVC 4. B: liver with multi cystic lesion (white arrow)

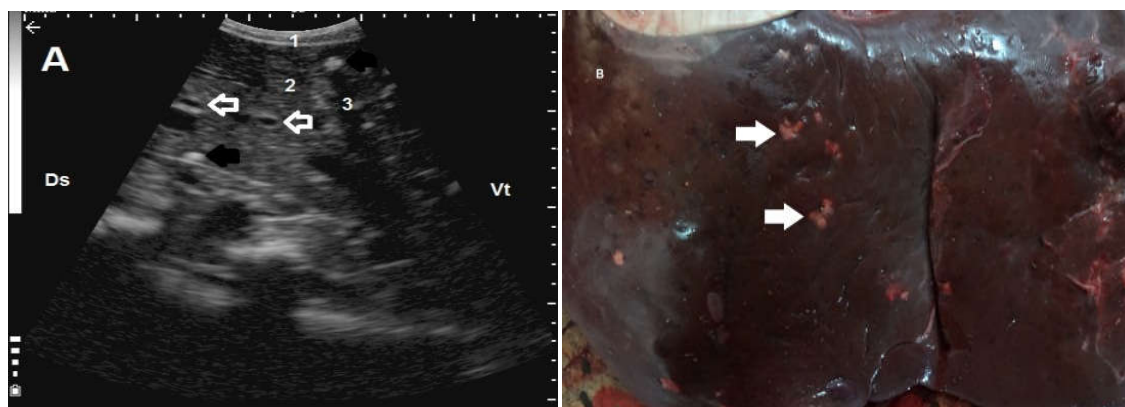


Figure 5: Ultrasonogram and postmortem of liver of diseased cow. A: skin 1, liver 2, calcified bile duct (white arrow), abscesses (black arrow). B: small abscesses (black arrow).

DISCUSSION

Liver situated directly under the abdominal wall so it is easy to examine by using a low frequency transducer and depend on the varying ultrasound velocity within tissues a different echogenicity appeared could differentiate between skin, subcute and liver tissue. The results of the current study were agreed with others (11, 14, 24). The parenchyma of the liver agree with (10) liver

has an echogenic appearance of equally distributed white dots and had a uniform mild echogenicity within liver tissue, there were an anechoic round and tubular vascular structures seen, representing hepatic and portal veins. The lumen of these vessels was anechoic and therefor appeared black. In contrast to hepatic vein, an echoic border characterized the wall of the portal vein, so it is easy to diagnose.

Mean liver thickness decreases caudally and measured (105, 134, 141) mm in the 12th, 11th, 10th intercostal spaces respectively, these results disagree with (10) and one of the explanation is due to the small size of the local breed cow were included in this study.

Clinically diseased cattle suffered from jaundice, debility and decrease milk production and on ultrasonographic examination were display many lesions include 6 cows have encapsulated hypoechoic cyst and other 4 cows have small abscesses with calcified bile ducts these results agree with (8, 25, 26, 27) which demonstrate ultrasonography has a benefit effect in diagnosis of liver lesions such as fascioliosis which appeared as heterogeneous parenchyma with calcified hyperechoic lined bile duct with hyperechoic dots that have distal acoustic shadowing. While hydatid cyst imaging display a circle capsulated hypoechoic area furthermore postmortem examination confirm the diagnosis of hydatid cysts and fascioliosis in liver parenchyma in 2 cows, these results agree with (19, 20) they demonstrate that in fascioliosis there were a hypertrophy, inflammatory cells infiltration with calcium salt precipitation in bile duct due to migration of liver fluke while hydatid cyst appear as white colored cyst.

Results of the current study of normal liver measurements can be used as references for local cattle breeds furthermore a diagnostic ultrasound can be used for follow up and give the prognosis of cattle with liver diseases.

REFERENCES

- 1-Reef, BV. (1998).** Equine diagnostic ultrasound. Saunders company.1-23.
- 2-Sttouffer, J. (2004).** History of ultrasound in animal science. American institute of ultrasound in medicine. Cornell university. New York USA.
- 3-Gonenci, R., Durgut, R., and Erdogan, S. (2003).** Evaluation of subclinical liver lesions in goats by ultrasonographic and biochemical analysis. Ankara Univ Vet Fak Derg, 50, pp: 47-51.

- 4-Ghadiri, A., Hajikolaie, M., Mohammadian, B., and Shahmarvandi, R. (2007).** Ultrasonographic Findings of the Liver in Lori Breed Sheep. Iran. J. vet. surg. 2(3): 39-48.
- 5-Stamatova, K., Dimitrov, R., Yonkova, P., Russenov, A., Yovchev, D., and Kostov, D. (2012).** Comparative imaging anatomic study of domestic rabbit liver (*oryctolagus cuniculus*). Trak. J. Sci. 10(1): 57-63.
- 6-Constanta, J. L. and Acorda, J. A. (2012).** Ultrasound features of the spleen, liver and kidney of the Bulgarian murrah buffaloes (*Bubalus bubalis* L.) at different stages of lactation. Philipp. J. Vet. Anim. Sci. 38(1): 73-84.
- 7-Gerstenmaier, J. and Gibson, R. (2014)** Ultrasound in chronic liver disease. Royal Melbourne hospital. University of Melbourne. Australia.5:441-455
- 8-Kumar, A., Saini, NS., Mohindroo, J., Singh, BB., Sangwan, V., and Sood, NK. (2016).** Comparison of radiography and ultrasonography in the detection of lung and liver cysts in cattle and buffaloes, Vet. Worl. 9(10): 1113-1120.
- 9-Streeter, RN., and Step, DL. (2007).** Diagnostic ultrasonography in ruminants. Vet Clin Food Anim. 23: 541- 571.
- 10-Braun, U. (2009).** Ultrasonography of liver in cattle. Vet Clin Food Anim. 25: 591–609
- 11-Itabisashi, T., Yamamoto, R., and Satoh, M. (1987).** Ultrasonogram of hepatic abscess in cattle inoculated with *Fusobacterium necrophorum*. J Vet Sci 49(4):585–92.
- 11-Vázquez, JD., Miranda, M., Barreiro-Vilanova, MI., and Javier, DF., and Barreiro LA. (2019).** Characterization of the Normal Portal and Hepatic Blood Flow of Adult Holstein-Friesian Cows. Animal. 9: 386
- 12-Jonsson, G., Bergsten, C., and Carlsten, J. (1988).** Ultrasonic diagnosis of liver abscesses in intensively fed beef cattle. In: Proceedings of the 15th World Congress on Cattle Diseases. Palma de Mallorca. 1428–1430.
- 14-Powis, RL. (1998).** Ultrasound science for veterinary. In: Rantanine NW, and McKinnon AO. Equine diagnostic ultrasonography. 1st ed. Williams & wilkins. 1-18.

- 15-Acorda, JA., Yamada MH. and Ghamsari, SM. (1994).** Ultrasonographic features of diffuse hepatocellular disorders in dairy cattle. *Vet radiol ultras.* 35(3): 196-200.
- 16-Thijssen, JM., Starke, A., and Weijers G. (2008).** Computer-aided B-mode ultrasound diagnosis of hepatic steatosis: a feasibility study. *Trans Ultrason Ferroelectr Freq Control.* 55(6):1343–54.
- 17-Abdelaal, AM., Gouda, SM., and Tharwat. M. (2014).** Clinic-biochemical. ultrasonographic and pathological findings of hepatic abscess in feedlot cattle and buffaloes. *Vet world.* 7 (5):306-310
- 18-Acorda, JA., Yamada MH., and Ghamsari, SM. (1995).** Ultrasography of fatty infiltration of the liver in dairy cattle using liver-kidney contrast. *Vet radiol ultras.* 35(5): 400-404.
- 19-Jarjees, MT., and Al-Bakri, HS. (2012).** Incidence of hydatidosis in slaughtered livestock at Mosul, Iraq. *Iraq. J. Vet. Sci.* 26(1): 21-25.
- 20-Al-Mahmood, SS., Farhan, AM., Daoud, ZS., and Hamed, OS. (2017).** Pathological study of liver lesions in cattle slaughtered at Kirkuk province abattoir. *Iraq. J. Vet. Sci.* 31(1): 7-16.
- 21-Radostits, OM. (2000).** Clinical examination of cattle and calves, in: Radostits OM, Mayhew IG and Houston DM. (2000). *Veterinary clinical examination and diagnosis.* WB SAUNDERS. 151-177.
- 22-Braun, U. (1990).** Ultrasonographic examination of the liver in cows. *Am J Vet Res.* 51(10):1522–6
- 23-Braun, U. (1996).** Ultrasonographic examination of the liver and gallbladder in cows: normal findings. *Compendium on Continuing Education for the Practicing Veterinarian.* Am J Vet Res. 18(2):61–72.
- 24-Konig, HE., and Liebich, HG. (2007).** *Veterinary anatomy of domestic mammals text book and colour atlas.* 3rd ed. Schattauer. 340.
- 25-Tharwat, M., Oikawa, S., and Buczinski, S. (2012).** Ultrasonographic Prediction of Hepatic Fat Content in Dairy Cows during the Transition Period. *J Vet Sci Technol.* 3:111.
- 26-Braun, U., Nuss, K., and Soldati, G. (2005).** Clinical and ultrasonographic findings in four cows with liver tumours. *Vet Rec.* 157(16):482–4.

- 27-Braun, U., Wolfensberger, R., and Hertzberg, H. (1995).** Diagnosis of liver flukes in cows: a comparison of the findings in the liver, in the feces, and in the bile. *Schweiz Arch Tierheilk.* 137(9):438–44.