

HISTO-MORPHOMETRIC COMPARSION STUDY OF THE COLON IN SHEEP AND GOAT IN SOUTH IRAQ.

Eyhab R. M. AL-Samawy*, Diyar M.H.Kadhim**, Dina Hamid Sadiq***,
Israa Jawad**, Ihab Abbas Taher*

*Department of Anatomy, College of Medicine, University of AL Muthanna, AL Muthanna, Iraq

**Department of Anatomy, College of Veterinary Medicine, University of AL Muthanna, AL Muthanna, Iraq

***College of Nursing, university of Basrah, Basrah, Iraq.

Key words: Goat, Large intestine, Mucosa.

Corresponding Author: eyhabrazzaq2@gmail.com

ABSTRACT

In the present study, the histo-morphometric comparison study of colon in goat and sheep was aimed. Ten of clinically healthy sheep and goats of both sexes were collected by Al-Simawa abattoir, age ranged between 2 to 3 years, which was estimated according to the dental equation of the animals. The colon was cut and stained alternatively with Hematoxylin and Eosin (H & E) and (PAS).

The epithelium was simple tall columnar epithelia that has goblet cells, these epithelia lining the folds of mucosa. In sheep the folds characters by a large number of goblet cells and the fold appeared long leaf-shaped folds arranged in a zig-zag pattern, whereas, in goat appeared short and blunt. The submucosa of the colon in the animals composed of abundant, dense connective tissue containing blood vessels and nerves. The muscularis externa composed of a thin, outer longitudinal layer and a thick inner circular layer between this was a narrow connective tissue. Externally, there was coated with layer of simple squamous epithelium under which was a thin layer of loose connective tissue containing a few small elastic fibers.

INTRODUCTION

The digestive system is the only system, which satisfies the energy need of the body through absorption of nutrients and thus it makes the powerful relation with nature by digesting various

types of feed, which are digested to specific animals. The large intestine is the termination of the ileum to the anus. The function of the large intestine is absorption of considerable quantity of water, vitamins and electrolytes and production of mucus (1).

The prime function of the colon as part of the large intestine is to reclaim excess moisture and return it to the body (2). In the process, fecal balls are formed, which can be passed through the rectum and are expelled out the anus (3).

Previous macroscopic and microscopic studies were conducted on the large intestine of different mammalian species. They showed its construction of three principal parts that were cecum, colon (transverse colon, ascending colon and descending colon) and rectum. Microscopically, the wall throughout its length is constructed of tunica mucosa, tunica submucosa, tunica muscularis and serosa or adventitia (4). The mucosa is made of simple columnar epithelium, lamina propria with intestinal glands lymphatic nodule and lamina muscularis. Lymphatic nodules are aggregated in the vicinity of the latter structure. Intestinal glands are lined by tall columnar cells, argentaffin cells and goblet cells. The latter type of cells is in highest number at the rectum (5).

Undigested feed and unabsorbed nutrients leaving the small intestine pass into this compartment. The functions of the large intestine include water absorption and further digestion of feed materials by microorganisms. The large intestine is comprised of the colon and rectum. Fecal pellets are formed in the end portion of the spiral colon. The capacity of the large intestine of goats ranges from 1 1/4 to 1 1/2 gallons. (6).

In the present study, the histo-morphometric comparison study of colon in goat and sheep were aimed.

MATERIALS AND METHODS

Specimens from ten of clinically healthy sheep and goats of both sexes were collected by Al-Simawa abattoir. The animals' age ranged between 2 to 3 years, which was estimated according to the dental equation of the animals. The study was carried during the period extended from 2017 to 2018. From the dissected animals, mid part of each segment of the colon was cut and fixed at 10% neutral buffered formalin for 48-72 h. The tissues were dehydrated in an ascending series of graded ethanol and then embedded in paraffin wax. By rotary microtome, sections were cut at 6 µm thicknesses, dewaxed in xylene, hydrated in descending graded ethanol and the

tissues were then mounted on grease free clean glass slides. The slides were prepared at room temperature stained alternatively with Hematoxylin and Eosin (H & E) and (PAS). The prepared slides were studied using a light microscope (Olympus binocular microscope). Photomicrographs of the prepared slides mounted on the binocular microscope were taken using a digital microscope objective. These pictures were then transferred to a computer and detailed studies were carried out.

RESULTS AND DISCUSSION

Morphological study:

The **colon** is about 7–9.5 m long, and consists of the ascending , transverse and descending colon. The **ascending colon**, the longest part of the large intestine, has three parts. The **proximal loop** runs chronically for a short distance to the plane of the right kidney, where it doubles back dorsal to the first part and the cecum. It then turns mediodorsally around the caudal border of the mesentery and runs cranially on the left .Side of the mesentery. Near the left kidney it becomes narrower and turns ventrally into the elliptical coil formed by the **spiral loop**. The transverse colon (2nd part of colon) crosses the abdomen in the umbilical region formed a wide U-shaped curve. This part was bended downward near the region of the spleen forming the left colic flexure then continues as descending colon. The latter extends from the left colic flexure to the pelvic below. It occupied the left upper and lower quadrants.

Light microscopy

The colon wall in the studied animals consists of four histological layers (Fig.1, 2) mucosa, submucosa, muscularis and serosa this study agreement with (1,5)

1- Tunica mucosa:

This layer is formed from the three sublayers; the epithelium was simple columnar epithelia that have goblet cells (Fig.1) these epithelia lining the circular folds of mucosa (Fig.1,A) this result agree with (7) in bovine. In sheep the folds characters by a large number of goblet cells and the fold appeared long leaf-shaped folds arranged in a zig-zag pattern (Fig.2, A), whereas, in goat appeared short and blunt (Fig.1, A).

The lamina propria formed from the loosely aggregation connective tissue with the presence of mucosal glands was simple branched tubular glands that lining by simple cuboidal epithelia (Fig.1,b) which have simple duct open between the fold and occupy most of the lamina propria between the base of the folds and the muscularis mucosa. The propria containing blood vessels, nerve and lymphocytes, the lamina propria extend inside the circular mucosa folds this study agreement with (1,5)

The last layer of the mucosa was formed from smooth muscle fibers called the muscularis mucosa; this separated the mucosa from the submucosa layer. Muscularis mucosa appeared as circularly arranged smooth muscle bundles interrupted by the presence of mucosal glands in the lamina propria in sheep (Fig.1,C), whereas, in goat appeared thinner layer of circularly arranged smooth muscle fibers separating the mucosa from the underlying submucosa (Fig. 2,C) this study was previously reported by(8,9,10).The mean thickness of this tunica in sheep was 3401 μ m, whereas, in the goat was 3281.1 μ m .

2- Tunica Submucosa:

The submucosa of the colon in the animals composed of abundant, dense connective tissue (Fig. 1, C). The mean thickness of this tunica in sheep was 132.2 μ m, whereas, in the goat was 112.5 μ m .

3- Tunica Muscularis :

The muscularis externa composed of a thin, outer longitudinal layer and a thick inner circular layer between this was a narrow connective tissue layer this in sheep (Fig.1, b), whereas, in the goat this tunica was collected of smooth muscle fibers oriented in three main directions,(Fig.2,b) the external layer is longitudinal, the middle layer is circular, and the internal layer was oblique this study was similar with (11) in ruminants. The mean thickness of this tunica in sheep was 3602.8 μ m, whereas, in the goat was 3632.3 μ m .

4- Serosa

Externally, there is a coated with layer of simple squamous epithelium under which was a thin layer of loose connective tissue containing a few small elastic fibers (Fig. 1,C) Blood vessels and nerves this study agreement with previous study with (7) in bovine and (12) in phillippine carabao (*Bubalus Bubalis*) and (13). The mean thickness of this tunica in sheep was 101 μ m, whereas, in the goat was 99.3 μ m .

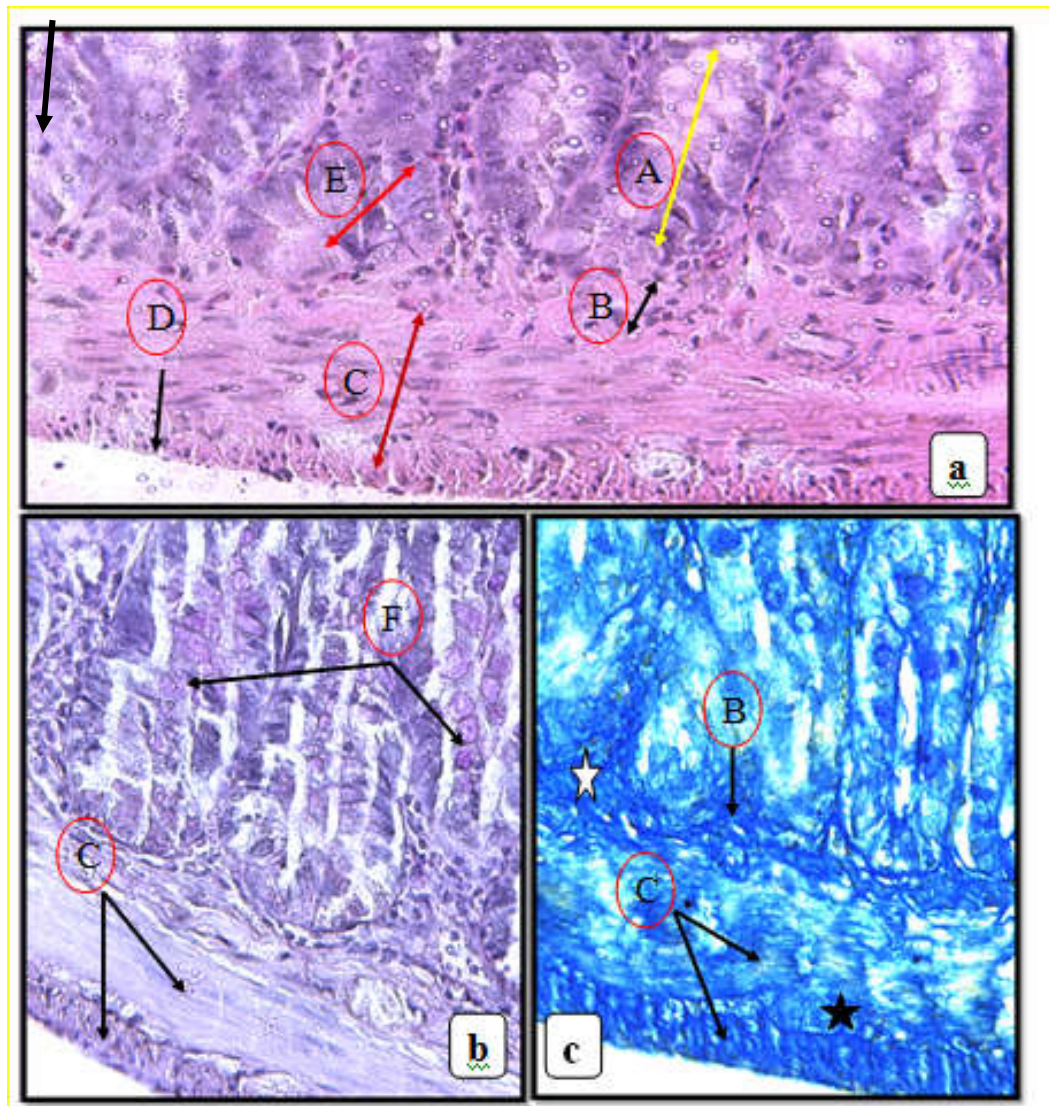


Fig.1. Cross section in the wall of colon in sheep showed mucosa (A, yellow double head arrow), submucosa (B), muscularis externa (C, brown double head arrow), serosa (D), intestinal glands (E, red double head arrow), goblet cells (F), connective tissue (white stars) in submucosa and between smooth muscle bundles of muscularis externa (black stars) H&E, . (a): PAS X 200 (b) and Lille's Alchrome stain, X200 (c).

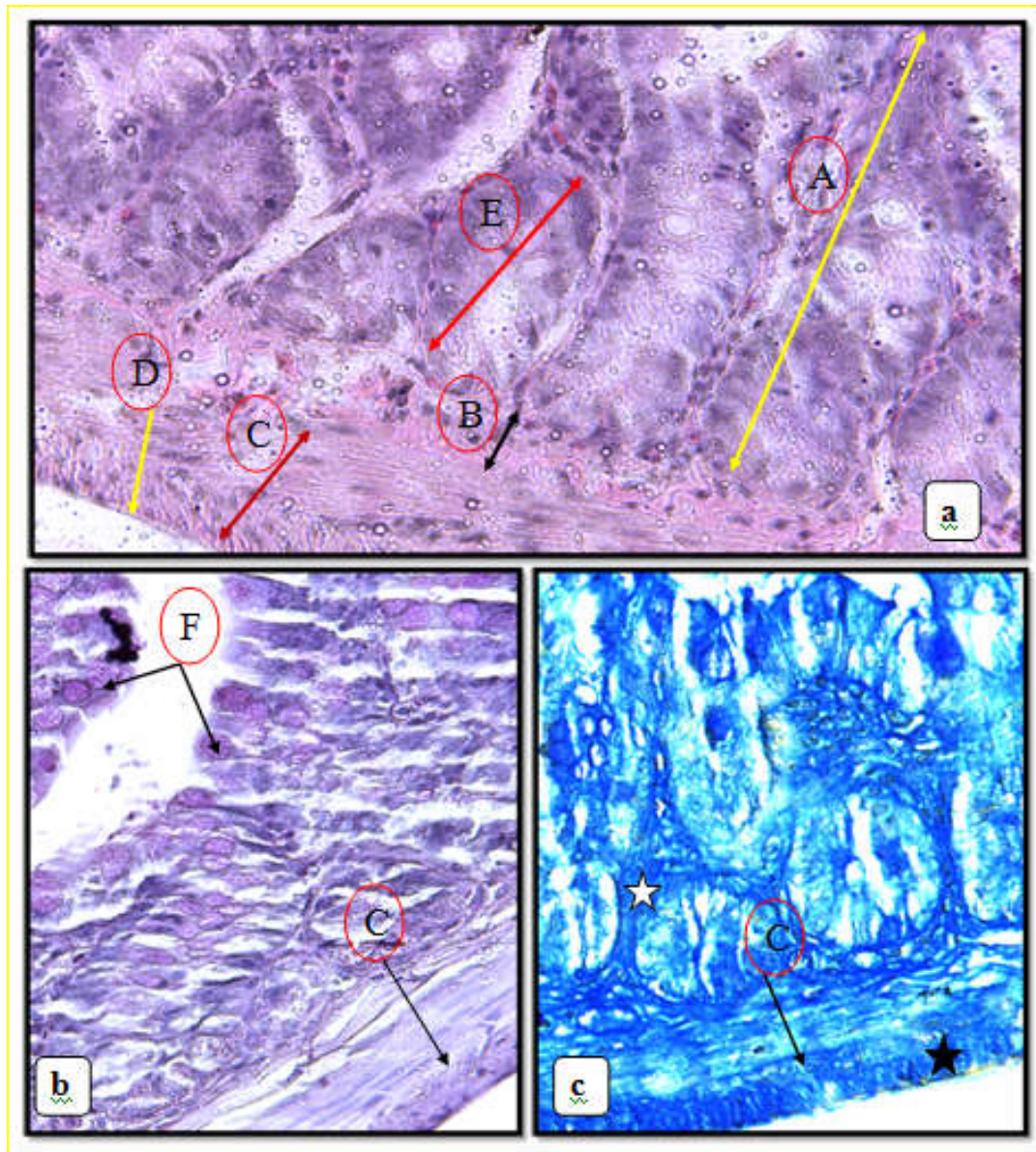


Fig.2. Cross section in the wall of colon in goat showed mucosa (A.yellow double head arrow), submucosa (B), muscularis externa (C. brown double head arrow) , serosa (D), intestinal glands (E. Red double head arrow), goblet cells (F), connective tissue (white stars) in submucosa and between smooth muscle bundles of muscularis externa (black stars)
H&E, X100. (a): PAS X 400 (b) and Lille's Alchrome stain, X200(c).

REFERENCES

- 1- Kadam S.D. , N.S. Bhosale, H.M. Aage and P.J. Kapadnis (2007).** STUDY OF HISTOARCHITECTURE OF LARGE INTESTINE IN GOAT. Indian J. Anim. Res., 41(3): 196 – 199.
- 2- Franco, A., Masot, A.J., Gómez, L. And Redondo, E. (2004).** Morphometric and immuno histochemical study of the rumen of red deer during prenatal development. J. Anat. 204: 501–513.
- 3- Bello, A., Sonfada, M.L., Umar, A.A., Umaru, M.A., Shehu, S.A., Hena, S.A., Onu, J.E. And Fatima, O.O. (2013).** Age estimation of camel in Nigeria using rostral dentition: Sci. J. Anim. Sci. 2(1): 9-14.
- 4- Călămar, C. D., Pătruică, S., Dumitrescu, G., Bura, M., Dunea, I. B. And Nicula, M., 2014.** Morpho-histological study of the digestive tract and the annex glands of *Chinchilla laniger*. Animal Science and Biotechnologies, 47 (1): 269-274.
- 5- Kadam S. D., Bhosale, N. S. And Kapadmis, P. J., 2009.** Comparative histological study of rectum in cattle, sheep and goat. Indian J. Anim. Res., 43 (2): 120-123.
- 6- Jurgens, M. H. (1993).** Animal feeding and nutrition. 7th Ed. Dubuque, IA: Kendall/Hunt Publishing Company.
- 7- Maala, C.P. And Cummings J.F.(1985).** *Anatomia Histologia Embryologia* 14(2): 116-141.
- 8- Raghavan, D. (1964).** Anatomy of the Ox. I. C.A.R. new Deih: 363-370
- 9- Getty, R. (1975).** Sisson and Grossman's Anatomy of the Domestic Animals. Vol. I, 5th Edn: 739-740, 904-908.
- 10- Ghosh, R.K. (1998).** Primary Veterinary Anatomy. Ist Edn.:133-135.
- 11- Bacha W.J. and Bacha L.M. (2000).** Color Atlas of Veterinary Histology 2nd Edn. Lippincott, Williams and Wilkins, Baltimore Maryland: 148-149.
- 12- Estacio, A.C. and Maala, C.P. (1996).** Abstracts of completed studies, PCC at UPLB College, Laguna.
- 13- Dellmann H.D. and Brown B.M.(1987).** Textbook of Veterinary Histology 3rd Edn. Lee and Febiger, Phialadelphia : 209-253.