

## Histological effects of cold watery fenugreek seeds extract on the Nephron in kidney of Albino mice

<sup>1</sup>Sarah Shareif Akool , <sup>2</sup> Bassim Abdullah Jassim

<sup>1,2</sup>Department of Biology , College of Science, Muthanna University.

\*Corresponding Author: [Bassimabdullah2017@gmail.com](mailto:Bassimabdullah2017@gmail.com)

Received:27/3/2016, Accepted:8/5/2016, published:6/10/2016

**Abstract:** The present study was designated to estimate the histological effect after administration of cold watery fenugreek seeds extract of the nephron in albino mice. This work was carried out on 40 healthy adult mice aging (6-8 months). The experimental animals was divided into four treated groups (A, B, C, D) and control group. Preparation the watery fenugreek seeds extract for administration with (150 mg/g) of concentration. The experimental animals treated with extract for different time periods as the following (15, 30, 45, 60 days). The histological results of the treated groups show after the following time periods [A after(15) days, B after (30) days, C after (45) days and D after (60) days of administration]. The histological results showed the nephrons composed of renal corpuscle, proximal convoluted tubules, Henel's loop, and distal convoluted tubules, the current results appears that the renal corpuscle composed of tuft of tinny capillaries glomerular surrounding by double layer called Bowmans capsule which contain between two layers occur main space that called Bowmans space, so showed the mesangial cells occupied the spaces between the glomerular capillaries. The glomerular capillaries had significant increase in diameter. The proximal convoluted tubules, lined by simple high cuboidal epithelial cells with more prominent brush border, the tubules characterized by significant increase in diameter. The present study Henel's loop notification the epithelial layer of internal surface of lined with simple squamous epithelial and acidophilic cytoplasm. The tissue section appears that the nephron composition characterized by significant increase in diameter with increased the time periods of administration of extract for the treated groups which showed exfoliated cells that aggregation in the lumen on tubular structures of the nephron. The extract have significant effect on the depression of height the epithelial cells lining of the internal surface of the proximal, henel loop, and distal convoluted tubules that associated with increased time of administration of extract which led to increase the glomerular infiltration rate that led to increase the amount of infiltration inside the tubular structures of the nephron in addition to increase the speed the infiltration flow .

© 2016 Muthanna University. All rights reserved.

---

### Introduction:

The nephron is the functional unite of the kidney; each nephron consists of corpuscle, proximal convoluted tubules, Henel's loop, distal convoluted tubules. The mammalian kidneys control the concentration of the body fluids. Some arid-adapted small mammals are efficient at concentrating urine in order to reduce water loss. [1,2].

*Trigonella fonum-graecum* (Linn.) is one of several herbal medicine that known as fenugreek, that have seeds and leaves are as food or as therapy in some disease [3]. Where is a major source of new drugs [4]. The fenugreek is an annual dicotyledonous herb belonging to the family Fabaceae, which have 30 to 60 cm tall, the seed of fenugreek is 3-6 mm long, 2-5 mm wide and 2 mm thick in

geometry. cultivated throughout Asian countries [5].

The fenugreek consist of compounds, soluble fiber [6,7], trigonelle [8], diosgenin [9], saponins [10,11] and 4-hydroxyisoleucine [12,13].

The fenugreek have pharmacological activities like diuretic activity, most of these effects have been well studied. However there is no isolated study that evaluates the diuretic effect of fenugreek. Therefore, this study was planned to evaluate clinically the diuretic effect of this herb.

The herbal medicine recommends by boiled fenugreek seeds in the case of the treatment of edema and fragmentation of urinary stones and urinary tract in the treatment of sprains. The fenugreek caused a significant increase in

sodium and potassium excretion with a significant decrease in osmolality. Where have a significant hypocalciuric effect, it was concluded that fenugreek has a very powerful diuretic effect and this effect is thiazide-like regarding urine flow and urine composition of electrolytes [14].

Fenugreek seeds extract used for antioxidant property of the plant material is due to the existence of many active phytochemicals containing vitamins, flavonoids, terpenoids, carotenoids, coumarins, curcumins, lignin, plant and sterol etc [15].

The seeds of fenugreek are considered to be of commercial interest as a source of a steroid diosgenin, which is important in the pharmaceutical industry. Where, the seeds are rich source of soluble dietary fiber content which described that the fiber content of fenugreek extract plays a role in its ability to

#### Materials and methods:

The present study was carried out on 40 healthy adult mice aging (6-8 months). The experimental animals was divided into four treated groups (A, B, C, D) and one control group. Each group composed of eight experimental animals.

Preparation of Cold Watery of Fenugreek Seeds Extract:

Trigonella seeds, bought from the local market Al-samawa city-Iraq, mode (50) gm of plant powder used in a glass flask with a capacity of (1000) ml airtight lid and container to 500 ml of cold water distilled, and shake the mixture using a motor stirrer device for 24

#### Experimental animals:

Histological study taken forty adult white mice, weighing  $30 \pm 3$  gm. The animals have been administrated by the aqueous extract of fenugreek seeds, and a groups of animals taken after different time periods (15,30,45,60). The animals were anaesthetized with gaseous chloroform in a closed container, after which a simple exploratory laparotomy procedure by its extremities were fixed to the dissection board with drawing pins and a vertical midline incision was done from the xiphoid process down to the pubic symphysis under the skin,

modest metabolism of glucose in the gastric tract [16, 17].

The general application of fenugreek is an important spice, its seeds and green leaves are used in food., the seeds have wide using in food and beverages as a flavoring additive as well as in medicines [15]. In Iranian traditional medicine the seeds are used as tonic and blood sugar lowering [18].

The seeds of fenugreek used hypoglycemic [19], hypocholesterolemic [20] properties, hypolipidemic, this plant decrease body fats and fenugreek use in therapy atherosclerosis [21], rheumatism [22], appetizer [23]. Animal studies shown that fenugreek seed extracts have the potential to slow enzymatic digestion of carbohydrates, decrease gastrointestinal absorption of glucose and thus decrease post-prandial glucose levels [9].

hours at room temperature and then the separation of the filtrate using a centrifuge (Centrifuge quickly) 3000/ rpm [24], put the filtrate in glass bottles and dried in an electric oven degree (40 m) for drying the extract and the survival of the solid material to prepare the concentrations required to test the impact (25). Concentration prepare (stock):

Dissolve 500mg active ingredient in 50 ml DW

Mean=500 mg/ 50 ml (DW)= 500,000µg /50 ml D.W.= 10,000µg/ ml

Mean each 0.1 ml of stock solution equal to 1000 µg active ingredient, this dose (150 mg/g) of fenugreek seeds extract.

abdominal muscles to the abdominal cavity and the viscera were retracted and the kidneys were exposed. Kidneys were released from their fatty covering connective tissue and gently removed. The kidneys were cut along the mid dorsal plane and immediately fixed in 10% neutral buffer formalin. The tissue was washed in tap water and processed by routine histological techniques by dehydration, clearing then embedding with malted paraffin. Cutting was done by using the rotary microtome. The thickness is (5 µm). And Staining which is two kinds of stains were

used hematoxylin and eosin stain also periodic acid Schiff (PAS)(26).

#### Results and Discussion:

The histological results of the control groups:

##### At fifteen days:

The result appeared that the cortical region consists of aggregation of nephrons, the renal corpuscles was the initial part of nephron which have  $(17.2 \pm 1.19 \mu\text{m})$  in diameter (Table1), this structure composed of a tuft of capillaries with  $(3.7 \pm 0.16 \mu\text{m})$  in diameter, (Table7), the renal corpuscle surrounded by double capsule consist of two layers (parietal and visceral layers), the parietal layer of the capsule was supported by prominent basement membrane with (PAS), the visceral layer covers the capillaries of the glomerulus, the podocyte and the mesangial cells are located among the glomerular capillaries, the mesangial cells located between glomerular capillaries with  $(3.2 \pm 0.22 \mu\text{m})$  in diameter, (Table6), between the two layers of capsule found space (Fig.1). These results similar to [27,28] which noted that the kidney of mammalian species has typical bean-shaped appearance characteristic of the unipolar mammalian kidneys, the nephron is the functional unite of the kidney; each nephron consists of corpuscle, proximal convoluted tubules, loop of Henle, distal convoluted tubules and collecting tubules. The mammalian kidneys control the concentration of the body fluids. Some arid-adapted small mammals are efficient at concentrating urine in order to reduce water loss.

The proximal convoluted tubules have  $(5 \pm 0.04 \mu\text{m})$  in diameter, (Table2), lined by high simple cuboidal epithelium, with prominent brush border. These results are similar to [29,30] who found that the proximal convoluted tubules are more acidophilic and more in number than distal convoluted tubules. The proximal convoluted tubules have brush border and have cuboidal to low columnar cells with clear central spherical nuclei.

The ascending branch of Henel's loop were in diameter  $(2 \pm 0.05 \mu\text{m})$ , (Table3) and lined with simple squamous epithelial cells (Fig.1). The descending branches of Henel's loop were

$(1.8 \pm 0.08 \mu\text{m})$  in diameter, (Table5), and lined with flat squamous epithelial cells with the nuclei protrude into the lumen. This result agree with (31,32) who showed that The medulla of each kidney is formed from thick parts lined by simple cuboidal epithelium and thin parts of the loops of Henle lined by simple squamous epithelium and the thin limb had a distinct rounded lumen. It could be clearly distinguished from the other parts of the nephron on the bases of its low lining epithelial squamous cells and the cytoplasm was homogenous eosinophilic. The thinner wall of this limb resembles the capillaries or small venules in their luminal. The thick descending portion in medulla is similar to the proximal convoluted tubules in cortex, while the thick ascending portion of medulla is similar to distal convoluted tubules in the cortex. The ascending limb of loop of Henle appears large in size than that of the descending limb and is enclosing a wider lumen.

The present study of distal convoluted tubules in the control group were  $(16.5 \pm 0.63 \mu\text{m})$  in diameter, (Table4), and lined by pale simple cuboidal epithelium without brush border. This result is similar to [33] who registered that the distal convoluted tubule is fewer in number and may be recognized by the pale cuboidal epithelial cells.

##### At thirty days:

The diameter of the renal corpuscles was  $(17.25 \pm 1.42 \mu\text{m})$ , (Table1) and the diameter of glomerular capillaries was  $(3.50 \pm 0.14 \mu\text{m})$ , (Table7). While the diameter of mesangial cells was  $(3.4 \pm 0.24 \mu\text{m})$ , (Table6), and have triangular shape between glomerular capillaries.

The proximal convoluted tubules with  $(5.1 \pm 0.04 \mu\text{m})$  in diameter, (Table2), and longer than the distal convoluted tubules, the tubules lined by simple cuboidal epithelium, which distinguished by the apparent brush borders of their epithelial cells.

The ascending limbs of Henels loop had diameter  $(2.0 \pm 0.05 \mu\text{m})$ , (Table3). In descending limbs of Henel loop have diameter  $(1.7 \pm 0.11 \mu\text{m})$ , (Table5), and continuations of

the proximal convoluted tubules, each descending limb wall was formed from flattened cells with round bulging nuclei.

The distal convoluted tubules with ( $17.1 \pm 0.54 \mu\text{m}$ ) in diameter, (Table4) and a smooth internal surface, and their cells lack a brush border, This tubules lined by simple cuboidal epithelia(Fig.1). The present results agreement with [29,34] which appear that the Henel's loop which consist of the straight proximal and distal tubules with the thin region. The thick descending tubule like to the proximal convoluted tubules, but the thick ascending tubules like to the distal convoluted tubules. The thin segment which composed of the thin descending and ascending portions of the nephron loop that is lined with simple squamous epithelium whose nuclei tend to bulge into the lumen.

At forty five days:

The histological results of nephron for this period that the diameter of the renal corpuscles with( $17.16 \pm 1.43 \mu\text{m}$ ),(Table1). The diameter of glomerular capillaries( $3.53 \pm 0.13 \mu\text{m}$ ),(Table7). The mesangial cells located between the golmerular capillaries which have diameter( $3.32 \pm 0.35 \mu\text{m}$ ),(Table6).

The proximal convoluted tubules had diameter( $4.9 \pm 0.02 \mu\text{m}$ ), (Table2), and longer than the distal convoluted tubules and comprise the major portion of the cortex, the proximal convoluted tubules lined by simple cuboidal epithelium which distinguished by the apparent brush borders of their epithelial cells.

The ascending limbs of Henel loop had diameter( $2.2 \pm 0.07 \mu\text{m}$ ),(Table3).

The descending limbs of Henel's loop had diameter ( $1.6 \pm 0.10 \mu\text{m}$ ),(Table5), and continuations of the proximal convoluted tubules. Each descending limb wall was formed from flattened cells with round, bulging nuclei.

The distal convoluted tubules with( $16.03 \pm 0.65 \mu\text{m}$ ) in diameter,(Table4), and a smooth internal surface, and their cells lack a brush border. The tubules lined by simple cuboidal epithelia. These results are in agreement with [35] who reported that the proximal convoluted tubules are more

acidophilic and longer than the distal convoluted tubules. The proximal convoluted tubules has large mitochondria and the luminal surface of the cells contain large number of microvilli. The length of microvilli reach ( $1 \mu\text{m}$ ) forming brush border. The proximal convoluted tubules have cuboidal to columnar cells with clear central circular nuclei. The increased in the constituent of the nephron was due to the normal growth of adult white mice.

At sixty days:

The present results of the nephron at this time noted the renal corpuscles was( $17.22 \pm 1.39 \mu\text{m}$ ),(Table1)

Glomerular capillaries surrounded by double layer of control group(Fig.1), with ( $3.60 \pm 0.17 \mu\text{m}$ ),(Table7). The mesangial cells located between the golmerular capillaries which have diameter( $3.3 \pm 0.41 \mu\text{m}$ ),(Table6). Proximal convoluted tubules had diameter ( $5.15 \pm 0.06 \mu\text{m}$ ),(Table2), and longer than the distal convoluted tubules and comprise the major portion of the cortex, The tubules lined by simple cuboidal epithelium which distinguished by the apparent brush borders of their epithelial cells.

The ascending limbs of Henel's loop had diameter( $2.1 \pm 0.06 \mu\text{m}$ ),(Table3).

The descending limbs of Henel's loop had diameter( $1.65 \pm 0.13 \mu\text{m}$ ),(Table5), and continuations of the proximal convoluted tubules. Each descending limb wall was formed from flattened cells with round, bulging nuclei(Fig.1).

The distal convoluted tubules had diameter( $16.27 \pm 0.44 \mu\text{m}$ ),(Table5) and a smooth internal surface, and their cells lack a brush border. The tubules lined by simple cuboidal epithelia. These results coincides with [31,36] The proximal convoluted tubule and distal convoluted are the initial and terminal parts of the nephron. The proximal convoluted tubule arises from the parietal epithelium of Bowman's capsule of the urinary pole of the renal corpuscle and exhibit a small, uneven lumen were lined by simple cuboidal epithelium. However, the proximal tubular cells were stained with more eosinophilic, granular cytoplasm and the lumen of the proximal tubules were narrower caused by

cellular microvilli at the apical border (brush border). The distal convoluted tubule is fewer in number and may be recognized by the pale cuboidal epithelial cells. The lumen diameters of distal convoluted tubules and collecting duct were larger than proximal convoluted tubules.

The treated group which administration with (150 µg/g)

After fifteen days:

The current study show the nephron , the renal corpuscle , this structure like to histological structure of the renal corpuscle in the control groups, the renal corpuscle have significant increase in the diameter with (19.09±1.28µm) (Table1 ). The wider than the structure in the control groups.

In This study the mesangial cells don't appear any change in diameter (3.2±0.25µm),(Table6).

The glomerular capillaries have significant increase of diameter that was (3.69±0.21µm),(Table7).

In proximal convoluted tubules ,the histological results appear this structure lined with simple high cuboidal epithelial cells with more prominent brush border, the tubules characterized by significant increase of diameter with (5.2±0.07µm),(Table2).The present study Henel's loop notification the epithelial layer of internal surface of lined with simple squamous epithelial and acidophilic cytoplasm (Fig.2).

The ascending branches of Henel's loop don't any increase with diameter (2±0.04µm),(Table3).

The descending branches of henels loop don't elevated any increase in diameter with (1.5±0.08µm),(Table5). These results similar with [37] who suggested that the fenugreek had a significant hypocalciuric effect, in respect to the control group. Serum values of sodium, potassium, chloride, calcium, pH and osmolality did not reveal any significant change compared with the control values. It was concluded that fenugreek has a very powerful diuretic effect and this effect is thiazide-like regarding urine flow and urine composition of electrolytes.

This result noted that the epithelial cells of the internal surface of the distal convoluted tubules lined with low simple cuboidal epithelial cells without any brush border. This result show the significant elevated in the diameter of tubules with (7.3±0.4µm) compared with control (Table4 ),(Fig.2). This results coincides with [38,39] who reported that the fenugreek has a wide range diuretic activities. Many of these effects have been well studied regarding the mechanism of action, clinical evaluation and the specific constituent behind each effect.

At thirty days:

The histological section of the kidney show the cortex at this period show slightly the variation in histological components of the renal corpuscle which show this structure, have normal shape and have significant increase in diameter (26.94±1.21µm),(Table1), with prominent Bowmanns spaces,

The diameter of glomerular capillaries with (4.0±0.20µm),(Table7).

The mesangial cell don't show any increase in diameter (3.5±0.30µm),(Table6).

The proximal convoluted tubules appear normally structures with prominent narrow lumen similar to the control group, with prominent the cell shape which have significant increase in diameter (6.6±0.1µm),(Table2).

The histological section of the ascending of henels loop show similar to the ascending in the control group which don't noted any increase in

diameter(2.2±0.06µm),(Table3).The descending branches of Henel's loop, show similar to the descending in the control group, the descending branches don't appear any increase in diameter(1.8±0.12µm),(Table5).

The distal convoluted tubule, Same to the control groups with prominent in the lumen (Figure.3), and also prominent the cell epithelia, the distal convoluted tubules increased in diameter(8.8±0.64µm),(Table4). These results agreement with [40] who reported that the section of kidneys from experimental animals without any histological damage that compared with control.



At forty five days:

The histological results of the kidney for administration for this period to concentration (150mg/g) of watery fenugreek seeds extract showed renal corpuscle that the diameter ( $28.00 \pm 1.20 \mu\text{m}$ ), (Table1) which appear more prominent from previous time in the mesangial cell that slightly proliferation and don't noted any increase in diameter ( $3.6 \pm 0.32 \mu\text{m}$ ), (Table6).

The glomerular capillaries with ( $4.96 \pm 0.19 \mu\text{m}$ ) in diameter, (Table7).

In present study appeared that the proximal convoluted tubules have the wide lumen than the previous groups with decrease in the height epithelial cells in the lumen of this structure (Fig.4), the proximal convoluted tubules have significant increase of diameter ( $7.7 \pm 0.15 \mu\text{m}$ ), (Table2).

The histological results present that the lumen of the ascending and descending of the Henels loops more prominent than the previous times, where the ascending don't appear any increase of diameter ( $2.5 \pm 0.09 \mu\text{m}$ ), (Table3), and the descending don't show any increase in diameter ( $2 \pm 0.09 \mu\text{m}$ ), (Table5).

The distal convoluted tubules show that have wide lumen than in the previous group with decrease in height epithelial cells in the lumen (Fig.4), the distal convoluted tubules have significant increase of diameter ( $9.9 \pm 0.6 \mu\text{m}$ ), (Table4). These results coincides with [41,42] which stated that the fenugreek seeds is known to protect kidney morphology and improve renal functions and increased diuresis, antioxidant activity and lowering of urinary concentrations of stone forming constituents are suggested mechanism for anti-urolithiatic effects of fenugreek seeds with need of further exploration for responsible chemical constituents. However, such exploratory

studies on fenugreek seed extract for active constituent or therapeutic action reported.

At sixty days: The histological section of the kidney after gives watery extract of the fenugreek seeds, the present study showed that renal corpuscle larger than the previous time that have increase of diameter ( $30.00 \pm 1.16 \mu\text{m}$ ), (Table1), with decrease the Bowman's spaces, the outer line the renal corpuscle show more prominent the basement membrane in the parietal layer of Bowman's capsule.

The glomerular capillaries have significant increase of diameter ( $5.0 \pm 0.22 \mu\text{m}$ ), (Table7) and with more prominent the mesangial cell that located as slightly aggregation between the glomerular capillaries (Fig5), the mesangial cell don't show any increase in diameter ( $4.0 \pm 0.36 \mu\text{m}$ ), (Table 6), (Fig.5).

The histological section in the proximal convolute tubule show the primary proliferation of the cells in the well of this structure and more prominent with slightly increase in internal lumen and have significant increase of diameter ( $7.8 \pm 0.18 \mu\text{m}$ ), (Table2). There are no any changes in the histological structures of cross section in the descending and ascending henels loop, where don't show any increase in diameters of the ascending which ( $2.8 \pm 0.10 \mu\text{m}$ ) in diameter, (Table3) and descending which ( $2.2 \pm 0.08 \mu\text{m}$ ) in diameter, (Table5).

The distal convoluted tubules dispersed brush border that located in apical surface of epithelial cell in the lumen of the proximal convoluted tubules (Fig.5), the results elevated that distal convoluted tubule have significant increase in diameter ( $10.0 \pm 0.5 \mu\text{m}$ ), (Table4). These results are agreement with [39] who reported that the proliferation rate and activity of epithelial cells in the nephron. The fenugreek seeds have effects on the intestinal epithelia and immunological variables.

Table1. Diameter of renal corpuscles in white mice. ( $\mu\text{m}$ )

Group Period	Treated G1	Control
After 15 days	19.09 $\pm$ 1.28 B b	17.2 $\pm$ 1.19 B b
After 30 days	26.94 $\pm$ 1.21 B a	17.25 $\pm$ 1.42 C a
After 45 days	28.00 $\pm$ 1.20 B a	17.16 $\pm$ 1.43 C a
After 60 days	30.00 $\pm$ 1.16 C a	17.22 $\pm$ 1.39 D a

Different capital letters denote significant results ( $P \leq 0.01$ ) between different groups Row Different small letters denote significant results ( $P \leq 0.01$ ) between periods Column

Table2. Diameter of proximal convulated tubules. ( $\mu\text{m}$ )

Group Period	Treated G1	Control
After 15 days	5.2 $\pm$ 0.07 B b	5 $\pm$ 0.04 B a
After 30 days	6.6 $\pm$ 0.1 B a	5.1 $\pm$ 0.04 C a
After 45 days	7.7 $\pm$ 0.15 B a	4.9 $\pm$ 0.02 C a
After 60 days	7.8 $\pm$ 0.18 C a	5.15 $\pm$ 0.06 D a

Values represent mean  $\pm$  S.E

Different capital letters denote significant results ( $P \leq 0.05$ ) between different groups (Raw).

Different small letters denote significant results ( $P \leq 0.05$ ) between periods (Column).

Table3. Diameter of ascending branch of Henel's loop. ( $\mu\text{m}$ )

Group Period	Treated G1	Control
After 15 days	2 $\pm$ 0.04 A a	2 $\pm$ 0.05 A a
After 30 days	2.2 $\pm$ 0.06 B a	2.0 $\pm$ 0.05 B a
After 45 days	2.5 $\pm$ 0.09 B a	2.2 $\pm$ 0.07 C a
After 60 days	2.8 $\pm$ 0.10 B a	2.1 $\pm$ 0.06 C a

Values represent mean  $\pm$ S.E

Different capital letters denote significant results( $P<0.05$ ) between different groups (Raw).

Different small letters denote significant results ( $P< 0.05$ ) between periods(Column).

Table4. Diameter of distal convulated tubules in white mice. ( $\mu\text{m}$ )

Group Period	Treated G1	Control
After 15 days	7.3 $\pm$ 0.4 B c	16.5 $\pm$ 0.63 A a
After 30 days	8.8 $\pm$ 0.64 C b	17.01 $\pm$ 0.54 A a
After 45 days	9.9 $\pm$ 0.6 D a	16.03 $\pm$ 0.65 A a
After 60 days	10.0 $\pm$ 0.5 B a	16.27 $\pm$ 0.44 A a

Values represent mean  $\pm$ S.E

Different capital letters denote significant results( $P<0.01$ ) between different groups(Raw).

Different small letters denote significant results ( $P< 0.01$ ) between periods(Column).



Table5. Diameter of descending branch of Henel's loop.  $\mu\text{m}$ 

Group Period	Treated G1	Control
After 15 days	1.5 $\pm$ 0.08 B a	1.8 $\pm$ 0.08 B a
After 30 days	1.8 $\pm$ 0.12 B a	1.7 $\pm$ 0.11 B a
After 45 days	2 $\pm$ 0.09 BC a	1.6 $\pm$ 0.10 C a
After 60 days	2.2 $\pm$ 0.08 B a	1.65 $\pm$ 0.13 C a

Values represent mean  $\pm$ S.E

Different capital letters denote significant results( $P < 0.05$ ) between different groups(Raw).

Different small letters denote significant results ( $P < 0.05$ ) between periods(Column).

Table6. Diameter of mesangial cells in white mice. ( $\mu\text{m}$ )

Group Period	Treated G1	Control
After 15 days	3.2 $\pm$ 0.25 B a	3.2 $\pm$ 0.22 B a
After 30 days	3.5 $\pm$ 0.30 B a	3.4 $\pm$ 0.24 B a
After 45 days	3.6 $\pm$ 0.32 B a	3.32 $\pm$ 0.35 B a
After 60 days	4.0 $\pm$ 0.36 B a	3.3 $\pm$ 0.41 B a

Values represent mean  $\pm$ S.E

Different capital letters denote significant results( $P < 0.05$ ) between different groups (Raw).

Different small letters denote significant results ( $P < 0.05$ ) between periods(Column).

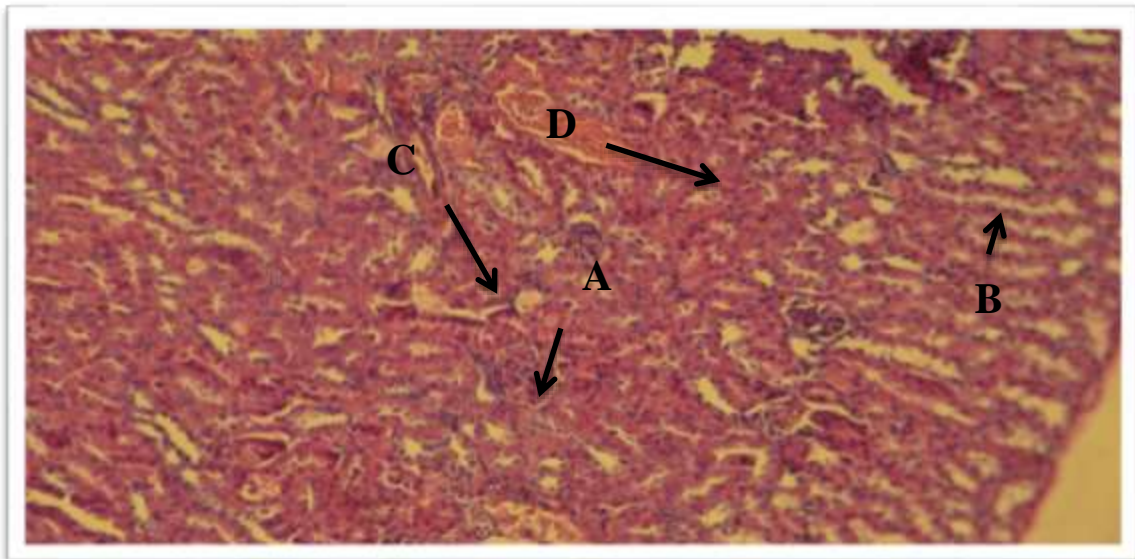
Table7. Diameter of glomerular capillaries in white mice. ( $\mu\text{m}$ )

Group Period	Treated G1	Control
After 15 days	3.69 $\pm$ 0.21 B c	3.7 $\pm$ 0.16 B a
After 30 days	4.0 $\pm$ 0.20 BC bc	3.50 $\pm$ 0.14 C a
After 45 days	4.96 $\pm$ 0.19 B ab	3.53 $\pm$ 0.13 C a
After 60 days	5.0 $\pm$ 0.22 C a	3.60 $\pm$ 0.17 D a

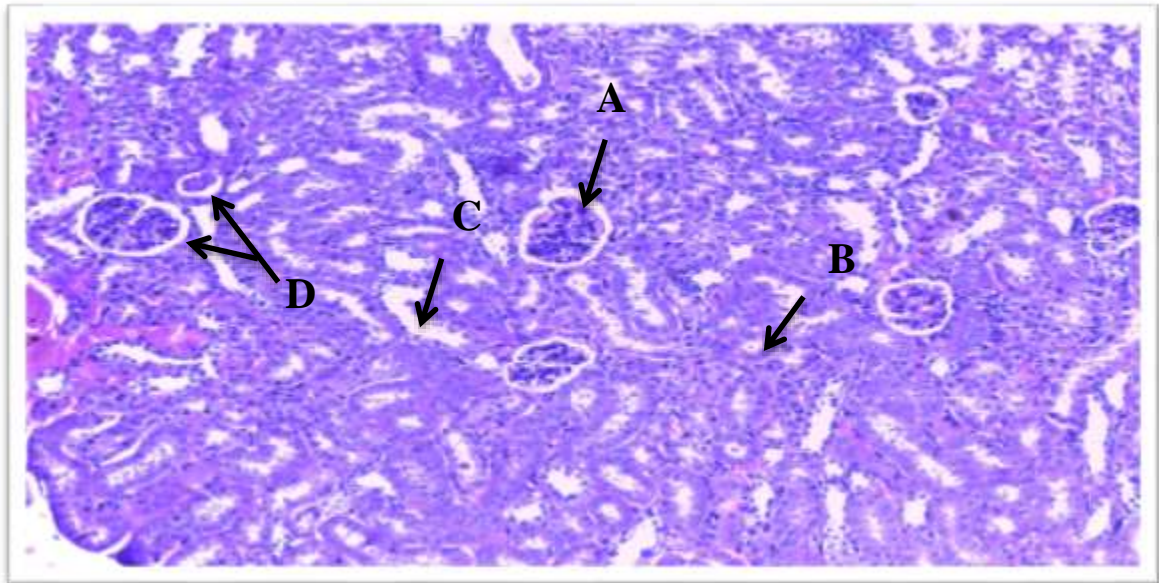
Values represent mean  $\pm$ S.E

Different capital letters denote significant results ( $P < 0.05$ ) between different groups (Raw).

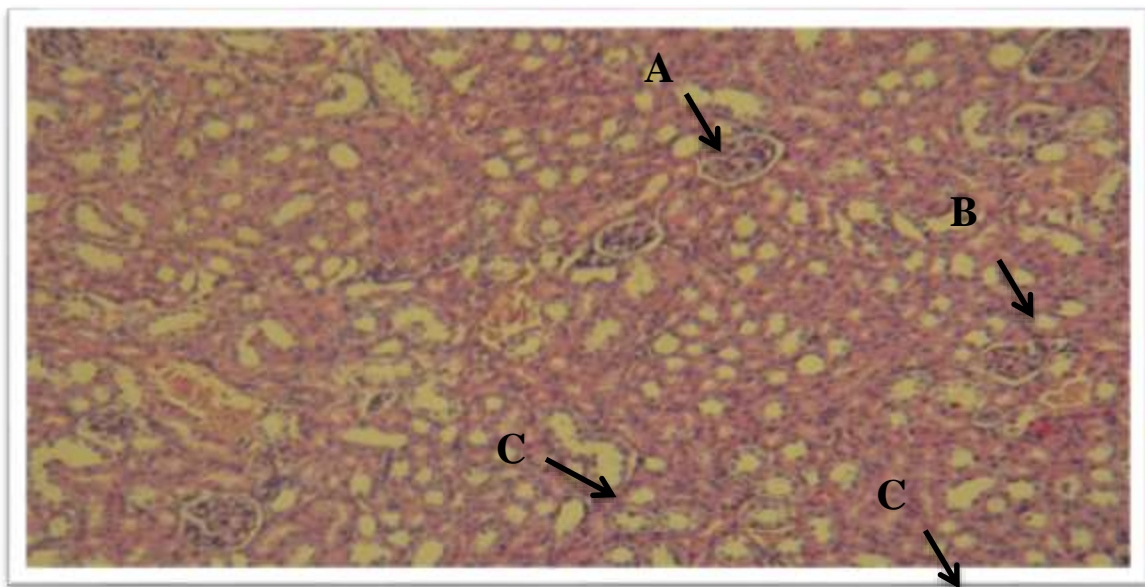
Different small letters denote significant results ( $P < 0.05$ ) between periods(Column).



**Fig.(1):** Cross section of the control kidney in mice showed the glomeruli (A), bowman capsule (B), distal tubules (C), proximal tubules (D)Henel loop. H & E X40.

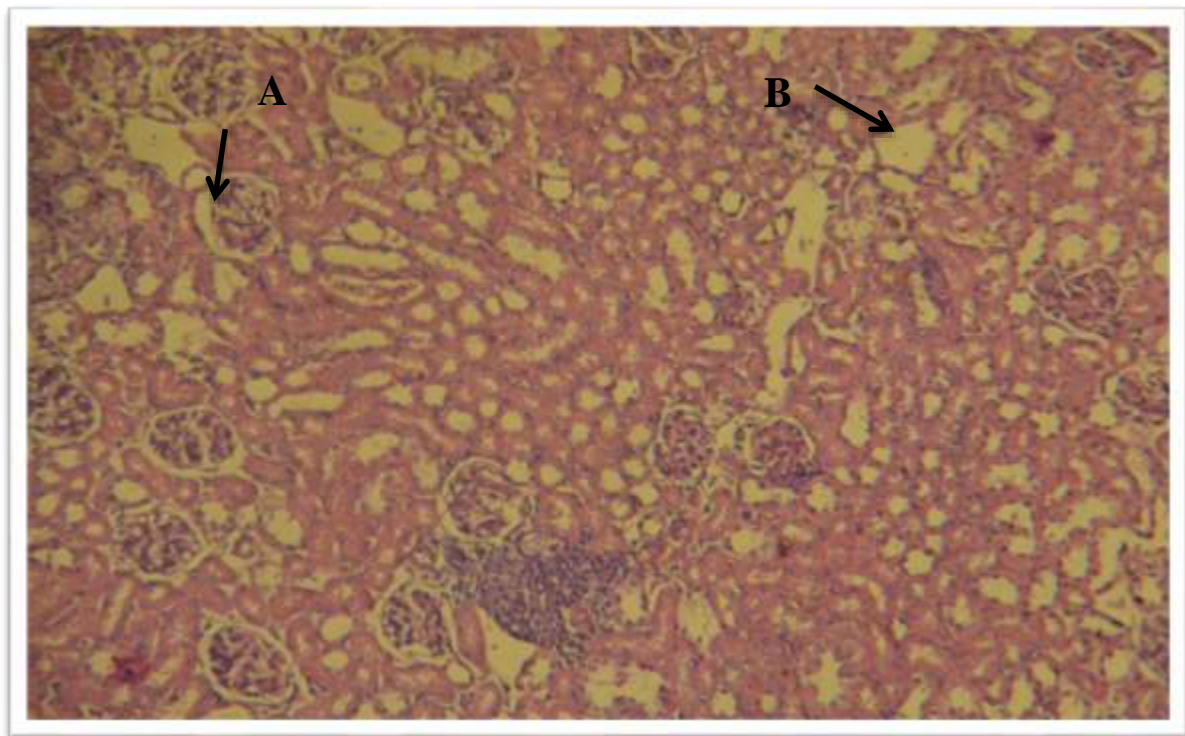


**Fig.(2):** Cross section of the kidney in mice at 15 day showed A- renal corpuscle and bowmans space, B- proximal tubules. C- distal convoluted t, D- basement membrane H & E (400).

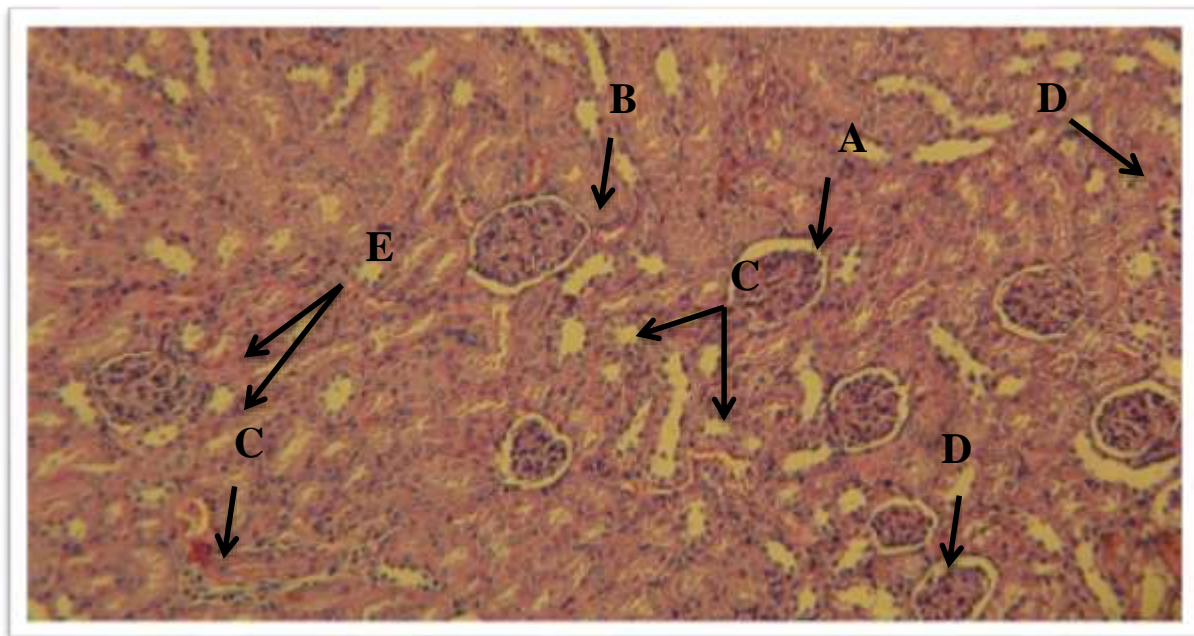


**Fig.(3):** Cross section of the tread kidney in mice at(30) days that showed the A-Renal corpuscle prominent bowmans space. B- epithelial cells of P.C.T. C-epithelial of D.C.T. D- lumen of henel loop. H & E (X40).





**Fig.(4):** Cross section of the tread kidney in mice at(45) days that showed A- wide bowmans space of renal corpuscle, B- cystic dilation of P.C.T., C- Prominent diameter of glomerular capillary, D- henel loop with wide diameter H & E ( 400).



**Fig.(5):** Cross section of the tread kidney in mice at(60) days that showed the A- wide bowman's space and prominent basement membrane ,B- Enlarges tuft of glomerular capillaries, C- Disappear some epithelial cells in D.C.T., D- Prominent diameter of henel loop. P.A.S (A) X40.

## References:

- [1]Brooker, B. and Withers, P. (1994): Kidney structure and renal indices of dasyurid marsupials. Australian Journal of Zoology, V:42 pp:163-176.
- [2]Cutler, R. E. (2006): Kidney :Biology of the Kidneys and Urinary Tract, In: The Merck Manual Home Edition. Retrieved From <http://www.merck.com/mmhe/sec11/ch141/ch141b.html> on 29/12/09 at 13: 23 GMT +1West Africa.
- [3]Bellakhdar, J. (1997): La Pharmacopee Marocaine Traditionnelle Arabe Ancienne et SavoirsPopulaires. Ibis Press: Paris, pp:320-321.
- [4]Vuorelaa P. M, Leinonenb M, Saikkuc P, Tammela P, Rauhad JP, Wennberge T, Vuorela H. (2000): Natural products in the process of finding new drug candidates. Med Chemistry,11(11): pp:1375-89.
- [5]Shishtoppo F, Akh and RandPathak AK. (2009): Pharmacological actions and potential uses of Trigonella foenum-graecum: a review. Asian J Pharmaceut Clin Res, 2(4) pp:29-38.
- [6]Neeraja A, Rajyalakshmi P (1996): Hypoglycemic effect of processed fenugreek seeds in humans. J Fd Sci Technol 33:pp: 427-430.
- [7]Hannan JM, Ali L, Rokeya B, Khaleque J, Akhter M, Flatt PR, Abdel-WahabYH. (2007): Soluble dietary fibre fraction of Trigonella foenum-graecum (fenugreek) seed improves glucose homeostasis in animal models of type 1 and type 2 diabetes by delaying carbohydrate digestion andabsorption, and enhancing insulin action.v:97 pp:514–521.
- [8]Moorthy R, Prabhu KM, Murthy PS. (2010): Anti-hyperglycemic compound (GII) from fenugreek (Trigonella foenum-graecum Linn) seeds, its purificationand effect in diabetes mellitus.V:48. pp:1111–1118.
- [9]Uemura T, Hirai S, Mizoguchi N, Goto T, Lee JY, Taketani K, Nakano Y, ShonoJ, Hoshino S, Tsuge N, ( 2010): Diosgenin present in fenugreek improves glucose metabolism by promoting adipocyte differentiation and inhibiting inflammation in adipose tissues. v: 54pp: 1596–1608 .
- [10]Lu F, Shen L, Qin Y, Gao L, Li H, Dai Y. (2008): Clinical observation on TrigonellaFoenum-graecum L. total Saponins in combination with sulfonylureas in the treatment of type 2 diabetes mellitus.v:14 pp:56–60.
- [11].Sauvaire Y, Baissac Y, Leconte O, Petit P, Ribes G(1996):Steroid saponins fromfenugreek and some of their biological properties.Adv Exp Med Biol1996,405:37–46.
- [12]Singh AB, Tamarkar AK, Narender T, Srivastava AK, (2010): Antihyperglycaemic effect of an unusual amino acid(4hydroxyisoleucine) in C57BL/ KsJ-db/db mice.v:24:pp:258–265.
- [13]Sauvaire Y, Petit P, Broca C, Manteghetti M, Baissac Y, Fernandez-Alvarez J, Gross R, Roye M, Leconte A, Gomis R, Ribes G. (1998): 4-Hydroxyisoleucine: a novelamino acid potentiator of insulin secretion.Diabetes,v:47 pp:206–210.
- 14ج.اغروتیکا1999.المجلة الزراعية في الشرق الاوسط والعالم العربي- التداوي بالاعشاب د. منى رويحة
- [15]Birjees Bukhari S, Bhanger ML, Memon SH. (2008): Antioxidative activity of extracts from fenugreek seeds (Trigonella foenum-graecum), Pak J Anna EnviroChem,;V:9.pp: 78-83.
- [16]Raju J, Gupta D, Rao AR, Yadava PK, Baquer NZ (2001): Trigonella foenum graecum (fenugreek) seed powder improves glucose homeostasis in alloxan diabetic rat tissues by reversing the altered glycolytic, gluconeogenic and lipogenic enzymes. Mol Cell Biochem.v:224 pp:45-51.
- [17]Sharma RD, Raghuram TC, Rao NS (1990): Effect of fenugreek seeds on blood glucose and serum lipids in type I diabetes. V:44, pp:301-306.
- [18]Nasroallah M and Kolsum M.(2013): Physiological and pharmaceutical effects of fenugreek (Trigonella foenum-graecum L.) as a multipurpose and valuable medicinal plant. Global J Med Plant Res, 1(2):199-206.

- [19]Shashikala. (1997): Management of non insulin dependent diabetes mellitus by using traditional medicinal plant products. Ph.D. Thesis. Haryana Agricultural University, Hisar, India.
- [20]Khosla P, Gupta D.D. and NagPAL, R.K.(1995): Effect of Trigonella faenum Graecum (fenugreek) on serum lipids in normal and diabetic rats. Ind. J. Pharm.v: 27 pp:89-93.
- [21]Nandini V, S. Devaraj N, Devaraj H. A(2007): fibre cocktail of fenugreek, guar gum and wheat bran reduces oxidative modification of LDL induced by an atherogenic diet in rats. MoleCel Bio294,pp: 145–153.
- [22]Vyas AmitS, Patel NaileshG, Panchal Aashish H, Patel Rameshwar K, Patel Madhabhai M. (2010): Anti-Arthritic And Vascular Protective Effects Of Fenugreek, Boswellia Serrata And Acacia Catechu Alone And In Combinations.Pharma Sci Moni, Vol-1, Issue-2.
- [23]Max B.(1992): The essential pharmacology of herbs and spices Trends. v:13 pp:15 –20.
- 24.الخرعلي, زياد متعب فجة سلطان (2001). دراسة في Datura fastuosal تأثير مستخلص نبات الداتورة بعض انسجة الجسم في الجرذان رسالة ماجستير. كلية التربية.جامعة القادسية.
- 25.الموسوي,احمد محمد (2000). تأثير مستخلصات Artemisia herba- alba في الدودة في الفأر Hymenolepis nana الشريطية القزومه الابيض.رسالة ماجستير.كلية العلوم, جامعة بابل.
- [26]Luna, G. (1968): Manual of histological staining methods of the armed forced institute of pathology. 3<sup>rd</sup>.MCRW hill book Co. NewYork.
- [27]Zaki Z T; Basuony M I and Ibrahim I G (1994): Ecological significance of anatomical and histological structure of some mammalian kidney. Egypt. J. Histol., v:17(1): pp:193–208.
- [28]El-Salkh, A. B.; Zaki, T.; Mohammad, I. & Khidr, H. A. (2008): Anatomical, Histological and Histochemical studies on some organs of true desert rodents in the Egyptian Habitats. The Eyp. J. of Hosp. Med., v:33pp: 578- 306.
- [29]Dellmann, H. D. and Brown, E. M (1987): Text book of Veterinary histology (Urinary System) 3<sup>rd</sup> ed, Lea and Febiger ,philadelphia. PP:264-278.
- [30]Banks, W. J. (1986): Applied Veterinary histological Urinary system 2<sup>nd</sup>ed Williams & Wilkins , Baltimore .London. Los Angeles. Sydney PP:431-445.
- [31]Al-Samawy, E. R. M. (2012): Morphological and Histological study of the kidneys on the Albino rats. Al-Anbar J. Vet. Sci., Vol.: 5 No. (1).
- [32]Junquera, L. C., Carneiro, J. (2005). Basic histology. 11<sup>th</sup> ed. Rio de Janeiro, U.S.A., p.373-390.
- [33]William, J. B. & Linda, M. B. (2000): Color atlas of veterinary histology. 2nd Ed. Lippincott Williams & Wilkins.
- [34]Banks, W. J. (1982): Applied veterinary histology" Urinary system ".Baltimore / London ,U.S.A. PP:424-437.
- [35]Ganong, W. F. (1997):Formation and excretions of Urine In : Review of medical physiology. 18<sup>th</sup> ed .Appleton and langy .PP:699.
- [36]Ajayi, I. E.; Ojo, S. A.; Ayo, J. O. and Ibe, C. S. (2010): Histomorphometric Studies of the Urinary Tubules of the African Grasscutter (*Thryonomys swinderianus*). J. Vet. Anat. Vol.3 No 1, p 17-23.
- [37]LaftaF. AL-atwi. (2010): Clinical evaluation for the diuretic effect of the alcoholic extract of Trigonella faenum-gracum seeds (fenugreek) on rabbits. V: 1,pp:121-116.
- [38]Riyad, M. A; Abdulsalam, S. A., and Mohammed, S. S.(1988): Effect of fenugreek and lupine seeds on the development of experiment diablets in rats. Planta medica. pp:286-290.
- [39]Ghosal, S.; Srivastara, R. S. and Chatterjee, D.C.(1974): Fenugreekin, anew steroidal sapogenin- peptide ester of trigonella foenum groecum.Phytochem.v:13 pp: 2247-51.
- [40]Chinmay U. Kapase1, Subhash L. Bodhankar1, Vishwaraman Mohan2, Prasad A. Thakurdesai. (2013): Therapeutic effects of standardized



fenugreek seed extract on experimental urolithiasis in rats. V:3(09), pp. 029-035.

**41.Laroubi A, Touhami M, Farouk L, Zrara I, Aboufatima R, Benharref A, (2007):** Prophylaxis effect of *Trigonella foenum graecum* L. seeds on renal stone formation in rats. *Phytother Res.*v:21pp:921-

**42.Xue W, Lei J, Li X, Zhang R. (2011):***Trigonella foenum graecum* seed extract protects kidney function and morphology in diabetic rats via its antioxidant activity. *Nutrition Research.*v:31:pp:555-62.