

The pathogenesis of experimental infection by *Staphylococcus aureus* in rabbits

Nawras Kadhum Mahdee AL-Nakeeb

College of Veterinary Medicine, AL-Qadisiya University

Abstract:

The present study was carried out on experimental infected rabbit with *Staphylococcus aureus* to study some aspects of pathogenesis of staphylococcal infection. Twelve rabbit were randomly divided into two equal groups: group1 (treated group) were inoculated subcutaneously with (0.5ml) of bacterial inocula contain (30×10^{10}) CFU and group2 (control). Blood samples were taking to evaluate some of blood parameters include: WBC counts, (LYM., Mon. and GRA.) percentage, Mon.#, GRA.#, RBC counts, HB, PCV, MCV, MCH, MCHC, RDW, PLT counts, MPV, PCT and PDW. Most clinical signs noticed in treated group were: mild fever, depression, decreased appetite, respiratory distress and abscess formation in some cases at site of injection. Also the P.M. lesion included: congestion of internal organs (liver, lung) and signs of pneumonia. Histopathological investigations were carried on liver, lung and bone. The statistical analysis revealed that there were significant increased in WBC count and GRA % ($P < 0.05$) in treated group as compared with control. The MCV, MCH, MCHC and RDW ($P < 0.05$) showed significant differences between groups. The PLT counts and PCT ($P < 0.05$) revealed significant decreased in treated group as compared with control. Other parameters studied did not show significant differences between two groups. Histopathological study revealed that there were: hydropic degeneration, necrosis and occluded of bile sinusoid with bile pigment in the livers of infected animals, in lung: there were edema, hemorrhage and necrosis with thickening of the wall of alveoli and infiltration of inflammatory cells and in bone there were sever necrosis of osteoblast, osteoclast and osteocyte cells in the infected animals.

أمراضية الإصابة التجريبية للمكورات العنقودية الذهبية *Staphylococcus aureus* في الأرانب

نورس كاظم مهدي النقيب

كلية الطب البيطري، جامعة القادسية

الخلاصة:

أجريت هذه التجربة لدراسة بعض جوانب أمراضية الإصابة التجريبية لجراثيم المكورات العنقودية في الأرانب. استخدم اثنا عشر أرنب قسمت عشوائيا إلى مجموعتين متساويتين: المجموعة الأولى

(المجموعة المعاملة) والتي حقنت تحت الجلد ب (0,5مل) من الجراثيم بتركيز ($10^{10} \times 30$) خلية في وحدة السائل والمجموعة الثانية التي تركت بدون حقن واعتبرت كمجموعة سيطرة ، أكثر العلامات السريرية التي لوحظت على المجموعة المعاملة كانت حمى ، قلة شهية ، علامات تنفسية وتكوين خراج في بعض الحالات عند موضع الحقن وكذلك كانت التغيرات الموجودة احتقان الأعضاء الداخلية للحيوانات المقتولة والتي تشمل الكبد والرئة وأيضا ظهور علامات ذات الرئة. أخذت عينات الدم لتقييم بعض معايير الدم والتي تشمل (العد الكلي لكريات الدم البيض، حساب النسب المئوية وأعدادها للخلايا الحبيبية و الخلايا الوحيدة والنسبة المئوية للخلايا اللمفية وكذلك العد الكلي لكريات الدم الحمر، تركيز خضاب الدم، حجم الخلايا المضغوطة، معدل حجم الكرية، معدل خضاب الكرية، معدل تركيز خضاب الكرية، معدل انتشار الكرية، العد الكلي للصفائح الدموية، قياس معدل انتشار الصفائح الدموية، معدل حجم الصفائح الدموية، ومعدل الصفائح الدموية الكبيرة. كذلك دراسة التغيرات النسيجية للكبد والرئة والعظم. اظهر التحليل الإحصائي ارتفاعاً معنوياً ($P < 0.05$) في العد الكلي للكريات البيض والنسبة المئوية للخلايا الحبيبية في المجموعة المعاملة مقارنة مع مجموعة السيطرة وكذلك كان هناك اختلافات معنوية في معدل حجم الكرية ومعدل خضاب الكرية ومعدل تركيز خضاب الكرية ومعدل انتشار الكرية عند مستوى احتمالية ($P < 0.05$) كما لوحظ انخفاضاً معنوياً ($P < 0.05$) في العدد الكلي للصفائح الدموية في المجموعة المعاملة مقارنة مع السيطرة. إما بالنسبة للمعايير الأخرى المدروسة فلم يظهر أي اختلاف معنوي بين المجموعتين. التغيرات النسيجية شملت ظهور التنكس المائي و تآكل ووجود صبغات الصفراء بين الجيوب في أكباد الحيوانات المصابة، في الرئة كانت هناك خرب ونزف وتآكل وتثخن في جدران الاسناخ مع ارتشاح للخلايا الالتهابية. في العظم كان هناك تآكل للخلايا العظمية الهادمة والبانية والخلايا العظمية للحيوانات المصابة.

Introduction:

Staphylococcus aureus is an extremely flexible organism: it can be commensal but also dangerous pathogen, causing skin abscesses, wound infections, endocarditis, osteomyelitis, pneumonia, and toxic shock syndrome, bacteremia and septic arthritis (1,2).

The organism an important opportunistic gram-positive human pathogen ,is the most common organism isolated from soft-tissue and wound infections (3). And responsible for many human diseases including food poisoning, soft-tissue infections, pneumonia, and osteomyelitis: *S.aureus* can asymptotically colonize human skin and mucous membrane including the lid and conjunctiva of eye (4). Staphylococcal septicemia

of the newborn especially lambs. This is relatively common disease and may a significant mortality rate, partly due to a high incidence of myocardial lesion. In the most cases the navel appears to be the portal of infection but infection may also occur through marking wounds (5).

After inoculation, the organism can spread hematogenously or via local extension resulting in pyoderma and purulent mastitis, internal abscessation, septicemia and purulent bronchopneumonia: pod dermatitis or "sore hock" may occur in association with abscesses or mastitis (6). The organism expresses several factors that compromise the effectiveness of neutrophils and macrophages, the first line of defense against infection. *S.aureus*

secretes proteins that inhibit complement activation and neutrophil chemotaxis or that lyses neutrophils, neutralize antimicrobial defenses peptide and its cell surface is modified to reduce their effectiveness. The organism can survive in phagosomes, express polysaccharides and proteins that inhibit opsonization by antibody and complement and its cell wall is resistant to lysozyme (7). This study was designed to investigate some aspects of pathogenesis of *Staph.aureus* in rabbit which include: clinical signs, P.M. lesion, changes in blood parameters and Histopathological studies in some organs like: liver, lung and bone.

Materials and methods:

Experimental animals:

Twelve local domestic rabbits of (2-2.5) Kg. in weight were housed in the same environmental condition obtained from Diwaniya city for pathological test.

Bacterial strain:

Prepared from *Staph.aureus* from microbiological lab. of veterinary college of Al- Qadisiya university .Over night (18 hours) cultures of bacterial inoculate were prepared by inoculating a single colony from brain heart infusion agar plate into ten milliliters of trypticase soy broth (HIMDIA) . Cultures were centrifuged for 10 min. at 3000 rpm and then decanted.

The bacterial sediment was resuspended in a volume of sterile normal saline equal to the discarded

supernatant .Serial tenfold dilution in normal saline were made from each inoculums .Bacteria were counted by incubating 0.1ml portions on nutrient agar then incubated for 24hours and the number of colonies were recorded as previously described in(8).

A measured volume of resuspended cells, which regularly contain dose (30×10^{10}) CFU was used for this experiment according to (9).

Experimental protocol:

The experimental animals kept in the same condition for 2weeks for adaptation, after that divided randomly into two groups (each group contain 6 animals): group (1) (control group) were kept without inoculation. The second group(treated group) were inoculated subcutaneously with (0.5ml) of bacterial inocula; the treated group also subdivided according to time of blood aspiration into : group(2) in day(0), group(3) in day(15) and group(4) in day(30).

The experiment lasting for 30day, with daily investigation of clinical signs, in the end of the experiment the animals were sacrificed for checking gross lesion and taking histological specimens for Histopathological examination.

The blood samples:

The blood samples(3ml) with anticoagulant were taking in (0,15,30) day to evaluate some blood parameters include(WBC counts, lymphocytes, granulocytes, monocytes (count and percentage) ,RBC counts ,PLT counts,Hb concentration , PCV, RBC indices (MCV,MCH,

MCHC, RDW (RBC distribution width) , PDW(platelet distribution width) , MPV (mean platelet volume)used automated hematology : ABX Micros ES60 (HoRIBA medical, FRENCH).

Histopathological examination:

Organs include (liver,lung,heart) and (aspiration of bone marrow from bone by syringe)all of them were fixed in 10% buffered formalin and using routine methods and section of 5 micro meter thickness were cut and stained with hematoxylin and eosin(10,11)

Statistical analysis:

Was done using SPSS (version17); the data were analyzed statistically using one way ANOVA with LSD to establish significant differences among groups.

Results:

The clinical signs noticed were: depression, decrease in appetite, mild fever, respiratory signs, in some cases (2 rabbits) abscesses palpated at the site of injection. The p.m. lesion in experimental infected animals: congestion in the liver and lung and signs of pneumonia were observed in the examined cases, while, no signs observed in control group. The statistical analysis revealed that there was significant increase in WBC counts ($P<0.05$) between (3, 4) groups (treated) and control group (1), and between group (2) with group (4) while no significant differences between (3and 4) groups. GRA% there was significant differences between

group (3) with control groups (1 and 2) while no significant differences between group (4) with others groups. GRA# and MON% there were significant differences between (3 and 4) treated groups with (1 and2) control groups while no significance between (3) and (4). Also there were no significant differences in treated group compared with control in LYM% and MON# (Table 1). MCV was revealed significant increased between (3, 4) treated group with control while non significant differences between (3 and 4) treated group. Also MCH revealed significant differences ($P<0.05$) between group (3) and group (1) control also between (3) and (4) groups but no significant between group (2) with other groups. MCHC was revealed significant differences ($P<0.05$) between treated group (4) with other groups. RDW there was significant differences ($P<0.05$) between (3 and 4) treated group with control groups but no significance between (3 and 4) treated group while the RBC, HB and PCV revealed no significant differences in infected animals compared with control (Table 2). The PLT was revealed significant decreased ($P<0.05$) between (3,4) treated group and control groups and significant differences between (2 and 3) groups but no significant differences between(3 and 4)and (4)treated group with (2 and 3) groups. PCT was revealed significant decreased ($P<0.05$) between (3,4) treated

groups compared with control but no significant differences between (3 and 4) treated group while MPV and PDW were revealed no significant differences in treated compared with control groups (Table 3). Histopathological study revealed in the liver there was hydropic degeneration with feathering cytoplasm, necrosis and occluded of bile sinusoid with bile pigment in the

infected animals. (figure1). In lung there was edema, hemorrhage and necrosis (figure4) with thickening of the wall of alveoli, presence of interstitial exudates, infiltration of inflammatory cells and hemorrhage (figure5). In the bone there was severe necrosis of bone tissue with absence of osteoblast, osteoclast and osteocyte cells (figure8).

 **Table (1)**

	Group(1)control (0)day	Group(2)treated (0)day	Group(3)treated (15)day	Group(4)treated (30)day
WBC	5.91±0.24 a	6.38±0.66 a	8.71±0.57 ab	9.51±1.30 b
LYM%	54.50±3.50 a	55.56±3.20 a	49.78±3.38 a	56.36±7.70 a
MON%	17.18±3.05 a	18.83±1.96 a	9.60±1.08 b	10.11±1.23 b
GRA%	28.31±1.72 a	25.60±1.60 a	40.61±2.54 b	33.51±6.78 ab
MON#	0.95±0.18 a	1.08±0.04 a	0.76±0.06 a	0.90±0.18 a
GRA#	1.81±0.12 a	1.71±0.13 a	3.60±0.21 b	3.63±0.83 b

Values represented Mean±SE

The different letters (a & b) referred to significant differences at level (P<0.05) between groups

Similarity letters (a & b) represent no significant differences at level (P<0.05) between groups

(ab) united letters represented significant & non significant differences at level (P<0.05) between groups

 **Table (2)**

	Group(1)control (0)day	Group(2)treated (0)day	Group(3)treated (15)day	Group(4)treated (30)day
RBC	5.38±0.19 a	5.33±0.09 a	5.25±0.19 a	4.93±0.22 a
HB	10.48±0.38 a	10.61±0.20 a	10.70±0.41 a	9.78±0.40 a
PCV	34.18±1.42 a	34.61±0.68 a	35.13±1.48 a	33.10±1.43 a
MCV	63.50±0.50 a	64.83±0.54 a	66.66±0.49 b	67.16±0.30 b
MCH	19.46±0.18 a	19.88±0.19 ab	20.33±0.13 ab	19.80±0.11 a
MCHC	30.68±0.27 a	30.61±0.07 a	30.48±0.16 a	29.51±0.15 b
RDW	15.30±0.31 a	15.53±0.26 a	13.91±0.24 b	14.08±0.19 b

Values represented Mean±SE

The different letters (a, b & ab) referred to significant differences at level ($P < 0.05$) between groups

Similarity letters (a, b) represent no significant differences at level ($P < 0.05$) between groups

(ab) united letters represented significant & non significant differences at level ($P < 0.05$) between groups

 **Table (3)**

	PLT	MPV	PCT	PDW
Group(1)control (0)day	518.50 \pm 62.52 a	5.08 \pm 0.13 a	0.25 \pm 0.02 a	9.11 \pm 0.39 a
Group(2)treated (0)day	479.50 \pm 37.74 a	5.20 \pm 0.12 a	0.24 \pm 0.01 a	9.38 \pm 0.25 a
Group(3)treated (15)day	278.16 \pm 40.79 b	5.26 \pm 0.03 a	0.14 \pm 0.02 b	9.26 \pm 0.53 a
Group(4)treated (30)day	331.00 \pm 55.70 ab	5.18 \pm 0.27 a	0.16 \pm 0.02 b	9.16 \pm 0.77 a

Values represented Mean \pm SE

The different letters (a, b & ab) referred to significant differences at level ($P < 0.05$) between groups

Similarity letters (a, b) represent no significant differences at level ($P < 0.05$) between groups

(ab) united letters represented significant & non significant differences at level ($P < 0.05$) between groups

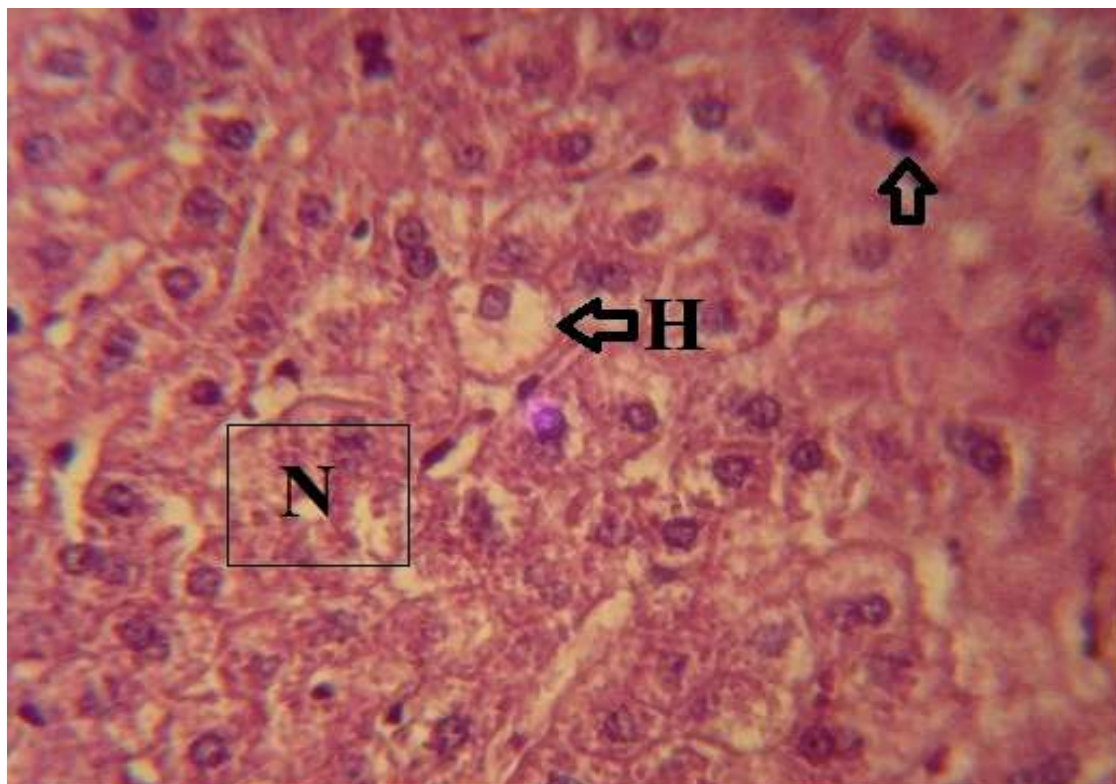
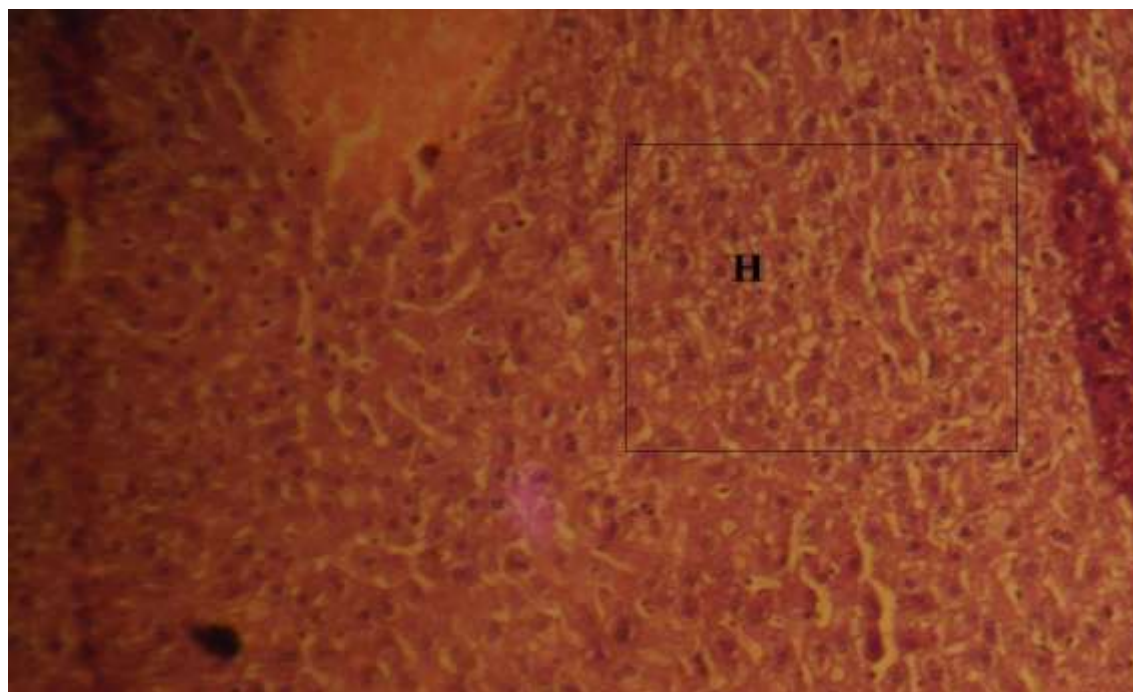


Figure (1): liver, there are hydropic degeneration (H) with feathering cytoplasm, necrosis (N) and occluded of bile sinusoid with bile pigment (arrow). H&E, 400X.



Figure(2): liver, there are hydropic degeneration(H). H&E, 100X

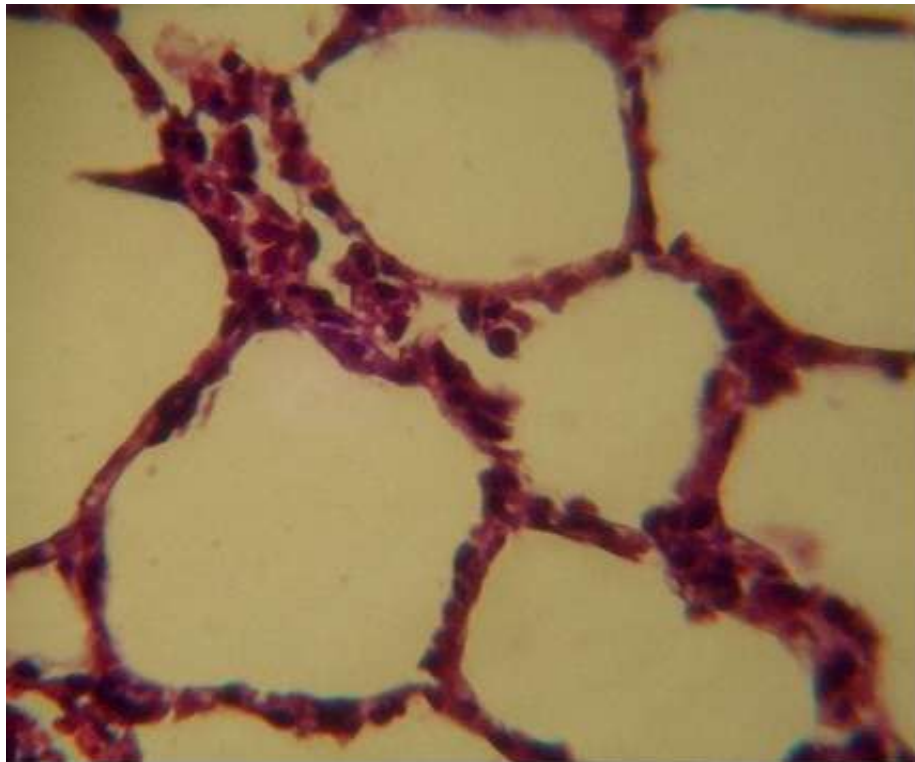
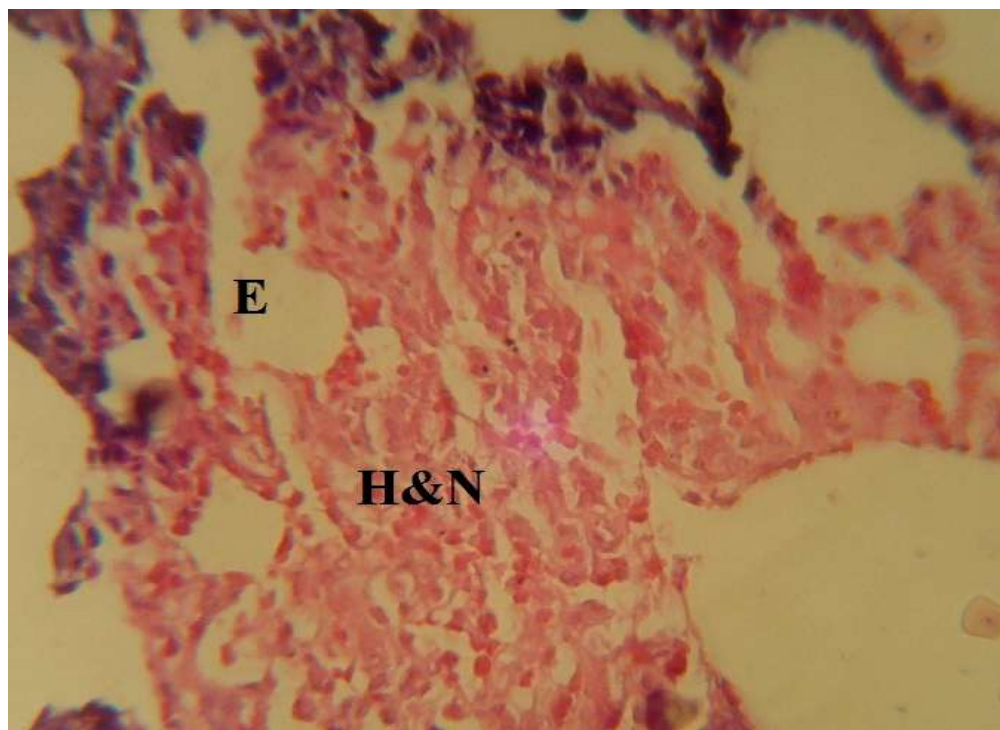
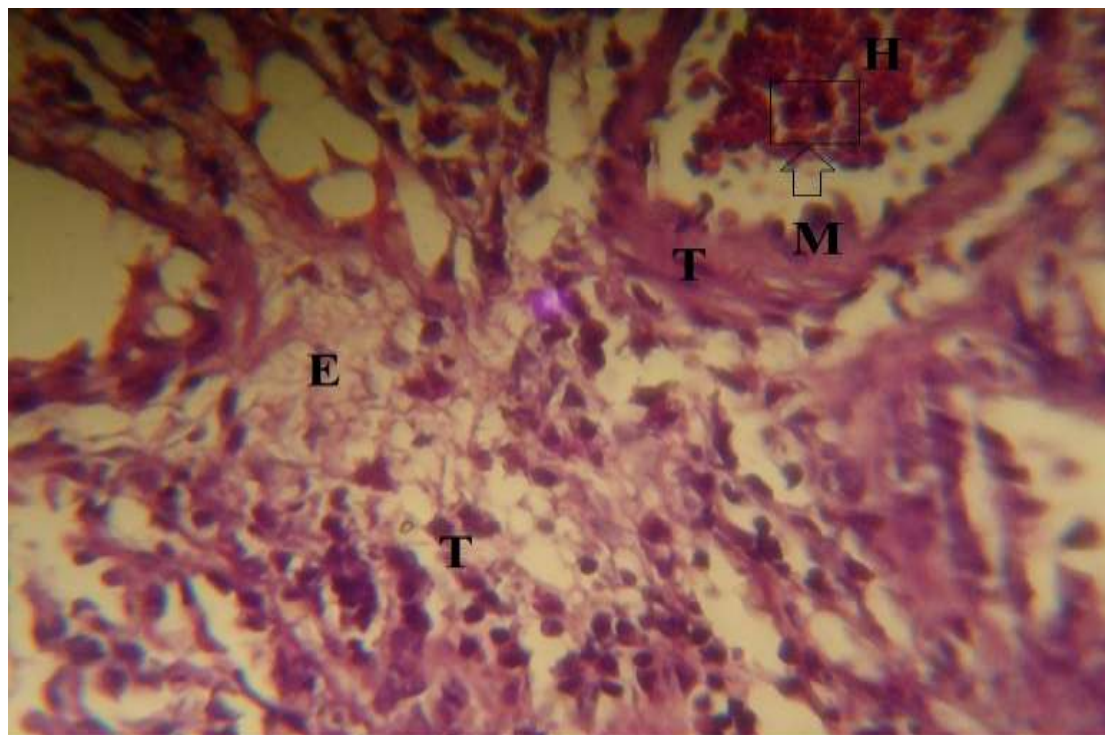


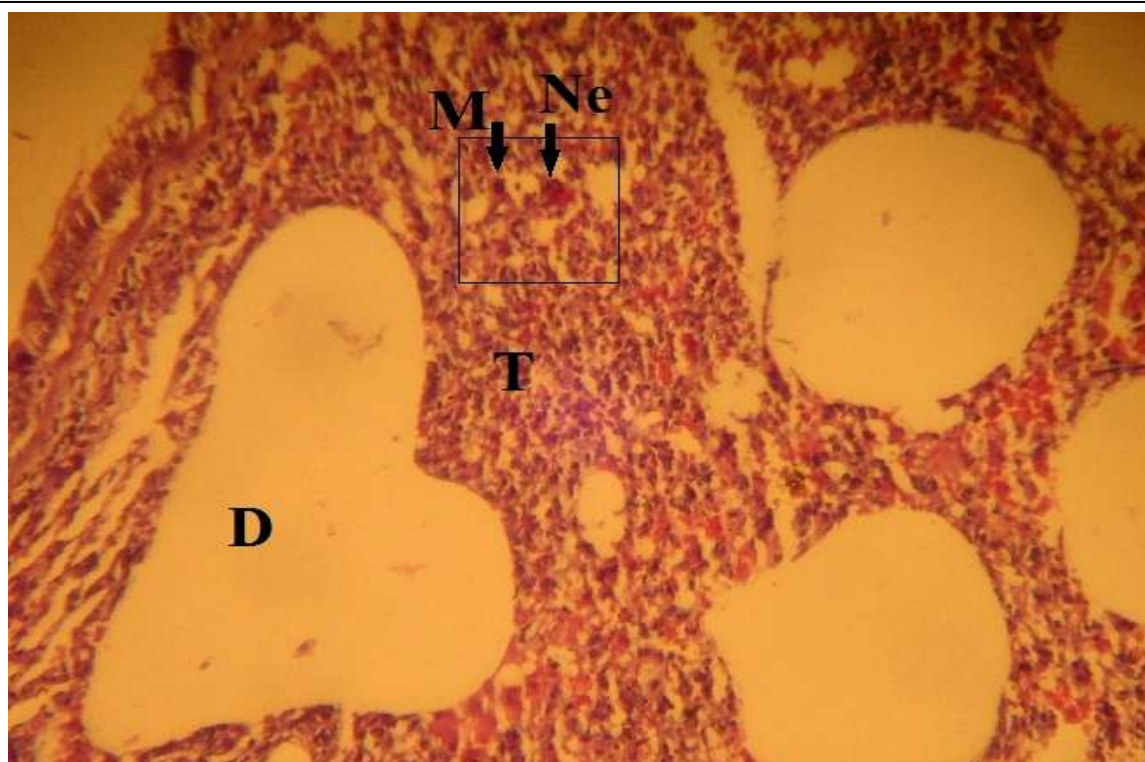
Figure (3): Normal Lung tissue



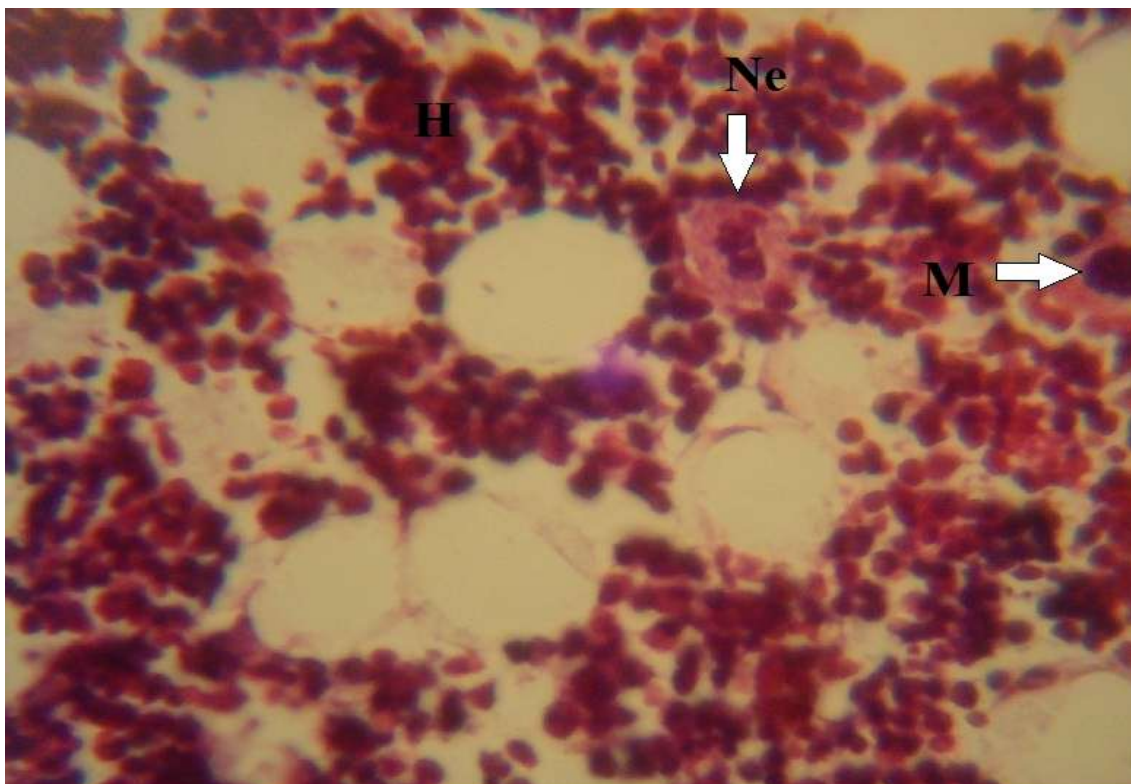
Figure(4): lung, there are edema(E), hemorrhage and necrosis(H&N). H&E, 100X.



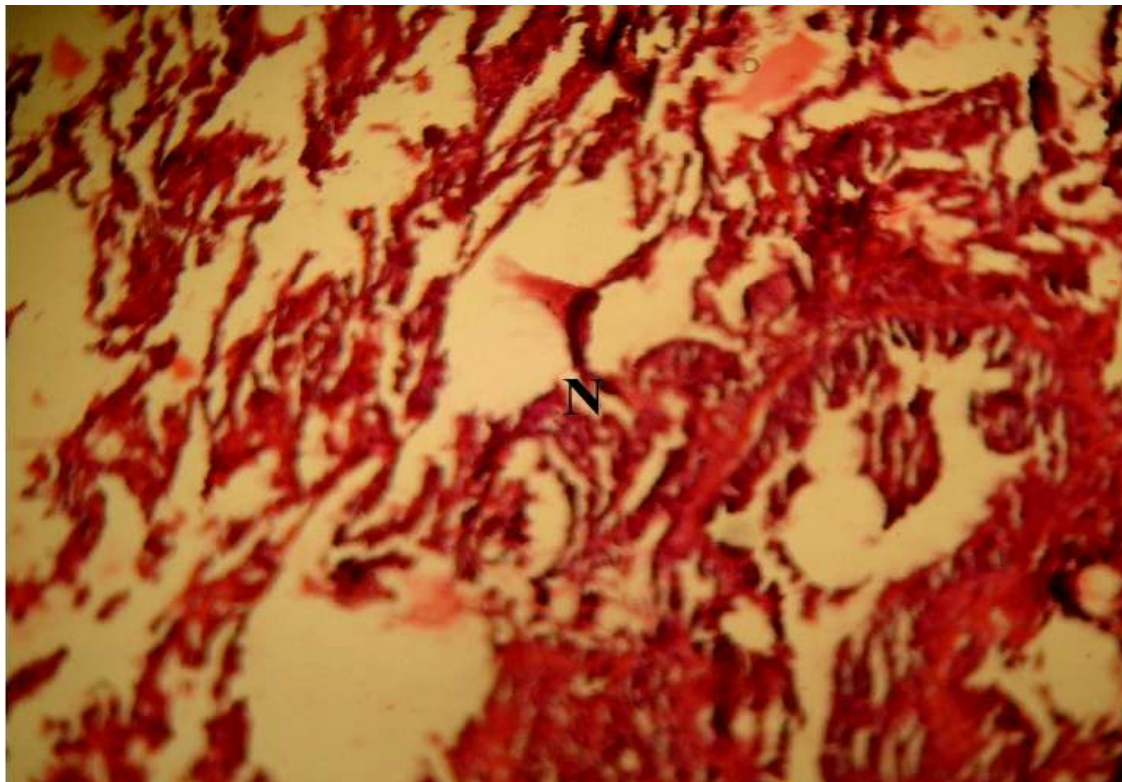
Figure(5): lung, there are thickening in the wall of alveoli(T), presence of interstitial exudate (E) , infiltration of inflammatory cells(M) and hemorrhage(H). H&E. 100X.



Figure(6): lung, there are dilatation of alveoli(D), thickening of alveolar wall(T) and infiltration of inflammatory cells {macrophage(M) and neutrophil(Ne)}. H&E. 100X.



Figure(7): lung, there are congestion (H) and infiltration of neutrophil(Ne) and macrophage(M) in the interstitial tissues. H&E , 400X.



Figure(8): Bone, there are severe necrosis of bone tissue(N) with absence of osteoblast, osteoclast and osteocyte cells. H&E, 100X

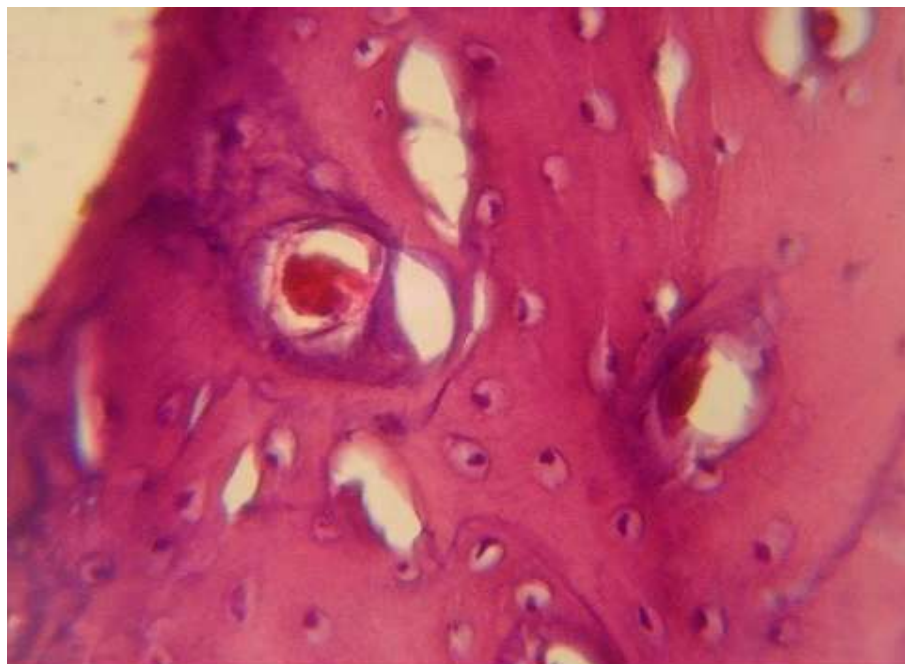


Figure (9): **Normal Bone Tissue**

Discussion:

Staphylococcus aureus can cause superficial skin infection, occasionally, deep seated infection that entails spread through the blood stream such as septic arthritis, osteomyelitis,(7)and pneumonia (2). In the present study, most obvious signs like depression, mild fever, respiratory signs and abscess formation with p.m. lesion: congestion of liver and lung and pneumonia, similar clinical and P.M. lesion have been recorded by many researchers(9,6,12,13,14and15). The organism expresses several factors that compromise the effectiveness of neutrophils and macrophages the first line of defense against infection. *Staph.aureus* secretes proteins that inhibit complement activation and neutrophils chemotaxis or that lyses neutrophils, neutralizes antimicrobial

defension peptides, and its cell surface is modified to reduce their effectiveness. The organism can survive in phagosomes, express polysaccharides and proteins that inhibit opsonization by antibody and complement, and it's cell resistant to lysozyme. Furthermore, *Staph.aureus* expresses several types of super antigen that corrupt the normal humoral immune response, resulting in anergy and immunosuppression. (7).the result revealed significant increased in WBC counts between infected and control groups. Similarly, (16) reported *Staph.aureus* infection lead to leucocytosis and (17) showed to significant increase in WBC in infected animals. This significant change in numbers of cells due to inflammatory process in animal's

body. During infectious process we were able to see significant increase of circulatory polymorphonuclear granulocyte, a prerequisite for efficient homing to the site of inflammation (18), while these changes in numbers in both groups regard the normal range of leukocytes, similarly (19) showed the infection with *Staph.* resulted fever, neutrophilia and lymphopenia but no significant increase in total WBC count and this change in numbers in the experiment contain normal value in both groups compared with normal value in the same references'. The platelet was revealed significant decreased between infected and control groups and this agreed with (20) which showed the several studies performed in vitro on the interaction of platelets with *Staph.aureus* indicated that the bacteria induce the platelet-release reaction and rapid irreversible platelet aggregation in the presence of normal plasma, α -toxin the major cytolysin of *Staph.aureus*, promotes blood coagulation by its effect on human platelets. Thus, infectious thrombocytopenia are secondary to multiple and combined mechanism. After inoculation the organism can spread hematogenously or via local extension resulting in pyoderma, internal abscessation, septicemia and purulent bronchopneumonia (6). Histopathological changes in the livers agree with (15) that referred to moderate to severe periportal inflammation with infiltration of

leukocytes. (6) Also showed presence of focal suppurative necrotizing lesion in the infected organs. Histopathological changes in lungs also agree with (15, 21 and 12) and (12) concluded that bronchopulmonary secretion from rats and rabbit don't have bactericidal against *Staph.aureus*. (17) showed that *Staph.aureus* is characterized by their high affinity to bone, their rapid induction of osteonecrosis and resorption of bone matrix.

Reference

- (1) Capparelli, R.; Paralato, M.; Borriello, G.; Salvatore, P. and Iannelli, D. (2007). Experimental phage therapy against *Staphylococcus aureus* in mice. Antimicrobial agents and chemotherapy. Vol.51, No.8, P.2765-2773.
- (2) Greenberg, D.P.; Bayer, A.S.; Cheung, A.L. and Word, J.I.(1989). Protective efficacy of protein A-specific antibody against bacteremic infection due to *Staphylococcus aureus* in an infant rat model. Infection and immunity. Vol.57, No.4, P.1113-1118.
- (3) Bengston, S.H; Phagoo, S.B.; Teglund, A.N.; Pahlman, L.; Morgelin, M.; Zuraw, B.L.; Lundberg, F.L.M. and Herwald, H.(2006). Kinin receptor expression during *Staphylococcus aureus* infection. Blood Journal. Doi: 10.1182/Blood-2006-04-016444.

- (4) Balzli, Ch.L; Bartell, J.; Dajcs, J.J.; McCormick, C.C.; Caballero, A.R.; Stroman, D. and O'Callaghan, R.J. (2010). A highly virulent *Staphylococcus aureus*: rabbit anterior chamber infection, characterization and genetic analysis. IOVS. Manuscript ivos.10-5179.
- (5) Radostits, O.M.; Gay, C.C.; Hinchcliff, K.W. and Contable, P.P. (2006). Textbook of veterinary medicine. 10th ed. Elsevier. Edinburgh, London. P 793.
- (6) Wilbar, J.L. (1999). Pathology of rabbit. Armed forces institute of pathology. Washington, D.C.
- (7) Foster, T.J. (2005). Immune evasion by *Staphylococci*. Doi: 10.1038/nrmicro11289. Vol.3.
- (8) Tortora, G.J; Funke, B.R. and Case, C.L. (2004). Microbiology: An introduction. 8th (ed.) Pearson (Benjamin Cummings) pp: 170- 180.
- (9) Abdel-Gwad, A.M.; Abdel-Rahman, A.A. and Ali. M.M. (2004). Significance of *Staphylococcus aureus* in rabbits in Assiut governorate. Ass. Univ. Bull. Environ. Res., Vol.7. No.1.
- (10) Luna, L.G. (1968). Manual of histologic staining methods of the armed forces institute of pathology, 3rd ed., McGraw-Hill Book Company. New York, Toronto, London. PP: 1-38.
- (11) Chauhan, R.S. (2004): Veterinary laboratory diagnosis, 1st ed, International book distributing Co., Lucknow. pp: 269-285.
- (12) Demaria, T.F. and Kapral, F.A. (1978). Pulmonary infection of mice with *Staphylococcus aureus*. Infection and immunity. Vol.21, No.1, P.114-123. U.S.A.
- (13) Lipinska, U.; Hermans, K.; Meulemans, L.; Dumitrescu, O.; Badiou, C.; Duchateau, L.; Haesebruck, F.; Etienne, J. and Lina, G. (2011). Panton-Valentine leukocidin does play a role in the early stage of *Staphylococcus aureus* skin infection: A rabbit model. Plos one 6(8): e22864, doi: 10.1371/journal. Pone.0022864.
- (14) Parsonnet, J.; Gillis, Z.A.; Richter, A.G. and Pier, G.B. (1987). A rabbit model of toxic shock syndrome that uses a constant, subcutaneous infusion of toxic shock syndrome toxin 1. Infection and immunity. Vol.55, No.5. P.1070-1076.
- (15) Rasheed, J.K; Arko, R.J.; Feeley, J.C.; Chandler, F.W.; Thornsberry, C.; Gibson, R.J.; Cohen, M.L.; Jeffries, C.D. and Broome, C.V. (1984). Acquired ability of *Staphylococcus aureus* to produce toxic shock-associated protein and resulting illness in rabbit model. Infection and immunity. Vol.47, No.3, p.598-604.

(16) Sakiniene, E.; Bremell, T. and Tarkowski, A. (1999). Complement depletion aggravates *Staphylococcus aureus* septicemia and septic arthritis. Clin. Exp. Immunol., 115(1): 95-102.

(17) Lucke, M.; Schmidmaier, G.; Sadoni, S.; Wildemann, B.; Schiller, R.; Stemberger, A.; Haas, N.P. and Raschke, M. (2003). A new model of implant- related osteomyelitis in rats. J.biomed mater Res Part B. Appl Biomater 67B:593-602.

(18) Molne, L. and Tarkowski, A. (2000). Experimental model of cutaneous infection induced by super antigen- producing *Staphylococcus aureus*. Journal of dermatology. 114, 1120-1125.

(19) Harcourt-Brown, N.H. (2002). Textbook of rabbit medicine (ed). Alden press, Oxford, Britain.

(20) Youssefian, T.; Drouin, A.; Masse, J.M.; Guichard, J. and Cramer, E.M. (2002). Host defense role of platelets: engulfment of HIV and *Staphylococcus aureus* occurs in a specific sub cellular compartment and is enhanced by platelet activation. Blood journal. Vol.99. No.11:4021-4029.

(21) Ulrich, R.G.; Wilhelmsen, C.L. and Krakauer, T. (2006). Staphylococcal enterotoxin B and related-toxin. Chapter 14. Medical aspects of biological warfare. PP. 311-322.