

## Potential Nephroprotective Effect of Curcumin against Gentamicin Induced Nephrotoxicity : An Experimental Study In Rats

Sahar A. Majeed\*, Karar K. Alhydari\*, Bassim I. Mohammad<sup>#</sup>

\*Kufa University /Faculty of Medicine/Department of pharmacology and therapeutics  
.Dr\_alhar@yahoo.com

<sup>#</sup>The University of Al Qadisiyah, Faculty of Pharmacy / Iraq

### Abstract

**Background:** Nephrotoxicity is a serious & common side effect of aminoglycoside and is induced by generation of reactive oxygen species. Emerging evidence reveals that curcumin possesses antioxidant activity, therefore, this research was undertaken to evaluate the potential protective effects of curcumin in amelioration of nephrotoxicity induced by gentamicin in male rats.

### Materials and Methods:

Eighteen male Sprague-Dawley rats were included in this study. They were divided randomly into three equal groups (six rats each). Groups I (Control) received only normal saline i.p, Groups II (GN) received gentamicin (100 mg/kg/day), Group III (GN+CUR) received a combination treatment gentamicin (100 mg/kg/day, i.p) & curcumin (200 mg/kg/day p.o). The duration of treatment was eight days and at the end of the study, animals were sacrificed and the blood sample was collected for assessment of renal function, blood urea & serum creatinine. Both kidneys were removed and prepared for a histopathology examination.

**Results:** blood urea and creatinine were significantly higher ( $P < .05$ ) in gentamicin treated group (group II) as compared to the control group (group I). However, the levels of these parameters in group 3 (co-treatment of gentamicin and curcumin) were significantly lower than those in group 2 ( $P < .05$ ). Further, the histological score of renal damage was higher in the gentamicin group than in the control group. Combination treatment of curcumin and gentamicin (group III) significantly attenuated the histopathological damage.

**Conclusion:** Curcumin attenuated gentamicin-induced renal injury in rats' models.

**Keywords:** gentamicin, nephrotoxicity, curcumin, antioxidant

### Introduction

The kidney is a very important body part in disease and health. Many environmental contaminants and chemical substances, including some drugs, affect the function of the kidneys (1) the most common cause of acute kidney injury is drug-induced nephrotoxicity, characterized by an elevated in urea levels and serum creatinine and mild to severe damage mainly to the proximal renal tubular cells. It occurs in 10–25% of patients treated gentamicin at acceptable doses. there different mechanisms by which gentamicin can induce nephrotoxicity. The phenotypic alterations that respond to acute kidney injury include apoptosis and renal tubular epithelial cells necrosis hemodynamic changes, oxidative stress, and inflammatory response (2)

Gentamicin is an antibiotic belonging to protein synthesis inhibitor aminoglycoside antibiotic used in the treatment of bacterial infection (mainly Gram-negative). Intake of it can precipitate severe nephrotoxicity (3), gentamicin becomes a famous substance used to induce nephrotoxicity in researches. Thus, a therapeutic approach to reverse and protect kidney injury induced by aminoglycoside would have

significant clinical importance. Rats treated with gentamicin have been shown to exhibit increased infiltration of macrophage, which was associated with increases in endothelin, and angiotensin II levels, transforming growth factor (TGF)-  $\beta$ , which is responsible for tubule interstitial nephritis progression. Many other factors are found to play a role in the pathogenesis of nephrotoxicity Induced by gentamicin either indirectly or by direct toxicity or; these include decrease phospholipase activity, resulting in lysosomal phospholipidosis and oxidative stress (3). Many studies have found that infiltration of inflammatory cells is the major cause of tubulointerstitial nephritis and fibrosis in an experimental study. In fact, virtually every all kidney cells are able to produce chemokines (pro-inflammatory) after tissue injury like leukocyte adhesion molecules, such as monocyte chemoattractant peptide (MCP)-1 and intercellular adhesion molecule(ICAM)-1, Tubular cell expression of ICAM-1 enhances inflammatory cells migration recruitment to the site of damaged tissue mainly (macrophages and monocytes ). Apoptosis has also been found in rats N-terminal kinase (JNK) and plays an important role in the signaling pathway of apoptosis.TGF-  $\beta$ 1 has also been implicated in apoptosis associated with glomerulonephritis, and may activate the apoptotic signaling pathway in proximal tubules after administration of aminoglycoside. (4)

Curcumin is the yellow pigment that occurring naturally isolated from the rhizomes of the plant *Curcuma longa*, it has anti-inflammatory, anti-tumor, and antioxidant effects. At the cellular and molecular levels, these pleiotropic effects of curcumin are mediated by up-regulation of defense proteins; such as reduced glutathione, heme oxygenase-1 (HO) and, free-radical scavenging, and inhibition of pro-apoptotic/pro-inflammatory cytokines/transcription factors; like NF- $\kappa$ B and TNF- $\alpha$  and. The hypoglycemic effect of curcumin has been studied in animals (5).

Curcumin is absorbed well and has low toxicity. It has various beneficial activities in the body and is effective on a different type of diseases including coryza, sinusitis, cough, diseases of the liver, and anorexia. New researches give scientific evidence regarding the potential pharmacological therapeutic or prophylactic Curcumin use, as anti-infectious, antifungal, antiviral, antiparasitic, anti-inflammatory, anti-carcinogenic. antimutagenic, antihepatotoxic and antioxidant compound. Curcumin also found to be helpful in inhibiting oxidative stress induced by diabetes in rats (6). Curcumin has a role in the neurogenesis process which in turn has possesses neuroprotective effects in age-related neurodegenerative diseases Curcumin has anticonvulsant and antioxidant effects and also protect against oxidative damage and show powerful oxygen free radical scavenging effects and elevate the level of glutathione intracellularly thereby preventing peroxidation of lipid (7). Commercial Curcumin contains 77% curcumin, 17% dimethoxy curcumin, and 3% bisdemethoxy curcumin all these three components in Curcumin have protective properties and active biologically (8)

## Materials and methods

### Animals

In this study, we used 18 white adult male rats Sprague Dawley rats, 4–6 weeks of age and 250–350 g in body weight. Animals were kept in the animal house of College of Medicine, Kufa University, Iraq at an ambient temperature of 25C and 45–55% relative humidity with a twelve hrs dark – light schedule cycle. They allowed free access to food pellets and water intake. The animals were divided into 3 groups randomly.

Group I. was the control group (six rats)

Group II. Was given gentamicin 100mg i.p for 8days(six rats)

Group III. Was given 200mg of curcumin (p.o) 200mg along with gentamicin daily for 8 days. (six rats)

The Institutional Animal Use and Care Committee approved the experimental protocol.

At the end of the study, all rats were sacrificed, blood samples were collected directly from the heart for measurement of renal function, blood urea, and serum creatinine. Both kidneys were removed and longitudinal sections were excised from each animal for histological analysis.

### Drugs

Gentamicin (ZENTIVA CO.) ampules (80mg/2ml) were purchased from a local pharmacy and given according to the body weight in a dose of 100 mg/kg /day i.p. Curcumin was purchased from (Sigma Aldrich CO.). The curcumin powder was dissolved in distilled water & given to animal orally by gavage in a dose of 200mg/kg/day. Normal saline, 500ml bottle (BIONEER CO.), was purchased from a local pharmacy and given to the animal intraperitoneally in a volume equivalent to the gentamicin injection.

### Biochemical parameters

At the end of the experiment, the animals in the control & the two treatment groups were sacrificed. 5 ml of blood was collected from the heart by cardiac puncture using a disposable syringe. Then, the samples were left to clot and centrifuged at 3000rpm for 15 minutes to obtain the serum, which is utilized for the assessment of renal function, urea and blood serum creatinine. by kit purchased from SIGMA ALDRICH.

### Histological Examination.

Sections from a renal specimen from all three group and To avoid heterogeneity, five sections were obtained from each animal and these sections were subjected to semi quantitative analysis by using light microscopy. The renal histopathological alteration was divided into normal (zero change), mild Scores + show show less than 25% histopathological alteration , moderate score ++ show 50%, and severe score +++ show 75%. Histopathological alteration of total fields examined, (9) Histological sections were examined and scored by histopathologist who doesn't know the treatment protocol.

### Statistical Analysis.

The data are expressed as means  $\pm$ SEM from six rats in each group. the nephroprotective activity was analyzed Statistically using SPSS.with p value< 0.05 being considered as statistically significant.

### Results

#### Effects of gentamicin on renal functions & renal histopathology

Gentamicin treated group had a significant increase (P value <0.05) in blood urea and creatinine as compared to the control group. as shown in table 1and figure 1A, B, histopathological examination revealed severe renal structural changes in gentamicin treated group. Renal histopathology of Gentamicin treated group (II) revealed tubular

alteration in form of necrosis, degeneration, and vacuolization (1) which affect mainly proximal convoluted tubules(PCT) and the distal tubules(DCT) to a lesser extent. Diffuse and Massive necrosis of the cell was observed in the PCT. In addition, the lumens of PCT were occupied with hyaline casts, desquamated and degenerate epithelial cells and Severe inflammatory cell infiltrate mainly monocyte were found in the renal sections of the gentamycin treated group(II) as shown in figure 2B.

Administration of Curcumin was able to return histopathological damage that induced by gentamicin these changes observed in figure 2C.

**Table 1 shows the effect of gentamycin 100mg/kg IP group (II) administration alone and gentamycin+ curcumin 200mg/kg PO group (III) on blood urea and serum creatinine .the data expressed as mean  $\pm$ SEM**

parameter	Group I	groupII	Group III
Blood urea mg/dl	47.4 $\pm$ 2.61	90.6 $\pm$ 7.27*	60.3 $\pm$ 2.81#
Serumcreatinine mg/dl	0.44 $\pm$ 0.05	1.04 $\pm$ 0.06*	0.63 $\pm$ 0.06#

P value <0.05.

\*significant as compared with the control group(group I)

#significant as compared with gentamycin treated group (group II)

### **Curcumin effect on renal functions and histopathology**

Serum level of creatinine and urea were assessed as markers of renal functions. In comparison to gentamicin (Group II) group, adding curcumin treatment to gentamicin –intoxicated rats (group III) improved renal function as evidenced by significant ( $p < 0.05$ ) reduction in serum levels creatinine and urea as in figure 1A&B. Addition of curcumin to gentamicin was able to attenuate the progression of histological damage and to restore gentamicin-induced histopathological structural changes as shown in figure 2C.

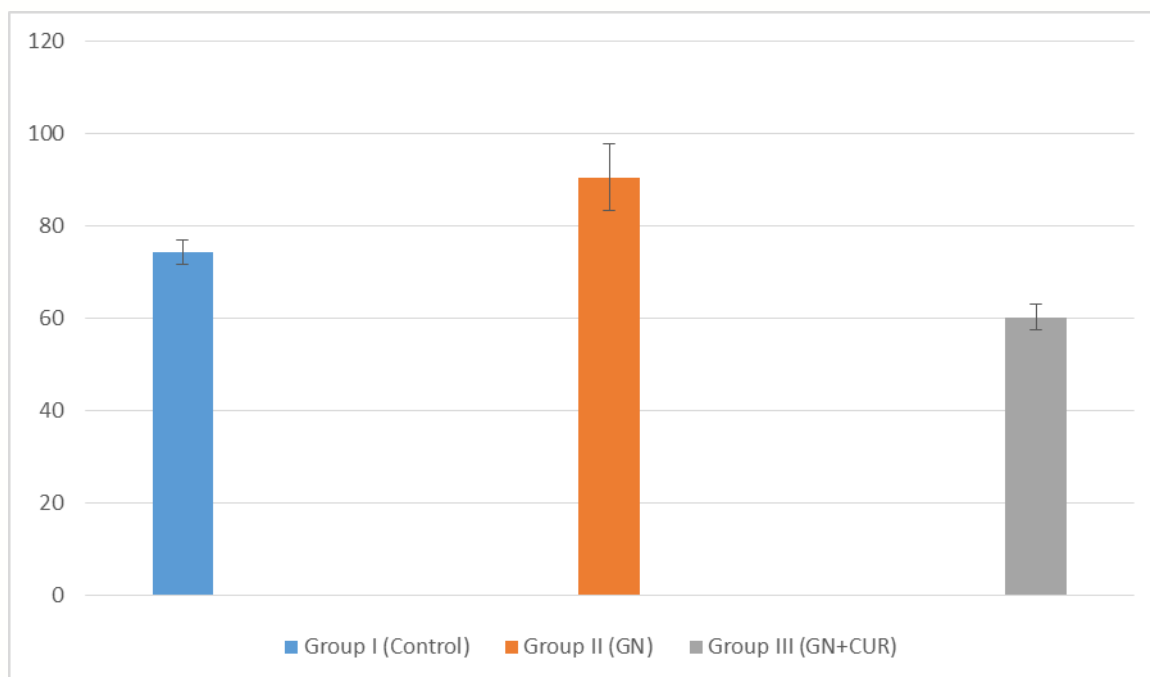


Figure 1A shows the effect of oral curcumin on blood urea in mg/100ml in male rats with gentamycin induced nephrotoxicity expressed by mean+SEM.  
P value<0.05

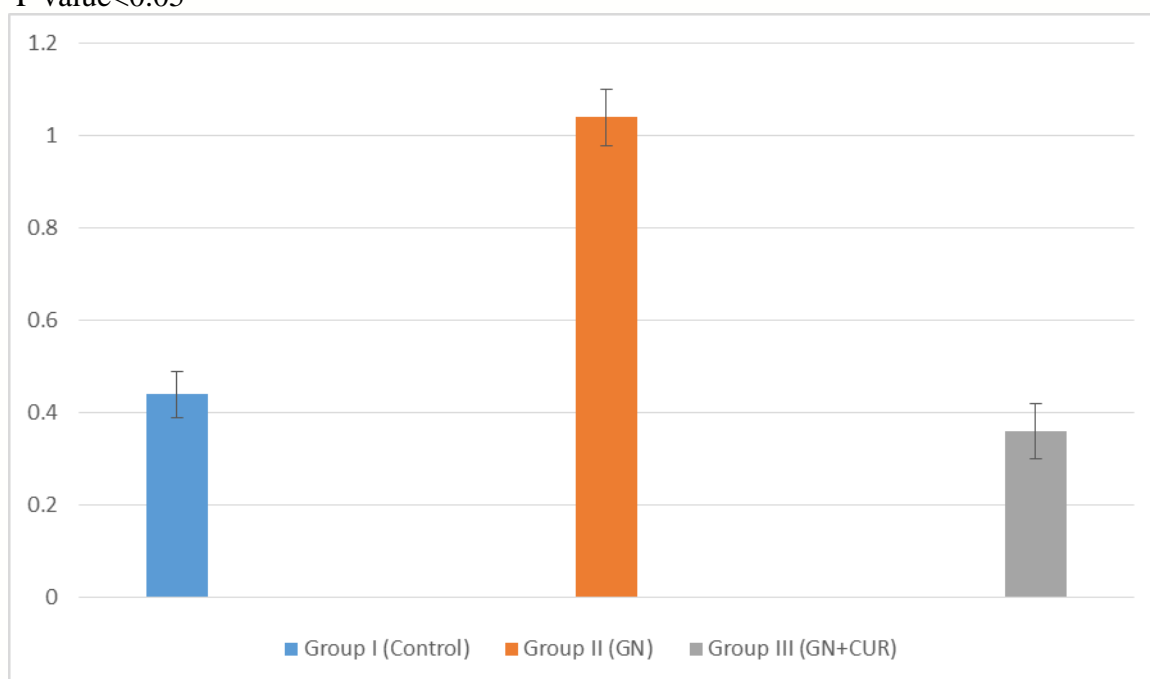


Figure 1B show the effect of oral curcumin on serum creatinine in mg/100ml in male rats with gentamycin induced nephrotoxicity expressed by mean+SEM  
P value<0.05



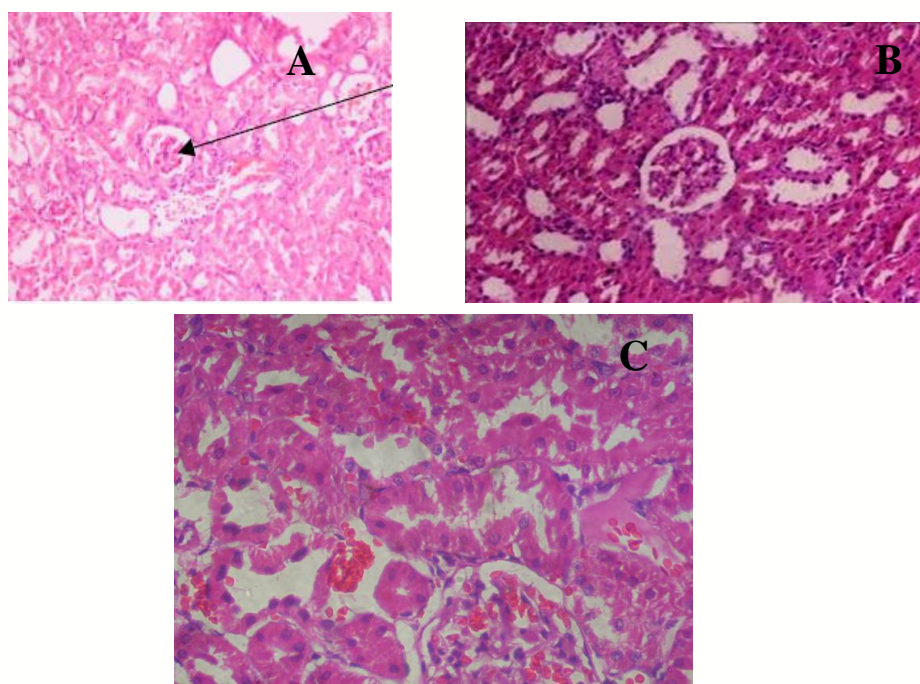


Figure (1): Photomicrograph from renal tissue of rats; (A) control group rats showed normal histology, (B) histological section from rat kidney treated with gentamicin, shows severe renal damage; necrosis, degeneration & vacuolization of proximal convoluted tubules and (C) rat kidney section from the combined curcumin and gentamicin treated group in which the renal tissue appeared normal. Sections were stained with H & E. Original magnifications:  $\times 200$ .

## Discussion

Gentamycin is a member of Aminoglycoside antibiotic which widely used for gram-negative bacterial infection treatment. However, gentamycin administration induces nephrotoxicity which is the most serious complication of gentamycin. (10) Gentamycin carries a positive charge that binds strongly to the brush border phosphoinositide components of the membrane the which is a negative charged and acidic, and they mainly act on the cationic drug receptor, megalin, located deeply at the base of the brush border villi. The drug-receptor complex thus formed is internalized rapidly by a process of pinocytosis and checked up by lysosomes, where lysosomal phospholipidosis occurs that impaired many renal intracellular processes. (11) the attenuation of renal injury that induced by gentamycin would encourage its clinical use. Several approaches involving the use of chemical substances have been used to decrease nephrotoxicity induced by gentamycin (10, 12). Gentamycin is known to produce reactive oxygen species associated with an increase in peroxidation of lipid and a decrease in antioxidant enzyme activity in the kidney(13). Furthermore, it acts as an iron chelator by forming a gentamycin \_iron complex that is a potent catalyst of radical generation (1, 14). Our result revealed that co-administration of curcumin significantly ( $P < 0.05$ ) reduce the serum creatinine and blood urea levels which were increased due to gentamycin injection. Also, the scores of pathological damage indicated that coadministration of curcumin significantly attenuated the damage score. The finding of our study is in agreement with those reported by Bashun et al(15) who found that Curcumin exerts pleiotropic effects which include anti-

inflammatory actions, antioxidant and, show better protection from nephrotoxicity induced by gentamycin. In the current study, curcumin coadministration decreased urea and creatinine significantly and restore some histopathological changes induced by gentamycin administration in rats(16). oxidative stress plays a vital role in the induction and progression of gentamicin-induced nephrotoxicity. curcumin increase renal antioxidant enzyme (superoxide dismutase and glutathione peroxidase) and this finding are consistent with Tapia *et al.* (16) who observed that curcumin elevate antioxidant enzyme in rat remnant kidney. This inhibitory effect of curcumin on lipid peroxidation could be secondary to its antioxidant activity. On the other hand, curcumin reduces the renal level of nitric oxide in gentamicin- and cholestasis-induced renal injury (17, 18). acute renal failure and tubular damage occur because of free radical nature of nitric oxide(NO) (18). Additionally, tubular injury and renal failure may result from the reaction between NO with the radical of superoxide and formation of peroxynitrite which is highly cytotoxic and responsible for tubular cell damage resulting in renal failure. Curcumin reduces the level of NO by its inhibitory effect on inducible nitric oxide synthase (9, 15) in rats treated with gentamicin and curcumin together; biochemical and histopathological changes were found to be reversed. (15).

Sometimes the rate of ROS (hydroxyl radicals and hydrogen peroxide) production exceeding antioxidant level inside the cell nonenzymatically (e.g., carotenoids, glutathione, ascorbic acid, a-tocopherol) and enzymatic (e.g., superoxide dismutase, glutathione peroxidase and catalase.). This discrepancy between antioxidant levels and reactive oxygen species production will damage the cell and lead to many health problems (19). For example, in the brain, ROS overproduction and accumulation enhances the development of Alzheimer's disease and aggravate its progression. The diet supplemented with antioxidant substances from natural source will solve this problem. Supplementation with Antioxidant can ameliorate the effect of ROS which can protect the cell from damage and death (20). So Antioxidant supplements are effective in the treatment of many diseases in human including various types of cancer, atherosclerosis, cardiovascular diseases, inflammatory injuries, neurodegenerative diseases, and aging. Natural antioxidants can serve as a type of preventive medicine. Curcumin inhibits lipid peroxidation and effectively scavenges ROS so has a potent antioxidant activity (2) (19).

## Conclusion

Adding curcumin to gentamicin treatment attenuated renal damage and improved renal function possibly through ROS scavenging and antioxidant activity. Further studies are recommended to clarify the antiapoptotic potential of curcumin.

## References

1. Alarifi S, Al-Doaiss A, Alkahtani S, Al-Farraj SA, Al-Eissa MS, Al-Dahmash B, et al. Blood chemical changes and renal histological alterations induced by gentamicin in rats. Saudi journal of biological sciences. 2012;19(1):103-10.
2. Daniel S, Limson JL, Dairam A, Watkins GM, Daya S. Through metal binding, curcumin protects against lead-and cadmium-induced lipid peroxidation in rat brain homogenates and against lead-induced tissue damage in rat brain. Journal of inorganic biochemistry. 2004;98(2):266-75.

3. Ali B. Gentamicin nephrotoxicity in humans and animals: some recent research. *General Pharmacology: The Vascular System*. 1995;26(7):1477-87.
4. Bledsoe G, Crickman S, Mao J, Xia CF, Murakami H, Chao L, et al. Kallikrein/kinin protects against gentamicin-induced nephrotoxicity by inhibition of inflammation and apoptosis. *Nephrology, dialysis, transplantation : official publication of the European Dialysis and Transplant Association - European Renal Association*. 2006;21(3):624-33.
5. Abdel Aziz MT, El-Asmar MF, Rezaq AM, Mahfouz SM, Wassef MA, Fouad HH, et al. The effect of a novel curcumin derivative on pancreatic islet regeneration in experimental type-1 diabetes in rats (long term study). *Diabetology & metabolic syndrome*. 2013;5(1):75.
6. Hussein H, Abu-Zinadah O. Antioxidant effect of curcumin extracts in induced diabetic wister rats. *Int J Zool Res*. 2010;6(4):266-76.
7. Noor NA, Aboul Ezz HS, Faraag AR, Khadrawy YA. Evaluation of the antiepileptic effect of curcumin and Nigella sativa oil in the pilocarpine model of epilepsy in comparison with valproate. *Epilepsy & behavior : E&B*. 2012;24(2):199-206.
8. Ahmad M. Protective effects of curcumin against lithium-pilocarpine induced status epilepticus, cognitive dysfunction and oxidative stress in young rats. *Saudi journal of biological sciences*. 2013;20(2):155-62.
9. Morsy MA, Ibrahim SA, Amin EF, Kamel MY, Rifaai RA, Hassan MK. Curcumin ameliorates methotrexate-induced nephrotoxicity in rats. *Advances in pharmacological sciences*. 2013;2013:387071.
10. Randjelovic P, Veljkovic S, Stojiljkovic N, Jankovic-Velickovic L, Sokolovic D, Stojiljkovic M, et al. Salicylic acid attenuates gentamicin-induced nephrotoxicity in rats. *TheScientificWorldJournal*. 2012;2012:390613.
11. Hur E, Garip A, Camyar A, Ilgun S, Ozisik M, Tuna S, et al. The effects of vitamin d on gentamicin-induced acute kidney injury in experimental rat model. *International journal of endocrinology*. 2013;2013:313528.
12. Parlakpınar H, Tasdemir S, Polat A, Bay-Karabulut A, Vardi N, Ucar M, et al. Protective role of caffeic acid phenethyl ester (CAPE) on gentamicin-induced acute renal toxicity in rats. *Toxicology*. 2005;207(2):169-77.
13. Alarifi S, Al-Doaiss A, Alkahtani S, Al-Farraj S, Al-Eissa MS, Al-Dahmash B, et al. Blood chemical changes and renal histological alterations induced by gentamicin in rats. *Saudi journal of biological sciences*. 2012;19(1):103-10.
14. Khan SA, Priyamvada S, Farooq N, Khan S, Khan MW, Yusufi AN. Protective effect of green tea extract on gentamicin-induced nephrotoxicity and oxidative damage in rat kidney. *Pharmacological Research*. 2009;59(4):254-62.
15. Bashan I, Bashan P, Secilmis MA, Singirik E. Protective effect of L-arginine on gentamicin-induced nephrotoxicity in rats. *Indian journal of pharmacology*. 2014;46(6):608-12.
16. Tapia E, Soto V, Ortiz-Vega KM, Zarco-Márquez G, Molina-Jijón E, Cristóbal-García M, et al. Curcumin induces Nrf2 nuclear translocation and prevents glomerular hypertension, hyperfiltration, oxidant stress, and the decrease in antioxidant enzymes in 5/6 nephrectomized rats. *Oxidative medicine and cellular longevity*. 2012;2012.
17. Tokaç M, Taner G, Aydın S, Özkardeş AB, Dündar HZ, Taşlıpınar MY, et al. Protective effects of curcumin against oxidative stress parameters and DNA damage



in the livers and kidneys of rats with biliary obstruction. Food and Chemical Toxicology. 2013;61:28-35.

18. Christo JS, Rodrigues AM, Mouro MG, Cenedeze MA, de Jesus Simões M, Schor N, et al. Nitric oxide (NO) is associated with gentamicin (GENTA) nephrotoxicity and the renal function recovery after suspension of GENTA treatment in rats. Nitric Oxide. 2011;24(2):77-83.

19. Barzegar A, Moosavi-Movahedi AA. Intracellular ROS protection efficiency and free radical-scavenging activity of curcumin. PloS one. 2011;6(10):e26012.

20. Sun X, Liu Y, Li C, et al. Recent Advances of Curcumin in the Prevention and Treatment of Renal Fibrosis. *Biomed Res Int*. 2017;2017:2418671.