

STUDY OF SOME PHYSIOLOGICAL AND HISTOLOGICAL CHANGES IN *MUS MUSCULUS* MICE AFTER EXPOSURE TO CHLORPYRPHOS PESTICIDE

Majdy F. Majeed AL-Ali

Nowfel H. Jassim*

Department of Anatomy, College of Veterinary Medicine, University of Basrah, Basrah, Iraq

* Department of Physiology, College of Veterinary Medicine, University of Basrah Basrah, Iraq

(Received 20 September 2008, Accepted 2 December 2008)

Keywords: Pesticides ,GOT, Kidney.

ABSTRACT

The aim of this study to determinate the toxic effect for different concentrations of organophosphorous pesticide called Chlorpyrphous, some histological and physiological features of the internal organs of (*Mus musculus*) mice by oral administration. The experimental mice were oral administration of (0.1mg/kg and 0.2 mg /kg.) twice weekly during 3 weeks. After 21 day of experiment the (GOT, GPT)enzymes and urea and total protein were estimated . The following organ were taken for histological studies: liver, kidney, lung, stomach, intestine, and testes.

The histological studies were carried out on the liver and kidney. The results of this study showed that the oral administration of chloropyrphose in some histological changes in kidney and liver. and elevation in the level of GOT of GPT enzyme also urea and protein.

INTRODUCTION

During the past two decades, the wide spread use of pesticides has lead to increasing contamination of the environment with these chemical this has provoked much. public concern, stimuli at us of the adverse effects on wild life and by possibility of similar toxic effect in man as the result of eating contaminated food snuffs.

Pesticide its biochemical metabolism in mammals and aquatic organism.

Most pesticide specially the phosphorus insecticide group. were recognized by its higher lipophilic ability and it is easily absorbed by the body of living microorganisms (1) All pesticide undergoes different serous biochemical changes inside the living organism body either it was aquatic animals or mammals. The study of pesticides metabolism is consider from every important this because of most of the metabolic products of this pesticides was toxic inside to its originated compounds if unless it was toxic (2) Each of Hill of (3) and story

of (4) confined that mammals like human, mice, rat and dogs have a more modern detoxification system than fishes and other aquatic organism because of its higher ability in metabolic process of toxic metabolized material which results by the desulphuration (driver and bouquet). This process depends on the hepatic microsomal enzymes which are able to hydrolyse. The toxic metabolized material such as the chlorpyrifos-Oxon produces diethoxythiophosphate which is easily excreted outside the body with urine or bile, but other studies have conferred that there is a probability to occurring of a secondary reaction to chlorpyrifos pesticides during the hydrolysis and producing chlorpyrifos-monoethyle which is easily excreted outside of the body (5).

Mechanism of metabolic and behavior of response to pesticide in mammals. In mammals the pesticides show an obvious physiological and metabolic effects on it (6)

Although its high ability to metabolic conversion in most of this compound inside of its bodies (7) There for there are several studies has been occur to observe the toxic effect of pesticide on mammals and there are several enzymes effected agriculture chemical (8) has been reported during their studies the effect of diclofop-methyl pesticide on the apodemus sylvaticus.

Increasing the activity of (GOT) Glutamic oxaloacetic transaminase and glutamicpyruvic transaminase (GPT) in the plasma by using of serial concentration(20,200,500,1000)mg/kg of diet. While (9) observed that there is inhibiting in the activity of GOT and GPT and alkaline phosphates in the intestine of rats which is treated with 5mg/kg of B.w. with malathion pesticide for 45 exposure time while the administration of phosphamion pesticide for (30-60) exposure time reveal an increase in the concentration of GOT and GPT and bilirubin in blood plasma.

MATERIALS AND METHODS

Nine adult laboratory mice weighted about (20-30 gm) were housed in separated cages in the room temperature and fed a diet with high power.

These animals were divided into three groups one the first group consist of three mice still untreated for control , second group consist of three mice administration chlorpyrifose(technical grade 10% dissolved in distilled water 90% given twice weekly at a dose of 0.1 mg/kg B.w. for three weeks , third group consist also of three mice administrated chlorpyrifose (technical grade 10% dissolved in distilled water 90% given twice weekly at dose of 0.2 mg/kg B.w for three weeks also one of each control and experimental. The animal groups sacrificed .are

sacrificed after 3,4 weeks respectively. At necropsy liver, kidney and digestive system tissue were taken and then it is perpetrated for microscopic inspection. The tissue of over said organs are taken from the control of experimental animal and fixed in 10% formalin for 24h. subsequent the tissues were washed. In running tap water, dehydrated in alcohol cleared in methyl benzoate and embedded in paraffin wax(paraffin embedding method)section of 5-6 were cut by microtome and stained by haematoxylin and eosin (HARRIS 1900) in order to observe histological change. The histological study was revealed that the liver and kidney tissues are more affected organs than the other organ. This is for histological examination. But in physiological examination there are measurements for urea. GOT and GPT also total plasma protein as following.

1-Urea ; By using Patton of crouch method for estimation of urea in serum by biomeriux which depending essentially on urea reaction with water to liberation of ammonium and by its reaction with salicylate and hypochlorite in alkaline medium to produce indophlrite and then measured the color intensity by spectrophotometer in wave length (580) nm as in procedure.

Physiological Parameters

1- Measure of GPT

The GPT values were estimated by using by (10) method for determination GPT enzyme activity in serum by using kits provided by RANDOX laboratories that depending essentially on reaction between &-oxalo acetate and l- a lanine to form oxaloacetate and the last will react with 2,4 Dinitrophen-hydrazin then read it is color density by spectrophotometer in (546) wave length.

2- Measured of GOT

The GOT values were estimated by using Reitman of By using (10) method for estimation the activity of Gpt enzyme in serum by using Kits provided by Randox laboratories that depend on reaction between & Oxaloacetate with L- alanine which produce the pyrovate which react with 2,4 Dinitrophenyl hydrazine to produce pyruvate hydrazOne then reading it is color density by spectrophotometer.

3- Measured of Serum protein

The Total protein of serum was determinate by using Biuret method for estimation of total protein in serum by using kit provided by Randox laboratories this method depending on

reaction CUI with protein peptide linkage in alkaline medium to form complex then measured its color density by spectrophotometer in 546 nm.

RESULTS AND DISCUSSION

Liver is the natural position for detoxification therefore it is considered from the important organ which is affected by the toxin leading to disturbance of its normal function such as degeneration, swelling, inflammation ending by necrosis and complete destruction of the cells and these changes depend on the intensity of the toxic effect of pesticide (11).

Most of organophosphorus pesticides are compounds that easily cross the hepatocytes membranes and affect on this membranes function and increase its permeability to water and then hepatocytes swelling (12).

(13) reported the loss of hepatic cords division and hepatic cord and increase number of phagocytes and granulocytic cells considered as an origin to initiate the inflammation around the bile ducts. Figure (1).

(14) preferred during their study on *S. sairdneni* fish which is treated with tetramethylthiuramdisulfide pesticide that there is necrosis in hepatocytes figure also there is degeneration in liver cell which is reported by (15) during his study on *T. Tandanus* fish which treated by endosulfan for (24) who thought that, it's starting to necrosis due to the toxicity of the pesticide (figure 2 and 3)

Histopathological changes in kidney:

Kidney also reveal histopathological changes laboratory white mice treated with chlorpyrifos in first and second group. It's (11) during their study on white mice treated with 25 g/kg of alpha cypermethrin who observed the accumulation of inflammatory lymphatic cells around the renal tubules. Atrophy in the glomerulus, hypertrophy in Bowman's capsule also accumulation of edema fluid between the renal tubules and degeneration and necrosis to the tubules endothelium. Also there are several factors affected the toxicity degree of pesticide that interfere with its affection on renal tissue such as type of pesticide, its concentration and dosage also. (8) mention that the kidney is the essential organ for excretion of toxins out side the body in same time this toxins lead to destroy the renal tissue depending on the dosage and (16) mentioned the necrosis in different tissue appeared after the appearance of degeneration which results from the tissue death due to decrease in

oxygenated blood supply and nutrient that reach to this tissue degeneration occur after 24 hours from administration of toxic materials while the complete atrophy of glomerulus is due to increase the permeability of glomerulus capillaries endothelium by action of toxic material lead to increase the osmolarity of plasma elements which form the hyaline this process known as plasmatic vesicles is which lead to ischemia of and atrophy of glomerulus's and the blood capillaries replaced by pale homogenous material (11)The results revealed specific references between the treated mice from the controlled mice and we recorded maximum overage in urea during 21 days from the experimental maximum increase during this time , its recorded (8.542) ml mol / L . in compare with first group treated mice and control that revealed 7.98 , 6.87 untidy. We can to referred the previous changes to tissue damage of kidney that lead to distmption of natural renal filtration. The observed degeneration of necrosis in epithelial cells that lined the renal tubules and glomerulus's cause loss of ability of the tubules to reabsorb and filtrate the large molecules such as protein , mineral , salts and vitamins also distraction of urea filtration which lead to increase its level in the blood. Also liver damage that caused by pesticides effect obviously on the formation of protein. while in the detection of Got and Gpt enzymes the results revealed that there is increase in the value of these enzymes during 21 days of experiment and the 0.2 concentration revealed maximum increase 7.24 for Got and 21.087 for Gpt enzymes in compare to 0.1 concentration and control that revealed 6.89 GOT and 99 for GPT untidy. (17)mentioned that GOT and GPT consider from important transference enzymes in diagnosis of damage hepatocytes because it is released from distraction cells to the blood. (18)during their study on white mice treated with phosphamidon pesticides mentioned that there is increase in level of Got and Gpt enzymes during the necrosis in hepatocytes which lead to increase the permeability of cell membrane cause release of this enzymes to blood.

Fig (1) Results of peroteins parameters in blood tissue of mice groups .

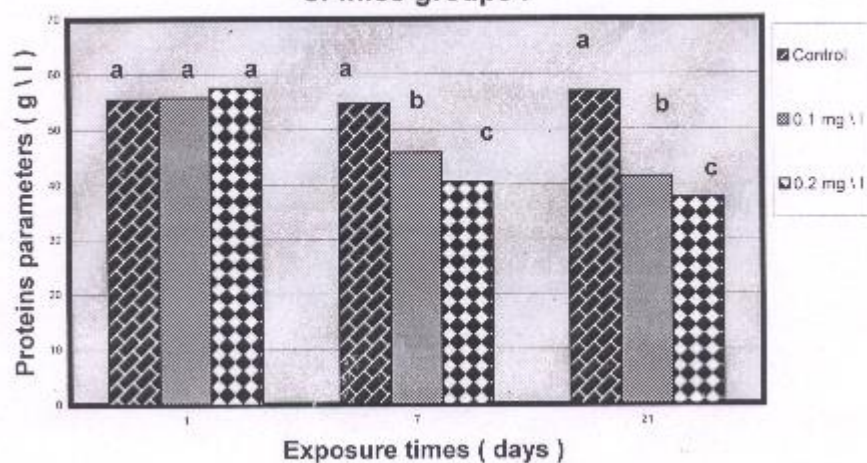


Figure (2) Results of GOT enzymes content in blood tissue of mice groups .

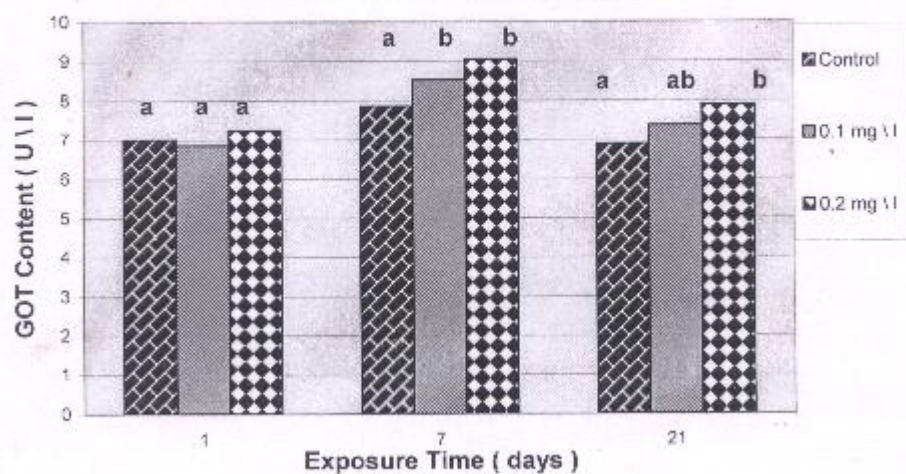


Figure (3) Results of GPT Enzymes Content in Blood tissue of mice groups .

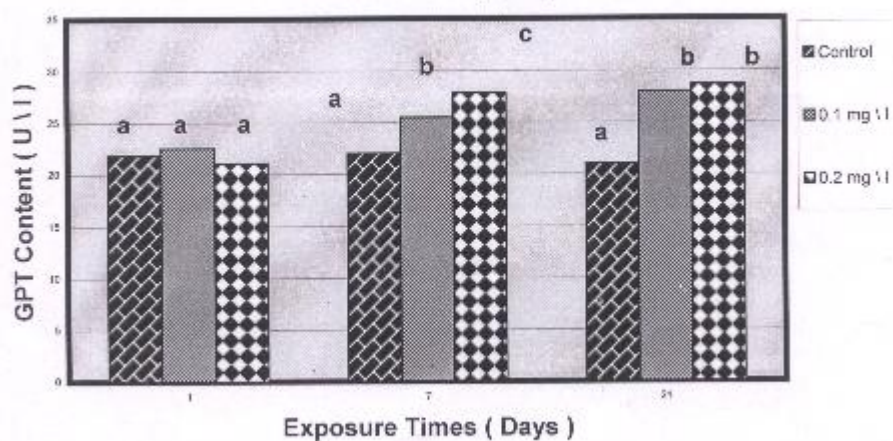
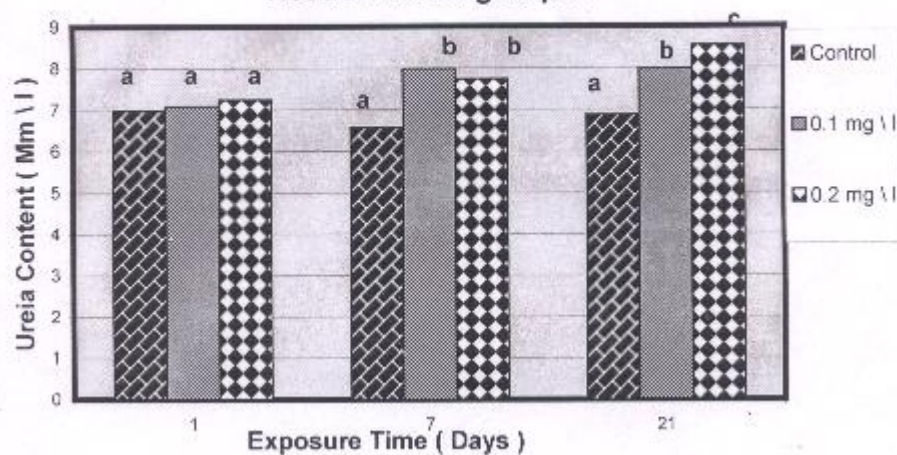
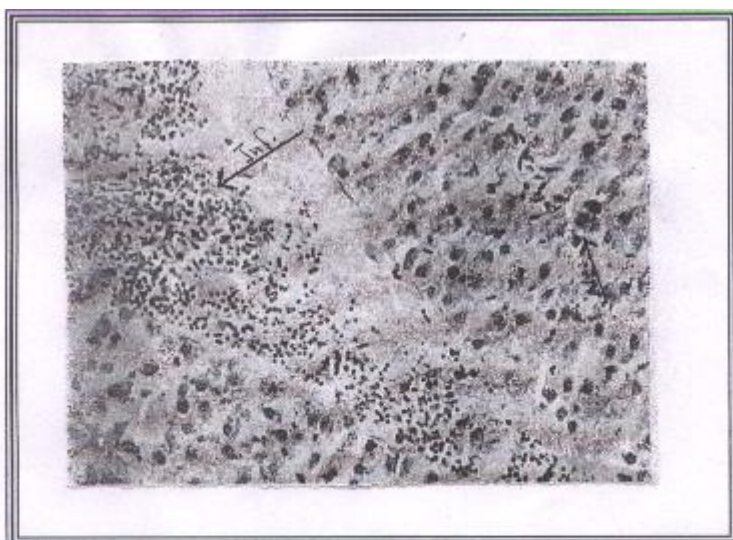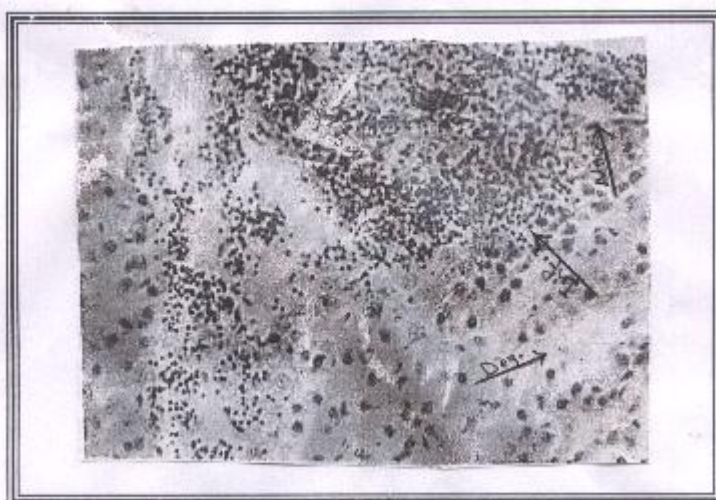


Figure (4) Results of Ureia Content in Blood Tissue of mice groups .





**Figure (1) Liver of mice after (7) days of exposure to 0.1 mg \ l , appeared
Inflammation and necrosis**



**Figure (2) Liver of mice after (7) days of exposure to 0.2 mg \ l , appeared
Inflammation , necrosis and degeneration in hepatocytes**



Figure (3) Liver of mice after (21) days of exposure to 0.2 mg \ l , appeared degeneration in hepatocytes

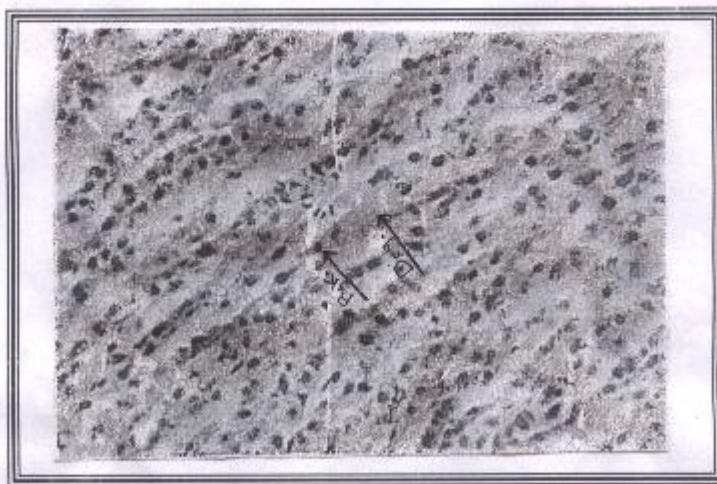

Figure (4) Liver of mice after (21) days of exposure to 0.2 mg \ l , appeared of degeneration , pyknosis of hepatocytes

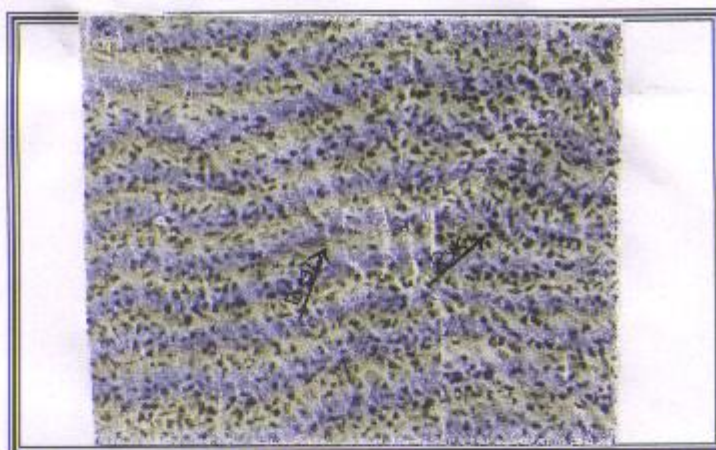


Figure (5) Liver of mice after (21) days of exposure to 0.2 mg \ l , appeared of degeneration , pyknosis of hepatocytes

Figure

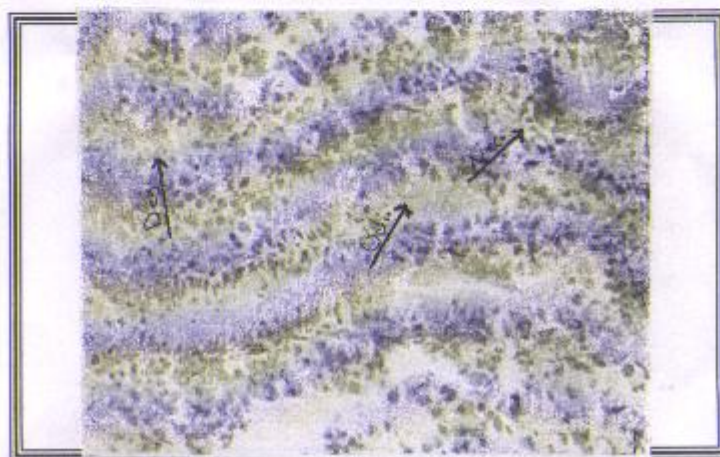


Figure (6) Kidney of mice after (7) days of exposure to 0.1 mg \ l , appeared of degeneration , necrosis and odima in urinary tubules

Figure (8) Kidney of mice after (21) days of exposure to 0.2 mg \ l , appeared of degeneration , Inflammation and necrosis in urinary tubules

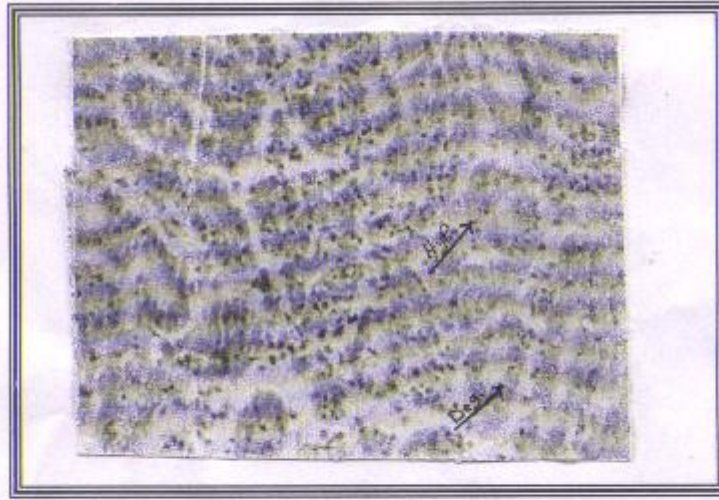


Figure (9) Kidney of mice after (21) days of exposure to 0.2 mg \ 1 , appeared of Hyperplasia and Degeneration in urinary tubules

دراسة بعض التأثيرات الفسلجية والنسجية للأعضاء الداخلية للفئران المختبرية بعد تعرضها للمبيد الحشري الكلوروفوس

مجدي فيصل مجيد * نوفل حمادي جاسم **

*فرع التشريح، كلية الطب البيطري، جامعة البصرة، البصرة، العراق.

**فرع الفسلجة، كلية الطب البيطري، جامعة البصرة، البصرة، العراق

الخلاصة

هدف هذا البحث دراسة التأثير السام للتركيز المختلفة لمركبات (organophosphrus) وتدعى (chlorpyrphose) ودراسة بعض الخصائص النسيجية والفسلجية للأعضاء الداخلية للفئران بطرق الأعطاء عن طريق الفم.

الفئران المختبرية أعطيت جرعة (0.1 mg/kg and 0.2 mg/kg) مرتين كل اسبوع لمدة ثلاثة اسابيع وبعد 21 يوم نقيس أنزيمات (GOT, GPT) وكذلك اليوريا والبروتين. وعملنا دراسة نسيجية للأعضاء الأخرى مثل الكبد والكلية والرئة والمعدة والأمعاء وكذلك الخصيتين.

ونستنتج أن أعطاء (chloropyrphose) عن طريق الفم أحدث تغييرات نسيجية في الكبد والكلية وكذلك في مستوى (GOT,GPT) واليوريا والبروتين.

REFERENCE

- 1-Ufodike , E. B. and Omoregie, E. (1994) . Acute toxicity of water extract of bark of *balanites aegyptica* and *kigelia Africana* to *oreochromis niloticus* . *Aquacul. Fish Mange.*, 62A: 658 – 689 .
- 2-Alfartosi A. H. (2003) . Determination of chlorpyrifose residues in data palm trees and its soil by gas chromatography technique and studying of some physiochemical characteristics . thesis , col. Agricul. , Univ. Basrah. pp74 .
- 3-Hill, E. F. and Mendenhall , V. M. (1980) . Secondary positioning of bran owls with famphur an organophosphores insecticides . *J. Wild. Mang.*, 44 : 676- 681 .
- 4-Cox , B. (2001) . Poracrine control of human ledig cell and sertoli cell function Foolia. *Histo. Chem. Cytol.*, 34: 111 – 119 .
- 5-Krueger, H. R. and obrien, R. D. (1989) . relashinship between metabolism and differential toxicity of malathion and chlorpyrifose in insect and mice . *J. Econ. Ent.* , 52: 1063 – 1067 .
- 6-Ramesh, N. ; Balakrishna, M. P. and Philip, K. S. (1996) . In vivo and vitro effects of an organophosphate pesticide, monocrotophos on acetylcholinestrerase activity in wistar rate . *J. Environ. Biol.* , 17 : 235 – 238 .
- 7-Ecobichon, P. J. and zelt, D. (1979) . The acute toxicity of fenitrothion in weanling rats and effects on tissue esterase monooxygenase . *Toxicol.* , 13: 287 – 296 .
- 8- westlacke , G. E. ; Tarrant, K. A. and Hard, A. R. (1988) . Biochemical and histological effects of diclop – methyl in mice and voles under labrotary conditions . *Bull. Enveron. Contam. Toxicol.* , 40: 153 – 158 .
- 9-Wail , R. K. ; Singh, R. ; Daduj; P.K. and Sarker, a. K. (1984) . Subchronic malathion treatment effects on rats intestinal function . *Bull . Enveron. Contam. Toxicol.*33: 289 – 294 .
- 10-Reitman, S. and Frankel, S. (1957) . Calorimatrec methods for determination of serum alanine and aspart aminotransferase . *Amer. J. Cli. Path.* 28: 56pp.
- 11-Luty , S.; Tokarska, M. and Latuszynska, J. (2002). Dermal absorption and distribution of C14 DDT in the organs of rat . *Ann. Agric. Enveron. Med.*, 9 : 215 – 223 .
- 12-Gengerich,W. H.(1982) . Hepatic toxicology of fishes In: *Aquatic toxicology* . Weber , L. J. (ed) Raven, Prees NY., pp: 55 – 106 .
- 13-American Petroleum Institute (A. P. I.) (1985) . Cadimum : Environment and community health impact . EA report API , 137C , P: 404 .

- 14-Schramm, M. ; Behrens, A. ; Braunbeck, T. ; Eckwert, H. ; Kohler, H. R. ; Konradt, J. ; Muller, E. ; Pawert, M. ; Schwaiger, J. ; Segner, H. & Triebkron, R. (1999) . Cellular, Histological & Biochemical Biomarkers. Environ. Sci. Forum, 96: 33-64.
- Valnleeuwen *et. al.*, (1986)
- 15-Nowak, B.; Deavin, J. G. & Munday, B. L. (1992). Scanning electron microscopy in aquatic toxicology. J. Computer-Assisted Microscopy, 4(3): 241-246.
- 16-Andoson, J. R. (1980) . Muri,s Textbook of pathology . Prented by Butler and anner Ltd. , London, UK. 108p.
- 17-Stempel, D. A. & Miller, J. J. (1977). Lymphopenia & hepatic toxicity with ibuprofen. Toxicol. , 90: 657-658.
- 18-Bhatnagar, P. & Jain, N. (1986). Morphofunctional changes in the liver of male mice after chronic treatment with phosphamidon. Bull. Environ. Contam. Toxicol., 37: 767-773 .