

Effect of silver nanoparticles on some blood parameters in rats

A.A. Al-Baker¹, A.A. Al-Kshab² and H.Kh. Ismail³

¹Department of Biology, College of Education for Girls, ²Department of Biology, College of Education for Pure Sciences,

³Department of Pathology and Poultry Diseases, College of Veterinary Medicine, Mosul University, Mosul, Iraq

Email: ¹azharalbaker@uomosul.edu.iq, ²amal.biology@uomosul.edu.iq, ³hana_khismail@yahoo.com

(Received October 25, 2019; Accepted December 4, 2019; Available online July 23, 2020)

Abstract

The present study aims are investigating the effects of oral administration of AgNPs on some blood the parameters to show potential of toxicity of AgNPs as tool therapy and diagnosis. In this study, 20 healthy male and female rats were used. Randomly, rats were divided into 5 groups depending on the period variable respectively; AgNPs-treated rats' groups for a period of 3 days in concentration 0.2 and 0.4 gm/kg B.W, while the second period after 20 and 30 days after treatment with concentration 0.08 and 0.008 gm/ kg B.W. In addition to a control group. A Manual method was used to measure Hematological parameters. Rats treated with AgNPs showed the significant $P < 0.05$ decrease in Hemoglobin, Packed Cell Volume, Red Blood Cells. Also, Mean Corpuscular Volume; Mean Corpuscular Hb and Mean Corpuscular Hb Concentration. Platelets levels and White Blood Cell Count were After the administration of AgNPs, a protective effect on hematopoietic levels and on Red Blood Cell morphology were shown respectively as it is assessed by Leishman stained blood smears resulted in ovalocytosis at the dose 0.4 gm/kg body weight, while at the dose, 0.08 gm/kg showed echinocytes, acanthocytes, tear drop, stomatocyte and codocyte (target RBCs). Thus, it is concluded that oral administration of AgNPs caused a decreased in the level of Hb concentration, PCV, RBC, MCV, MCH, MCHC, but increase PLTS and WBCs. It means that AgNPs has a toxic effect on blood.

Keywords: Silver nanoparticles, White blood cells, Blood smear

DOI: [10.33899/IJVS.2020.165812](https://doi.org/10.33899/IJVS.2020.165812), ©2020, College of Veterinary Medicine, University of Mosul.

This is an open access article under the CC BY 4.0 license (<http://creativecommons.org/licenses/by/4.0/>).

تأثير صغائر الفضة على بعض معايير الدم في الجرذان

أزهار عبد الجبار البكر^١، أمال عبدالاله الخشاب^٢ و هناء خليل إسماعيل^٣

^١ قسم علوم الحياة، كلية التربية للبنات، ^٢ قسم علوم الحياة، كلية التربية للعلوم الصرفة، ^٣ فرع الأمراض وأمراض الدواجن، كلية الطب البيطري، جامعة الموصل، الموصل، العراق

الخلاصة

هدفت الدراسة الحالية إلى معرفة التغيرات الدموية للجرذان المجرعة فمويًا صغائر الفضة وذلك لتحديد سمية صغائر الفضة كأداة علاجية وتشخيصية. إذ استخدم ٢٠ جرذاً سليماً من الذكور والإناث في هذه الدراسة. قُسمت الحيوانات بشكل عشوائي إلى ٥ مجموعات، مجموعة الفئران المعاملة بالفضة النانوية عند التركيزين ٠,٢ و ٠,٤ غم / كغم ولمدة ثلاثة أيام، في حين عوملت الجرذان بالتركيزين ٠,٠٨ و ٠,٠٠٨ غم / كغم من وزن الجسم و شُرحت الجرذان بعد ٢٠ و ٣٠ يوماً من المعاملة، بالإضافة إلى مجموعة السيطرة. وقد تمَّ قياس المعايير الدموية باستخدام الطريقة اليدوية. ظهرت نتائج الدراسة الحالية للجرذان المعاملة بصغائر الفضة النانوية حدوث نقص معنوي في كل من المعايير الدموية التالية: الهيموغلوبين، حجم مكّداًس الدم، عدد كريات الدم الحمراء، متوسط حجم كريات الدم الحمراء، متوسط حجم هيموغلوبين الكرية، متوسط تركيز هيموغلوبين الكرية باستثناء الصفائح الدموية وعدد خلايا الدم البيضاء. إذ أظهرت نتائج الدراسة الحالية تأثير الفضة النانوية على الشكل الخارجي لكريات الدم الحمراء لمسحات الدموية المصبوغة لشمّان، إذ أظهرت كريات الدم الحمراء بيضوية الشكل في الجرذان المعاملة بالتركيز ٠,٤ غم / كغم، بينما ظهرت في دم الجرذان المعاملة بالجرعة ٠,٠٨ غم / كغم شوكة الشكل، ودمعية

الشكل ومفوهة الشكل (كريات الدم الحمراء المستهدفة). خلّصت هذه الدراسة إلى أن تناول صغائر الفضة فمويّاً يسبب انخفاض في مستوى تركيز الهيموكلوبين، مكداس الدم، عدد كريات الدم، MCV، MCH، MCHC، ولكن زيادة عدد الصفائح الدموية وكريات الدم البيضاء، مما يعني أن صغائر الفضة له تأثير سام على الدم.

Introduction

It is widely known that Silver nanoparticles (Ag-NP) used as antimicrobial substances (1). The use Ag⁺ ions cause damage to many microorganism (2). Different studies have showed that nanostructures especially nanoparticles, nanorods, nanotubes, cause hemolysis and blood clotting (3). The materials used were different from each other both in size and coating that led to difficulty in holding a comparison. Moreover, a default of suitable control studies done on this subject were not systematic enough which in turn impedes a comprehensive evaluation of AgNPs blood compatibility. Anyhow, it is reported that, due to the large surface area, a significant increase in an *in vitro* hemolysis was observed with AgNPs that compared with micron-sized particles (4). A Complete Blood Count (CBC) explain the type and the numbers of cells in the blood especially RBCs, WBCs and platelets, a CBC helps in diagnosing conditions, such as anemia, infection, and many other disorders (5). Qualifying the AgNPs toxicity, an important step should be considered, i.e. assessing the various hematological parameters such as HCT; Hb; RBCs; WBCs; and PLTs counts (6). In medicine, there is a kind of unawareness of the parameters hematological alterations induced by Nanomaterial. This research, as mentioned earlier, aimed at measuring routine hematological indices and at identifying and interpreting different dimensional hematological parameters to quantify the AgNPs toxicity.

Materials and method

Experimental animals

Twenty male and female of Albino rats 4 weeks old and 45-50 gm body weight were housed in hanging cages and kept at temperature 25±2°C and 14 hours light and 10 hours dark and were given normal food and tap water. The size of AgNPs which used in this study is 100nm were orally administered in rats which were randomly divided into five groups. Each one contains 4 animals.

Experimental design

In group 1 rats treated with AgNPs at concentration 0.2 gm/kg orally given with water and dissection after 3 days. In group 2, rats treated with AgNPs in concentration 0.4 gm/kg orally given with water and dissection after 3 days. In group 3, rats treated with AgNPs in concentration 0.4 gm/kg orally given with water and dissection after 3 days. In group 4, rats treated with AgNPs in concentration 0.4 gm/kg orally given with water and dissection after 3 days. In group 5, rats fed

with standard diet and water with any treatment. Blood samples were collected anticoagulant (EDTA) and used for examination of hematological analysis by manual methods. Blood smear was stained with Leishman stain (7).

Statistical analysis

Our data analyzed via the mean ± St. deviation Data were analyzed via using SPSS, the statistical software. One-way ANOVA option was used. Post hoc test was performed using the Duncan's test. Mean values were considered to be statistically significant at P≤0.05 (6).

Results

The present study showed that rats treated with AgNPs developed a difference in Hb, PCV, total WBCs, lymphocyte, mononuclear and granulocyte numbers and RBCs compared with control group. Hb, PCV and red blood cell are higher decrease significantly compared with control animals.

Figure 1, showed the Hb in rats after oral administration 0.2, 0.4, 0.08 and 0.008 gm/wb of AgNPs compared with the control. Figure 2, showed the hematocrit % or packed cell volume in animals after oral treatment of 0.2, 0.4, 0.08 and 0.008 gm/W.B. compared with the group 5.

Most of the WBCs parameters were higher in the treated rats than in the group 5 ones but not significantly, although the lymphocyte percent was significantly higher in the treated compared with control ones, with increasing of lymphocytes percentage accompanied compared with control.

A depletion the majority of monocytes%, neutrophils%, and eosinophils % after treatment with AgNPs compared with the group five. While the account of RBC was decreased in treated animals compared with the control ones. The PLTs count increased after treatment of AgNPs compared with the group 5.

The relationships between the HCT, the HG level, and the RBCs are converted to erythrocyte osisindices through mathematical formulas. The indicator includes MCV, MCH, MCHC and RDW. Figure 2 showed significantly increased in MCV after given 0.2, 0.4, 0.08 and 0.008 gm/wb of AgNPs compared with the non-treatment animal (control group), respectively (Tables 1 and 2). The MCV accompanied with the given of treatment of AgNPs significantly increased compared with control. The MCV shows the size of RBCs (Figure 3), while figure 4 showed decrease, RBCs count and increase total WBCs count.

Table 1: Effect of AgNPs on blood parameters in rats in concentration 0.2-0.4 gm/kg of body weight

Blood parameters	Control	0.2 gm/Kg	0.4 gm/Kg
Hb(g/L)	14±0.2 b	10.8±0.08 a	10.5±0.5 a
PCV (%)	0.42±0.02 b	0.33±0.03 a	0.31±0.01 a
WBC(×10 ³ /ul)	7.0±1.0 a	7.3±0.3 a	7.5±0.5 a
RBC×10 ⁶ /mm ³	4.5±0.5 a	4.0±1.00 a	4.1±0.1a
MCV fl	93.3±0.3 c	82.5±0.5 b	75.6±0.6 a
MCH (pg)	31.1±0.11 b	27±1.5 a	25.6±1.0 a
MCHCg HB/100ml	33.3±3.0 a	32.7±1.0 a	33.8±1.7 a
PLT (x10 ³ cells/μL)	435±5.0 a	460±10.0 a	497±100 a
NEU %	21±3.0 a	17±2.00 b	10±2.00 a
LYO%	72±2.00 a	78±2.00 b	82±2.00 b
MONO%	6±1.0 a	5±2.00 a	3±2.00 a
EOS%	1±1.0 a	4±2.0 a	3±1.5 a
BASO%	0±0.001 a	1±0.7 b	1±1 b

The different letter indicates to significant differences at P<0.05.

Table 2: Effect of AgNPs on blood parameters in rats at concentration 0.08-0.008 gm/kg of body weight

Blood parameters	Control	0.08 gm/Kg	0.008 gm/kg
Hb (g/L)	14.0±0.2 b	10.2±0.2 a	9.8±0.1 a
PCV (%)	0.42±0.02 b	0.30±0.1 a	0.28±0.02 a
WBC (×10 ³ /ul)	7.0±1.0 a	8.3±0.3 ab	8.8±1 b
RBC (10 ⁶ /mm ³)	4.5±5.0 a	3. 8±1 a	3. 5±2 a
MCV (fl)	93.3±0.3 a	78.9±10 a	80±10 a
MCH (pg)	31.1±0.11 b	27.6±1 a	28±1 a
MCHC (HB/100ml)	33.3±3 a	34±2 a	35±1 a
PLT (10 ³ cells/μL)	435±5.0 a	561±1.0 b	570±100 b
NEU (%)	21±3.0 a	7±2.0 b	5±1.0 b
LYO (%)	72±2.0 a	84±4.0 b	86±1.0 b
MONO (%)	6±1.0 a	4±2.0 a	5±3.0 a
EOS (%)	1±0.001 a	2±2.0 a	1±1.0 a

The different letter indicates to significant differences at P<0.05.

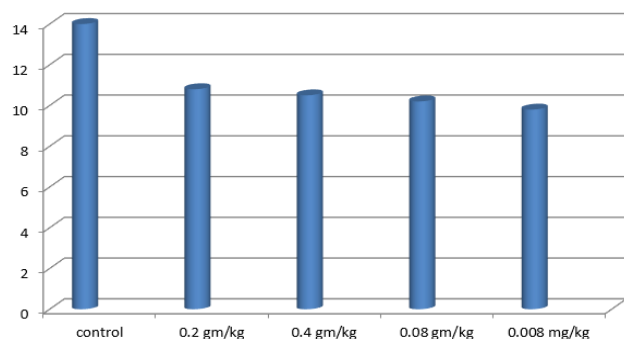


Figure 1: Effect of silver nanoparticles on hemoglobin in rats.

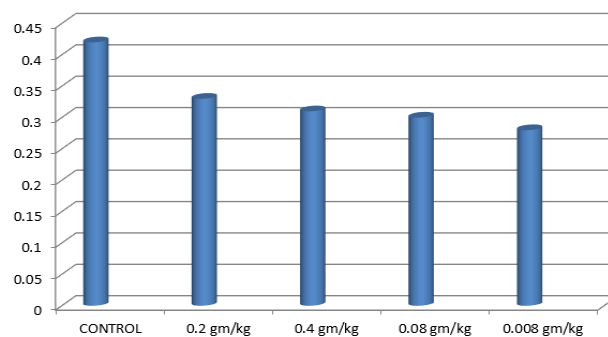


Figure 2: Effect of silver nanoparticles in rats on PCV in rats.

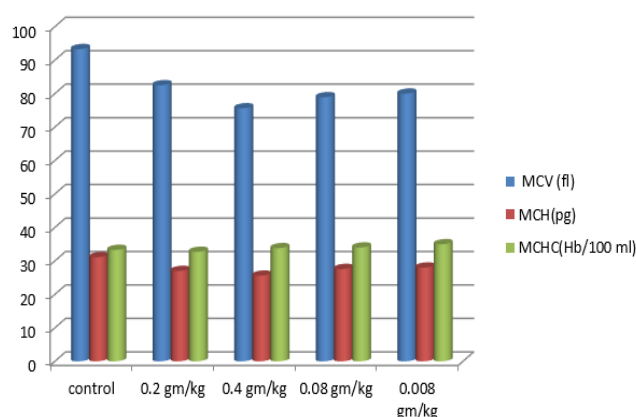


Figure 3: Effect of silver nanoparticles on MCV, MCH and mean corpuscular hemoglobin concentration.

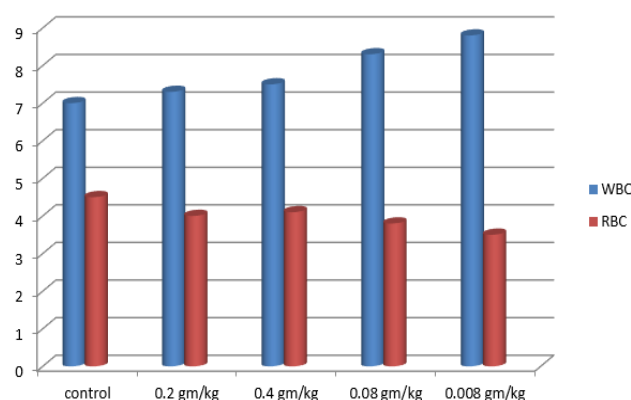


Figure 4: Effect of Ag nanoparticles on RBC, WBC.

RBCs Abnormality

Normal red blood cell has a biconcave disk shape and have an area of pallor center when viewed microscopically (Figure 5). Different kinds of RBCs anomalies were observed in blood film of rats treated with silver nanoparticles with different doses includes hypochromic normocytic (Figure 6) marked codocyte (Figure 7), ovalocytes (Figure 8), chinocytes (Figure 9), acanthocytes (Figure 10), tear drop (Figure 11), stomatocyte (Figure 12).

RBC Morphology

Figure (7) showed Hypochromic anemia seen in blood film of rats that are exposed to silver nanoparticles at concentration 0.2 g/kg. Figure (13) showed Macrocytic anemia which the RBCs appears abnormal in size. Figure (14) showed Rouleaux formation which means stacks either singular or rouleau or aggregation of red blood cells, that appear as stacks together in chain.

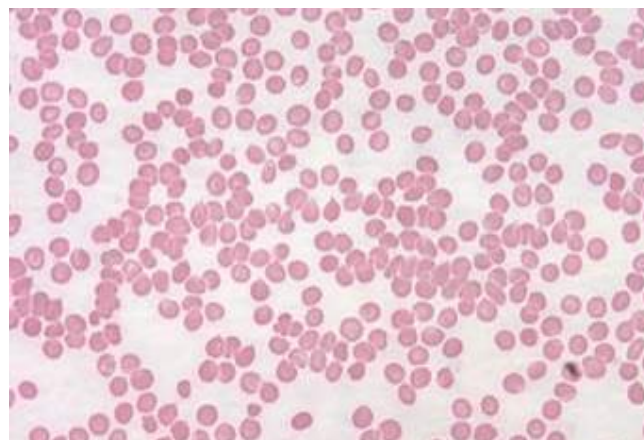


Figure 5: Blood smear of control group of rat showing normal shape of RBCs, Leishman stain, X400.

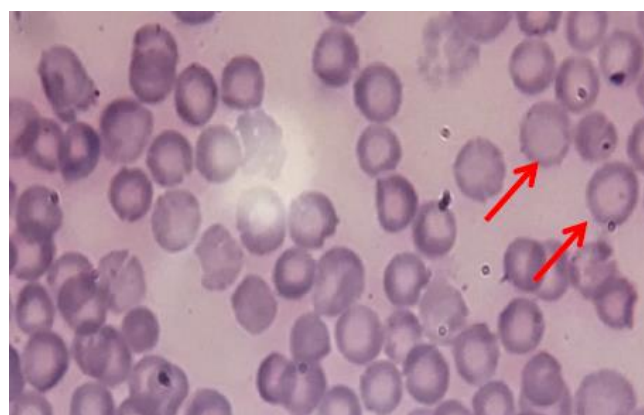

Figure 6: Blood smear of rat treated with 0.2 gm/kg of AgNPs showing hypochromic normocytic RBCs, Leishman stain, X1000.

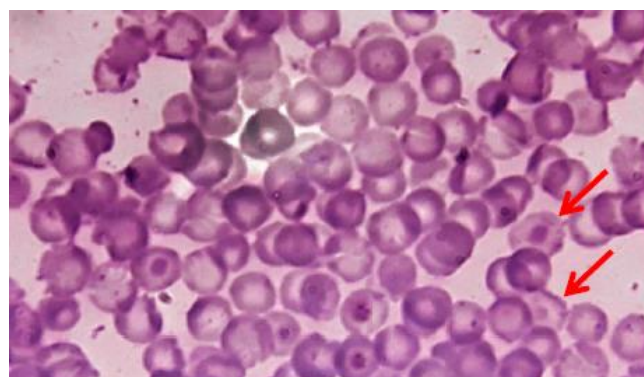


Figure 7: Blood smear of rat treated with 0.2 gm/kg of AgNPs showing macrocytic hypochromic normocytic RBCs and target RBCs (arrows), Leishman stain, X1000.

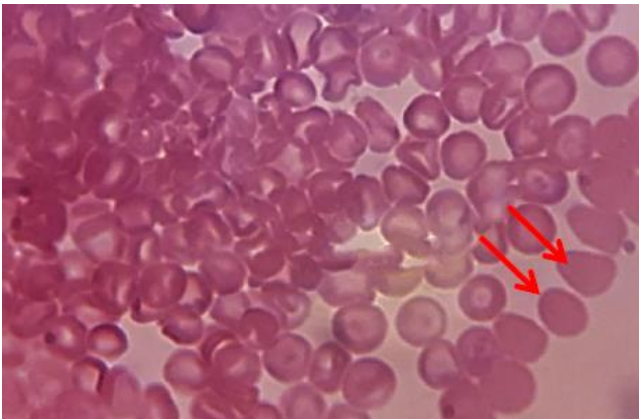


Figure 8: Blood smear of rat treated with 0.4 gm/kg of AgNPs showing ovalocytosis (arrows), Leishman stain, X1000.

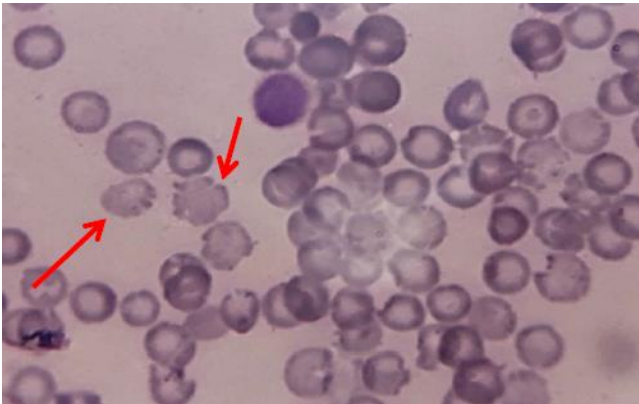


Figure 9: Blood smear of rat treated with 0.008 gm/kg of AgNPs showing a number of echinocytes which appeared speculated RBCs (arrows), Leishman stain, X1000.

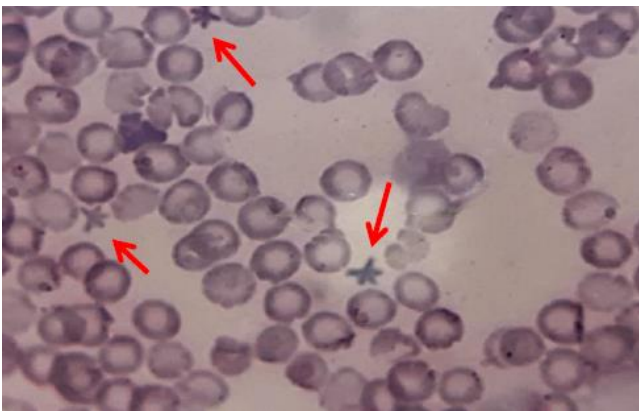

Figure 10: Blood smear of rat treated with 0.008 gm/kg of AgNPs showing a number of acanthocytes which appeared speculated RBCs (arrows), Leishman stain, X1000.

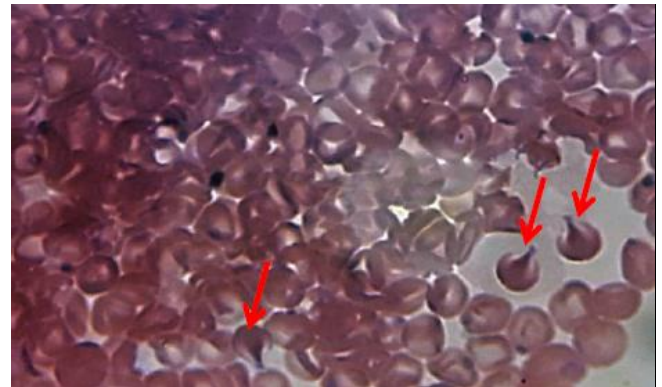


Figure 11: Blood smear of rat treated with 0.008 gm/kg of AgNPs showing tear drop RBCs (arrows), Leishman stain, X1000.

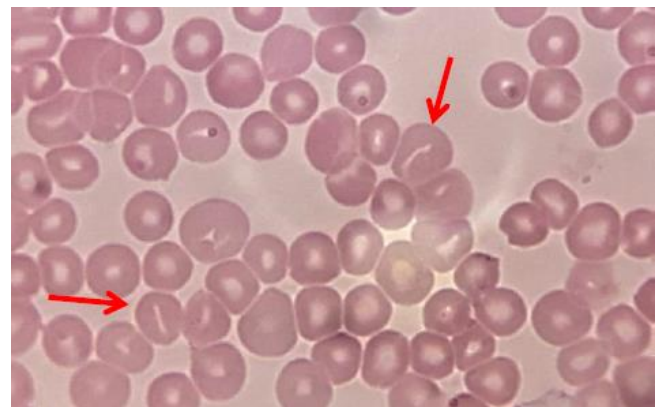


Figure 12: Blood smear of rat treated with 0.008 gm/kg of AgNPs showing stomatocyte RBCs (arrows), Leishman stain, X1000.

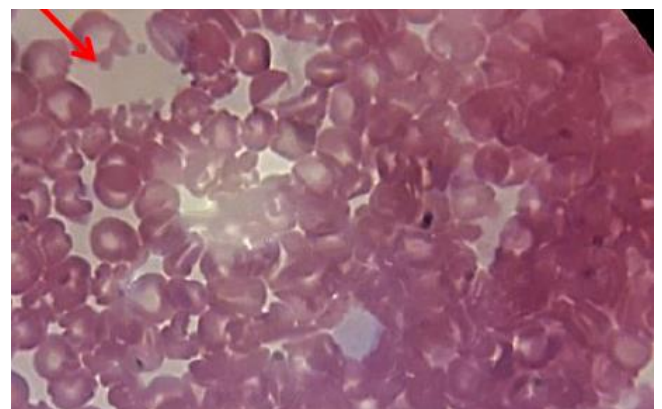


Figure 13: Blood smear of rat treated with 0.4 gm/kg of AgNPs showing normocytic macrocytic RBCs (anisopokilocytes) Leishman stain, X1000.

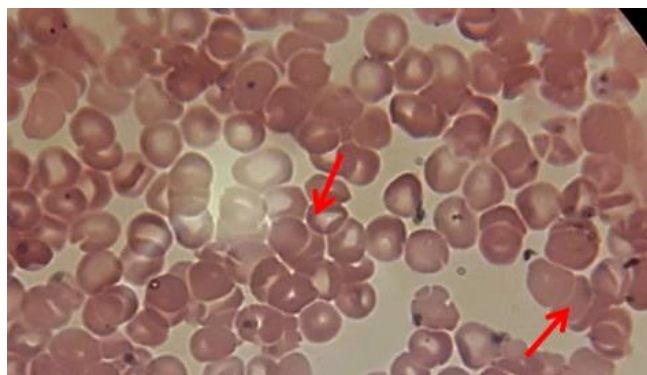


Figure 14: Blood smear of rat treated with 0.08 gm/kg of AgNPs showing the rouleaux formation (arrows), Leishman stain, X1000.

Discussion

Obtained result on hematology showed an alteration in blood picture and number of red cells parameters. These alterations in red blood cells may indicate effect of the nanoparticles on hemoglobin syntheses during red blood cells maturation during formation in bone marrow (7).

White blood cells have an important role in the immunity of body response, represent the first defense line different types of the neutrophils can indicate an infection, allergic or toxic reaction against drugs or chemicals, (8).

While the RBC account was decreased in treated animals in comparison with the control group. The occurrence of anemia is due to hypoxia and the decrease in RBCs count means that there was an increased destruction of (Red Blood Cells) RBCs which it might be due to the deficiency of iron and cobalamin, or folic acid or it is due to certain chronic diseases, and toxic substances that cause depletion in the account RBC which produce via the bone marrow, the oral administration and intraperitoneal injection of Ag NPs cause toxic effect on RBC (9).

The effect of AgNPs on hemopoietic system lead to decrease in the number of RBCs. Additionally, AgNPs which cause disturbances on the function of immune system (10,11). The slight decrease in the red blood cell and Hb may have been resulted from the suppression of circulating hormone, erythropoietin (a glycoprotein which stimulates the process of erythropoiesis) (12). Reduction in blood concentration of erythropoietin may result in a normochromic, normocytic anemia (13). Although iron deficiency is by far the most common cause, the hypochromic anemia is a generic term for any type of anemia. (14).

Macrocytic RBCs are abnormal caused due to a variety of illnesses. Abnormal red blood cells codocyteare seen in association with some forms of anemia (15). Platelets (thrombocytes) have important role on coagulation of blood

so the increase of platelets count lead to thrombus formation with in the blood vessels that promote the progression of atherosclerosis which results from the administration of AgNPs (16).

Hemolysis is the rupture of erythrocytes. This will lead to release of their contents (like hemoglobin) into surroundings the area (17), which failure disturbance decrease in function anemia, jaundice and renal failure (18). Macrocytosis is the first abnormality can be seen in complete blood counts of patients with folate or vitamin B12 deficiency. Tear drop shaped cells may indicate myelofibrosis; anemia decrease in the function of bone marrow in producing which cause by toxin effect. The reason high of plasma proteins, primarily fibrinogen, and globulins is rouleaux formation. It is seen in a variety of infectious and inflammatory disorders associated with polyclonal increases in globulins and/or increased levels of fibrinogen.

Rouleaux formation associated with monoclonal gammopathies can be seen in multiple myeloma and in malignant lymphomas such as Waldenstrom's macroglobulinemia.

The abnormal morphology of BCRs occur due to disturbances in function of bone marrow which caused by pathological processes of this will lead to formation of macrocytic RBC. Otherwise the Hypochromic erythrocytes was occurred due to failure hemoglobinization of erythrocytes in the bone marrow. White stomatocytes which appears bowl shape in three-dimensional views. these cells are appeared in an intermediate form in the transformation of diskocytes to spherocytes. Acanthocytes can be seen in patient suffered from chronic alcoholic liver disease also caused by deficiency of pyruvate kinase form. While the oval shape of RBCs is caused by abnormal proteins of membrane.

This occur due to disorder Infiltration of the bone marrow with disruption of vasculature of the marrow, are associated with the formation of oval and teardrop erythrocytes. Bite cells apparently arise when a phagocyte removes a portion of the red cell along with a Heinz body (19).

Several authors have suggested that silver nanoparticles link to sulfur and phosphorus containing biomolecules like DNA or other biological moieties, so that cause cell toxicity (20). Anther searchers have shown the cytotoxicity of silver nanoparticles related to free radical formation which causes distortion in cell membrane (21). Also, Ag nanoparticles cause low metabolic activity and have toxicological properties (22).

The chemical structure of nanoparticle, shape, size, agglomeration, surface, and function are the factors which effect the biokinetics of silver nanoparticles cytotoxicity effect (23). So, the toxic effect of silver nanoparticles is due to the direct interaction of it with the RBCs which it causes oxidative stress, membrane injury than hemolysis. However, taxological information has other effects on red blood cells (RBCs) and the mechanisms involved remain scant (24,25).

The toxic effects of Ag nanoparticles are hemolysis as membrane injury, lipid peroxidation with fair the production of antioxidant enzyme. The smallest size of AgNPs has ability to induce hemolysis and membrane destruction (24). The results of this study show that the size and the concentration of AgNPs are predisposing factor that affects the RBC by the interaction between erythrocytes and AgNPs.

Conclusion

We concluded that oral administration of AgNPs caused decreased in the level of Hb concentration, PCV, RBC, MCV, MCH, MCHC, but increase PLTS and WBCs. It means that AgNPs has a toxic effect on blood.

Acknowledgment

We would to express our grateful thanks to college of veterinary medicine and College of Education for Girls for their support of this study.

Conflict of interest

The current study included teamwork by researchers, as the work was done with the participation of all researchers to complete the results of the research and write it.

References

- Chen X, Schleusener HJ. Nanosilver: a nanoparticle in medical application. *Toxicology Lett.* 2008;176:1-12. Doi: [10.1016/j.toxlet.2007.10.004](https://doi.org/10.1016/j.toxlet.2007.10.004)
- Lok CN, Ho CM, Chen R, He QY, Yu WY, Sun H, Tam PK, Chiu J, Che C. Silver nanoparticles: Partial oxidation and antibacterial activities. *J Biol Inorg Chem.* 2007;12:527-534. Doi: [10.1007/s00775-007-208-z](https://doi.org/10.1007/s00775-007-208-z)
- De Jong WH, Borm PJA. Drug delivery and nanoparticles: Applications and hazards. *Int J of Nanomed.* 2008;3(2):133-49. Doi: [10.2147/ijn.s596](https://doi.org/10.2147/ijn.s596)
- Choi J, Reipa V, Hitchins VM, Goering PL, Malinauskas RA. Physicochemical characterization and in vitro hemolysis evaluation of silver nanoparticles. *Toxicol Sci.* 2011;123:133-143,2011. Doi: [10.1093/toxsci/kfr149](https://doi.org/10.1093/toxsci/kfr149)
- Kumar P, Clark M. *Clinical medicine.* 5th ed. London: WB Saunders Company; 2003. 592 p. ISBN-13: 978-0702025792.
- Meng H, Xia T, George S, Nel AE. A predictive toxicological paradigm for the safety assessment of nanomaterials. *Acs Nano.* 2009;3:1620-1627.
- Culling CF, Allison RT, Barr WT. *Cellular Pathology Technique.* 4th ed. New York: Butterworth; 1985. 642 p. Doi: [10.1016/C2013-0-06260-3](https://doi.org/10.1016/C2013-0-06260-3)
- Reddy MV. *Statistical methods in psychiatry research and SPSS.* Oakville: Apple Academic Press; 2019. 336 p Doi: [10.1201/9780429023309](https://doi.org/10.1201/9780429023309)
- Park E, Bae Y, Kim Y, Choi K, Lee SH, Reapert - dose toxicity and inflammatory responses in mice by oral administration of silver nanoparticles. 2010;30:162-168. Doi: [10.1016/j.etap.2010.05.004](https://doi.org/10.1016/j.etap.2010.05.004)
- Abdelhalim MA, Moussa SA. The dimensional hematological alterations induced in blood of rats in vivo by intraperitoneal administration of gold nanoparticles. *J Nanomed Nanotechnol.* 2012;3(4):138p. Doi: [10.4172/21577.439.1000138](https://doi.org/10.4172/21577.439.1000138)
- Zhang XD, Wu HY, Wu D, Wangm YY, Chang JH, Zhai, Z, Meng A, Liu P, Zhang L, Fan F. Toxicological effects of gold nanoparticles in vivo by different administration routes. *Int J Nanomedicine.* 2010;5:771-781. Doi: [10.2147/IJN.S8428](https://doi.org/10.2147/IJN.S8428)
- Hauck TS, Anderson RE, Fischer HC, Newbigging S, Chan WC. *In vivo* quantum-dot toxicity assessment. 2010;6(1):138-144. Doi: [10.1002/sml.200900626](https://doi.org/10.1002/sml.200900626)
- Rajendran V, Krishnaswamy K. Effect of *Solanum villosum* extract and its silver nanoparticles on hematopoietic system of diethylnitrosamine-induced hepatocellular carcinoma in rats. *Inno J of Health Sci.* 2016;5(1):13-16. ID:212550217.
- Guyton CA, Hall JE. *Textbook of medical physiology.* 10th ed. London: Academic Press; 2000. 730-801 p. ISBN-13: 978-0323597128.
- Tang MS, Wettach GR, Eby CS. Evaluation of a patient with extremely high mean corpuscular hemoglobin and mean corpuscular hemoglobin concentration. *Clin Chem.* 2020;66(3):497-8. Doi: [10.1093/clinchem/hvz036](https://doi.org/10.1093/clinchem/hvz036)
- Gjetting T, Arildsen NS, Christensen CL, Poulsen TT. *In vitro* and *in vivo* effects of polyethylene glycol (PEG)-modified lipid in DOTAP/cholesterol mediated gene transfection. *Int J Nanomedicine.* 2010;5:371-383. Doi: [10.2147/ijn.s10462](https://doi.org/10.2147/ijn.s10462)
- Savage DG, Ogundipe A, Allen RH, Stabler SP, Lindenbaum J. Etiology and diagnostic evaluation of macrocytosis. *Am J Med Sci.* 2000;319(6):343-352. Doi: [10.1016/s0002-9629\(15\)40772-4](https://doi.org/10.1016/s0002-9629(15)40772-4)
- Arzoumanian L. What is hemolysis, what are the causes, what are the effects. The BD Technical Services Department Tech Talk. 2003;2:1-3.
- Dobrovoiskaia MA, Clogston JD, Neun BW, Hall JB, Patri AK, McNeil SE. Method for analysis of nanoparticle hemolytic properties *in vitro*. *Nano Lett.* 2008;8:2180-2187. Doi: [10.1021/nl085615](https://doi.org/10.1021/nl085615)
- George TI, Etzell JE, Bradley KT, Clarke MR, Crossey MJ, Davis BH, Keren DF, Perkins SL, Piscitelli JB, Rizzo KA, Shier LR, Wong AK, Zwick DL, Eberie C, Girgis GM, Salansky S. *Hematology, Clinical Microscopy, and Body Fluids Glossary.* College of American Pathologists: USA; 2012. 1-64 p.
- Morones JR, Elechinguerra JL, Camacho A, Holt K, Kouri JB, Ramirez JT, Yacaman MJ. The bacterial effect of silver nanoparticles. *Nanotechnol.* 2005;16(10):2346-53. Doi: [10.1088/0957-4484/16/10/059](https://doi.org/10.1088/0957-4484/16/10/059)
- Nirmala R, Sheikh FA, Kanjwal MA, Lee JH, Park S, Navamthavan R, Kim HY. Synthesis and characterization of bovine femur bone hydroxyapatite containing silver nanoparticles for the biomedical applications. *J Nano Res.* 2011;13:1917-1927. Doi: [10.1007/s11051-010-9944-z](https://doi.org/10.1007/s11051-010-9944-z)
- Mocan T, Clichici S, Agoston CL, Simon S, Ilie, IR, Biris AR, Muresan A. Implication of oxidative stress mechanisms in toxicity of nanoparticles (review). *Acta Physiol Hung.* 2010;97(3):247-255. Doi: [10.1556/Aphysiol.97.2010.3.1](https://doi.org/10.1556/Aphysiol.97.2010.3.1)
- Chen LQ, Fang L, Ling J, Ding CZ, Kang B, Huang CZ. Nanotoxicity of silver nanoparticles to red blood cell, size dependent adsorption, uptake and hemolytic activity. *Chem Res Toxicol.* 2015;28(3):501-509. Doi: [10.1021/tx500479m](https://doi.org/10.1021/tx500479m)
- Mandeep SB. Nanotoxicity in systemic circulation and wound healing. *Chem Res Toxicol.* 2017;30(6):1253-1274. Doi: [10.1021/acs.chemrestox.7b00068.0](https://doi.org/10.1021/acs.chemrestox.7b00068.0)