

Preliminary Investigation for Intestinal and Blood Parasites in Starlings in Sulaimania Province.

مسح اولي للطفيليات المعوية والدموية في الزرزور في محافظة السليمانية

Abdulrahman, N. R., *Ameen, N. A., * Raoof, H. H.**

*Department of Histopathology, College of Veterinary Medicine, Sulaimania University. (nawz_ra@yahoo.com) (PhD Poultry Diseases), (nzarameen@yahoo.com), (MSc, Poultry Diseases).

**Department of Animal Health, Sulaimani Veterinary Directorate, Ministry of Agriculture and Water Recourses. (dr.herohussien@yahoo.com), (BSc V.M&S).

Abstract

Intestinal tract of 107 Common starling birds have been examined, the birds captured in Sulaimania region during the period from 5/1/2012 to 5/7/2012 for detection of intestinal and blood parasites, at least three blood smears prepared from each birds for detection of blood parasites. The results were; two types of helminths were identified one of each: cestodes *Choanotaenia masculosa* and Acanthocephalan spp., Prevalence rates with these helminthes were 8.56% and 13.91% respectively and concerning to blood parasites there were no parasites detected.

المستخلص

فحصت امعاء و مسحات دموية ل 107 طيرا من الزرزور الشائع (common starling)(*Sturnus vulgaris*) المصطادة في محافظة السليمانية خلال الفترة (2012/1/5 الى 2012/7/5) للتحري عن الطفيليات المعوية والدموية, وعلى الاقل تم عمل ثلاث شرائح دموية من كل طير للتحري عن الطفيليات الدموية. وكانت النتائج كالآتي : العثور على نوعين من الديدان , كل من الديدان الشريطية (*Choanotaenia masculosa*) و المشوكات الرؤوس (*Acanthocephala spp.*) وبنسبة 8,56% و 13,91% على التوالي, وبخصوص الطفيليات الدموية لم يتم العثور عليها في هذا المسح الاولي.

Introduction

Parasitism is an intimate relationship between two different species in which one (parasite) uses the other (host) as its environment from which it derives nourishment. Parasites are a highly diverse group of organisms that have evolved different strategies for infecting their hosts. Some, such as lice and ticks, are found on the external parts of the body (ectoparasites), but most are found internally (endoparasites). Some are microscopic, such as the blood protozoan's (1).

Parasites take nutrients from their host and usually inflict patho-physiology damage that may cause a negative effect on host fitness by reducing growth, reproduction and survival (2). Although this may be true in some cases, there is evidence that infection by intestinal parasites in wild bird can be completely asymptomatic and only affect the host under certain conditions (3).

Acanthocephalans, cestodes and nematodes have mostly been reported in free-ranging and captive large passerines (e.g. thrushes, grackles and starlings). Insect-eating species in particular show more parasitic infections (4).

Blood parasites may be detected on routine screening of apparently healthy passerines and ramphastids, but they are rarely implicated as the primary cause of disease or death. The most commonly encountered blood parasites include *Haemoproteus spp.*, *Leucocytozoon spp.*, *Trypanosoma spp.*, *Plasmodium spp.* (malaria) and *microfilaria* (4).

Since, wild birds including rooks, pheasants, robins, jays, crows, magpies, and starlings can act as reservoir hosts .These reservoirs have been implicated as the source of outbreaks on game

bird, particularly pheasant , as well as range poultry (5), therefore, the aim of this survey is to investigation for intestinal and blood parasites in starlings in Sulaimania province

Materials and Methods

Blood samples were collected from the wing vein with the help of syringe and needle, three thin blood smears were made immediately after the collection of blood for each bird. The smears then air dried and fixed in absolute methanol for 3 min after that stained with Giemsa's stain as per standard method (6). The slides were examined under microscope (40× and 100×) for the detection of blood protozoa.

In Hospital of Sulaimania University, the alimentary tracts of 107 captured starling birds (*Sturnus vulgaris*) were examined carefully for gastrointestinal helminthes. After that, the opened parts of intestinal tract were put in glass jars containing normal saline (0.85%) in water bath at 37°C for 10-15 min, to help the helminths to separate from the mucosal layer of the intestinal wall, and then will be easy to collected and examined by using dissecting microscope according to (7). collected helminths were kept in plates containing normal saline (0.85%) and then based on the type of the helminths the fixation stage was done on them.

For acanthocephalans after relaxation, the helminths were stored in ethanol 70 percent for identification, but for cestodes, after relaxation, they were killed and fixed in hot formalin and after a few hours, they were stored in ethanol 70 percent for identification with the help of reference key books (8 , 9).

Results and Discussion

The intestinal tracts of 107 starling birds (*Sturnus vulgaris*) were examined and we found two types of helminthes (cestodes and acanthocephalae) as shown in the table-1. The morphology of each one is shown in figures 1 and 2 respectively.

Table 1: shows No. of examined birds, Helminths Spp., No. of infected birds and Prevalence rate%

No. of examined birds	Helminths Spp.	No. of infected birds	Prevalence rate%
107	<i>Choanotaenia masculosa</i>	8	8.56%
	Acanthocephalan spp.	13	13.91%
Total		21	22.47%

Cestodes helminthes (*Choanotaenia masculosa*), these cestodes founded in the alimentary canal of 8 birds, this result is in accordance to the results mentioned by (10) in Baghdad city that starling birds were infected by this species of helminthes, previously, other author reported cestodes infection in migratory birds (*St. vulgaris*) in Iraq (7).

The second species helminths that found in this investigation was Acanthocephalans spp, and founded in intestinal tract of 13 birds.

The helminth referred to as thorny-headed worms because both the larval and adult parasites have a retractable proboscis or a tubular structure at the head, which has sharp, recurved hooks or spines. Much like the cestodes or tapeworms, they lack digestive tracts and absorb nutrients from the bird's intestinal canal. This may weaken the bird and may make it more susceptible to other diseases and to predation and found in a variety of bird species (1).our record is accordance to firstly reported (Acanthocephalans) by (7) in Erbil-city- Iraq and secondly reported by (10) in Baghdad city – Iraq, furthermore, the helminth was reported in many birds in many parts of the world; (11) reported this parasite in Europe, in Australia by (12).

There were no mixed infections detected in this Preliminary Investigation.

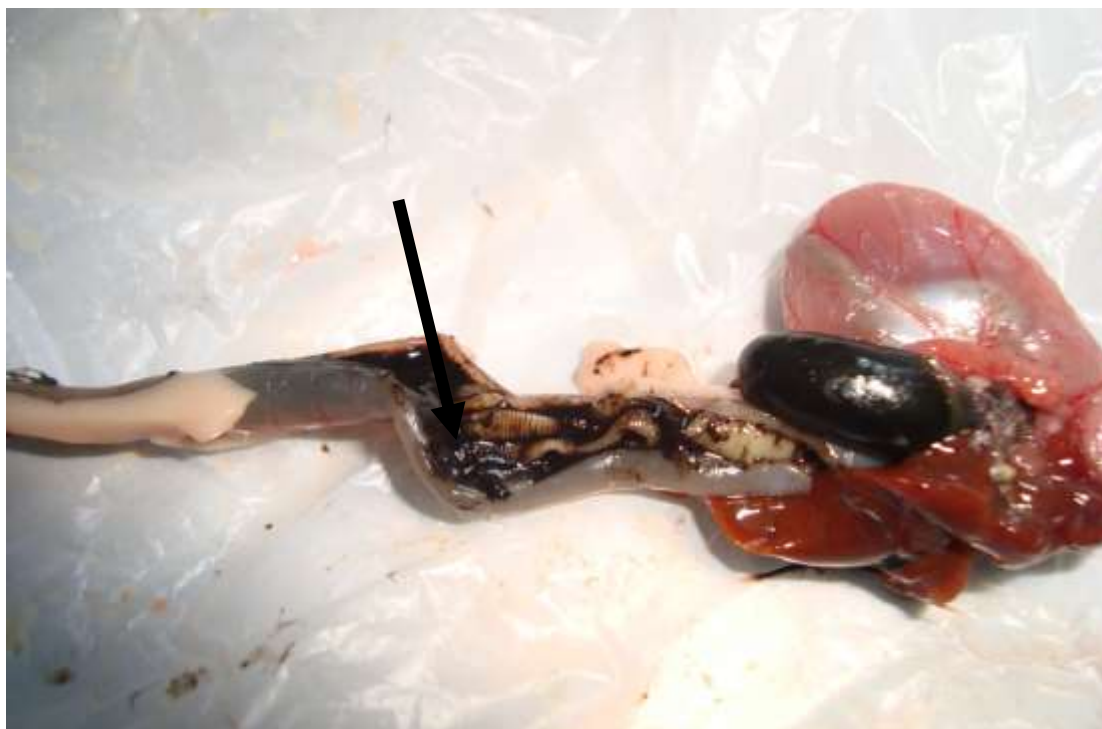

Fig (1) *Choanotaenia masculosa* (arrow) was identified in the intestinal tract of starling.



Fig (2) *Acanthocephalan* spp. (arrow) was identified in the intestinal tract of starling.

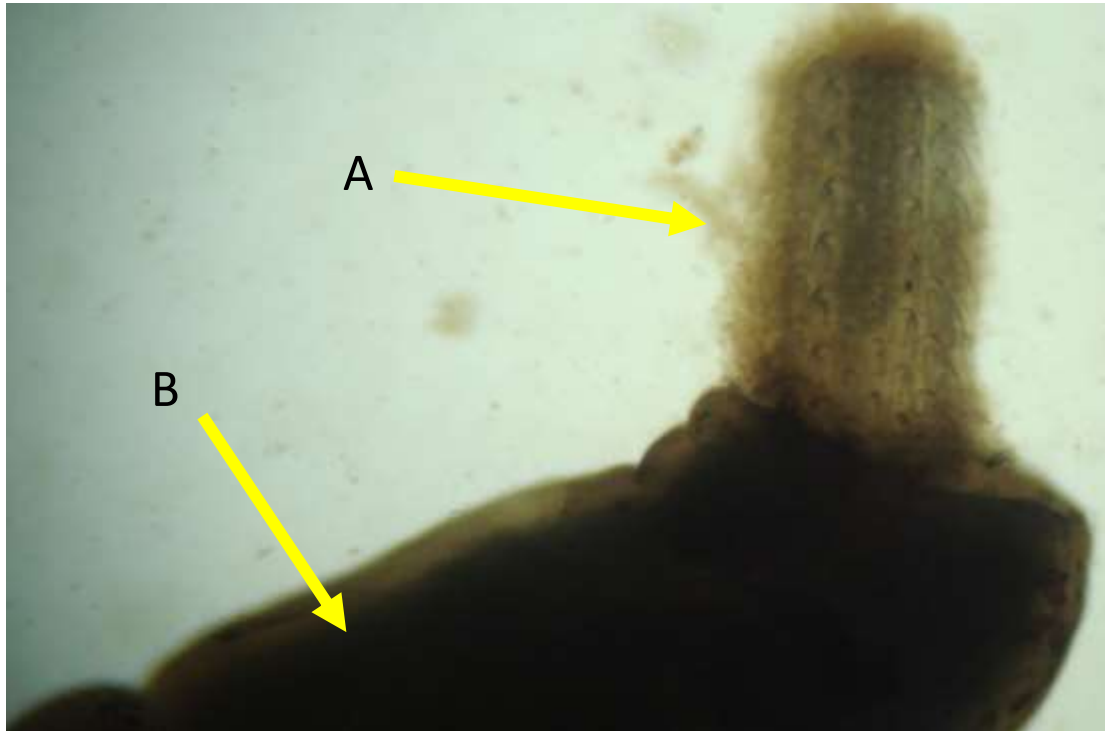


Fig (3) spiny-headed Acanthocephalan. A- Spiny proboscis by which the parasite attaches to the intestine of its host, B- body of the parasite.

Hematological pictures showed that there were no blood parasites present in these 107 examined birds (Common Starling), the interpretation of this result is resemble to what explained by (13, 14 , 15) that; some avian families appear to be more susceptible than others. For example, ducks, geese and swans are commonly infected with species of *Haemoproteus*, *Leucocytozoon*, and *Plasmodium*, and more than 75 percent of waterfowl species that were examined were hosts for one or more of these parasites. Wild turkeys in the eastern United States are also commonly infected by these parasites. Pigeons and doves have similar high rates of infection, but members of other families, such as migratory shorebirds, are less frequently parasitized, also (16) reported that Among the 116 wild species of birds observed they were found that only eight wild birds from three different species were actually infected with the *Plasmodium* species, (Starling birds were within non infected birds in their results). Furthermore, in winter the Common Starling is a widespread visitor to Iraq (17), and cold temperatures prevent the occurrence of suitable insect vectors, and transmission depends upon the availability of vector populations (1) so that this explanation a good support to our results and a results showed by (16).

References

1. Holmstad, P. R.; Hudson, P. J. and Skorpung, A. (2005). The influence of a parasite community on the dynamics of a host population: a longitudinal study on willow ptarmigan and their parasites. *Oikos*, 111(2): 377-391.
2. Tully T. N., Dorrestein, G. M. and Jones, A. K. (2000). Hand book of avian medicine, Composition by Genesis Typesetting, Laser Quay, Rochester, Kent Printed and bound by MPG Books Ltd, Bodmin, Cornwall, Sec. edi., pp: 237- 265.
3. Cole, R. A. and Friend, M. (1999). Parasites and Parasitic Diseases (Field Manual of Wildlife Diseases) section:5, p188-258, University of Nebraska – Lincoln DigitalCommons@University of Nebraska lincoln.
4. Ritchie, B. W. and Harrison, L. R. (1994). Avian medicine principle of application (vol. 1). lake worth, florida: Wingers Publishing Inc.
5. LeaMaster, B. R. (2007). Parasites Important to Poultry in Hawaii and Their Control. Cooperative Extension Service, College of Tropical Agriculture and Human Resources, University of Hawaii at Manoa. P:5.
6. Campbell, T. W. (1995). Avian Hematology and Cytology, 2nd ed. Iowa State University Press: Ames, IA.
7. Molan, A.I.; Isam, S.; Kusai. M. and Saeed, A.R.K.(1986). A survey for parasitic helminthes in the digestive tract and body cavity of the migrating birds *S. vulgaris* in Erbil city. Iraq. Procc. 4th. sci-conference. sci. Res. Council, 267-278.
8. Soulsby, E.J.L. (1982). Helminths, Arthropods and Protozoa of Domesticated Animals, 7th ed. Baillière Tindall, London.809 pp.
9. Anderson, R.C.; Chabaud, A.G. and Willmott, S. (2009). Keys to the nematode parasites of vertebrates. CABI 449-463 pp.
10. Saeed, A.R. K., Ibrahim Z. A. A. and Baban, A.F. (2003), preliminary investigations for the parasitic helminths of the starling *Sternus vulgaris* in alrashdia district (Baghdad), Dept. Clin. Pathol., Technical Institute, Al-Mansur, Baghdad, Iraq, Bull. Iraq nat. Hist. Mus, 10 (1): 89-95.
11. Meyer, A. (1932), Acanthocephala, Bronn's klass. U. ordn. D., Tierreicus. v.4, Abt, 2, Buch,2. lief, I, 1-332, Akedmische Verlag sqesellschaft, Leipzig.
12. Johnston, T.H. and Edmonds, S.J. (1947), Australia Acanthocephala, At, 51, Roy, Soc. south. Australia, 71(I) :13-19.
13. Greiner, E.C. (1991). Leucocytozoonosis in waterfowl and wild galliform birds: Bulletin of the Society for Vector Ecology, 16: 84–93.
14. Atkinson, C.T. and van Riper, C. III.(1991). Pathogenicity and epizootiology of avian haematozoa: Plasmodium, Leucocytozoon, and Haemoproteus, in Loye, J.E., and Zuk, M., eds., Bird-parasite interactions, Ecology, evolution, and behavior: New York, Oxford University Press, PP: 19–48.
15. Bennett, G.F.; Whiteway, M. and Woodworth-Lynas, C.B.(1982). Host-parasite catalogue of the avian haematozoa: Memorial University of Newfoundland Occasional Papers in Biology Number 5, p. 243.
16. Karamba, K. I.; Kawo A. H.; Dabo N. T and Mukhtar M. D. (2012). A survey of avian malaria parasite in Kano State, Northern Nigeria, Department of Biological Sciences, Bayero University, Kano, Nigeria. International Journal for Biotechnology and Molecular Biology Research , 3(1): pp. 8-14.
17. Ctyroky, P.(1986).Breeding assemblages of birds in Iraq. Zpravy Moravskeho Ornithologickeho Sdruzeni, 44: 7–29.