

The Biochemical and Histological Effects of Tramadol on Liver and Kidney of Albino Mice

Zahraa Zuhair Muslim*

*Assistant Lecturer / Kut Technical Institute

Abstract

The aim of this study is to assess the effect of usage of tramadol in liver and kidney in albino mice. Twenty albino mice were taken (25-30) gm and divided in to two groups, group I (10 mice) which received normal saline intramuscularly and group II (10 mice) which received (25 mg /kg body weight) daily of tramadol intramuscularly for 40 days, the biochemical assay showed significant increase (p value < 0.05) in the Aspartate aminotransferase (AST), alanine aminotransferase (ALT), Urea and Creatinine in experimental group compared to the control group. The histological examination regarded for liver tissues degenerative changes in the hepatocytes, dilated central vein, focal necrotic area, congested vessel, congested hepatic vein and cytolysis while kidney tissues show widening bowman capsule, interstitial nephritis, necrosis, degenerative change, lymphocyte infiltration in renal interstitial nephritis and degenerative changes in renal proximal tubules.

Introduction

Tramadol is a synthetic, centrally-acting opioid agonist that also acts as a serotonin and norepinephrine reuptake inhibitor. Its mechanism of analgesic action is rather complex. The analgesic action of tramadol and other clinical effects are believed to be via both opioid and non-opioid mechanisms. Tramadol exerts its action through binding to the μ -opioid receptor, however, its action is less than that of morphine [1]. Tramadol does not fit in the standard opioid classes. A unique analgesic, tramadol is an atypical opioid, a 4-phenyl-piperidine analogue of codeine, with partial mu agonist activity in

addition to central GABA, catecholamine and serotonergic activities. [2]. Tramadol metabolism takes place in liver by the enzyme system cytochrome p450. In general, tramadol is metabolized via O-demethylation, N-demethylation, glucuronidation, and/or sulfation. N-demethylation is done by CY2B6 and CY3A4 while CYP2D6 is responsible for O-demethylation [3]. Tramadol metabolites are excreted by kidneys [4].

Tramadol is commonly used as the first-line therapy in musculoskeletal pains [5]. and as an alternative agent in osteoarthritis (OA) patients in who have

contraindications to NSAIDs and those with resistant pain to other analgesics [6]. The side effects of tramadol, when compared with other opioids, is less than that of other type of opioids [7]. Screening of drugs for opioids is commonly negative in persons with overdose of tramadol [8]. In about 10% of the patients who takes tramadol, they developed severe unwanted adverse effects [9]. However, this percentage is mostly underestimated, because that drug-induced side effects are difficult to notice due to pre-existing medical disease, several drug usages, and absence of diagnostic standards [10].

In tramadol overdose, lethargy, nausea, tachycardia, hypotension, hypertension, respiratory depression, agitation, seizure, coma, edema, movement disorders, perspiration, dysuria, constipation, dizziness, facial paresthesia, ataxia, headache, blurred vision, hallucination, hyporeflexia and hyperreflexia, itching, diplopia, multi-organ failure, vertigo, palpitation, acute hepatic failure due to fulminant hepatic necrosis, renal failure, and urine retention have been reported [11-12-13]. Dizziness, nausea, vertigo, constipation, and headache are the most common symptoms [14].

The liver and kidney play central role in detoxification and metabolism of drug increases the risks of toxic injury to these organs. Many different mechanisms lead to hepatotoxicity, including disruption of the cell membrane and cell death resulting from covalent binding of the drug to cell proteins, which creates new adducts that serve as immune targets, thus inciting

an immunologic reaction. [15]. Chronic administration of tramadol in experimental model have been associated with elevation of renal indices like blood urea and serum creatinine. [16].

Materials and methods

1- Type of study:

The present study was experimental design conducted to evaluate the biochemical and histopathological effects of Tramadol injection on liver and kidney.

2- Sample & duration of study:

Twenty mice are used in this experiment and they were left to adapt for two weeks prior to the experiment and were housed in plastic cages maintained at controlled room temperature (22-24 C) with 12-hour diurnal (day and night change) with free access to standard pellet animal diet and tap water. The animals in this experiment injected tramadol for 40 days and the animals were divided into two groups, ten animals in each group, as follows:

Group I: (10 mice) used as control group, each animal received daily normal saline intramuscularly.

Group II: (10 mice) Each animal received 25 mg/kg/body weight daily of tramadol hydrochloride intramuscularly for 40 days.

Both experimental and control groups of mice were dissected after forty days' tramadol treatment.

3- Biochemical studies:

The blood sample (2ml) was collected directly from cardiac puncture to detect the level of liver enzyme (AST & ALT) and kidney enzyme (urea & creatinine) in the

serum. The blood was collected into jelly tube, labeled and centrifuged at 4000 g for 10 minutes. Sera were separated and kept at -20°C until analysis.

4- Instruments

Instruments used in this investigation are balance, dissection set, centrifuge, disposable insulin needles, light microscope and jelly tubes.

5- Histological studies:

Animals from control and treated groups were sacrificed, then they were dissected and the livers and kidneys were

removed and fixed in 10% neutral buffered formalin fixative fluid. Following fixation, specimens were dehydrated, embedded then, sectioned with thickness of 10 microns and then mounted on the clean slides without using any adhesives medium. Sections were stained with Hematoxylin and Eosin for histological examination.

6- Statistical analysis:

Data from treated and control group (10 for each group) were expressed as mean ± standard divisions (M±SD) and analyzed by using the student_ test p value (p< 0.05) considered significant increase.

Results:

Table (1) explains the effect of tramadol on serum of the treated group after administration of 25 mg/kg body weight of tramadol in albino mice. The results show significant elevation (p< 0.05) in the levels of Alanine aminotransferase (ALT) in treated group (51.7 ±15.6) compared to the control group (33.5 ± 9.6) U/L. While the results show highly significantly increased (p< 0.01) in serum aspartate aminotransferase (AST) in treated group (294.9 ± 120.4) U/L compared to the control group (60.0 ± 7.02) U/L.

The biochemical assay of serum creatinine shows significant increased (p< 0.05) in treated group compared with control group with means (0.32 ± 0.08 - 0.49 ± 0.19) in control and treated group respectively (**Table 2**). The blood urea significant increased (p< 0.05) in treated animals and had activities (43.3 ± 12.6 -59.0 ± 15.12) in control and treated group respectively (**Table 2**).

Table (1) show effect of tramadol on Serum Alanine Aminotransferase (ALT) and Serum Aspartate Aminotransferase (AST) * refer to significant differences between compared mean, ** refer to highly significant increase between compared mean.

Variables / Groups	ALT	AST
Group I (control)	33.5±9.6	60.0±7.02
Group II	51.7±15.6*	294.9±120.4**

Table (2) show the effect of tramadol on blood urea and serum creatinine, * refer to significant differences between compared mean.

Variables Groups	Blood urea (mg/dl)	Serum creatinine (mg/dl)
Group I (control)	43.3±12.6	0.32±0.08
Group II	59.0±15.12*	0.49±0.19*

Histopathological results:

The histological examination of liver section of the control group show central vein with normal hepatic cords composed of one layer hepatocytes, in addition to normal appearing portal tract (**fig 1**), while the histological examination of liver of treated animals with tramadol for 40 days (**group II**), showed degenerative changes in the hepatocytes (**Figure2**), dilated central vein (**Figure 3**), focal necrotic area (**Figure 4**), congested vessel (**Figure 5**), congested hepatic vein (**Figure 6**) and vacuolated hepatocytes, degenerative changes, cytolysis (**Figure 7**). while the histopathological examination of renal tissue of mice treated with tramadol showed widening bowman capsule (**Figure 9**), interstitial nephritis (**Figure 10**), necrosis (**Figure 11**), degenerative change (**Figure 12**) and lymphocyte infiltration in renal interstitial tissue (**Figure 13**).

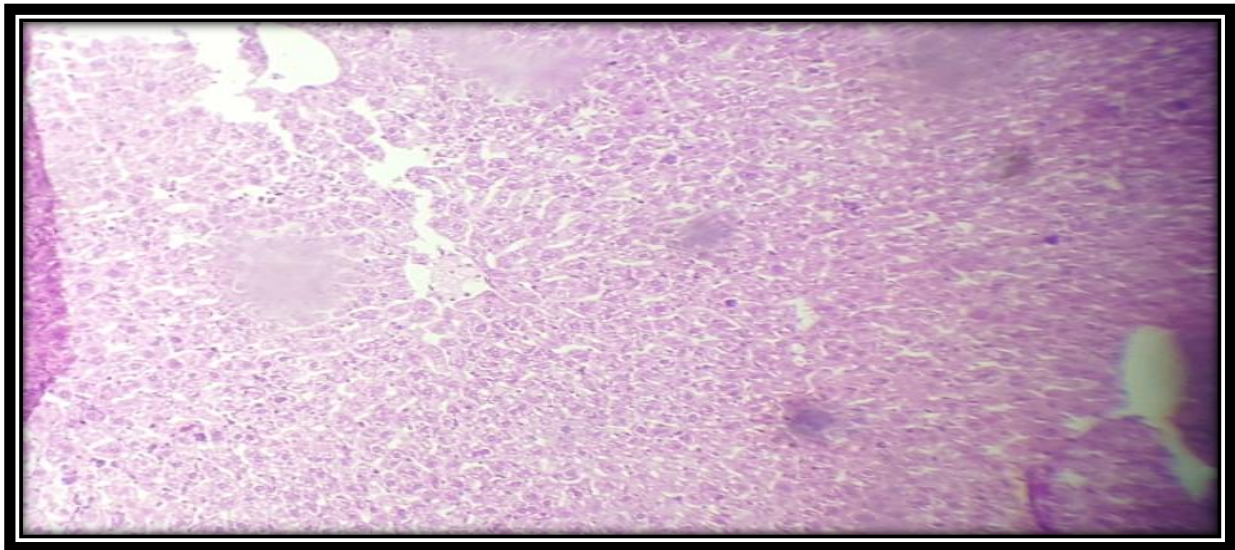


Figure (1) photomicrograph of liver section of control group show showing normal hepatic tissue hepatocytes, normal hepatic cords, normal central vein and normal appearing portal tract (X10, H&E)

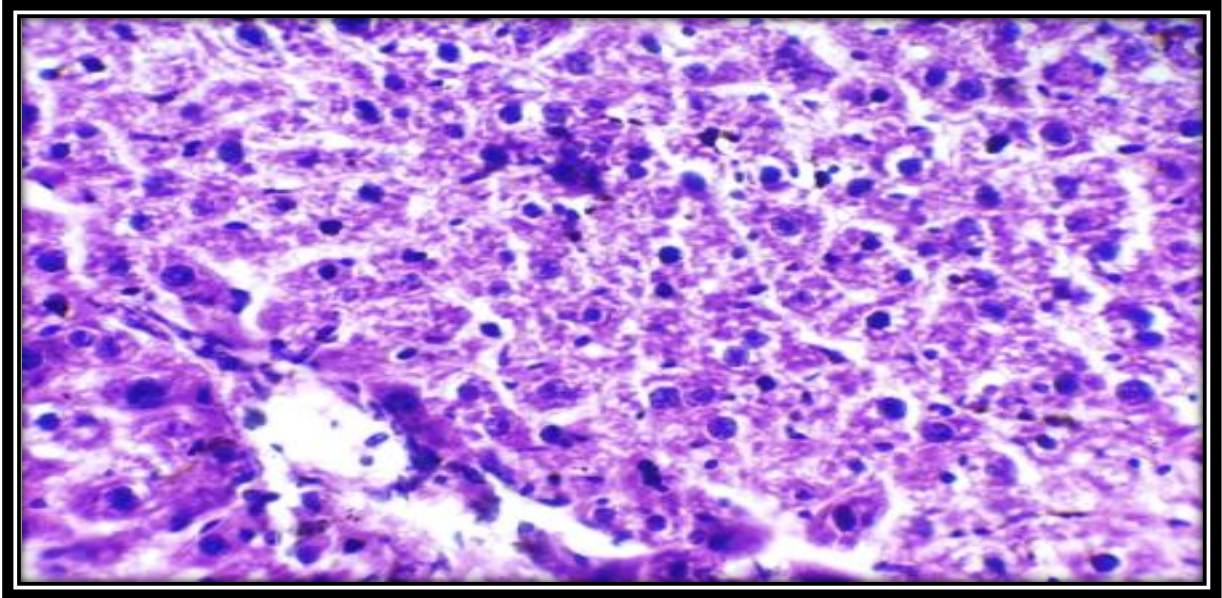


Figure (2) photomicrograph of liver section of experimental group treated with 25 mg/kg body weight of tramadol for 40 days' show degenerative changes in the hepatocytes.

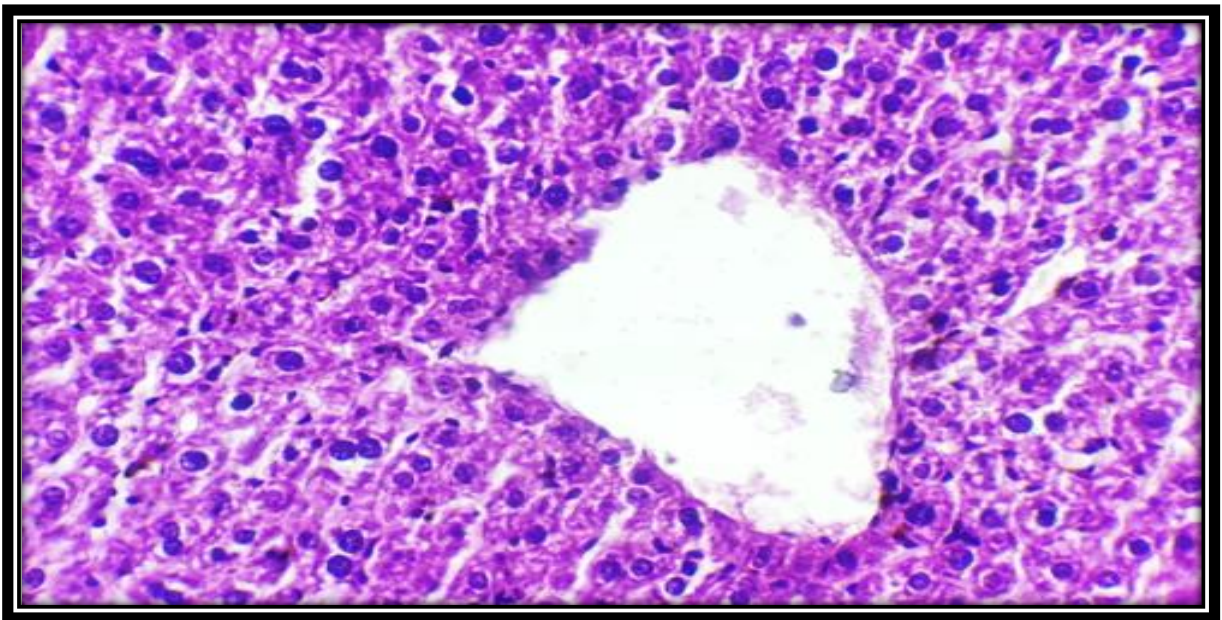


Figure (3) photomicrograph of liver section of experimental group treated with 25 mg/kg body weight of tramadol for 40 days' show dilated central vein (high power)

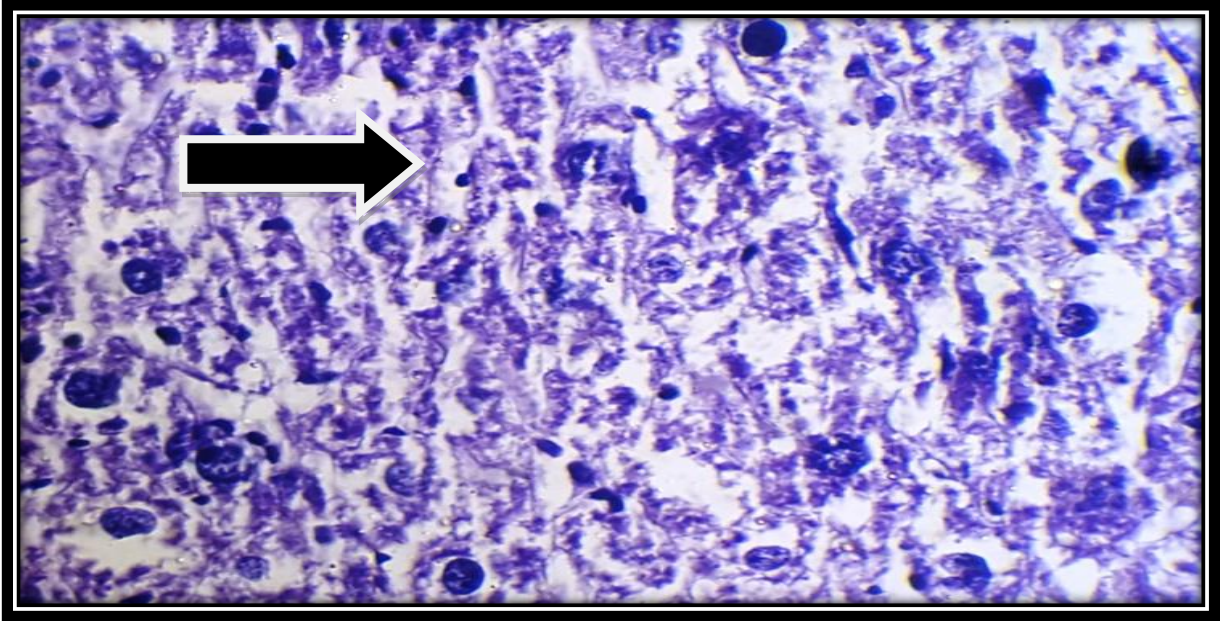


Figure (4) photomicrograph of liver section of experimental group treated with 25 mg/kg body weight of tramadol for 40 days' show focal necrotic area → arrow

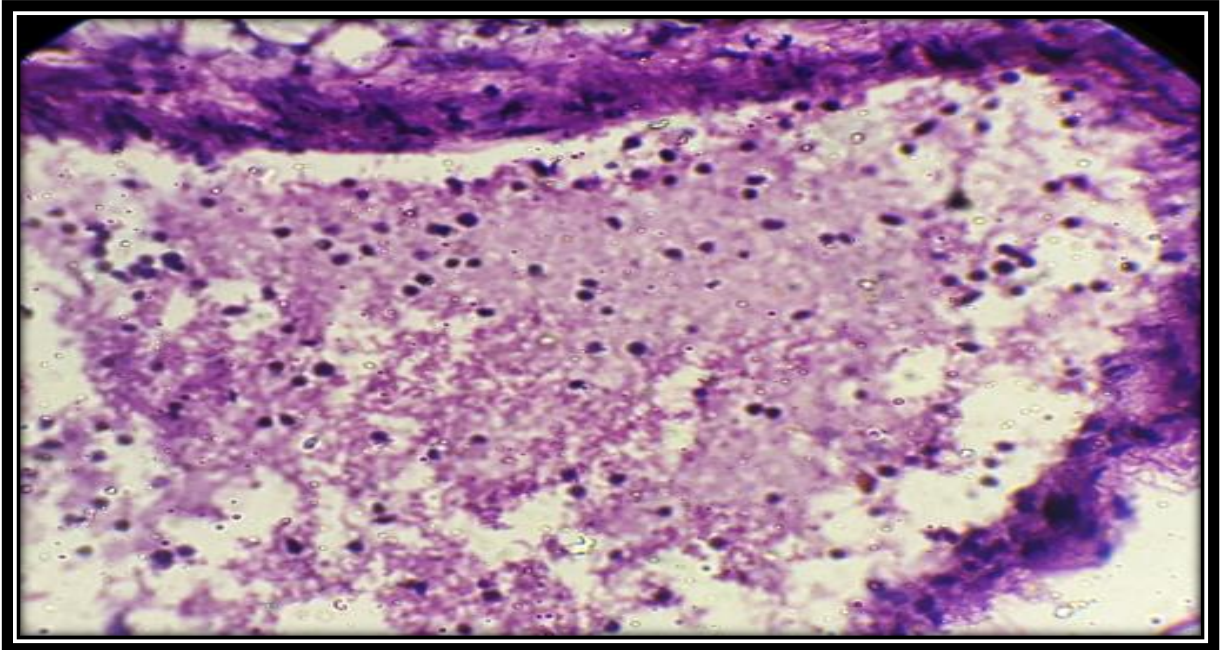


Figure (5) photomicrograph of liver section of experimental group treated with 25 mg/kg body weight of tramadol for 40 days' show congested vessel (high power)

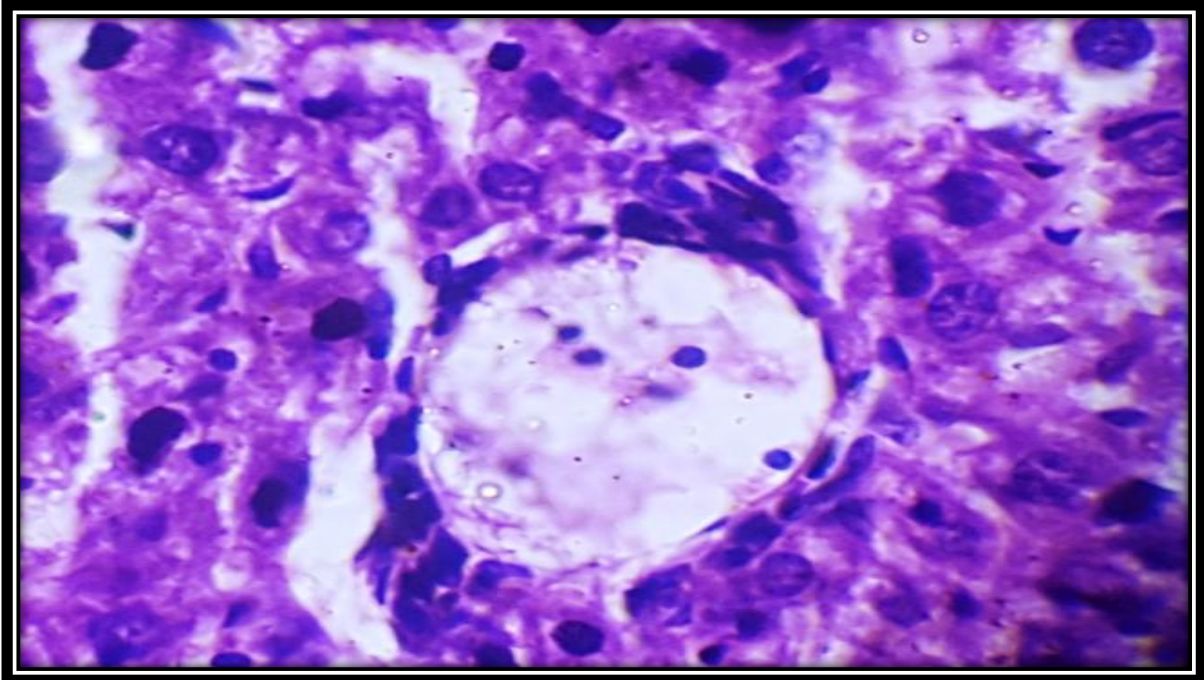


Figure (6) photomicrograph of liver section of experimental group treated with 25 mg/kg body weight of tramadol for 40 days' show congested hepatic vein

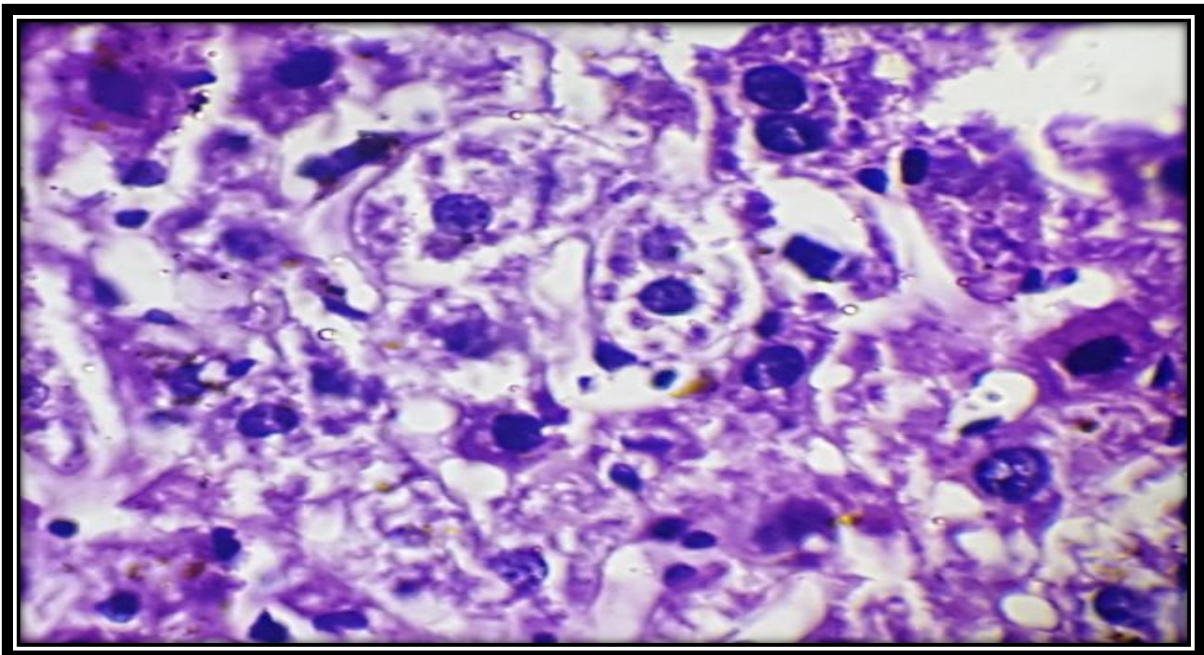


Figure (7) photomicrograph of liver section of experimental group treated with 25 mg/kg body weight of tramadol for 40 days' show vacuolated hepatocytes → degenerative changes → cytolysis

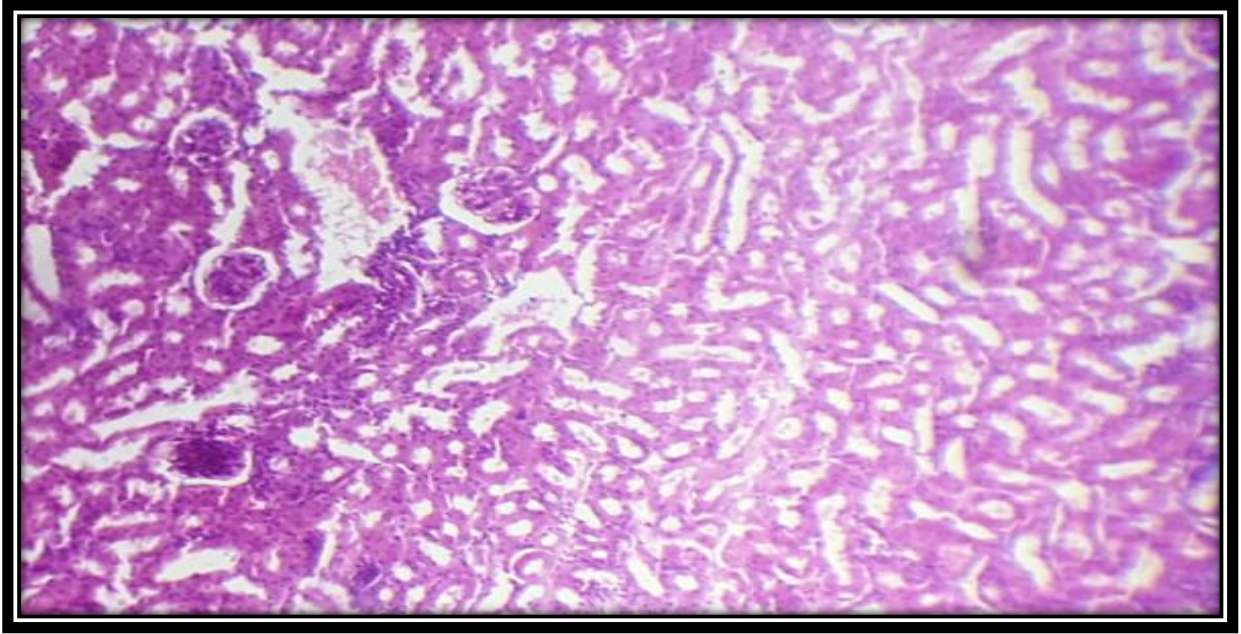


Figure (8) photomicrograph of kidney section of control group show normal appearing glomeruli and tubules of the kidney...4x10

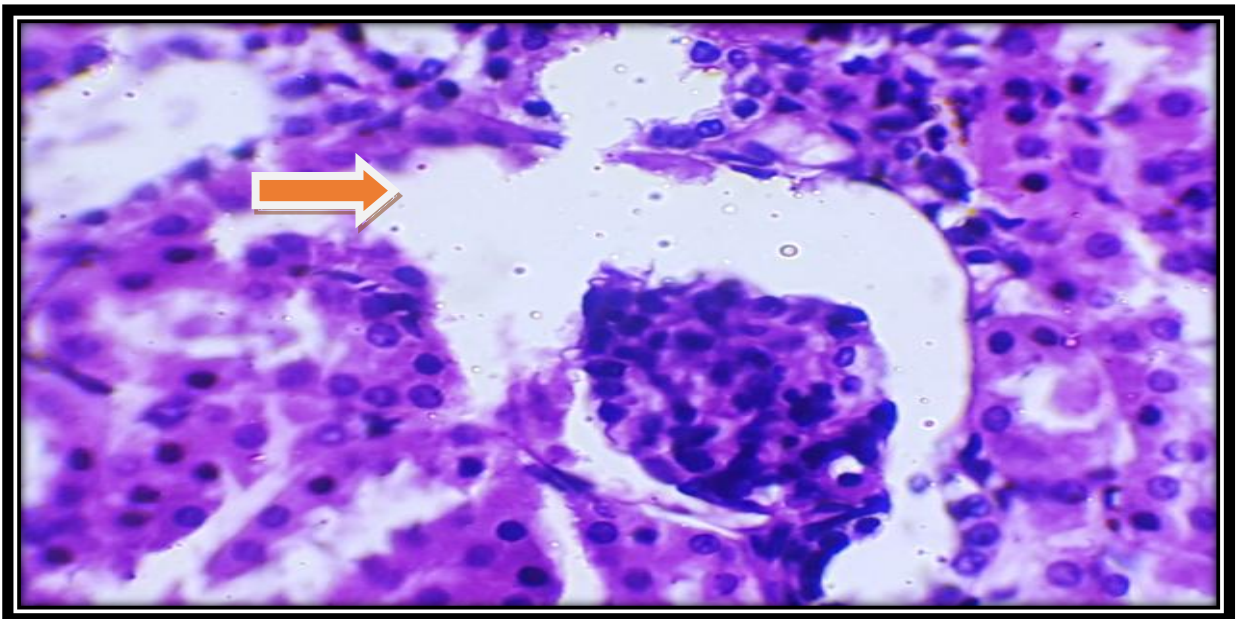


Figure (9) photomicrograph of kidney section of experimental group treated with 25mg/kg body weight of tramadol for 40 days' showed widening of bowman capsule→ arrow

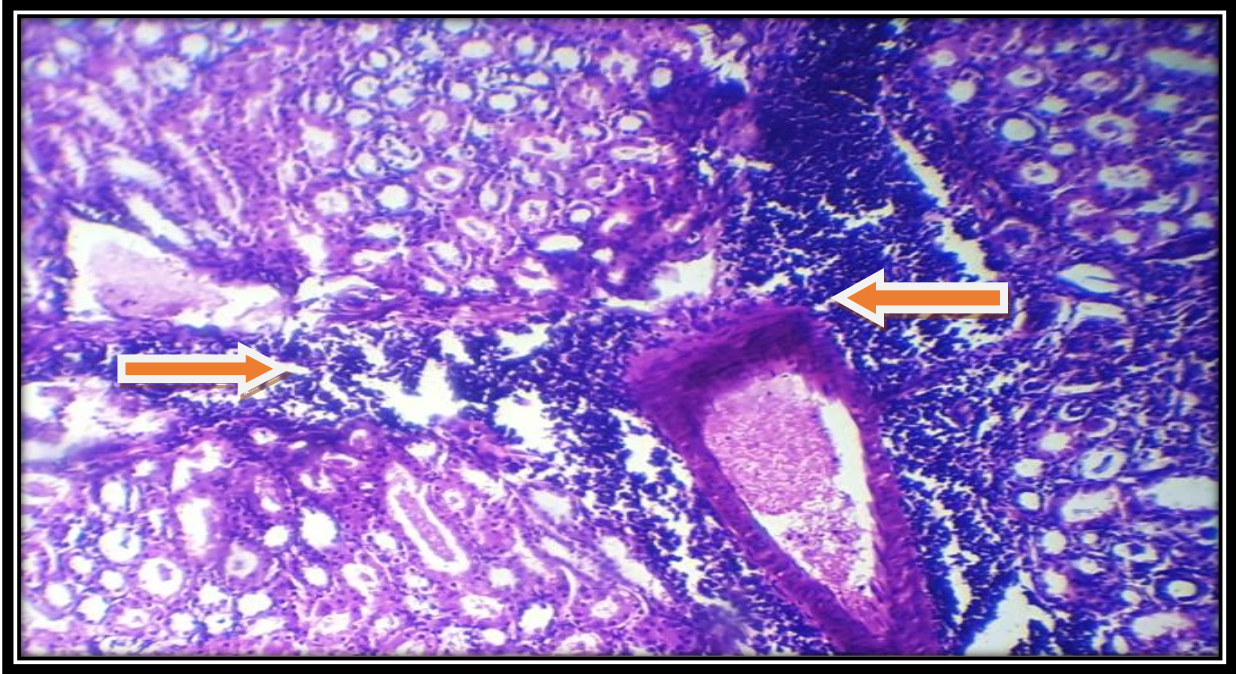


Figure (10) photomicrograph of kidney section of experimental group treated with 25mg/kg body weight of tramadol for 40 days' showed interstitial nephritis → arrows

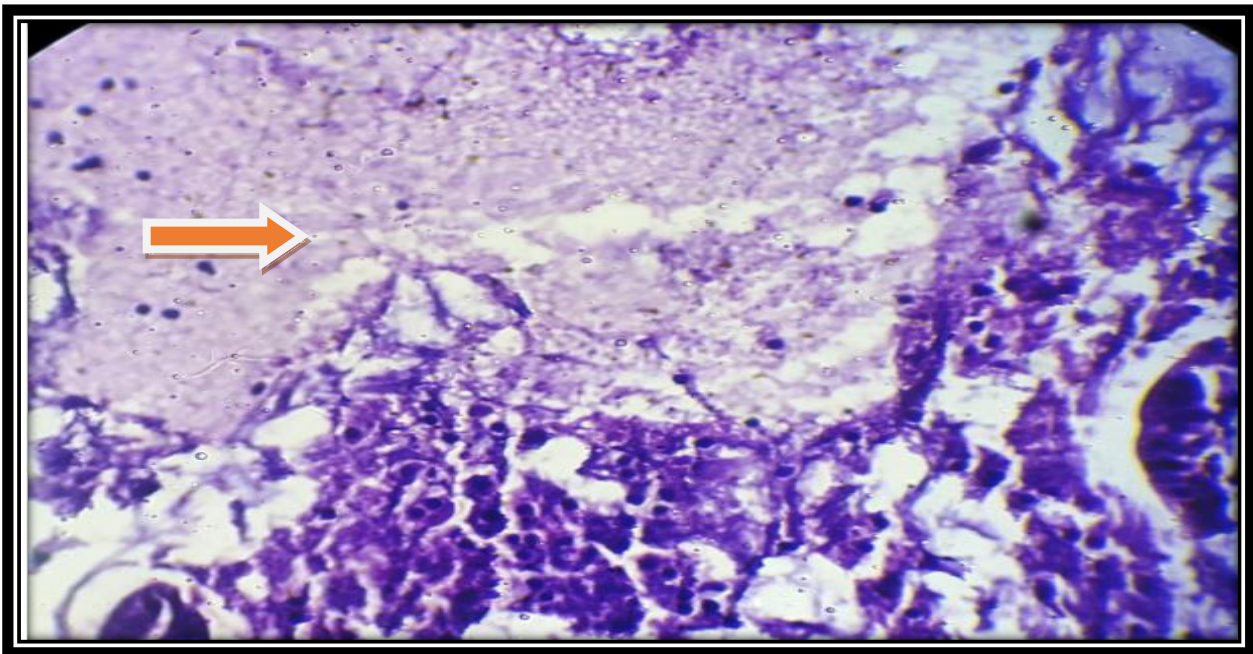


Figure (11) photomicrograph of kidney section of experimental group treated with 25mg/kg body weight of tramadol for 40 days' showed necrosis → arrow

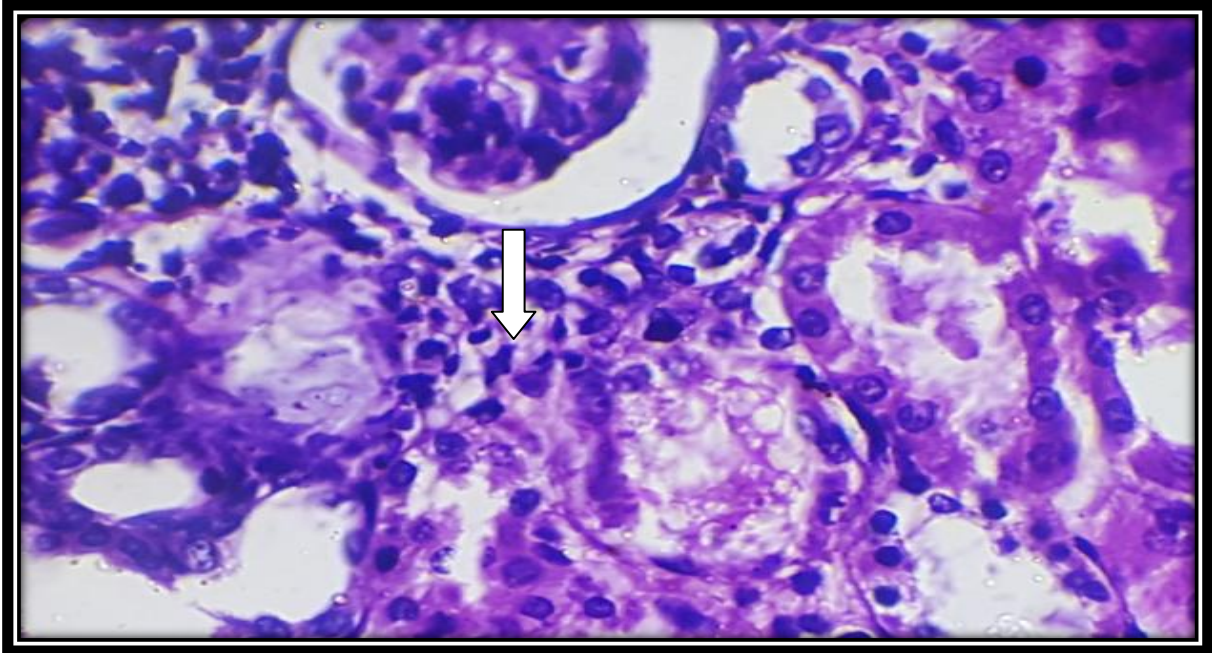


Figure (12) photomicrograph of kidney section of experimental group treated with 25mg/kg body weight of tramadol for 40 days' showed degenerative changes→ arrow

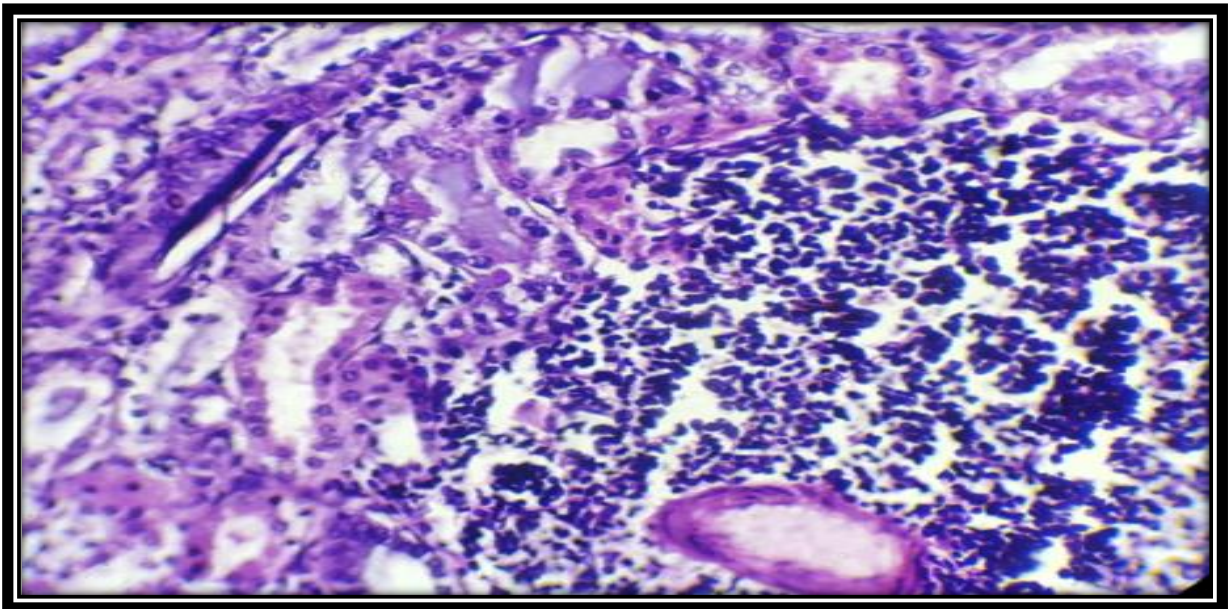


Figure (13) photomicrograph of kidney section of experimental group treated with 25mg/kg body weight of tramadol for 40 days' showed lymphocytes infiltration in renal interstitial tissue. (high power)

Discussion

Tramadol hydrochloride is a morphine derivative agent used widely in clinical settings for alleviating acute and chronic pain [17]. Tramadol is metabolized in the liver and excreted through the kidneys and so may have hepatotoxic and nephrotoxic adverse effects on animal body [18].

The biochemical assay of serum creatinine, urea, ALT and AST, were recorded in mice before and after administration of tramadol at a dose of 25 mg/kg body weight daily for 40 days. The serum Alanine aminotransferase (ALT) activity significantly increased ($p < 0.05$) in experimental group which has been treated with 25 mg/kg body weight compared to the control group (Table 1). Yang, et al 2009 has found an increase in the levels of ALT indicating the malfunction and damage of liver cells. However, its elevation has also been reported in non-liver injury conditions e.g. muscle injury.[19] Furthermore, a significant elevated level of ALT has been found in rats receiving morphine and tramadol for longtime compared to control group.[20] Our findings were also concomitant with the findings shown by another trial conducted on rats treated with morphine-like substance called levo-alpha-acetylmethadol HCl (LAAM).[21] Similar findings have also been documented in chronic heroin users.[22]

Our study revealed highly significant elevation in the levels of aspartate aminotransferase (AST) in the tramadol treated group as compared to

control group. These results were in accordance with another study performed on male rabbits treated with tramadol for 15 days which revealed significant increase in AST level in the experimental group as compared to control group [23]. On the other side, another study conducted by Habibian-Dehkordi et al., (2010) [24], there was no effect on ALT, AST, and ALP levels after short term administration of tramadol.

Aspartate aminotransferase (AST) found in liver, heart, skeletal muscle, kidney, brain and red blood cell. Acute viral hepatitis, ischemic or toxic liver damage might be responsible for elevated level of AST and ALT [25].

As the tramadol is metabolized in the liver by the cytochrome P450 enzymes and its metabolites are excreted in the kidneys [26] elevated levels of ALT and AST shown by this study might indicate the toxic effect of tramadol on the hepatocytes.

The measurement of blood urea and serum creatinine is widely practice to determine the renal function state, however, both of them can be affected by some non-renal conditions. Therefore, the measurement of serum creatinine and blood urea remain the “standard fare” in the evaluation of renal function. [27]. In the current study there is an increase in blood urea and serum creatinine levels in the tramadol treated mice as compared to control group. These findings are consistent with other studies confirming that levels of blood urea and serum creatinine were elevated after tramadol administration in rats [28] and rabbits [23].

But these results were in contrast to results reported by Atici *et al* (2005) [20] who found no significant difference in blood urea and serum creatinine levels between tramadol treated rats and control groups.

Histopathological examination of the liver showed normal liver tissue and renal tissue in the control group (**Figure 1**) and (**Figure 8**) respectively. In the tramadol treated mice group, the histopathological examination showed degenerative changes in the hepatocytes (**Figure 2**), dilated central vein (**Figure 3**), focal necrotic area (**Figure 4**), congested vessel (**Figure 5**) congested hepatic vein (**Figure 6**) and vacuolated hepatocytes, degenerative changes, cytolysis (**Figure 7**). These results could be explained by the liver is responsible for the metabolism and excretion of tramadol [29]. Similar results were demonstrated by other studies of acute and long term treatment of morphine in mature albino rats which revealed that morphine can produce hepatotoxic effects during its metabolism in the form of necrosis; hemorrhage and cytolysis [20]. These findings are consistent with other studies that found degenerative changes of the hepatocytes after tramadol administration in mice [30] [31]. While the histopathological examination of renal tissue revealed widening bowman capsule (**Figure 9**), interstitial nephritis (**Figure 10**), necrosis (**Figure 11**), degenerative change (**Figure 12**) and lymphocyte infiltration in renal interstitial tissue (**Figure 13**) Our results are in agreement with the findings of Atici *et al.* [20], who observed renal tubular vacuolization, mononuclear cell infiltration, focal

necrosis and hemorrhage as well as an increase in creatinine levels in rats receiving opioids. These observations can be considered as evidence of renal damage. This could be explained by the toxicokinetics process of tramadol, since 30% of the drug is excreted through the kidney in an unchanged manner. While the rest are changed into active metabolites by the liver. Metabolites of the drug that are excreted via kidneys may also cause cellular damage leading to kidney dysfunction [16].

References

- [1] Grond S, Sablotzki A. Clinical pharmacology of tramadol. *Clin Pharmacokinet.* 2004;43(13):879–923.
- [2] Trescot A.M., Datta S., Lee M., Hansen H. Opioid pharmacology. *Pain Physician.* 2008;11:S133–S153.
- [3] Afshari R, Afshar R, Mégarbane B 2011. Tramadol overdose: review of the literature. *Ré- animation.*;20(5):436-41.
- [4] Dickman A. Tramadol: a review of this atypical opioid. *European Journal of Palliative Care.* 2007;14(5):181–185.
- [5] Stoops WW, Lofwall MR, Nuzzo PA, Craig LB, Siegel AJ, Walsh SL 2012. Pharmacodynamic profile of tramadol in humans: influence of naltrexone pretreatment. *Psycho-pharmacology (Berl).*;223(4):427-38.
- [6] Schnitzer TJ. Update of ACR guidelines for osteoarthritis: role of the coxibs. *Journal of pain and symptom management.* 2002;23(4):S24-S30.
- [7] Agrawal A, Diwan S, Mahajan R. Severe delirium following single dose of

tramadol. Indian journal of medical sciences. 2009;63(2):80-1.

[8] Goldfrank LR, Flomenbaum N, Lewis NA, Howland MA, Hoffman RS, Nelson LS, editors. Goldfrank's 2000 Toxicologic Emergencies. 7 ed. New York: McGraw-Hill Medical;916.

[9] Shi Q, Hong H, Senior J, Tong W. Biomarkers for drug-induced liver injury, Expert Rev. Gastroenterol. Hepatol., 2010, vol. 4 (pg. 225-234)

[10] Assis DN, Navarro VJ. Human drug hepatotoxicity: a contemporary clinical perspective. Expert Opin Drug Metab Toxicol 2009; 5: 463-473.

[11] Marquardt KA, Alsop JA, Albertson TE. Tramadol exposures reported to statewide poison control system. Ann Pharmacother 2005; 39: 1039-1044

[12] Sanaei-Zadeh H. Tramadol intoxication and shoulder pain. European review for medical and pharmacological sciences. 2014;18(2):285.

[13] Lofwall MR, Babalonis S, Nuzzo PA, Siegel A, Campbell C, Walsh SL. Efficacy of extended-release tramadol for treatment of prescription opioid withdrawal: A two-phase randomized controlled trial. Drug and alcohol dependence. 2013;133(1):188-197.

[14] El-Naggar M, El-Sehly WM, Morad GM, Eeed M, Hassan M. P19: The toxic effect of prolonged Ultram administration on cerebral cortex of albino rats: Toxicological and histological study. Experimental and Toxicologic Pathology. 2009;61(3):290.

[15] Kaplowitz N. Drug-induced liver injury. Clin Infect Dis 2004;38: Suppl 2: S44-S48

[16] Eizadi-Mood N, Ozcan D, Sabzghabae AM, Mirmoghtadaee P, Hedaiaty M. Does naloxone prevent seizure in tramadol intoxicated patients? Int J Prev Med. 2014; 5:302-7.

[17] Lee CR, McTavish D, Sorokin EM. Tramadol. A preliminary review of its pharmacodynamic and pharmacokinetic properties, and therapeutic potential in acute and chronic pain states. Drugs 1993; 46: 313-40

[18] Wu WN, Mcknown LA, Gauthier AD, Jones WJ and Raffa RB. Metabolism of analgesic, tramadol hydrochloride, in rat and dog. Xenobiotica. 2001; 31: 423-441.

[19] Yang RZ, Park S, Reagan WJ. Alanine amino transferase isoenzymes: molecular cloning and quantitative analysis of tissue expression in rats and serum elevation in liver toxicity. Hepatology. 2009; 49: 598-607.

[20] Atici S, Cinel I, Cinel L, Doruk N, Eskandari G, Oral U. Liver and kidney toxicity in chronic use of opioids: An experimental long term treatment model. J Biosci. 2005; 30:245-52.

[21] Borzelleca, J.F., J.L. Egle, L.S. Harries, D.N. Johnson, J.B. Terrill and J.A. Belleville. Toxicological evaluation of mu-agonists. Part 1: Assessment of toxicity following 30 days of repeated oral dosing of male and female rats with levo-alpha-acetylmethadol HCL (LAAM). Journal of Applied Toxicology. 1994; 14: 435-446.

[22] Panchenko L. F., S.V. Pirozhkov, A.V. Nadezhdin, V.I. Baronets and N.N. Usamanova. Lipid peroxidation, peroxyl radical-scavenging system of plasma and

liver and heart pathology in adolescence heroin users. *Vopr.Med. Khim.* 1999; 45:501-506.

[23] Obed Khalid Ali, AL- Jmor Sara Ahmed, Al-Graibawi Mawlood. A. A. Effects of Tramadol on Histopathological and Biochemical Parameters in Male Rabbits. *American Journal of Biology and Life Sciences.* Vol. 3, No. 3, 2015, pp. 85-90.

[24] Habibian- Dehkordi S, Bigham-Sadegh A, Abaspour A, Beigi Brojeni N. Intravenous administration of tramadol hydrochloride in sheep. *J Comp Clin Pathol.* 2010; 21: 289- 293

[25] Giannini, E.G., R. Testa and V. Savarino. Liver enzyme alteration: a guide for clinicians *Canadian Medical Association Journal.* 2005; 172(3): 367-379.

[26] Shadnia S, Soltaninejad K, Heydari K, Sasanian G, Abdollahi M. Tramadol intoxication: a review of 114 cases. *Hum Exp Toxicol.* 2008; 27: 201-205.

[27] Lyman, J.L. Blood urea nitrogen and creatinine. *Emergency Medicine Clinics of North America.* 1986; 4(2): 223-33.

[28] El-Gaafarawi I.I. Biochemical effects of some analgesics. *Egypt. J. Hosp. Med.* 2006; 21:16–32.

[29] Shah NH, Thomas E, Jose R, Peedicayil J. Tramadol inhibits the contractility of isolated human myometrium. *Auton Autacoid Pharmacol.* 2013; 33:1–5.

[30] Albarakai, A.Y. & Abd Elrhman Alsbery, H.M. Evaluation of the hepatoprotective efficacy of *Moringa oleifera* on tramal-induced liver toxicity in animal modules. *Research Journal of Pharmaceutical, Biological and Chemical Sciences.* 2016; 7. 1494-1501.

[31] Youssef SH, Zidan AHM. Histopathological and Biochemical Effects of Acute and Chronic Tramadol Drug Toxicity on Liver, Kidney and Testicular Function in Adult Male Albino Rats. *J Med Toxicol Clin Forensic Med.* 2016;1:2

التاثيرات النسيجية و الكيموحياتية للترامال على الكبد والكلية في فئران الالبينو

زهراء زهير مسلم

الخلاصة:

ان الهدف من هذه الدراسة هو تقييم التاثير الناتج من استخدام الترامال على الكبد والكلية في الفئران البالغة, حيث استخدم في هذه التجربة (20) فار حيث قسمت الى مجموعتين , المجموعة الاولى (10) فئران عدت كمجموعة سيطرة حيث حقنت بالعضلة بمحلول النورمال سلاين يوميا و المجموعة الثانية (10) فئران حقنت 25 ملغم/ كغم يوميا بالعضلة بمادة الترامال لمدة 40 يوم , اظهرت النتائج التحليلية ارتفاع معنوي في انزيمات الكبد وزيادة معنوية في اليوريا والكرياتينين في المجموعة المعالجة مقارنة بمجموعة السيطرة, اما الفحص النسيجي للكبد فقد بين تغيرات خزبية في الخلية الكبدية وتوسع بالوريد المركزي ومنطقة تنخر بؤري واحتقان للاوعية واحتقان للوريد الكبدي وانحلال خلوي بينما الفحص النسيجي لنسيج الكلية فقد اظهر توسع كبسولة بومان, التهاب الكلية الخلالي ,تنخر, تغيرات خزبية, ارتشاح الخلايا اللمفية في التهاب الخلالي الكلوي وتغيرات خزبية في الانابيب الكلوية القريبة.