

Urokinase Type Plasminogen Activator Receptor Expression In Colorectal Neoplasms

Dr. Rasha Qusai AL-Jawher

rasha-k@utq.edu.iq

Abstract

Background—The urokinase type plasminogen activator receptor (uPAR) may play a critical role in cancer invasion and metastasis.

Aims—To study the involvement of uPAR in colorectal carcinogenesis.

Methods—fourty four cases of colorectal adenocarcinoma were obtained and diagnosed as colonic carcinoma with it's grade received as formalin fixed, paraffin embedded tissue in AL-nassiriyah teaching hospital with cases of carcinoma also 6 cases of normal endoscopic biopsies used as control –ve and 10 cases of adenoma with dysplastic changes all these cases stain by immunohistochemical methods for expression and localisation of uPAR.

Results— all the cases of endoscopic biopsies were –ve for this receptors so used as –ve control, while cases of adenoma 3 out of 10 cases showing focal positivity in areas of dysplasia, while the cases of invasive carcinoma showing diffused positivity and the case percent of positivity depend on grade so high grade tumor showing high percentage of positivity.

Conclusions—Colorectal adenoma uPAR, expressed essentially in dysplastic epithelial cells, was upregulated with increasing severity of atypia, and increased notably during the critical transition from severe dysplastic adenoma to invasive carcinoma. These findings implicate uPAR expression in the invasive and metastatic processes of colorectal cancer.

Introduction

Colorectal cancer (CRC) accounts for one of the highest mortality rates from cancer worldwide. The survival rate is highest at about 90% when diagnosed at early stages where tumor growth is localized to primary sites and about 35%–70% in invasive but regional disease. However the occurrence of distant metastasis to the liver or lungs in CRC is a major contributing factor to death, with five-year survival rate at less than 15%^[1-2]. The pathogenesis of CRC from normal

colonic epithelium to adenoma is fairly well-characterized and often involves a number of genetic alterations, including mutational activation of oncogenes such as K-ras as well as mutational inactivation of tumor suppressors such as p53^[3] and adenomatous polyposis coli (APC) gene^[4]. In contrast, less is known about the molecular mechanisms which convert a non-invasive colorectal neoplasm to one with an invasive phenotype. In most solid tumors, the spread of tumor cells is

facilitated by events which result in the detachment of malignant cells from the primary site and subsequent dissemination through tissues and vasculature [5]. This metastatic cascade is critically dependent on the integration of migratory and invasive signals involving cytoskeleton and extracellular matrix (ECM) remodeling [6]. Colorectal cancer, one of the most prevalent cancers worldwide, is the second leading cause of cancer-related mortality in developed countries. Tumor cell invasion and metastasis are regarded as multi-step phenomena, involving the proteolytic degradation of the basement membrane (BM) and the extracellular matrix (ECM), altered cell adhesion, and the physical movement of tumor cells. Among the many steps in invasion and metastasis, excessive degradation of the matrix is one of the hallmarks of this process [7].

Many proteinases are capable of degrading ECM components, but the proteinase system primarily responsible for ECM degradation in vivo are matrix metalloproteinase (MMPs) and plasminogen activator (PA) systems [8]. These proteinases have been closely linked with the invasive and metastatic phenotype of cancer cells [9]. Urokinase plasminogen activator (uPA) is a 55 kDa serine protease, which is secreted as an inactive pro-enzyme (pro-uPA). It seems that activation of pro-uPA mostly occurs after binding to its receptor uPAR (uPA receptor). Plasminogen activator inhibitors (PAI-1 and PAI-2) inhibit both receptor-bound and free uPA [10]. uPA is found in cellular structures at the leading edge of migrating cells that are involved in

adhesion, migration, invasion, and intravasation [11]. The uPA system is considered to be a marker for malignancy in several types of cancer including colorectal cancer [12-13].

Patient, material and method:

Fourty four cases of primary human colorectal adenocarcinoma were obtained by surgical resection at Al-nassryaha teaching hospital from January 2011-December 2012 included in this study 10 cases of rectal polyps obtained by colonoscopic resections in addition to 6 cases appear as normal endoscopic biopsies taken as _ve control.

The cases of adenoma reveal :

- 1- 4 cases tubular adenoma.
- 2- 3 villous adenoma.
- 3- 3 tubulovillous adenoma.

All these cases were formalin fixed, paraffin-embedded tissue retrieved from the archived files of main laboratory in Al-Nassriyah teaching hospital, reviewed by histopathologist to confirm diagnosis.

The information regarded in this study was age, sex of patients and grading of these tumors, in cases of polyps assessment for the presence of dysplasia also done.

This retrospective study and the samples were collected from archives of histopathology laboratory of al-Nasiriyah teaching hospital, the sex of patients reveal 30 case male and 14 cases female in cases of cancer while their ages range from 32-80 years old, in each case one representative section was stained with hematoxylin & eosin other stain immunohistochemically for uPAR.

H&E stained sections were examined for the type of tumor and histopathological grade, cases of polyp for type of polyp and presence of dysplasia, tumor tissue were histopathologically graded according to the WHO classification to:

- 1- well differentiated (grade I).
- 2- moderate differentiated (grade II).
- 3- poorly differentiated (grade III).
- 4- undifferentiated (grade IV).

So that according to this grading system the cases were classified as following:

- 1- 10 cases diagnosed as well differentiated colorectal adenocarcinoma.
- 2- 20 cases diagnosed as mild to moderate differentiated colorectal adenocarcinoma.
- 3- 14 case diagnosed as poorly differentiated grade III-IV colorectal adenocarcinoma. According to figure (1).

Method of Immunohistochemistry:

The procedure was carried out in accordance with the manufacturer's instructions with minor modifications to optimize the results. The primary Ab used was monoclonal mouse anti-human Urokinase plasminogen activator receptor (uPAR, CD87) clone no. 9B17 (manufactured by Dako). Four microns sections were obtained from formalin fixed-paraffin embedded tissue blocks and mounted on Fisherbrand positively charged slides then the slides were placed in a drying oven (hot air oven) at 65°C overnight deparaffinizing and rehydration then blocked by peroxidase reagent then added of primary antibody, enough primary antibodies was applied onto each section and incubated at 37°C for 60 minutes in humid chamber, and then slides were rinsed with a stream of buffer from a washing bottle, and then placed in fresh

buffer bath for 5 minutes. Slides were rinsed again with buffer then drained and blotted gently then secondary (Biotinylated link) antibody were applied onto the sections and incubated at 37°C for 30 minutes in humid chamber then the slides were rinsed with a stream of buffer from a washing bottle, and then placed in a fresh buffer then streptavidin-AP reagent added then substrate-Chromogen solution applied on each section covering the whole specimen then enough drops of the hematoxylin counter stain solution were applied covering the whole section and incubated at room temperature for 5 minutes then the slides washed, dehydrated and mounting with (DPX) and covered with coverslides and examine by light microscope.

Aims of study —To study the involvement of uPAR in colorectal carcinogenesis.

RESULTS: the male is in high percentage to exposed to colorectal carcinoma than female, the male is 75% while female is 25% according to figure (2).

All the cases of normal endoscopic biopsies was –ve stain for this marker

From the cases of adenomas 3 cases from 10 showing only focal positivity in areas of focal dysplasia 30% of cases.

While the cases of malignancy

- 1- from 10 cases of well differentiated or grade I 4 was positive for the marker and 6 was negative 40%.

- 2- 20 cases of moderate differentiated 15 was positive and 5 negative 75% of cases.
- 3- 14 cases 12 was positive and 2 was negative 84% . according to figure (3).

Discussion

Extracellular proteolytic degradation regulates cancer invasion as well as tissue remodelling under physiological conditions.(14) Numerous clinical and experimental studies have provided evidence of a critical role of the uPA system in cancer invasion and metastasis.(15-16) One of the components of this system, uPAR expression on the surface of tumour cells, has proved to be central to the invasion process and to tumour progression.(17) uPAR is also involved in angiogenesis and tumour growth (18) In contrast with carcinomas, the contribution of uPAR in premalignant lesions has received little attention.

Our study showed both the cellular expression and distribution of uPAR during the progression from colorectal adenomas with dysplasia to invasive carcinoma by immunohistochemical study . In 30% of adenomas, the uPAR marker was focally positive in dysplastic epithelial cells and this result is similar to most of studies on adenoma.while in cases of invasive carcinoma the distribution of immunostain in positive cases were diffused within cell membrane and cytoplasm and the percentage of positivity , this study is different from other study in percentage of positivity other study by

immunohistochemical staining revealed that only 14% of adenomas and 45% of invasive carcinomas displayed immunoreactive signals in both cell membranes and the cytoplasm of dysplastic epithelial or cancer cells, so our study percentage is higher than this study .

much of studies correlate positivity of immunohistochemistry with Duck's staging system but my work and study correlate with grading for prognosis and predict for metastasis in cases of endoscopic inscional biopsies . Furthermore, immunohistochemical study localised the corresponding antigens to adenomatous dysplastic cells or carcinomatous cells. These findings indicate that the main source of uPAR synthesis is essentially dysplastic epithelial or carinomatous cells in colorectal neoplasms. It should be noted that this result differs from earlier studies using in situ hybridisation and immunohistochemistry that have suggested that uPAR is produced by stromal, not dysplastic or malignant epithelial cells.

The increases of uPA content and proteolytic activity have been reported to associate with adenoma-carcinoma sequence.(19-20)

While the incidence and difference between male and female which's 75% for male and 25% for female is not so different from other studies, especially in rectal tumors.

Conclusion:

Taken together, these observations document the contribution of uPAR in colorectal premalignant lesions during

cancer progression. We suggest that uPAR expresses essentially in dysplastic epithelial cells in colorectal adenomas and that the expression is upregulated with increasing severity of atypia in adenomas and increases notably during the critical transition from severe dysplastic adenoma

to invasive carcinoma. These findings implicate uPAR expression in the invasive and metastatic processes of adenocarcinoma of the colon and rectum.

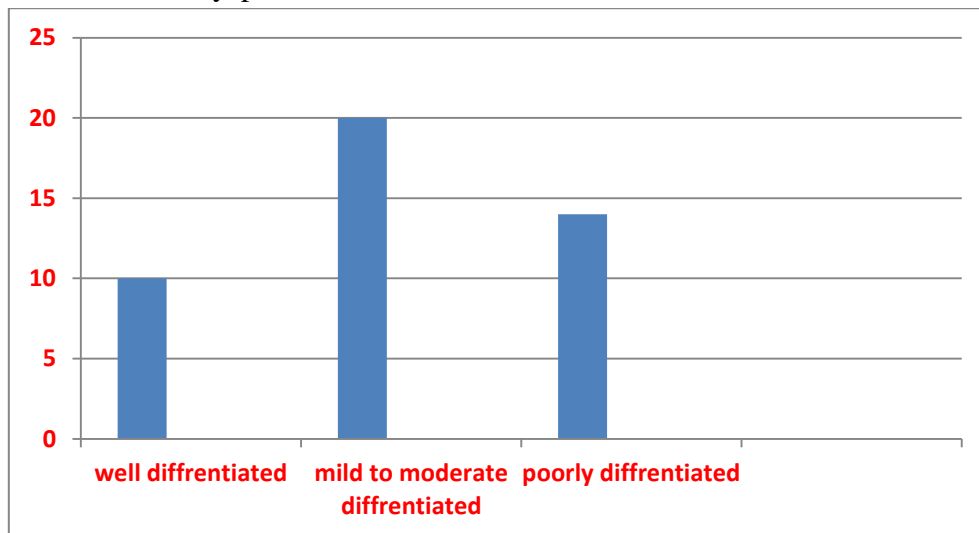


Fig. (1) Distribution of adenocarcinoma of colon according to the grading showing

- 1- 10 cases of well differentiated adenocarcinoma.
- 2- 20 cases of mild to moderate differentiated adenocarcinoma.
- 3- 14 cases of poorly differentiated adenocarcinoma.

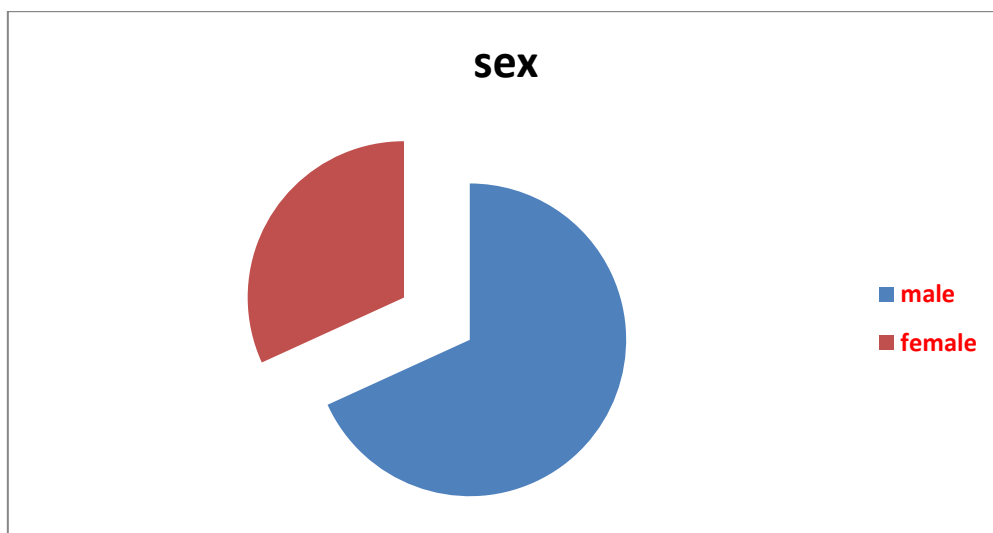


Fig.(2) : Finding according to the sex showing male predominance in incidence on female sex

- (1) 75% male (2) 25% female.

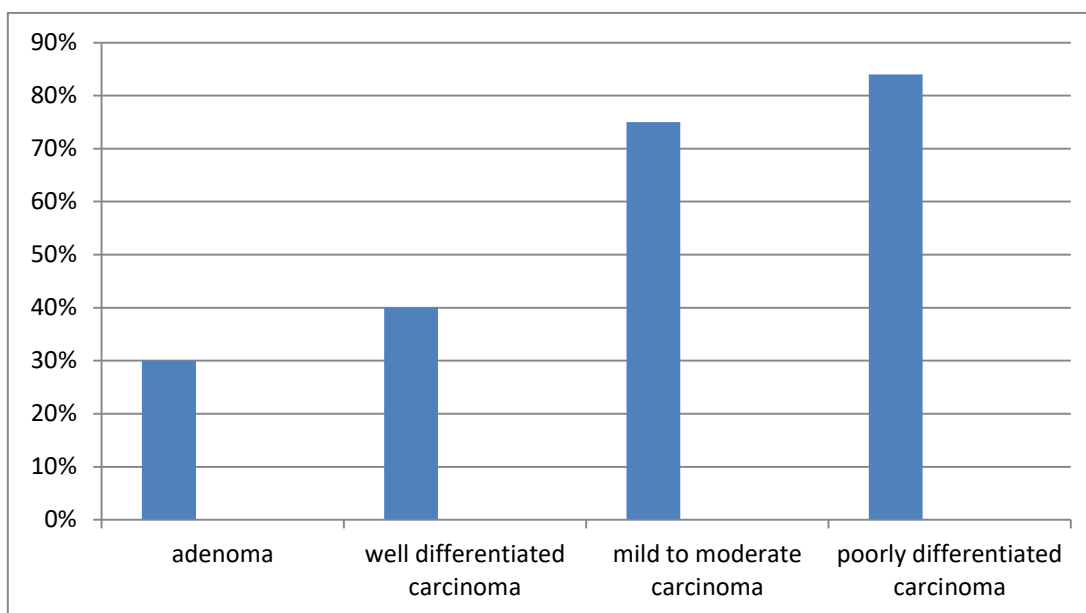
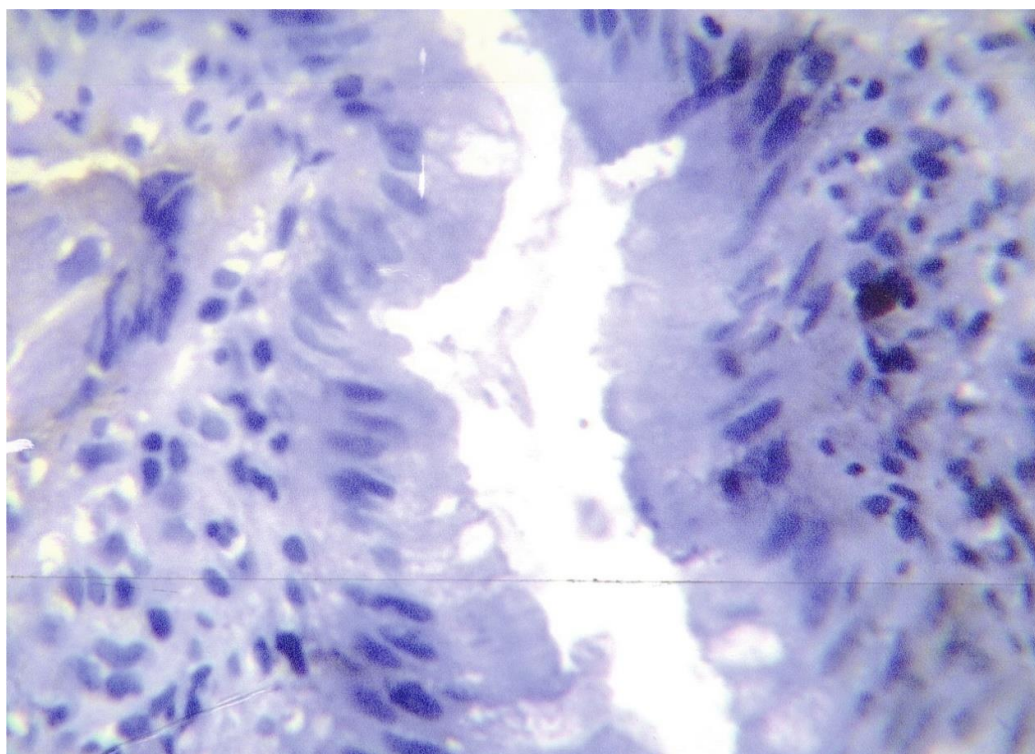
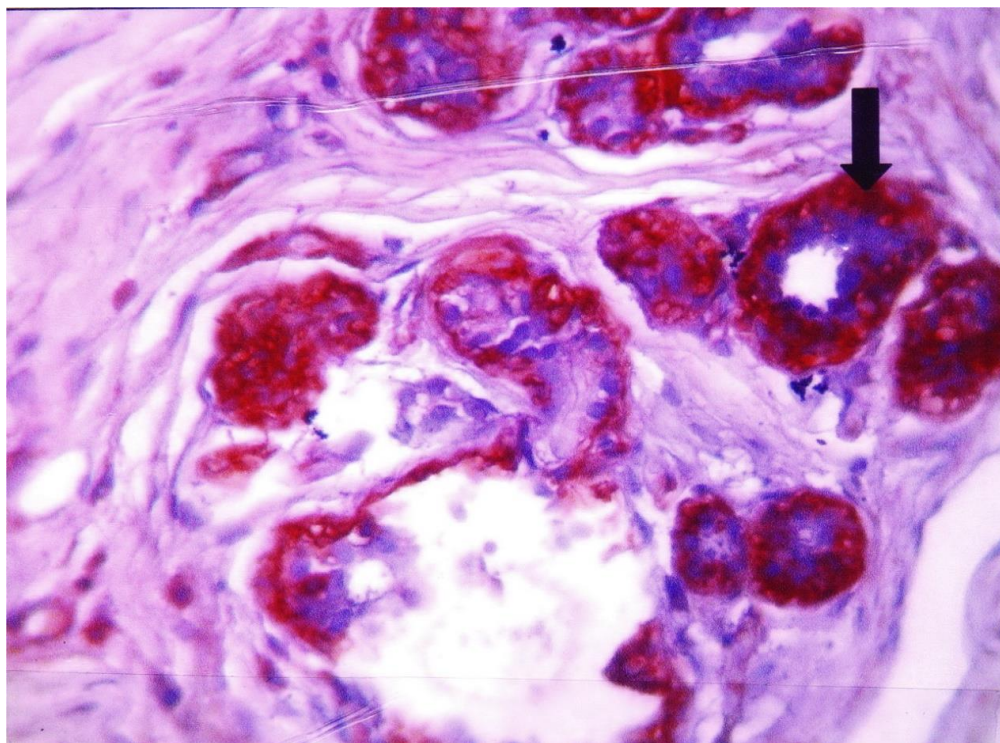


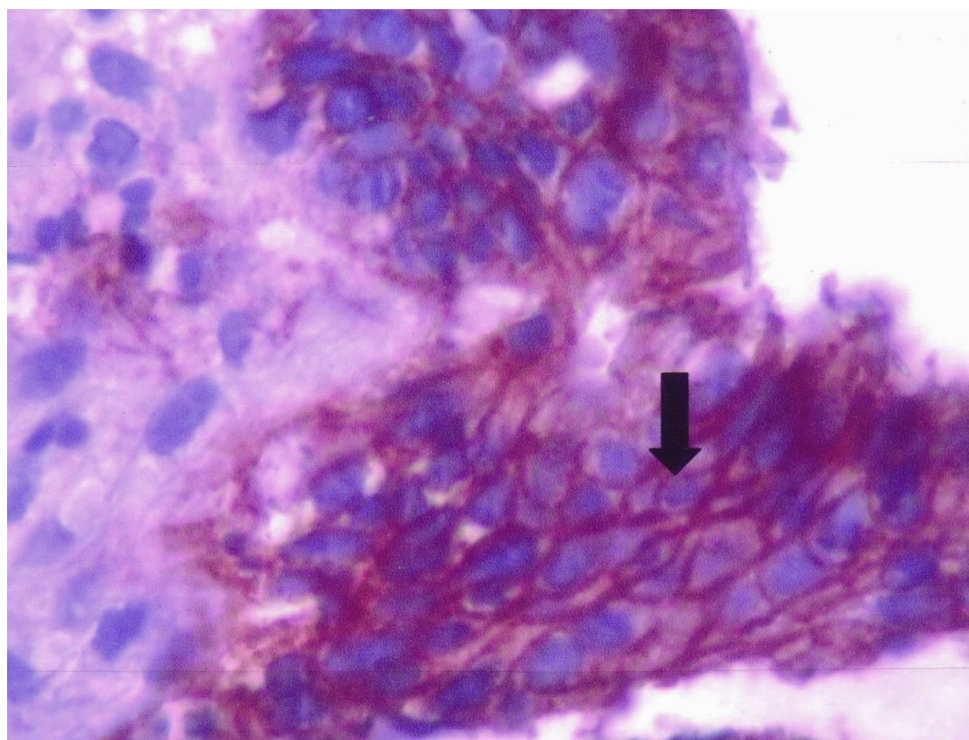
Fig (3) the percentage of positive cases in immunohistochemical study of uPAR which's reveal increament with increased in grade of carcinoma.



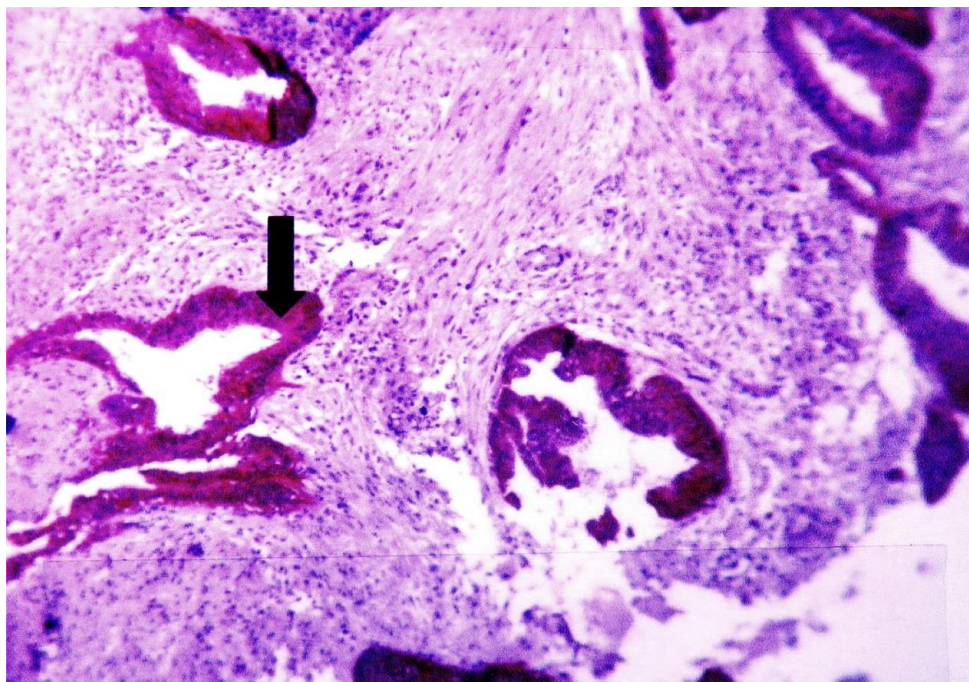
Pic.(1) Well differentiated colorectal adenocarcinoma used as negative control for uPA-receptor × 40



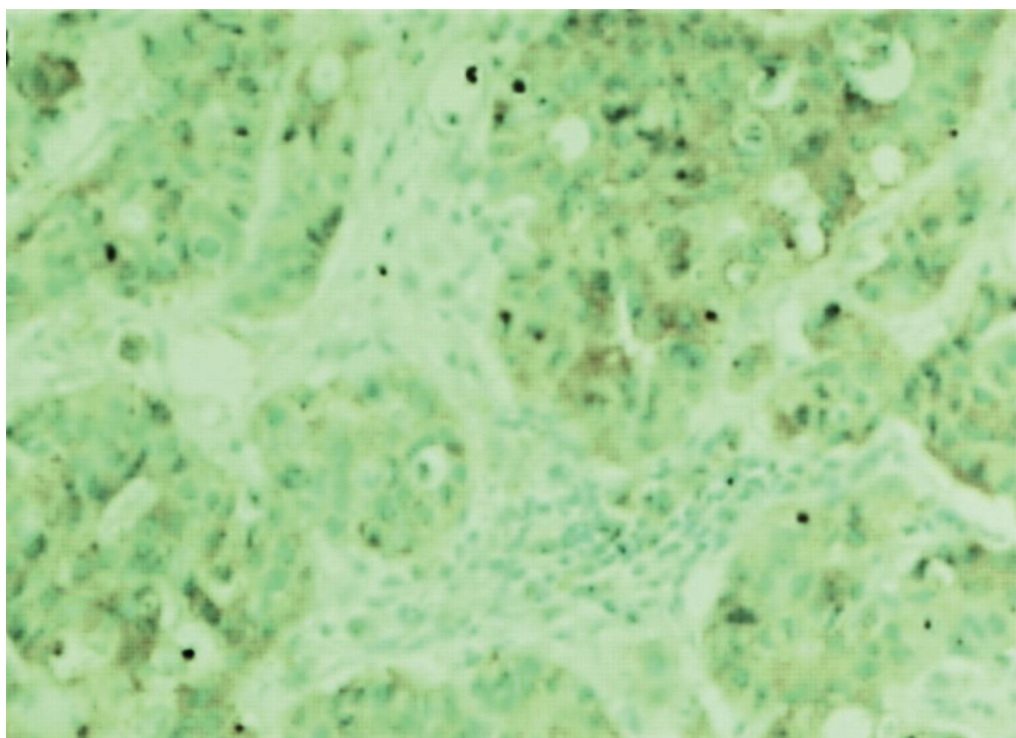
Pic.(2) moderately differentiated colorectal adenocarcinoma show strong positive uPA-receptor expression membrane and cytoplasm arrow (IHC staining) $\times 40$



Pic.(3) well to moderately differentiated colorectal adenocarcinoma show strong positive uPA-receptor expression membrane and cytoplasm arrow (IHC staining) $\times 40$



Pic.(4) well to moderately differentiated colorectal adenocarcinoma show strong positive uPA-receptor expression membrane and cytoplasm arrow (IHC staining)×40



Pic.(5) poorly differentiated colorectal adenocarcinoma with positive uPA-receptor expression cytoplasm and membrane (IHC staining)×40

Refrencess;

1- Jemal A, Murray T, Ward E, Samuels A, Tiwari RC, Ghafoor A, Feuer EJ, Thun MJ: Cancer statistics.

CA Cancer J Clin 2005, 55:10-30. PubMed Abstract | Publisher Full Text

2- Greenwald P: Colon cancer overview.

Cancer 1992, 70:1206-1215. PubMed Abstract | Publisher Full Text

3- 15. Fearon,E.R. and Vogelstein,B. (1990) A genetic model for colorectal tumorigenesis. *Cell*, 61, 759–767.

4. Kohonen-Corish,M., Ross,V.L., Doe,W.F. *et al.* (1996) RNA-based mutation screening in hereditary nonpolyposis colorectal cancer. *Am. J. Human Genet.*, 59, 818–824.

5- Muto T, Bussey HJR, Morson BC

(1975) *The evolution of cancer of the colon and rectum. Cancer* 36:2251–2270.

6- Dahiya R, Yoon W, Boyle B, Schoenberg S, Yen T, Narayan P: Biochemical, cytogenetic, and morphological characteristics of human primary and metastatic prostate cancer cell lines.

Biochem Int 1992, 27:567-577. PubMed Abstract

7- Mook ORF, Frederiks WM, Van Noorden CJF: The role of gelatinases in colorectal cancer progression and metastasis.

Biochim Biophys Acta 2004, 1705:69-89. PubMed Abstract | Publisher Full Text

8- Gomez DE, Alonso DF, Yoshiji H, Thorgeirsson UP: Tissue inhibitors of metalloproteinases: structure, regulation and biological functions.

Eur J Cell Biol 1997, 74:111-122. PubMed Abstract

9- Andreasen PA, Kjoller L, Christensen L, Duffy MJ: The urokinase-type plasminogen activator system in cancer metastasis: a review.

Int J Cancer 1997, 72:1-22. PubMed Abstract | Publisher Full Text

10- Li BH, Zhao P, Liu SZ, Yu YM, Han M, Wen JK: Matrix metalloproteinase-2 and tissue inhibitor of metallo-proteinase-2 in colorectal carcinoma invasion and metastasis. *World J Gastroenterol* 2005, 28:3046-3050.

11- Andreassen PA, Kjoller L, Christensen L, Duffy MJ: The urokinase-type plasminogen activator system in cancer metastasis: a review.

Int J Cancer 1997, 72:1-22. PubMed Abstract | Publisher Full Text

12- Seetoo DQ, Crowe PJ, Russell PJ, Yang JL: Quantitative expression of protein markers of plasminogen activation system in prognosis of colorectal cancer.

J Surg Oncol 2003, 82:184-193. PubMed Abstract | Publisher Full Text

13- Harvey SR, Sait SNJ, Xu Y, Bailey JL, Penetrante RM, Markus G: Demonstration of urokinase expression in cancer cells of colon adenocarcinomas by immunohistochemistry and in situ hybridization.

Am J Pathol 1999, 155:1115-1120. PubMed Abstract | Publisher Full Text

14- Tryggvason K, Höyhty M, Salo T

(1987) *Proteolytic degradation of extracellular matrix in tumor invasion. Biochem Biophys Acta* 907:191–217.

15- Nielsen BS, Sehested M, Timshel S, et al.

(1996) *Messenger RNA for urokinase plasminogen activator is expressed in myofibroblasts adjacent to cancer cells in human breast cancer. Lab Invest* 74:168–177.

16- Ganesh S, Sier CFM, Heerding MM, et al.

(1994) *Urokinase receptor and colorectal cancer survival. Lancet* 344:401–402.

17- Wang H, Skibber J, Juarez J, et al

(1994) *Transcriptional activation of the urokinase receptor gene in invasive colon cancer. Int J Cancer* 58:650–657.

18- Min HY, Doyle LV, Vitt CR, et al.

(1996) *Urokinase receptor antagonists inhibit angiogenesis and primary tumor growth in syngeneic mice. Cancer Res* 56:2428–2433.

19- Gelister JSK, Lewin MR, Savage F, et al.

(1987) *Plasminogen activators in experimental colorectal neoplasia: a role in adenoma-carcinoma sequence? Gut* 28:816–821.

20- Suzumiya J, Hasui Y, Kohga S, et al.

(1988) Comparative study of plasminogen activator antigen in colonic carcinomas and adenomas. *Int J Cancer* 42:627–632.

College of medicine , dep. Of pathology and forensic medicine , university of Thi-Qar

دراسة مُستقبل منشط انزيم يوروكاينيس بلازمانوجين في سرطان القولون والمستقيم

الدكتورة رشا قصي عبدالله

الخلاصة

يُعنى هذا البحث بدراسة وجود مُستقبل منشط انزيم يوروكاينيس بلازمانوجين في سرطان القولون والمستقيم ودوره في اعطاء الغزو والانبتات لهذا النوع من السرطان ، قامت الدراسة على ٤٤ حالة من سرطان القولون والمستقيم شخّصت واخذ بنظر الاعتبار درجة خباثة النسيج وقد تم الحصول عليها من مستشفى الحسين التعليمي في الناصرية مع اخذ ست حالات خزعات بالمنظار العادي طبيعية وعشر حالات ورم حميد مع وجود خلل في التنسج في بعض منها جميع هذه الحالات صبغت بطريقة الصبغ المناعي النسيجي الكيميائي لهذا المُستقبل فكانت النتائج ان خزعات المنظار الطبيعية كانت سالبة من هذه الصبغة بينما في حالات الورم الغدي الحميد كانت ثلاث من اصل عشرة موجبة الصبغة وظهرت في اماكن وجود خلل التنسج في حين حالات السرطان اظهرت الايجابية بنسب متصاعدة مع ارتفاع درجة الورم من خلال هذه النتائج يتبين لنا ان مُستقبل منشط انزيم يوروكاينيس بلازمانوجين يظهر في الخلايا التي تُظهر خلل التنسج في ورم الغدة الحميد بعد ذلك تكون هذه الصبغة اكثر كثافة وشدة في السرطان الغازي والمنتشر بنسبة مئوية تزداد مع درجة خباثة السرطان لان هذا المستقبل هو الذي يكسبه القابلية على الغزو والانتشار