

EFFEC OF THE ZINC ON THE SOME OF BLOOD PARAMETER AND SOME ORGANS IN LOCAL DUCK (*ANAS PLATER HYCOUS*)

Firas Ali Hussein^{*}, Abdalkareem Abas Bade^{**},Alaa Kadhum Mousa^{**}

^{*} department of Anatomy, College of Veterinary.Medicine. University of Basrah,Basrah,Iraq

^{**} Department of Animal Production , College of Agriculture, University of Basrah,Basrah,Iraq

(Received 11december 2011,Accepted 25 May 2012).

Keywords; kidney, zinc, myocardial.

ABSTRACT

This experiment was designed to elicit the effect of zinc on the hematological picture and the histological effect on heart, kidney and liver of the domestic ducks. The birds were divided into two groups of eight birds each. The first group was the control group and the second one was the treated group in which the birds were fed the zinc sulphate as 100 mg/kg with food for four weeks.

The results showed a decrease in hemoglobin, MCV, MCH, and MCHC. And an increase in red blood cells blood cholesterol,GOT and GPT. Histologically, the results showed a hydropic degeneration in the myocardial and renal cells beside a fatty degeneration in the liver texture.

INTRODUCTION

Zinc is used in different forms as elemental zinc, zinc acetate, zinc chloride, zinc citrate, zinc gluconate, zinc methionate, zinc oxide, zinc sulphate and etc., (1).

Zinc was found in all body organs and is needed for normal hair, skin feather and body bone growth (2,3). Zinc supports a healthy immune system (4), it is needed for wound healing (5), Zinc also supports normal growth and development during pregnancy, childhood and adolescence (6). Zinc is essential for adequate membrane function by its role as membrane stabilizer (7).

Zinc also has an antioxidant activity (8). According to Vallee and Fulchuk (9), zinc is a cofactor of the superoxide dismutase enzyme, which plays an important antioxidant role in the detoxification of the reactive oxygen species

Zinc deficiency is concerned with the nutritional aspects of food animal production. Deficiencies severely affect growth, health and well being of animals and even marginal zinc deficiencies can lead to significant economic losses (10).

Deficiency signs include loss of appetite, reduction of growth rate, bone abnormalities, diarrhea, excessive salivation and skin lesions usually around the mouth, nose, neck and eyes. (11).

The first signs of zinc toxicity include reduced feed intake, reduced weight gain, bone resorption. As the animal receives higher levels of zinc or toxic amount for long periods of time the animal will suffer from diarrhea, internal hemorrhage and even death (12)., pulmonary oedema and infiltration of the lung by leukocytes (13).Inhalation exposure to zinc chloride has been reported to result in various effects, including interstitial fibrosis, pneumonitis, bronchial mucosal oedema and ulceration, and changes in the mucous membrane of the larynx and trachea (14)

It has been noticed that when mice take a low – dose zinc, the Hb and erythrocyte levels increase significantly (15). Whereas (16) observed that the high dose of zinc has decreased the Hb, erythrocyte and hematocrit levels significantly in both male and female. Leukocyte levels were also observed to decrease in the high – dose male mice, the study did not show any adverse clinical signs or increases in mortality, and the study has shown also that the body weight gain decreased in the high – dose male rats. Several significant alterations in serum clinical chemistry parameters were observed in the high – dosed rats (16).

MATERIALS AND METHODS

The Local Duck (*anaspater hycous*)were fetched to the laboratories of college of agriculture-university of Basra to be checked clinically. The animals were divided randomly into two groups of eight animals each. The animals of the first group was the control group; the second group

were dosed 100mg/kg(B.W) body weight zinc sulphate for four weeks; the. The average weight of the animals was 1.250-1.750 kgm and of 12 months age.

The period of the experiment was four weeks through which zinc sulphates was offered freely with ration as 100mg/kg B.W with ration. Then the animals were terminated apart according to the groups .At the end of the experiment , 5ml blood was taken from each animal in to 2 test tubes (one with EDTA and the other without EDTA) .Blood with EDTA was used to measure RBC with help of Hematocytometer (Neubauer improved double) concentration of Hb and PCV were measured according to the method of (17).

Blood without EDTA was centrifuge at 1500 rpm for 20 minutes to separated serum . Serum cholesterol and total protein were measured by used chemical Kit SPECTRUM (Egyptian company for Biotechnology). The GPT Got was measured used a chemical Kit (Biomerieux , France).

Date was analyzed statistically used analysis of variance (18) .

Histologically, after the experimental was terminated the demanded organs such as heart, kidney, liver and pancreas were picked and put in formalin 10%. After three days dehydration process was done by the use of ascending concentrations of ethanol (70%, 80%, 90%, 100%) whilst the last two concentrations were repeated to ensure a good dehydration process.

The xylene was used to clear the organs. The specimens were soaked and embedded with paraffin wax then they were cut by the use of microtome at a thickness of 7 degrees. The samples were stained with Hematoxylin &Eosin stain

RESULT

Table (1) shows a significant ($p \geq 0.05$) increase in RBC. And a non significant decrease in Hb of the G2 comparing with those of G1. The MCV, MCH and MCHC of G2 were significantly ($p \geq 0.05$) decreased comparing with those of G1

Table (1) the effect of zinc toxicity (100mg/kg B.W) in some blood parameter ($p \geq 0.05$) (n=8, mean \pm SD)

	R.B.C *(10) ⁶	P.C.V %	Hb mg/dl	MCV	MCH	MCHC
Control G1	2.510 \pm 0,245 b	46.875 \pm 6.664 A	18.525 \pm 0.656 A	186.786 \pm 20.744 A	74.377 \pm 7.162 A	40.142 \pm 5.164 A
Experimental 100mg/kg G2	3.443 \pm 0.519 A	50.250 \pm 2.7 A	17.000 \pm 0.709 A	149.545 \pm 28.543 B	53.136 \pm 8.975 B	36.664 \pm 1.369 B

Table (2) observations after four weeks of zinc sulphate intoxication at dose 100 mg/kg B.W /daily. Cholesterol ,GPT and GOT level significantly ($p \geq 0.05$) increased in experimental group (G2) as compared with (G1).

Table (2) the effect of zinc toxicity (100mg/kg B.W) in some Blood Biochemistry ($P \geq 0.05$) ,(n=8 mean \pm S.D)

	Cholesterol mg/dl	Total Protein Mg/dl	GPT i.u	GOT i.u
G1	188.875 \pm 4.911 B	5.787 \pm 0.584 A	30.375 \pm 1.685 B	42.375 \pm 2.875 B
G2	200.125 \pm 7.698 A	5.662 \pm 0.647 A	33.187 \pm 2.852 A	57.875 \pm 3.482 A

Histological results as it's shown in the following pictures where the changes which occurred after offering zinc are seen:

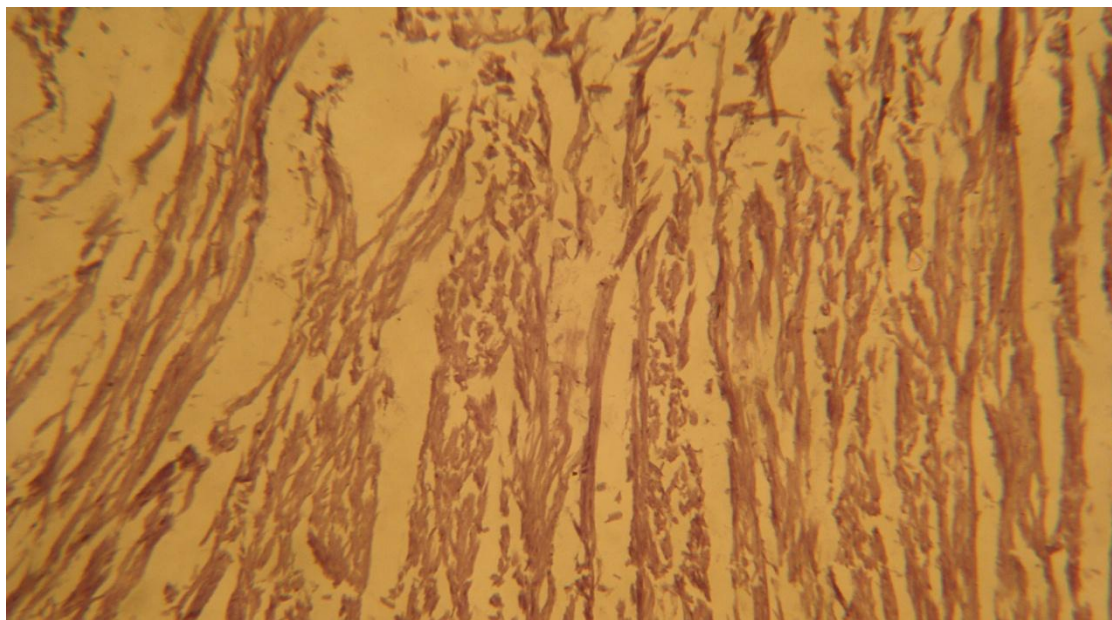


Figure (1). Histological aspect of heart of *Anas platyrhynchos* of the control group. H&E stain.
100 X

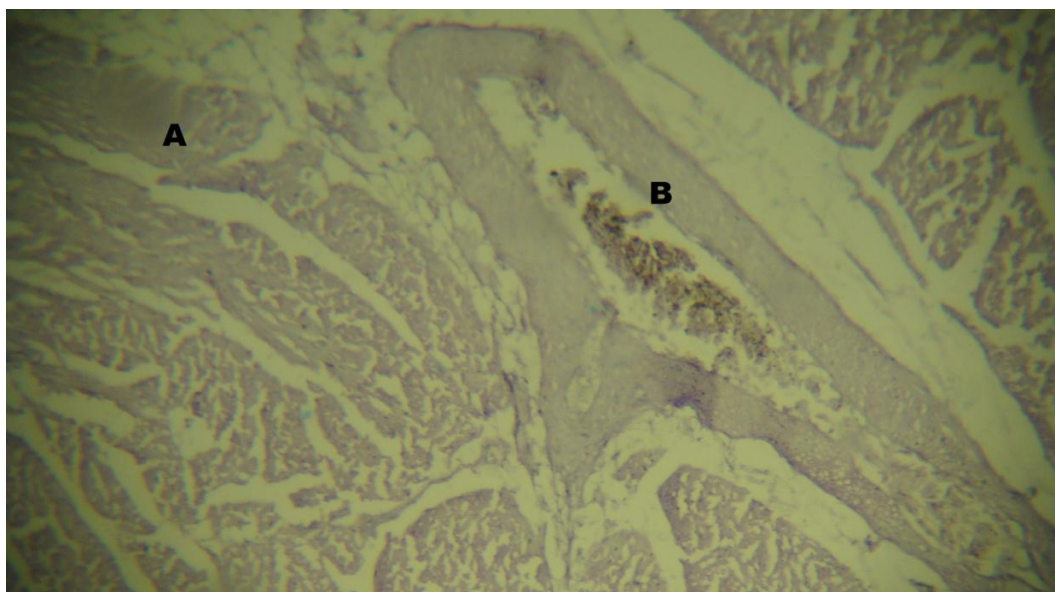


Figure (2). Histological aspect of heart of *Anas platyrhynchos* of the zinc treated group. Where a degeneration is noticed in the myocardial cells (A) and congested thickened wall blood vessel (B). H&E stain. 100 X

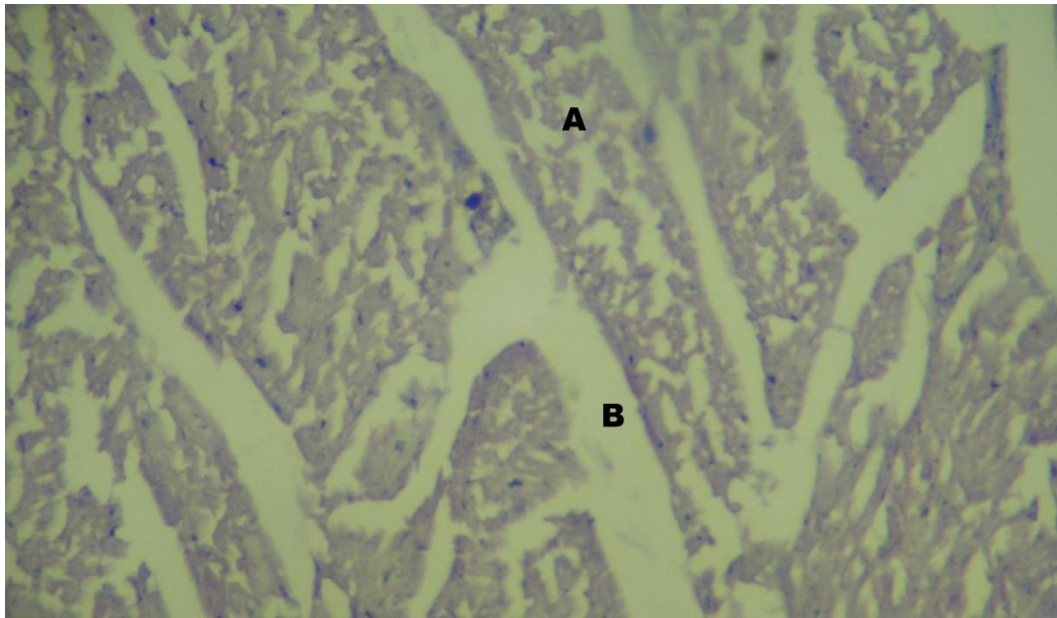


Figure (3). Heart of second group Hydropic degeneration is noticed in the myocardial cells (A) and edema (B). H&E stain. 100 X

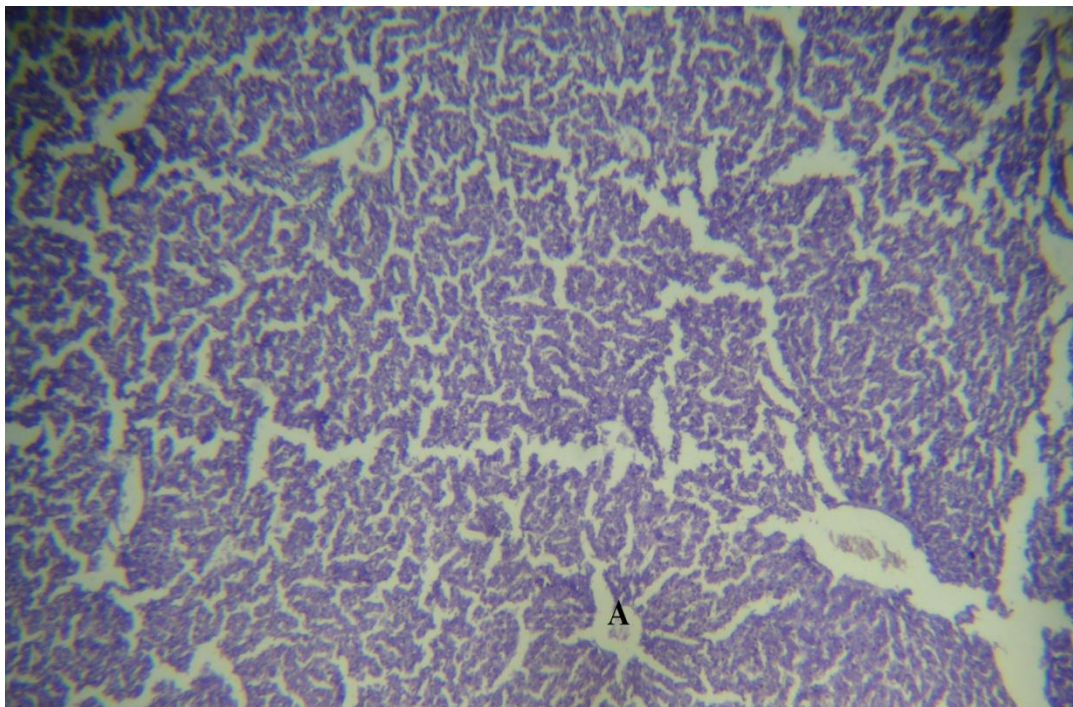


Figure (4) transverse section in control liver show the central vein(A) central vein H&E 100X

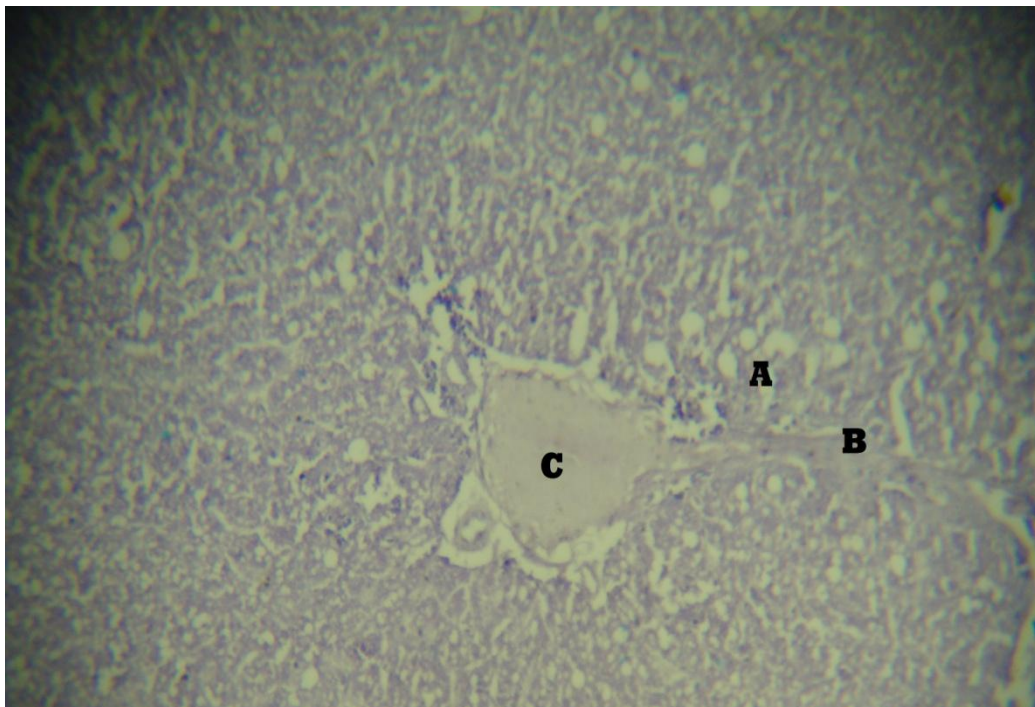


Figure (5) Histological section of liver of second group shows a fatty degeneration in the hepatic cells(A fibers accumulation in intralobular trabeculi(B) dilation in the blood vessel(C) . H&E stain. 100 X

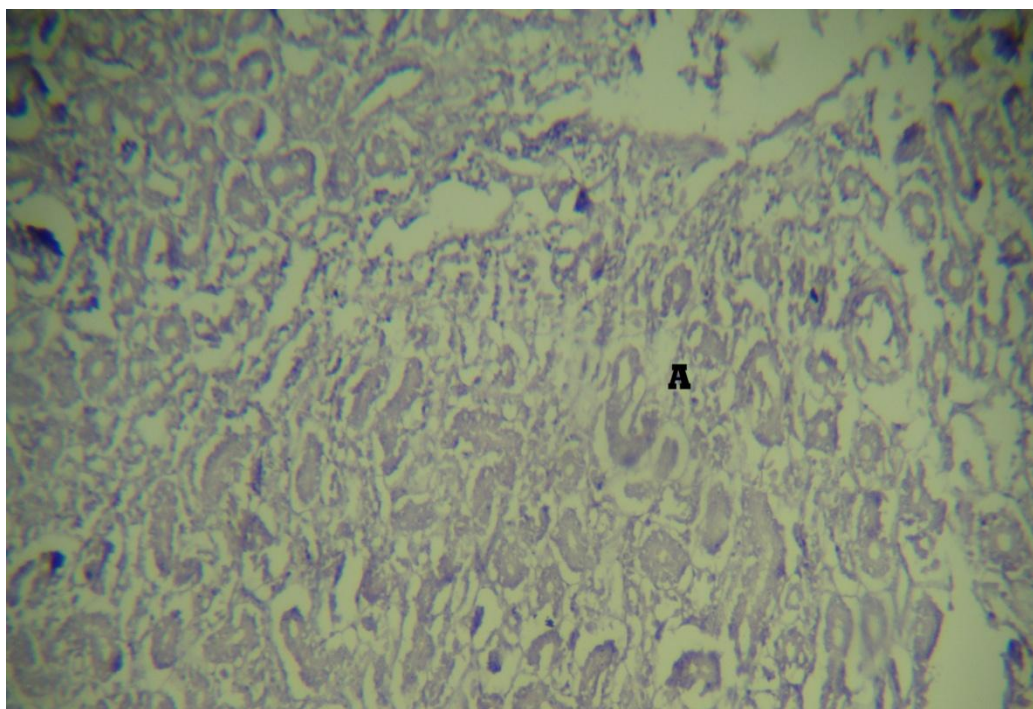


Figure (6) Histological section of kidney shows degeneration in renal tubules lining cells (A). H&E stain. 100x

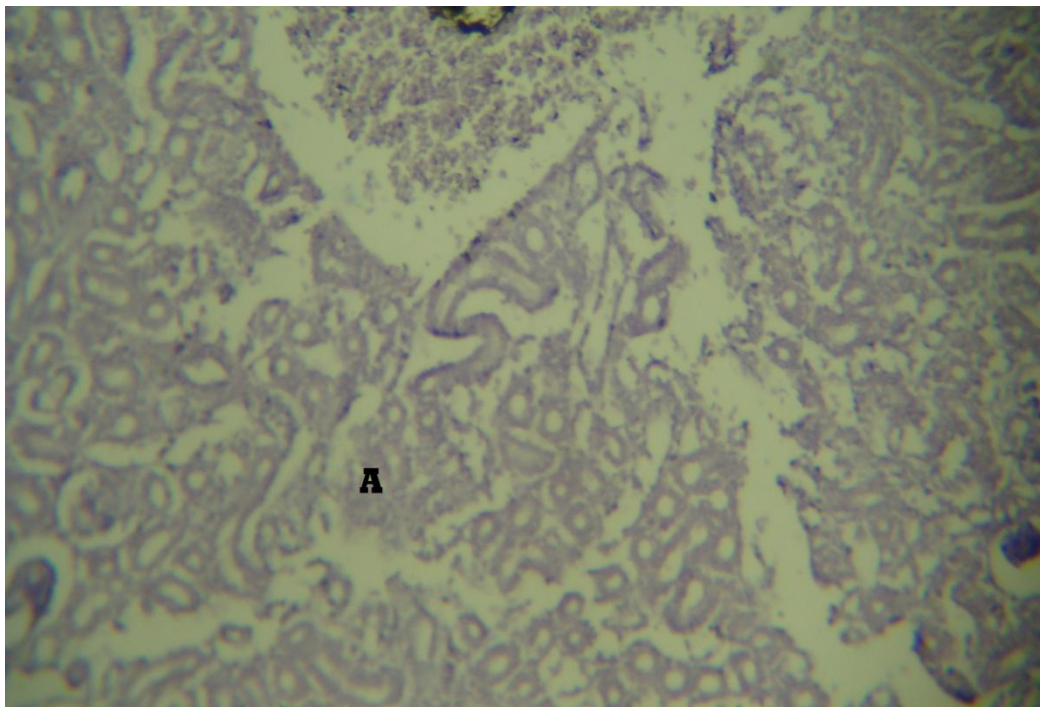


Figure (7) Histological section of kidney(G2) shows hydropic degeneration in renal tubules lining cells (A). H&E stain. 100x

DISCUSSIONS

The decrease in hemoglobin concentration in experimental group in our study which caused by zinc toxicity is due to decrease in copper absorption from small intestine. Excessive absorption of the zinc suppresses copper and iron absorption (17). High zinc intake can inhibit copper absorption some time producing copper deficiency and associated with anemia (18, 19)

Anemia which caused by Copper deficiency results from the un ability of reticulocytes to obtain iron from transferrin and to synthesize haem from iron (III) and protoporphyrin at normal rate (20).

The decrease in M.C.V.,MCH. And M.C.H.C. and decease in Hb referred to microcytic hypochromic anemia this result was cores pounded with chronic ingestion of low doses of zinc salt is associated with anemia (21) ,include hypo chromic (22).

The Significant increase of RBC count due to decrease in the hemoglobin concentration which produce decrease in oxygen transport from lungs to body tissue (Hypoxia) , the body in the case

of hypoxia will stimulate the bone marrow to produce new RBC to maintain the oxygen level in the blood and body tissue (23) the result agree with group of females were giving zinc sulphate at dose 50 mg/day for 12 days ,taken with breakfast small increase RBC count and plasma zinc were observe (24) .The elevation of PCV association with the increase of RBC count (25).

The Increase of the cholesterol concentration due to toxicity of zinc in tissue organs such as liver ,kidneys and pancreas with damage of cells of these organs .

The condition cause hyper cholestolema nephritic syndrome , hypothyroidism ,acute pancreatitis and hyper adernocorticism (26) ,the decrease in the thyroxin hormone level in plasma produce decrease I basll metabolism rate (B.M.R) and lipid metabolism causing elevation of cholesterol in blood (27) . the result agree with (28) suggested the relationship between fasting serum zinc diet and serum lipid level in group of adult that higher serum zinc level were associated with higher level of total cholesterol ,LDL, cholesterol triglyceral

High serum level of AST & ALT was usually indication of liver damage in anemia (29)the elevation of ALT was indication of liver damage and elevation of AST was indication for liver, heart, kidneys, skeleton muscles, brain, pancreas, lungs ,RBC, and WBC damage (30) .

Histological showed the hydropic degeneration in the cardiac muscle cells due to exposed to zinc and thicken in wall of blood vessel this result agree with (16).

In the liver of experimental group showed the fatty degeneration and fibers accumulation in the interlobular trabeculi this result agree with (31).

In the kidney showed the hydropic degeneration in the renal cells this study agree with (16) when study of effect of zinc on the kidney of libratory mice he found the damage in the renal tissue and necrosis in the epithelial layer of the renal tubules. But in this study not show the necrosis due to short period of experimental.

تأثير الزنك على الصورة الدموية وبعض الأعضاء الداخلية في البط المحلي

فراس علي حسين ، عبد الكريم عباس بادي، علاء كاظم موسى

فرع التشريح، كلية الطب البيطري، جامعة البصرة، البصرة، العراق.

قسم الثروة الحيوانية ، كلية الزراعة ، جامعة البصرة ، البصرة، العراق.

الخلاصة

بنيت التجربة لمعرفة تأثير الزنك على الصورة الدموية والتأثير النسيجي على أعضاء القلب والكلى والكبد في البط المحلي فقسمت الى مجموعتين كل منهما تتكون من ثمانية حيوانات الاولى للسيطرة والاخرى جرعت مادة كبريتات الزنك بواقع 100ملغم/كغم مع العلف لمدة اربع اسابيع . فظهرت نتائج التجربة نقص في الهيماكلوبين وزيادة في كل من كريات الدم الحمراء، وكذلك زيادة في الكولسترول ، نسيجيا اظهرت نتائج التجربة تنكس استسقاقي في خلايا عضل القلب وكذلك في خلايا الكلى وتنكس دهني في نسيج الكبد

REFERENCE

- 1 Lin, L.C.; Que, J and Lin, F.C. (2006). Zinc supplementation to improve mucositis and dermatitis in patients after radiotherapy for head and neck cancers: a double blind, randomized study. Int J Radial Oncol Biol Phys. Jul 1: 65(3): 745-50.
- 2 O'Dell, B.L. (1983). History and status of zinc in nutrition. Federation Proc. 43: 2821-2822.
- 3 Kechrid, Z. and Kenouz, R. (2003). Determination of Alkaline Phosphatase Activity in Patients with Different Zinc Metabolic Disorders. Department of Biochemistry, Faculty of Sciences, University of Annaba, PO BOX 12, Annaba 23000. ALGERIA. March 14.
- 4 Prasad, A.S. (1995). Zinc: An overview. Nutrition; 11: 93-99.
- 5 Heyneman, C.A. (1996). Zinc deficiency and taste disorders. Ann Pharmacother; 30: 186-187.
- 6 Fabris, N. and Mocchegiani, E. (1995). Zinc, Human diseases and aging, Aging (Milano); 7: 77-93.
- 7 Chang, L.W. (1996). Toxicology of Metals. Boca Raton, FL: Lewis Publishers, 982-792.

- 8 Salguerio, M.J.; Zubillago, M. and Lysionek, A.K. (2000). Zinc an essential micronutrient: a review. *Nutr Rev.* 20: 737-755.
- 9 Vallee, B.L. and Falchuk, K.H. (1993). *Physiological Reviews*, 73: 79-118
- 10 Chesters, J.K. (1983). Zinc Metabolism in animals: pathology – immunology, and genetic. *J. Inher, Metab. Dis.* 6 Suppl. 1: 34-38
- 11 Shaeffer, G.L. (2006). Evaluation of basic zinc chloride as a zinc source for cattle. M.Sc thesis in North Carolina State University. Animal Science. Raleigh
- 12 Kincaid, R.L.; Chew, P.B. and Cronrath, D.J.. (1997). Zinc oxide and amino acids as sources of dietary zinc for calves: Effects on uptake and immunity. *J. Dairy Sci.* 80: 1381-1388
- 13 Schenker, J.; Aaseth, J. and Refsvik, T. (1981). Excretion of zinc in rat bile – a role of glutathione. *Acta Pharmacol Toxicol*, 49: 190-194.
- 14 Matarese, S.L. and Matthews, J.I. (1986). Zinc chloride (Smoke bomb) inhalation lung injury. *Chest*, 89: 308-309.
- 15 Davis, C.D.; Milne, D.B. and Nielsen, F.H. (2000). Changes in dietary zinc and copper effect zinc – status indicates of postmenopausal women, notably, extracellular superoxide dismutase and myeloid precursor proteins. *Am J Clin Nutr* 71: 781-788.
- 16 Matia, K.; Hirana, M. and Mitsumor, K.(1981). Subacute toxicity studies with zinc sulphate in mice and rats. *J Pestic Sci* 6: 327-336.
- 17 Schalm , O.W. Jain, N.C. and Carrol, E.G. 1975. *Veterinary hematology* . Leo and febiger, Philadelphia, Pp: 140-152.

- 18 SPSS 1998. SPSS for windows for release 9.000 stander version, USA.
- 19 Fosmire,G.J.(1990)”zinc toxicity “ American Journal of clinical nutrition 51(2):225,PMID2407097.www.ajcn.org/cgi/content/abstract/51/2/225.
- 20 Broun, E.R.;Greist, A.;Tricot, G.; Hoffman, R.(1990). Excessive zinc ingestion: a reversible cause of sideroblastic anemia and bone marrow depression. JAMA, 264: 1441-1443.
- 21 Willis MS, Monaghan SA, Miller ML,McKenna RW Perkins WD,Levinson BS,et.al. zinc induce copper deficiency :a report of three causes initially recognized on bone marrow examination .AM J Clin Pathol. 2005;123:125-31 {pub med abstact}
- 22 Williams,D.M.,Lee,G.R. and Cartwright,G.E. Mitochondrial iron metabolism .fed. proc.,fed. Am Soc. Exp. Biol.,32:924(1973)
- 23 Chunn,V.D.(1973). Clin.Med. 80(mar), 7.
- 24 Porter,K.G.;McMaster D.; Elmes ME.;Love AHG.(1977). Anemia and low serum copper during zinc therapy. Lancet, 2:774(letter).
- 25 Ganong, W.F. (1999). Review of medical physiology. 19th ed. Appleton and Lang Asimen and Schuster company. United State of America PP:494-502.
- 26 Abdallah, S.M. , Samman, S.(1993). The effect of increasing dietary zinc on the activity of super oxide dismutase and zinc concentration in erythrocyte of healthy female subjects. European Journal of clinical nutrition 47,327-332.

- 27 Al- Channami, S.A.L.(2004).effect of vitamin C on some physiological and biochemical parameters of female rabbits. Msc. thesis, Education collage , university of kadsiya .(in Arabic)
- 28 Emberth,coles.(1986). Veterinary clinical pathology (fourth edition) press of W.B. Saunders Company. America.
- 29 Diekman, M.J.M.;Anghelescu, N.; ndert, E.; Bakker,O. and Wiersinga, W.M. (2000) Change in the plasma low- density lipoprotein (LDL) and high- densiy lipoprotein cholesterol in hypo-and hyper thyroid patient are related to change in free thyroxin not to polymorphisim in LDL receptor or cholesterol ester trabsfer protein genes. J. Clin. Endocrinol, 85(5):1857-1862.
- 30 Beer,W.H.;Johnson, R.F.;Gunetzet, M.N.;Lozano,J.;Henderson,G.I.and Schenker. S.(1992). Human Placenta transfer of zinc :normal characteristic and role of ethanol. Alcohol clin. Exp.Res., 16:89-105.
- 31 Durak I., Guven T., Birey M., Ozturk H. S., Kurtipek O., Yel M.(1996): Halothane hepato toxicity and hepatic free radical metabolism in guinea pigs:the effect of vitamin E. can. J. Anaesth. 43,741-748
- 32 Giboney, T.P.(2005).Mildly elevated liver transaminase level in the asymptomatic patient. Am.Fam.phsyiology, 71(6):1047.
- 33 LEAVENGOOD, J. M., G. C. SANDERSON, W. L. ANDERSON, G. L. FOLEY,L. M. SWOKRON, P. W. BROWN, AND J. W. SEETS. 1999. Acute toxicity of ingested zinc shot to game-farm mallards. Illinois Natural History Survey Bulletin 36: 1–36.