

Anatomical and Histological Study of The Optic Tectum In Diurnal Raptor Species *Buteo Buteo* (Buzzard).

Shermean Abdullah Abd_Alrahman

college of Education -IbnAlhatham / university of Baghdad. .

Abstract

Morphological and histological aspects on the optic tectum of (Buzzard) were studied to describe the size, position and the structural variation that related to bird behavior and function. The results of morphological aspects revealed that the optic tectum was large and thick. Its position was lateral and below the cerebral hemisphere. Histological aspects of this organ was studied with the using of rotary microtome and slides stained with Haematoxyline and Eosin (H&E) and periodic acid schiff reagent (PAS) methods. The results of microscopic examination indicated that optic tectum was divided in to : Superficial layers which constitutes the stratum opticum (SO) and Deep layers which constitutes the stratum griseumcentrale (SGC), the stratum album centrale (SAC) and the stratum griseumperiventriculare (SGP). The majority population of neurons especially of different sizes found in the stratum griseumcentrale (SGC). optic fibers were displayed different patterns and orientations in various tectum.

الخلاصة

تناولت الدراسة الجوانب الشكلية و النسيجية للسقف البصري لدماغ صقر الحوام (Buzzard) من حيث الحجم والموقع والاختلافات التركيبية ذات العلاقة بالسلوك و الوظيفة. أظهرت نتائج الشكليات ان السقف البصري كبير الحجم و سميك و يتخذ موقع جانبي و تحت نصفي كرة المخ. تضمنت دراسة الجانب النسيجي للسقف البصري باستعمال المشرحات التدويري واستخدام تقنية التلوين بالهيماتوكسيلين-الأيوسين و كاشف شف الدوري. اظهرت نتائج الفحص المجهرى ان السقف البصري مقسم الى طبقات سطحية تضم الطبقة البصرية و طبقات عميقة تضم الطبقة السنجابية المركزية والطبقة البيضاء المركزية و الطبقة الاخيرة السنجابية حول البطينية. تنتشر اكبر تجمعات للخلايا العصبية او العصبونات و بالاخص المختلفة الاحجام ضمن الطبقات السنجابية المركزية للسقف البصري. تنتشر الالياف باحجام و مستويات و اتجاهات مختلفة خلال السقف البصري لصقر الحوام (Buzzard).

Introduction

optic lobes are the visual roof of the mid brain (mesencephalon), which named optic tectum (Teo) in nonmammalian species, and superior colliculus (Sc) in mammalian species [Pettingil 1985 ; Northcutt 2002 ; Kent 1987]. The avian optic tectum (Teo), and the mammalian superior colliculus (Sc) are homologous [Hutchinson 2007 ; Luksch 2003a,b ; Linser 1985]. The optic tectum are well developed [Cook 2000 ; Linser 1985 ; Martin et al. 2007 ; Iwaniuk 2003], thick [Northcutt 2002 ; Martin et al. 2007 ; Tombol 1998], highly laminated, and complicated [Hutchinson 2007 ; Cook 2000 ; Dong et al. 2002 ; Hu et al. 2004] in birds. Avian optic tectum exhibits more variations in position [Martin et al. 2007 ; Iwaniuk 2003 ; Walker 1983]. The optic tectum exhibits characteristics important for motion processing and important as a large receptive fields, motion responsive and

directionally selective .Approximately 90% of the retinal ganglion cell axons in lateral-eyed birds project to optic tectum [Linser 1985 ; Cook 2000] .The purpose of the study has been find out the morphological and histological aspects of the optic tectum in (Buzzard) ,a bird of high degree of optical activity [Rosemary 2006] that may be helpful for better understanding the structural variations related to its important functions ,and birds behaviour .

Material and Methods

Four healthy adult (buzzard)were utilized in this investigation, the brains were obtained from the skull by careful dissection , the whole brain and the optic lobes were submersion fixed in 10% buffered formalin . The optic lobes were bisected in sagittal plane .Pieces of optic lobes made by a sharp knife were fixed in 10% buffered formalin , washed , dehydrated through ascending grades of alcohol , cleared and embeded in paraffin wax . Five –six microns thick sections were cut by using rotary microtome . The paraffin wax was removed by immersing the slides in xylene . The slides were passed through descending grades of alcohol , the sections were stained with Haematoxylin and Eosin (H & E) , and Periodic acid shift reagent (PAS) as per standered procedures, the tissue sections were cleared , mounted with D.P.X. as per usual method [Humanson 1972; Drury 1980] .

Result

The optic tectum : Gross anatomy

The optic tectum of the Buzzard mid brain were a pair of clearly visible well developed lobes ,Fig. (1&2) shows the size ,shap and the position of these structures . The optic tectum were large and oval , its position was lateral and below the cerebral hemisphere . The optic tectum of the Buzzard was thick and highly laminated. It was enclosed a reduced lateral narrow recesses which considered the end of the third ventricle of the brain .

The optic tectum :Histomorphology

Histologically the optic tectum (Teo) was divided into : Superficial layers which constitutes the stratum opticum (So) and Deep layers which constitutes the stratum album centrale (SAC) ,the stratum griseumcentrale (SGC) and the last stratum the layers of the stratum griseumperiventriculare (SGP) (Fig.3). Optic tectal layers exhibits alternating cellular and fibrous laminae , each cellular layer composed of a sparse population of neurons .(Fig. 4) shows the majority population of different sizes neurons found especially in the gray layers of the stratum griseumcentrale (SGC) .(Fig. 5) shows the different patterns and orientation of the optic fibers in various laminae of the Buzzard optic tectum .

Discussion

The results indicate that Buzzard has well developed ,large optic tectum , this finding was inagreement with [Kent 1987; Linser 1985] in birds , [Martin et al. 2007] in Emu ,pigeon and [Iwaniuk 2003] in parrots .The humming birds ,kiwi and Barn owl have relatively small optic tectum [Martin et al.2007 ;Wylie et al. 2006] .

The position of the optic tectum depends on the extension of the caudotemporal part of the cerebral hemisphere its position was ventral in parrots ,corvids [Iwaniuk 2003] and kiwi [Martin et al. 2007] ,while in Buzzard it was lateral and below the cerebral hemisphere .

Buzzard has thick optic tectum ,this was inagreement with the statement of [Northcutt 2002] in sparrow ,[Tombol 1998] in chicken and [Martin et al. 2007] in pigeon . Kiwi and Barn owl has a very much reduced thickness optic tectum [Martin et al. 2007;

Wylie et al. 2006] . This reflects on the feeding methods behaviour occurred in some birds that need to keep their vision stable in order to successfully feed [Iwaniuk & Hurd 2006] , and the uncanny ability of some birds to locate prey using only auditory cues [Wylie et al. 2006] .

The results indicate that Buzzard has highly laminated optic tectum , the latter divided into superficial layers which constitutes the stratum opticum (SO) , and deep layers which constitutes the stratum album centrale (SAC) , the stratum griseumcentrale (SGC) and the last stratum the layers of the stratum griseumperiventriculare (SGP) .These observations were in agreement with [Hutchinson 2007 ; Cook 2000] in birds and [Dong et al. 2002; Hu et al. 2004] in chicken .It was found that the majority population of different sizes neurons especially found in the gray layers of the stratum griseumcentrale(SGC) . According to [Cook 2000] who stated that the stratum griseumcentrale posses neurons which exhibit large receptive fields ,motion responsive and directionally selective . Other observation was made by [Linser 1985] in birds , he found three distinguished population of neuroglia by using immunochemical techniques .

The optic fibers displayed different patterns and orientations in various laminae of the Buzzard optic tectum . These observations were in accordance with [Tombol 1998] in chicken . [Anton et al. 1982] demonstrated four distinct bands of fibers which have some influence upon the motor output functions of the avian tectum . [Tombol et al. 2003] classified two types of optic fibers according to the thickness and terminal branching patterns which take part in the transmission of optic impulses to the neurons .According to [Hutchinson 2007] the avian optic tectum and the mammalian superior colliculus (SC) relays visual information through its more superficial layers and the somatosensory / multisensory information through its deeper layers . The colliculus function are to help the head for orient and the eyes toward something seen . [Hutchinson 2007; Luksch 2003a,b ; Linser 1985] considered the avian optic tectum and the mammalian superior colliculus homologous ..

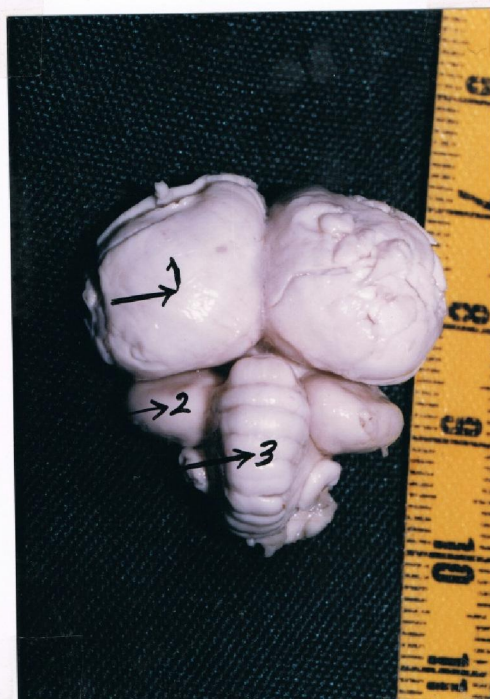

Fig. 1 Dorsal view of the buzzard brain showing the position of the optic tectum (Teo) . 1 → cerebral hemisphere 2→ optic tectum 3→ cerebellum .

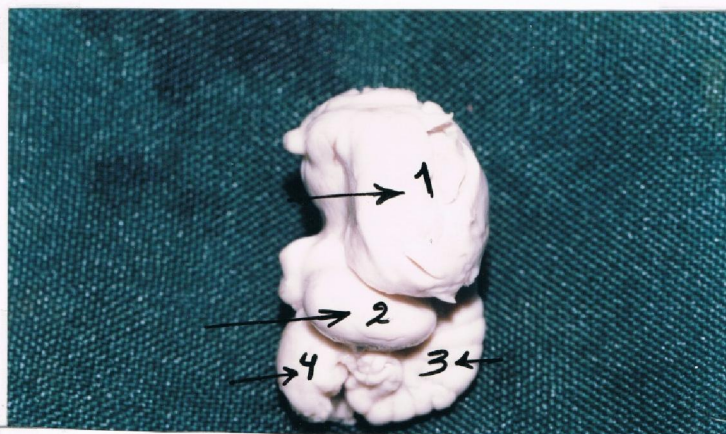


Fig. 2 Lateral view of the buzzard brain showing the shape and the size of the optic tectum . 1→ cerebral hemisphere 2→ optic tectum 3→ cerebellum 4→ medulla oblongata .

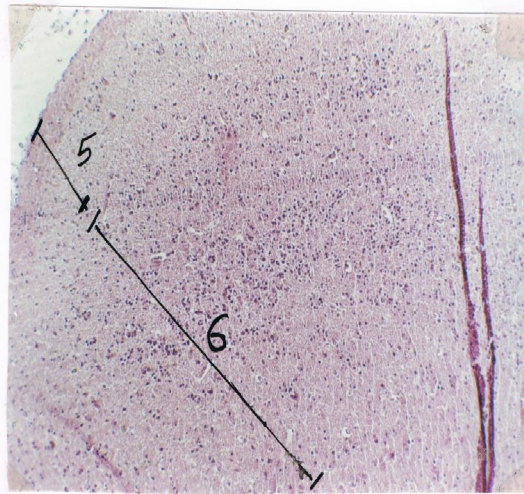


Fig. 3 The optic tectal layers in buzzard brain (H&E) (10X) .

5→ the superficial layers 6→ the deep layers .

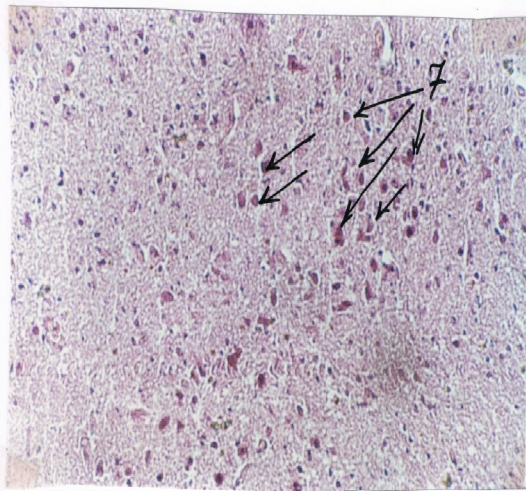


Fig. 4 The optic tectal gray layers of the stratum griseum centrale (SGC) (H&E) (10X) .

7→ neurons of different sizes .

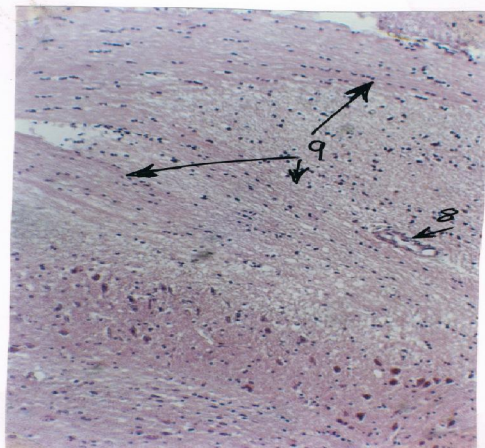


Fig. 5 The buzzard highly laminated optic tectum showing the alternating cellular and fibrous laminae (H&E)(20x).

8→ blood vessel 9 →different patterns and orientation of optic fibers .

References

- Anton, R., H.J. Karten and N.C. Brecha. (1982) Enkephalin mediated basal ganglia influences over the optic tectum : Immunohistochemistry of the tectum and the lateral spiriform nucleus in pigeon ,Wiley Interscience, Vol. 19, No.1 ,pp. 15-22
- Cook, R.G. (2000) Avian visual cognition ,Department of physiology ,tufts university ,Vol 9, No. 3, pp. 83-89 .
- Dong, H.S. ,E. Lee and S.S.Cho.(2002) Glial cells in the chicken optic tectum ,J. of Neuroscience ,Vol.962, issues 1-2 pp 221-225
- Drury, R.A. and Wellington E.A. (1980) Carletons histological technique 5 oxford, New York Toronto .
- Hu, M. ,Naito J. ,Chen Y. and Ohmori ,Y. (2004) Morphological characteristics of tectal neurons of layer I projecting to the nucleus geniculatus lateralis ventralis in chick .J.Vet .Med. Vol. 66 ,No. 8 pp 1015-1016 .
- Humanson, G.L, (1972) Animal Tissue Technique 3ed. W.H.Freeman and company Sanfransisco .
- Hutchinson wikipedia articles, the free encyclopedia (2007) Inc U.S. registered 501 (c) (3) .
- Iwaniuk, A.N. and Hurd P. (2006) Size of the Mld a cross species .Brain Behavior and Evolution ,167 :305.
- Iwaniuk, A.N. (2003) The evolution of brain size and structure in birds unpublished PhD thesis, Monash university ,Clayton ,Australia, 81: 1913-1928
- Kent ,G. (1987) Comparative anatomy of vertebrates 6th ed ,John wiley, New York PP.573-578 .
- Linser, P.J. (1985) Multiple marker analysis in the avian optic tectum reveals classes of neuroglia and carbon anhydrase -containing neurons .Neuroscience Vol. 5 ,2388-2396.
- Linser, P.J. (1985) Avian optic tectum, J. of Neuroscience, Vol.5 2388-2296 .
- Luksch, H. (2003a) cytoarchitecture of the avian tectum : neuronal substrate for cellular computation , Neurosciences, 14 (1-2):85
- Luksch, H. (2003b) Functional analysis of tectal neurons in birds .Biologie II. Vol. 975 issues 1-2 pp.48 .
- Martin, G.R.K. Wilson ,J.M.Wild, S.Parsons ,M.F.Fubke and J.Corfield. (2007) Kiwi forego vision in the guidance of thier nocturnal activities. Plos one 2:e 198.
- Northcutt, R.G. (2002) Understanding vertebrates brain evolution .Integrative and comparative biology ,Vol. 42, N.4 pp 743-756 . 473 .
- Pettingil, O.S. (1985) Ornithology in laboratory field ,cornell university ithace ,New York 4thed. ,pp 94-96.
- Rosemary, D. (2006) What are birds of prey ? Description of the bird group commonly called birds of prey, [http:// people.eku.edu/bribbrain.html](http://people.eku.edu/bribbrain.html) .
- Tombol, S.H. (1998) Golgi and Electron Microscopic Golgi -GABA Immunostaining study of the Avian optic tectum ,Acta Anatomica, Vol.162 No. 4
- Tombol, T. ,M. Eyre and N.Zayats (2003) The Ramifications and Terminals of optic fibers in layers 2 and 3 of the Avian optic tectum .Cell Tissues Organs .175 (4) :202 .
- Walker, S.(1983) Animal thought ,the functional organisation of the vertebrate brain . file :\\c iusers \\master\\Desk top \\doc.htm.
- Wylie, D.R. ,Hurd P. and Iwaniuk ,A.N. (2006) The pretectal nucleus lentiformis mesencephalon is hypertrophied in humming birds- Brain Behavior and Evolution .