

DERMATOPHYTOSIS IN SHEEP OF AL-SAFAT SHOW IN BASRAH, IRAQ

Abdul-Hafiz Al-Duboon*

Fadhil J. Farhan**

*Department of Marine Biology, Marine Science Centre, University of Basrah, Basrah
Iraq,.

** Department of Marine Chemistry, Marine Science Centre, University of Basrah, Basrah
Iraq,.

(Received 10 January 2007, Accepted 22 April 2007)

Keywords: thiamine, Ringworm, wool loss.

ABSTRACT

Out of 437 sheep inspected (1963 male and 2474 female), 242 (5.45%) sheep among 268 specimens collected from suspected cases of dermatophytosis, which had clinical lesions of dermatophytic infections, that confirmed by positive culture on (SDA+Chloramphenicol+Cycloheximide) supplemented with thiamine and yeast extract and /or by direct microscopic examination using 10% KOH solution. The ringworm infections were varied from summer months (June- October, 2005) to those of winter months (November,2005 to March,2006) which were 59 (3.06%) and 183 (7.29%) respectively . The fungus affect both, the outer layers of the skin as well as wool. It was spread centrally outward causing more or less circular areas of wool loss leaving scaly to powdery skin which was gray-white in color, measuring 2-10 cm. in diameter. The head, ears, loin, and neck were the most areas had been affected. The only causative fungus isolated was *Trichophyton verrucosum*.

INTRODUCTION

Animal are known to play an important role in the epidemiology of both animals and human mycoses. They can act as a reservoir or vectors for these diseases (1,2,3). Ringworm is an infectious diseases of animals caused by different species of keratinophilic fungi. It is a major public and veterinary health problems reported from different parts of the world and causes great economic

loss (4). The disease appears to be more common in tropical than temperate climates particularly in countries having hot and humid climatic condition (5). Very limited studies on ringworm infection in animals had been published from arab countries. *Trichophyton mentagrophytes*, *T. verrucosum* and *Microsporum gypseum* were the most common fungi isolated from cases of animal dermaophytosis (6,7,8,9,10)

Ringworm (club lamb fungus) in sheep have several names including wool rot, lumpy wool, ovine ringworm, and ovine dermatophytoses were caused by a members of the dermatophytic genus *Trichophyton* (11,12,13). Studies on dermatophytosis of sheep in Basrah have not been done, and the present study which is the first in Basrah was conducted to determine the causative agents and percentage of sheep dermatophytosis in Basrah/ Iraq.

MATERIALS AND METHODS

Animals

A total of 4437 sheep were examined clinically for fungal skin lesions (1927 sheep during hot months June-October 2005 and 2510 sheep through (November 2005 to March 2006), at Al-Safat Sheep market in Basrah from 8 large stables (each stable containing from 70-120 sheep), in which the sheep were transported from rural and suburban areas around Basrah, Missan and Dhe-Qar governorates. The sheep aged from 4 months to 3 years old.

Sampling

The affected areas were rubbed with cotton swab soaked in 70% ethyl alcohol to remove the adherent organisms, then skin scrapings and wool clippings were collected from the margin of the lesions in a small sterile plastic Petri dishes then after transported to the laboratory for direct examination and culture.

Direct examination

Skin scrapings and wool clipping were placed on a clean glass slide. A drop of 10% KOH solution was added, then covered with cover slip, passed on Benzen flame 2-3 times to hasten the

digestion of the keratinized tissues, and examined microscopically, using low and high power objectives to detect fungal structures (hyphae and spores).

Culture

Parts of clinical specimens (skin scales and wool clippings) were distributed on the surface of sabourauds dextrose agar with Chloramphenicol and cyclohexamide supplemented with thiamine (100 mg/L.) and yeast extracts (5 g/L.) for the enhancement of growth of dermatophytes. The plates were incubated at 28- 30°C until the fungal growth appears. Parts of the colonies were mounted in lacto-phenol cotton blue to study the morphological characteristics of the isolated pathogen microscopically and identified according to the criteria of (3,14,15,16,17).

RESULTS

Clinical signs

From 4437 sheep examined (1963 male and 2474 female), there were 42 (5.45%) sheep had clinical lesions of dermatophytic infections, which confirmed by positive culture on (SDA+C+C) supplemented with thiamine and yeast extract and /or by direct microscopy using 10% KOH solution. The ringworm infection varied from summer months (June- October, 2005) to that of winter months (November,2005 to March,2006) which were 3 (3.06%) and 17 (7.29%) respectively and the higher percentages of infection were during December and January (Table 1). The fungus affected both the outer layers of the skin and wool. It was spread centrally outward causing more or less circular areas of wool loss, leaving scaly to powdery skin. These lesions were covered by a gray-white scab, measuring 2-10 cm. in diameter. The head, ears, loin, and neck were the most likely areas had been affected. Fig.1

Table (1): Number of sheep examined and percentage of infection

Months	No. of examined animals		No. of infected animals				% of infection		Total (%)
			+ve KOH		+ve culture		Male	Female	
	Male	Female	Male	Female	Male	Female			
June	130	205	4	7	3	6	3.08	3.41	11 (3.28)
July	120	190	3	5	3	5	2.50	2.63	8 (2.58)
August	180	220	4	6	4	5	2.22	2.73	10 (2.50)
September	200	262	6	8	4	8	3.00	3.05	14 (3.03)
October	200	220	7	9	7	8	3.50	4.09	16 (3.81)
November	253	279	15	17	12	15	5.92	6.09	32 (6.02)
December	220	270	18	24	16	22	8.18	8.89	42 (8.57)
January	230	283	19	26	17	25	8.26	9.19	45 (8.77)
February	200	250	16	22	16	20	8.00	8.80	38 (8.44)
March	230	295	11	15	11	14	4.78	5.08	26 (4.95)
Total	1963	2474	103	139	93	128	5.25	5.61	242 (5.45)
	4437		242		221		5.45		

Microscopic examination

10% KOH mounting of skin scales and hair clippings revealed fungal hyphae and spores of dermatophytes (Ectothrix and Endothrix) in 242 clinical specimens out of 4437 specimens examined. Fig.2 (a-c).

Culture

Two hundreds and twenty one isolates were obtained from 268 specimens cultured. The isolated dermatophytes was *Trichophyton verrucosum* that is slow growing on SDA+C+C producing colonies that are heaped or button-like, irregularly folded, glabrous, moist and immersed in the medium, cream-colored to ochraceous. Fig.3 .

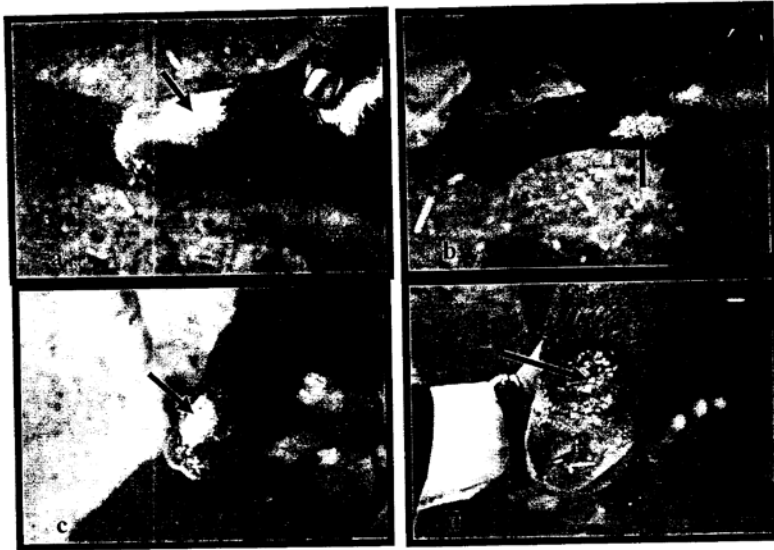


Fig. 1: Ringworm of sheep due to *Trichophyton verrucosum*
a,d,c- Face; b- Ear




Fig. 2: Direct microscopical examination of sheep wool showing the conidia of dermatophytes. a- Ectothrix by unknown dermatophytes (400x); b- Ectothrix (400x), and c: Endothrix (100x) by *Trichophyton verrucosum* (10% KOH).

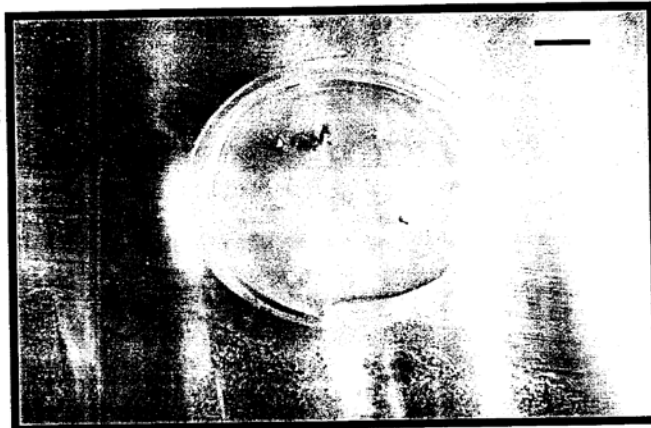

Fig.3. *Trichophyton verrucosum* . Two weeks old Colonies on SDA medium (Bar = 1 cm).

DISCUSSION

Dermatophytosis (ringworm) is a common infectious disease of many domestic animals. Its incidence is related to geographical region climate and animal husbandry techniques. It is more common in young, stray, sick, or debilitated animals. It is of increasing significance because of its zoonotic potential, especially in humans in an immuno-compromised state (18,19). In this study which is the first on dermatophytosis of sheep in Basrah, the only causative fungus isolated was *Trichophyton verrucosum*, which is a zoophilic dermatophyte causes many types of dermatophytosis of human in Basrah (3). The young animals were more susceptible to dermatophytosis than adults because of the low pH of lamb skin and the most noticeable clinical signs were more or less circular alopecic areas with thick scabs on the head and face. In other studies, *T. verrucosum* was the most common agent of ringworm infection in lambs (12,20), but Hullinger *et al.* (21) referred to *Microsporum gypseum* as the only agent of dermatophytosis cultured from wool samples collected from affected lambs in the United States.

Similar to our observations, dermatophytosis was commonly known to occur throughout the year with a higher frequency during winter (22,23). In this season close confinement of animals seems to favor the development and spread of the disease.

Higher positive result (251/268) in direct microscopy than in culture (221/268) confirms the finding of other workers (22,23), for *Trichophyton verrucosum* is isolated with some difficulty and grows slowly on SDA unless the medium is enriched with thiamine (vitamin B1) and inositol or yeast extract and differentiated from other dermatophytic species through its characteristic small colonies (Fig.4) and production of pearl-like chains of chlamydoconidia and absence of macroconidia and microconidia rarely produce which are unicellular and clavate.

Show sheep are more susceptible to infection because of frequent shampooing and washing for the wool and lanolin removed from the skin. It was referred to lanolin (the natural body oil found on sheep) as a role in preventing the fungus from entering the skin and also frequent shearing contributes to the disease as wool and lanolin are removed (12,13). The disease can spread from animal to animal or human as well as from contaminated equipment or surroundings by *Trichophyton verrucosum* spores which were known to survive several years on animals and in the environments (12,13), but our collected clinical specimens (wool and skin scales) were re-cultured after one year, and it was found that all kept spores were died.

مرض فطار الجلد في الضأن المعروضة في سوق الصفاة في البصرة / العراق

فاضل جبار فرحان**

عبد الحافظ الديون*

*قسم الأحياء البحرية، مركز علوم البحار، جامعة البصرة.
**قسم الكيمياء البحرية، مركز علوم البحار، جامعة البصرة.

الخلاصة

من مجموع ٤٤٣٧ رأساً من الأغنام (١٩٦٣ ذكراً و ٢٤٧٤ أنثى) التي فحصت للتحري عن مرض الفطار الجلدي كان ٢٤٢ حيواناً (٥,٤٥%) مصاباً بالمرض، ومن مجموع ٢٦٨ نموذج والتي جمعت من حيوانات تبدو عليها علامات جلدية لمرض الفطار الجلدي، أظهرت نتيجة موجبة حين الزرع على وسط السابروود دكستروز آكار + المضاد الحيوي الكلورامفينيكول + المضاد

الفطري السايكلوهكسامايد والمضاف إليه فيتامين B1 وخلصاة الخميرة وبالفحص المجهرى المباشر بأستخدام محلول ١٠% هايدر وكسيد البوتاسيوم. أن نسبة الإصابة بالمرض قد أختلفت في الصيف (حزيران – تشرين الأول ٢٠٠٥) عنها في الشتاء (تشرين الثاني ٢٠٠٥- آذار ٢٠٠٦)، إذ شكلت نسبة الإصابة (٣,٠٦%) و(٧,٢٩%) على التوالي. أصاب الفطر الطبقة الخارجية من الجلد وكذلك الصوف حيث سبب ظهور بقع أصابة أنتشرت مركزيا لتؤدي الى مناطق شبيه دائرية خالية من الصوف وذات ملمس طحيني الى قشري بيضاء الى رمادية اللون عادة قطرها ٢-١ سم وكان الرأس والأذن وجانبي البطن والرقبة هي أكثر أجزاء الجسم تعرضاً للإصابة، كما ان المسبب الفطري الوحيد الذي تم عزله هو الفطر الجلدي *Trichophyton verrucosum*.

REFERENCES

- 1-Austwick, P.K.C., The pathogenicity of fungi, Symposia of the Society for General Microbiology, 1972, 22,251-268.
- 2-Rippon, J.W., Medical mycology, W.B. Sanders Company, Philadelphia, USA, 1982
- 3-Al-Duboon, A.H., A study on superficial-cutaneous mycosis in Basrah (Iraq), Ph.D. Thesis, College of Science, University of Basrah, 1997, p.163.
- 4-Calderone, R.A., Immunoregulation of dermatophytosis, Crit. Rev. Microbial., 1989,16,339-368.
- 5-Pascoe, R.R., Studies on the prevalence of ringworm among horses in racing and breeding stables, Aust. Vet. J., 1976, 52,419-421.
- 6-Al-Khafaji, N.T.; Rhaymah; M.S.H. and Al-Saad, K.M., Skin diseases in deferent animal spp. Nineveh, Iraq, Iraqi J. of Vet. Sci., 1995, 13(2), 33-42.
- 7-Abou-Gabal, M.; El-Galilg, G.A.; El-Nore, E.A. and El-Rehim, D.A., Animal ringworm in Upper Egypt, Sabouraudia, 1976, 14,33-36.
- 8-Al-Ani, F.K.; Al-Bassam, L.S. and Al-Salahi, K.A., Epidemiological study of dermatomycosis due to *Trichophyton schoenleinii* in camels in Iraq, Anim. Hlth. Prod. Afr., 1995, 43,87-92.
- 9-Abdul-Aziz, J.M.; Abdullah, S.K. and Al-Duboon, A.H., A study on skin fungal infections in cows in Basrah, The Veterinarian, 2000,10(1),160-167.
- 10-Al-Ani, F.K.; Younes, F.A. and Al-Rawashdeh, O.F., Ringworm infection in cattle and horses in Jordan, ACTA Vet. BRNO., 2002, 71,55-60.

- 11-Connole, M.D., Review of animal mycoses in Australia, *Mycopathologia*, 1990, 111,133-164.
- 12-Animal Health News, , Club lamb fungus spotted at Dakota State fair, 1999, 2 (4), 1-7.
- 13-Hopkins, F.M. and Gill, W., Ringworm (club lamb fungus) in sheep, *Agricultural Extension Service*, 2006, <http://animalscience-ag.uk.edu/sheep/pdf>.
- 14-Emmons, C.W.; Binford, C.H. and Utz, J.P., *Medical mycology*, 2nd. Ed. Lea and Febiger, Philadelphia, 1974, p.508.
- 15-Frey, D., R. J. Oldfield. and R. C. Bridger., *A color atlas of pathogenic fungi*, Wolfe Medical Publications Ltd., London, UK, 1979, p.68.
- 16-Ellis, D.H., *Clinical mycology, The human opportunistic mycosis*, Pfizer, New York, 1994.
- 17-Hoog de, G. S. and Guarro, J., *Atlas of clinical fungi*, Center albureau voor schimmel- cultures and Universitat Rovirari Virgili, Spain, 1995, p. 720.
- 18-Al-Duboon, A.H.; Muhsin, T.M. and Al-Rubaiy, K.K., *Tinea capitis in Basrah, Iraq, Mycoses*, 1999, 42,331-333.
- 19-Dermatophytoses, The Centre for Food Security and Public Health, 2005, <http://www.cfsph.iastate.edu>. p.1-6.
- 20-Robbe, S., Reference and treatment guide for club lamb fungus. 2006, http://www.dlab.colostate.edu/webdocs/lect_vet/cleon15.html.
- 21-Hullinger; Cole, Jr.; Elvinger and Stewart, *Dermatophytoses in show lambs in United states*, *Vet. Dermatol.*, 1999, 10(1), 73-76.
- 22-Nooruddin, M.; Gill, B.S.; Singh, J. and Singh. K.B., *Prevalence of sarcoptic and psoroptic mange in buffaloes*, *Buffalo J.*, 1986, 2,81-86.
- 23-Nooruddin, M. and Singh, B., *Dermatophytosis in dairy animals and attendants*, *Mykosen*, 1987, 30(12),594-601.
- 24-Chatterjee, A. and Sengupta, D.N., *Ringworm in domestic animals*, *Indian J. Anim. Hlth.*, 1979, 18,19-33.