

## **EFFECT OF LONG-TERM ADMINISTRATION OF SILDENAFIL CITRATE (VIAGRA) ON SOME SPERM CHARACTERISTICS AND TESTIS ARCHITECTURE OF MALE RATS**

Khalid G. Al-Fartosi

Department of Biology , College of Education , University of Thi-Qar , Thi-Qar, Iraq

(Received 7 September 2009, Accepted 15 September 2009)

**Keywords:** Sildenafil, Sperm characteristics, Testis architecture.

### **ABSTRACT**

Sildenafil citrate (Viagra) is an oral medication used to treat male impotence by the inhibition of phosphodiesterase-5 in the corpus cavernosum and subsequent facilitation of penile erection. The side effects of sildenafil citrate have been reported. The present study was designed to investigate the effect of long term administration of sildenafil citrate on some characteristics (sperm count, sperm malformations) and testis architecture of male rats. The results indicated that the oral administration of 50 mg and 100 mg of sildenafil citrate (Viagra) for 8 weeks caused a significant decrease and a significant increase in sperm count and sperm malformations respectively. The results showed the histopathological changes in testis of male rats treated with 50 mg and 100 mg sildenafil citrate..

### **INTRODUCTION**

Erectile dysfunction (ED) is a widespread condition that can have a negative impact on quality of life (1), affecting both older and younger (2). It is defined as the inability to achieve or maintain an erection sufficient for sexual intercourse, affects approximately 1 in 10 men. The incidence increases with age and the causes of it are many including; neurogenic or vasculogenic abnormalities, psychogenic (anxiety), hormonal (hypogonadism), drug induced (responsible for up to 25% cases), or anatomical (peyronies disease) factors. Additionally, certain diseases predispose patients to erectile dysfunction, for example up to 50% of men with diabetes, 40% of men with heart disease and 90% of men with severe depression, suffer from ED( 3,4).

Sildenafil citrate (Viagra), the first oral drug which approved for the treatment of erectile dysfunction, selectively inhibits phosphodiesterase 5 (PDE5), the isozyme

that metabolizes cyclic guanosine monophosphate (c-GMP) in the corpus cavernosum (5). The penile erection is dependent on the release of nitric oxide (NO) in the corpus cavernosum during sexual stimulation. NO increase levels of (cGMP) which results during the smooth muscle relaxation and inflow of blood, and sildenafil enhanced the effect of NO by inhibiting PDE5 which is responsible for degradation of cGMP corpus cavernosum (6). When Viagra administered before sexual activity, it produces reliable efficacy, good tolerability and rapid absorption that yields prompt onset of action; it has a plasma half-life that produces an appropriate duration of action while avoiding accumulation on repeated once-daily use (5). In clinical trials, sildenafil has been shown to increase the duration and rigidity of penile erection in response to visual sexual stimuli in a hospital setting (5) and to greatly enhance the ability to achieve erections, leading to successful completion of intercourse in home setting (7). Sildenafil is rapidly absorbed after oral administration reaching maximum plasma concentration within 30-120 minutes of dosing in fasted subjects. It is therefore advised that sildenafil is taken 30-60 minutes before planned sexual activity and it still has an effect on erectile function for 4-5 hours after dosing (8).

It has been demonstrated that human sperm cells contain as yet uncharacterized PDE isoforms which are different from PDE<sub>1</sub> and PDE<sub>4</sub>, and that the in-vitro inhibition of sperm PDE<sub>1</sub> and PDE<sub>4</sub> isoenzymes by specific inhibitors stimulates acrosome reaction and sperm motility (9). Also, it is known that after acute administration of 100 mg sildenafil, the drug reaches a concentration of 0.1–0.3 µmol/l in the ejaculate (Pfizer, Viagra<sup>TM</sup> data sheet). This concentration is consistent with a possible inhibitory interaction of sildenafil with sperm PDE isoforms (10).

Sildenafil citrate is an effective drug for erectile dysfunction due to organic causes (7,10,11), however side effects have been reported such as flushing, headache, congestion and dyspepsia, occur due to the systematic vasodilator effect of the drug although no clinically adverse hemodynamic effects were observed when sildenafil was used by healthy men (5,12,13,14). Systolic and diastolic systemic arterial pressure were shown to be decreased 6% and cardiac output was also shown to be decreased 11% from the baseline during the postsildenafil exercise test (15). Sildenafil administration is contraindicated in patients who are taking nitrates or nitric oxide donors (16).

In addition to the peripheral effects of sildenafil, the localization of PDE-5 to the brain enables sildenafil to affect central nervous system functions such as

cognitive, motivational and emotional processes (17,18,19). A recent study showed that chronic sildenafil (10 mg/kg) exposure over three weeks produced an increase in aggressive behavior in mice following but not during drug administration (20,21). showed that chronic exposure to sildenafil (Viagra) affects anxiety and risk-taking behaviors in gonadally intact and castrated male rats.

In the present study we evaluated the effect of long term administration of sildenafil (50 mg & 100 mg) on some of sperm characteristics (sperm count, sperm malformation) and testis architecture of male rats.

## **MATERIALS AND METHODS**

Male rats weighing 200-250 g with 8 weeks of old were used. All animals were obtained from animal house of biology department / college of education / university of Thi-Qar / Iraq. They were housed in groups of three in a temperature controlled room ( $20\pm 2^{\circ}\text{C}$ ) with a 12 h light/12 h dark cycle (light on at 07.00 a.m.). The animals were divided into the bellow:

- 1- the control group (n=10) treated with 0.9% NaCl for 8 weeks.
- 2- The first treated group (n=10) treated with 5ppt from (50 mg) sildenafil citrate for 8 weeks.
- 3- The second treated group (n=10) treated with 5ppt from (100 mg) sildenafil citrate for 8 weeks.

The present study included the effect of sildenafil citrate (Viagra) on the following:

### **Sperm count and morphology:**

The caudal epididymis was cut and weighed. A cell suspension was prepared by macerating the cauda in 1.0 ml of 0.85% saline. The cell suspension was kept for 24 hrs at  $40^{\circ}\text{C}$ . The suspension was then filtered through a double gauze layer and an aliquot of the sample was used for sperm count in a Neubauer hemocytometer. An aliquot of the epididymal sperm suspension was smeared and stained with hematoxylin and eosin and then examined under a light microscope (Olympus, Japan) at magnification of 40X. The head and tail abnormalities (200 sperms per smear) were recorded (22).

### **Testicular histopathology:**

The testis was dissected out, cut into small slices, and fixed in 10% formaldehyde buffer for 24 hrs. The tissues were washed free of 10% formaldehyde and stored in 70% alcohol until being embedded. The tissues were dehydrated in alcohol series and embedded in paraffin. Tissue sections of 5  $\mu$ m thickness were prepared and placed on glass slides. The sections were stained with hematoxylin and eosin and mounted in mounting medium. The slides were examined under the light microscope. For each testis several cross sections composing of 20-50 tubule sections were examined for signs of interstitial edema, somniferous tubule degeneration, and congestion (22).

### **Statistical analysis:**

Statistical analysis was performed using one way analysis of variance (ANOVA). If significance was found, differences among individual group means were tested by the least significant difference (LSD) test. Values were considered statistically significant at  $P \leq 0.05$ .

## **RESULTS**

### **Effect of sildenafil citrate on sperm count :**

Long term administration of suldinafil citrate (50 mg and 100 mg) in male rats caused a significant reduced in number of sperms comparing with control group (table 1). The results also indicated that the treatment of male rats with 100 mg of Viagra was more effective from than those rats treated with 50 mg of Viagra.

### **Effect of sildenafil citrate on sperm morphology:**

The chronic treatment of the male rats with suldinafil citrate revealed a significant increased in abnormal sperms compared with control group. The results indicated that these changes were more effective in the rats treated with 100 mg compared with animals treated with 50 mg of Viagra (table 2).

Table (1): Effect of long term administration of sildenafil citrate on sperm count of male rats.

Treatments	N. of samples	Sperm count in mm <sup>3</sup> ( x10 <sup>4</sup> ) Mean +-S.E.
Control group	10	93.4 ±1.22
Group treated with 50 mg sildenafil citrate	10	60.7 * ±1.54
Group treated with 100 mg sildenafil citrate	10	23.5 ** ±1.45

\* There is a significant difference compare with control group at  $P \leq 0.05$ .

\*\* There is significant difference compare with group treated with 50 mg sildenafil citrate at  $P \leq 0.05$ .

Table (2): Effect of long term administration of sildenafil citrate on sperm malformations of male rats

Treatments	N. of samples	Normal sperms %	Abnormal sperms %
Control group	10	90.56 ±0.28	9.44 ±0.21
Group treated with 50 mg sildenafil citrate	10	35.5 * ±0.34	64.5 * ±0.42
Group treated with 100 mg sildenafil citrate	10	8.40 ** ±0.29	91.60 ** ±0.35

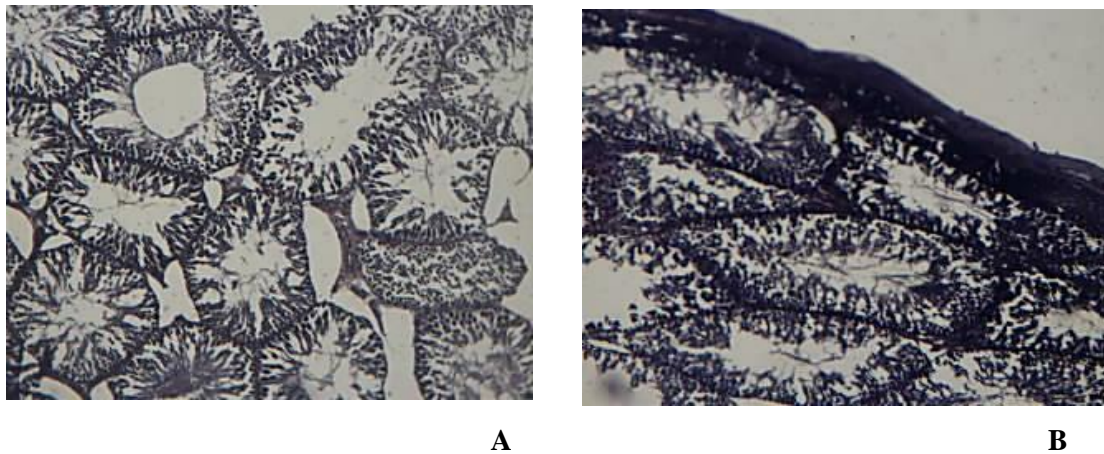
\* There is a significant difference compare with control group at  $P \leq 0.05$ .

\*\* There is significant difference compare with group treated with 50 mg sildenafil citrate at  $P \leq 0.05$ .

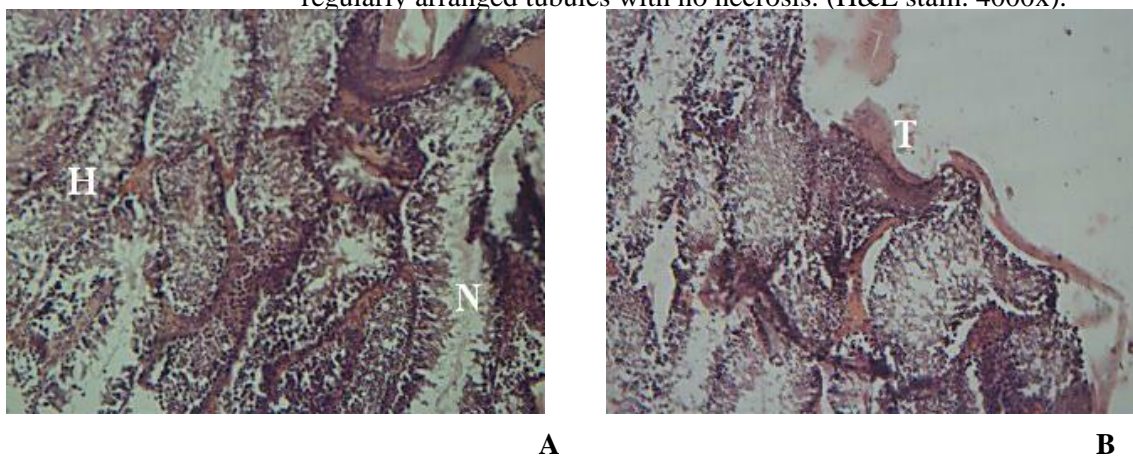
### Effect of sildenafil citrate on testes (testicular histopathology) :

The results of the present study indicated that the administration of 50 mg and 100 mg of Viagra for male rats caused histopathological changes in testis of male rats. All sections of testes collected from rats administrated 50 mg and 100 mg sildenafil citrate had necrosis of both somniferous tubules and the interstitial tissue, congested blood vessels, hypertrophy of the interstitial leydig cells and degeneration of the spermatogonial cells (figure

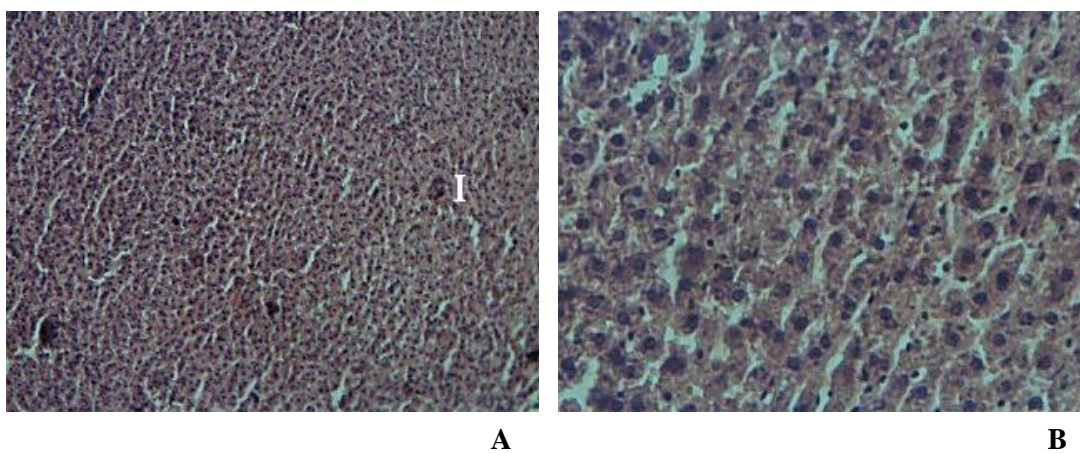
2 and figure 3). Also, the basement membrane was thin compare with thickness of basement membrane in control group, and loss of lumen architecture and loss spermatogenesis in testis of rats treated with 50 mg of sildenafil citrate (see figure 2 A,B). The result showed the destruction of testis and the presence of inflammatory cells in testis of male rats treated with 100 mg of Viagra (see figure 3 A,B). Control rats didn't have these histological abnormalities (figure 1).



**Figure 1:** Cross section of the seminiferous tubules in the testis of a control rat: notice regularly arranged tubules with no necrosis. (H&E stain. 4000x).



**Figure 2:** Cross section of the seminiferous tubules in the testis of rat administrated 5ppt of 50 mg sildenafil citrate (Viagra) : H: hypertrophy cells . N: necrosis of seminiferous tubules . T: thin of basement membrane. (H&E stain. 4000x).



**Figure 3:** Cross section of the somniferous tubules in the testis of rat administrated 5ppt of 100 mg sildenafil citrate (Viagra), shows complete destruction of seminiferous tubules. I: inflammatory cell. (H&E stain. 4000x).

## **DISCUSSION**

In the present study we investigated the effect of long term administration of sildenafil citrate on sperm count, sperm malformations and testicular histopathological changes of male rats. Sildenafil citrate caused sperm abnormality (decrease number of sperms and increase of sperm's malformations ) which supported by the histopathological changes in testis (hypertrophy cells, necrosis of seminiferous tubules, destruction of testis and presence of inflammatory cells ), these effects may be according to the changes in the expression of various receptors associated with cGMP or in the responsiveness of these receptors in the brain, and then this will caused damage in tissue of testis and failure in spermatogenesis (23,21). Alternatively, the inhibition of cGMP breakdown may produce changes in nitric oxide (NO) production via negative feedback mechanisms (24). NO may be able to affect neurotransmitter activity differentially across brain systems (21,25). showed a significant decrease in total sperm out put and sperm concentration in both insulin dependent (IDDM) and non insulin dependent (NIDDM) diabetic neuropathy patients after the oral administration of sildenafil when compared with the same values obtained before the administration of drug.

The very limited data available on the effects of sildenafil citrate on seminal parameters reveals that the oral administration of sildenafil citrate has some role on seminal parameters in the patients of erectile dysfunction. At least two distinct PDE isoforms (PDE1 and PDE4) have been demonstrated to be present in human sperm cells. Specific inhibition of PDE1 and PDE4 by 8-methoxy-isobutyl-methylxanthine and rolipram selectively stimulates the acrosome reaction and sperm motility respectively (9). After assimilation sildenafil circulates in plasma at micro molar concentrations which can cause a minor inhibition of PDE6 and PDE1 activities (ED50 1:10 and 1:100 of PDE5 inhibition respectively) and determine transient side effects (13).

(26,27,28)) indicated that sildenafil is potentially retinotoxic due to an associated increase in retinal c-GMP, and it has been shown to cause a depression of electroretinogram (ERG) functions suggesting clinical toxicity of the retina. . (29) showed that sildenafil had no statistically significant effect on sperm motility, count or density, the percentage of abnormal sperms, or the percentage of living sperm when 17 healthy male volunteers aged 19-34 years were randomized to receive a single dose of 100 mg dose of sildenafil for two periods and a single dose of placebo for two periods, with each period separated by a minimum of 5-7 days.

(30,31) found the minimal effect of sildenafil on sperm motility and count in men of reproductive age. In the study of 20 healthy male volunteers, (32) found no difference in



sperm number, progressive motility or morphologic abnormalities between semen samples obtained 1 hour after taking a 100 mg dose of sildenafil or double blind placebo.

Sildenafil citrate is rapidly absorbed, reaching maximum plasma concentrations within one hour after oral usage, and has a mean terminal half-life is 3 to 5 hours (33,34). showed minimal reductions in systemic and pulmonary artery pressure without any serious cardiovascular effects after sildenafil usage. (35) reported that sildenafil had no significant effect on aortic and superior mesenteric artery blood flow in ED patients, they did however observe mild blood flow alteration in the carotid arteries. In a recent study performed in dogs, significant increases were observed for the Vmax and RI of the aorta as well as decreases in the right carotid and left segmental renal artery Vmax (36).

Sildenafil has modest effects on blood pressure in normal subjects, producing an average decrease approximately 10-mm Hg after a single oral dose 100-mg ( 37,38). found that the vertebral artery diameter, area, and FV increased significantly following the administration of sildenafil citrate. The diameter, area and FV increased from 3.39 mm at 45 minutes to 3.64 mm at 75 minutes, 9.43 cm<sup>2</sup> to 10.80 cm<sup>2</sup> at 45 minutes and 10.81 cm<sup>2</sup> at 75 minutes, as well as from 0.07 L/min at baseline to 0.09 L/min at 45 minutes and unchanged at 75 minutes, respectively.

## **CONCLUSIONS**

According to high used of sildenafil citrate and in addition to the results of the present study we believed that it is very important for the increase of the studies related with the effect of the chronic administration of Viagra. The present study showed the correlation between the administration of Viagra and infertility in men.

## تأثير التعرض لفترة طويلة لخلات السلدينافيل ( الفياكرا ) على بعض خصائص النطف وقوام الخصية في ذكور الجرذان المختبرية

خالد كاطع الفرطوسي

قسم علوم الحياة، كلية التربية ، جامعة ذي قار ، ذي قار ، العراق

### الخلاصة

تستخدم خلات السلدينافيل (الفياكرا) لمعالجة العجز الجنسي لدى الذكور من خلال تثبيط الفوسفودايستريز - 5 ، وقد سجلت التأثيرات الجانبية لاستخدام هذا العلاج .صممت الدراسة الحالية لبحث تأثير التعرض لفترة طويلة للفياكرا على بعض خصائص النطف (عدد الحيامن وتشوهاتها) وقوام الخصية في ذكور الفئران المختبرية .النتائج أظهرت أن التجريع الفموي للفياكرا بتركيز 50 ملغم و100 ملغم لمدة ثمانية أسابيع قد سبب انخفاض معنوي في عدد الحيامن مع زيادة معنوية في الحيامن المشوهة مقارنة مع مجموعة السيطرة . كما اظهرت النتائج تغيرات نسجية في خصى ذكور الجرذان المعاملة بالتركيزين المذكورين

### REFERENCES

1. NIH. (1993). Consensus Development Panel on Impotence. *JAMA*, 270: 83-90.
2. Feldman, H.A.; *et al.* (1994). Impotence and its medical and Psychosocial correlates: Results of the Massachusetts male aging study. *J. Urol.*, 151:54-61.
3. Holmes, S.; Kirby, R. and Carson, C. (1997). Fast facts-male erectile dysfunction. Health press. Oxford.
4. Wanger, G. and Tejada, I.S. (1998). Update on male erectile dysfunction. *B. M. J.*, 316:678-682.
5. Boolell, M.; *et al.* (1996). Sildenafil: an orally active type 5 cyclic GMP-specific phosphodiesterase inhibitor for the treatment of penile erectile dysfunction. *Int. J. Impot. Res.*, 8:47-52.
6. Moncada, S. and Higgs, A. (1993). The L-arginine-nitric oxide pathway. *N. Engl. J. Med.*, 329:2002-2012.

7. Goldstein, I.; *et al.* (1998). Sildenafil study group. Oral sildenafil in the treatment of erectile dysfunction. *N. Engl. J. Med.*, 338:1397-1404.
8. Eardley, I.; *et al.* (1998). Sildenafil (Viagra ): an oral therapy for erectile dysfunction (ED) with efficacy of at least 4 hours duration. *Int. Impot. Res.*, 10(3):292-298.
9. Fisch, J.D., Behr, B. and Conti, M. (1998) Enhancement of motility and acrosome reaction in human spermatozoa: differential activation by type-specific phosphodiesterase inhibitors. *Hum. Reprod.*, **13**, 1248–1254.
10. Fabbri, A., Aversa, A. and Isidori, A. (1999). Sildenafil and erectile dysfunction: *J. Endocrinol. Invest.*, **22**, 486–491.
11. Medina, P.; *et al.* (2000). Effects of sildenafil on human penile blood vessels. *Urology*, 56:539-543.
12. Morales, A.; *et al.* (1998). Clinical safety of oral sildenafil citrate in the treatment of erectile dysfunction. *Int. J. Impot. Res.*, 10:69-74.
13. Jackson, G.; *et al.* (1999). Effects of sildenafil citrate on human hemodynamic. *Am. J. Cardiol.*, 83:13-20.
14. Marmor, M.F. and Kessler, R. (1999). Sildenafil (Viagra) and ophthalmology. *Surv. Ophthalmol.* 44:153-162.
15. Conti, C.R.; Pepine, C.J. and Sweeney, M. (1999). Efficacy and safety of sildenafil citrate in the treatment of erectile dysfunction in patients with ischemic heart disease. *Am. J. Cardiol.*, 83:29-34
16. Kurt, M.; *et al.* (2004). Effect of sildenafil on anxiety in the plus-maze test in mice. *Polish Journal of Pharmacology*, 56:353-357
17. Devan, B.D.; *et al.* (2006). Phosphodiesterase inhibition by sildenafil citrate attenuates a maze learning impairment in rats induced by nitric oxide synthase inhibition. *Psychopharmacology*, 183:439-445.
18. Tashili-Fahadan, P.; *et al.* (2006). Rewarding properties of sildenafil citrate in mice: Role of the nitric-cyclic GMP pathway. *Psychopharmacology*, 185:201-207

19. Hotchkiss, A.K.; *et al.* (2005). Aggressive behavior increases after termination of chronic sildenafil treatment in mice. *Physiology and Behavior*, 83:683-688.
20. Solis, A.A.; Bethankourt, J.A. and Britton, G.B. (2008). Chronic sildenafil (Viagra) administration reduces anxiety in intact and castrated male rats. *Psicothema*, 20:812-817.
21. Tocharus, C.; *et al.* (2005). Effects of long-term treatment of *Butea superba* on sperm motility and concentration. *Naresuan University Journal*, 13(2):11-17.
22. Hardley, M. E. (2000). Endocrinology. Prentice-Hall, Inc. PP. 585.
23. Canteros, G.; *et al.* (1996). Nitric oxide synthase content of hypothalamic explants: Increase by norepinephrine and inactivated by NO and cGMP. *Proceedings of the National Academy of Sciences USA*, 93:4246-4250.
24. Ali, S.T. and Rakkah, N.I. (2007). Neurophysiological role of sildenafil citrate (Viagra) on seminal parameters in diabetic males with and without neuropathy. *Pak. J. Pharm. Sci.*, 20(1):36-42.
25. Kretschmann, U.; *et al.* (1999). Short time influences on visual function. *Invest. Ophthalmol. Vis. Sci.*, 40:766.
26. Vobig, M.A.; *et al.* (1999). Retinal side effects of sildenafil. *Lancet*, 3:353-375
27. . Luu, J.K.; *et al.* (2001). Acute effects of sildenafil on the electroretinogram and multifocal electroretinogram. *Am. J. Ophthalmol.*, 132:388-394
28. Purvis, K.; Muirhead, G.J. and Harness, J.A. (2002). The effect of sildenafil citrate on human sperm functions in healthy volunteers. *J. Clin. Pharmacol.* 53:535-605.
29. Burger, M.; *et al.* (2000). The effect of sildenafil on human sperm motion and function from normal and infertile men. *Int. J. Impot. Res.*, 12:229-234.
30. Zavos, P.M. and Zarmakoupis-Zavos, P.N. (2000). The use of sildenafil citrate for treatment of male infertility in males with erectile dysfunction. *Obstet Gynecol.*, 95:549-550.

31. Aversa , A.; *et al.*(2000). Effect of sildenafil (Viagra) administration on seminal parameters and post-ejaculatory refractory time in normal males. *Hum. Reprod.*, 15:131-134.
32. Arnavaz, A.; *et al.*(2003). Effect of sildenafil (Viagra) on cerebral blood flow velocity: a pilot study. *Psychiatry Res.*, 122:207-209.
33. Herrmann, H.C.; *et al.* (2000). Hemodynamic effects of sildenafil in men with severe coronary artery disease. *N. Engl. J. Med.*, 342:1622-1626.
34. Kocakoc, E.; *et al.* (2005). Effects of sildenafil on major arterial blood flow using duplex sonography. *J. Clin. Ultrasound*, 33:173-175.
35. Serhatlioglu, S.; *et al.* (2003). Evaluation of the effects of sildenafil citrate (Viagra) on canine renal artery, carotid and aortic blood flow with the aid of color Doppler sonography. *Urol. Int.*, 71:103-107.
36. Webb, D.J.; Boolell, M. and Muirhead G. (1998). Cardiovascular effects of phosphodiesterase type 5 inhibition with concomitant nitrate therapy. *Circulation*, 98(17):637.
37. Hackett, G. (1998). Managing erectile dysfunction. *Practitioner*, 242:632-636.