

KERATOCONJUNCTIVITIS IN DROUGHT HORSES IN BASRAH, BASRAH-IRAQ

Kamal M. Alsaad,* Basil A. Abbas**J.Yaseen**

*Department of Internal and Preventive Medicine, College of Veterinary Medicine,
University of Mosul, Mosul, Iraq

**Department of Microbiology, College of Veterinary Medicine, University of Basrah,
Basrah, Iraq

(Received 20 August 2010,Accepted 20 September 2010)

Keywords; conjunctivitis, drought horses, Blepharospasm,.

ABSTRACT

The objective of the present work was to investigate infectious keratoconjunctivitis in drought horses in Basrah Province (Basrah-Iraq). The study was conducted on (200) local drought horses (3-10) years old and of both sexes. Animals were brought and examined at the consultant veterinary hospital-college of veterinary medicine-university of Basrah, during the period from July 2007 to June 2008. Result revealed that out of (200) drought horses, (77) animals have been exhibited the clinical signs of keratoconjunctivitis, with a prevalence rate of (38.5%). Diseased animals show signs of, severe conjunctival hyperemia, serious, mucoid and/or purulent ocular secretions, restless and anxiety, Presence of flies around the eyes, edematous eyes, Photophobia, Blepharospasm, rubbing eyes against hard objects, and corneal opacity. Results were also indicated different causative agents which were responsible for the disease, either in the form of single or mixed infection. *Thelazia lacrymalis* being the most important nematode detected, moreover *Staphylococcus aureus*, *E.coli*, *Klebsiella spp*, *Streptococcus spp.*, and *Pseudomonas aeruginosa*, were indicated as the main and common bacteria which were isolated from infected eyes of diseased drought horses, Furthermore yeast, *Cladosporium cladosporioides*, *Candida albicans* and *Aspergillus niger* were represent the fungal microorganisms isolated from infected eyes of diseased drought horses. Flies which found congregated around infected eyes were diagnosed as *Musca spp*.

INTRODUCTION

Keratoconjunctivitis refer to inflammation of the covering membranes of the eye including the orbit and the inner surfaces of the eye lids which may extend to layers below conjunctiva (1, 2). The disease requires prolonged and expensive treatment, therefore under worst circumstances, it can result in blindness or need for enucleating (3, 4).

The disease in horses considered as one of the most common, serious and painful type (5). A number of infectious agents have been reported to cause the diseases in horses such as, bacterial, parasites, fungi and viruses (6).

The diseases transmitted either by direct contact with an infective material from one animal to another, or by indirect transmission of conjunctival exudates by flies (1). Cattabiani (7) isolated more than (16) types of microorganisms from the conjunctival sac suffering from eye affections, whereas (8) describe *E. coli*, *Listeria monocytogenus*, *Proteus mirabilis*, *Moraxella equi* and *Klebsiella spp.* as a main causes isolates from diseased eyes of horses in Mosul –Iraq.

Thelazia lacrymalis is a common eye worms of horses, present in different structures of ocular tissues and have an adverse effect lead to sever inflammation and corneal ulceration (9). The nematode parasite was found in eye lids of (16) horses out of (57) examined (10, 11).

Fungi have been isolated from the conjunctival sac of horses (12) and surveys in horses identified (35) genera of these organism (5). Moreover (4) mention *Aspergellus*, *penicillum*, *Alternaria*, *Fusarium* and *Cladosporium* isolated from equine eyes.

Studies of keratoconjunctivitis in Drought horses are very scarce and little information had been provided in Basrah province (Basrah- Iraq), therefore the present study were undertaken to examine clinical cases of drought horses affected with keratocounjunctivitis and to detect the common microbiological causes.

MATERIALS AND METHODS

1- Animals and clinical examination:

The study was carried out in Basrah province (Basrah-Iraq) on (200) drought horses, 3-10 years old, of both sexes. Diseased horses were brought and examined at the Consultant Veterinary Hospital, College of Veterinary Medicine, University of Basrah, during the period from July 2007 to June 2008. Careful clinical and microbiological examination had been carried out in all animals. A complete history was obtained upon presentation in the clinic and emphasis was placed on clinical signs observed, course and duration of the presenting complaint, upon completion of the general examination a bilateral ophthalmologic examination was performed.

Prior to direct ophthalmologic examination, each horse was observed from a distance. The bony orbita and palpebral fissures were examined for symmetry, eyelid position was evaluated, and any deviation from normal or presence of palpebral edema was noted, Assessment of any ocular discharge was made according to its appearance and viscosity.

The menace response was measured bilaterally in each patient by rapidly moving a hand within the horse's visual field and care was taken to avoid creating wind currents or contact with the eyelashes which could lead to false positive reactions, the menace response was tested from several different angles (6).

During the direct ophthalmologic examination, the palpebral margins and the conjunctiva were examined for signs of inflammation, and the position of the third eyelid was evaluated, and opening of the palpebral fissure is readily achieved by using the thumb and forefinger from the same hand while approaching from the temporal aspect of the eye, the conjunctival surface appearance, color, and consistency were then evaluated, furthermore prolapse of the third eyelid using digital pressure placed indirectly on the dorsal globe through the upper eyelid facilitated examination of the outer surface (1).

2- Collection of samples

Several methods for obtaining samples were done for further diagnostic evaluation. Sixty swab samples of clinically diagnosed keratoconjunctivitis of drought horses were collected, sterile swabs inserting into the conjunctival fornix, gently rolled and then inoculated into nutrient broth, transferred to specific agar. Swabs were transferred to laboratory in ice box as soon as possible. Further sampling using a sterile dry swab was also done, smeared over a glass slide and then stained with Gram and Giemsa stains for bacterial and fungal identification.

Bacterial isolates growing on nutrient, blood and MacConkey agar after incubation for 24-48 hours at 37° C which were identified according to (13). The following biochemical tests were used for identification: coagulase, catalase, DNase, triple-sugar iron test, oxidase test, citrate utilization test, indole test, methyle red test, urase test, H₂S production test, and motility test.

Fungi growing on saburoid dextrose agar were identified according to (14) after examination of colonies characteristics and microscopic slides techniques.

Identification of *Thalazia spp.* was taken according to (15). Nematode parasites were collected from the conjunctival sac and placed in vials containing 70% ethanol and identified based on morphological characteristics under light microscope.

Flies which were congregated around eyes were taken by forceps, applies in normal saline and send to parasitological laboratory for identification (16).

RESULTS

Results revealed that 77 drought horses out of 200 were exhibited different sings of keratoconjunctivitis with a prevalence rate of (38.5%). Diseased horses were show sings of sever conjunctival hyperemia (88.3) (photo.1), serious, mucoid and/or purulent ocular secretions (72.7) (photo 2), restless and anxiety (59.7), presence of flies around the eyes (55.8), edematous eyes (50.6), photophobia (37.6), blepherospasim (28.5), rubbing eyes against hard objects (23.3) (photo 3), and corneal opacity (14.2) (photo4). Table (1).

Table (1) Clinical sings of infected horses with keratoconjunctivitis

Clinical sings	Numbers of animal affected	%
Sever conjunctival hyperemia	68	88.3
Serious, mucoid /purulent ocular secretions	56	72.7
Restless and anxiety	46	59.7
Presence of flies around the eyes	43	55.8
Edematous eyes	39	50.6
Photophobia	29	37.6
Blepherospasim	22	28.5
Rubbing eyes against hard objects	18	23.3
Corneal opacity	11	14.2

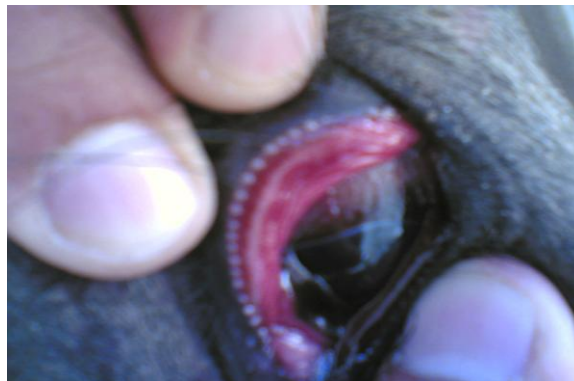

Photo 1. Severe conjunctival hyperemia

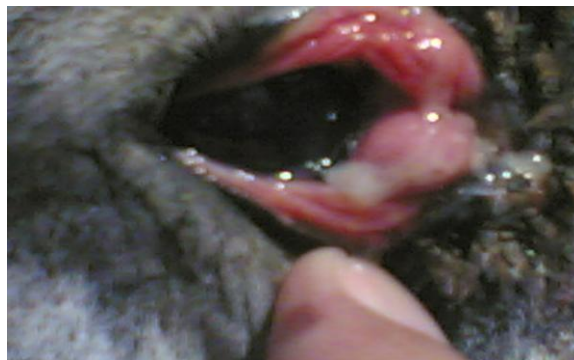


Photo 2. Mucoied ocular discharges

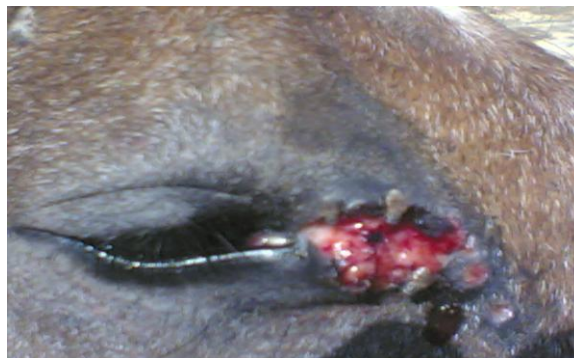

Photo 3. Rubbing eyes against hard objects with cogregation of flies

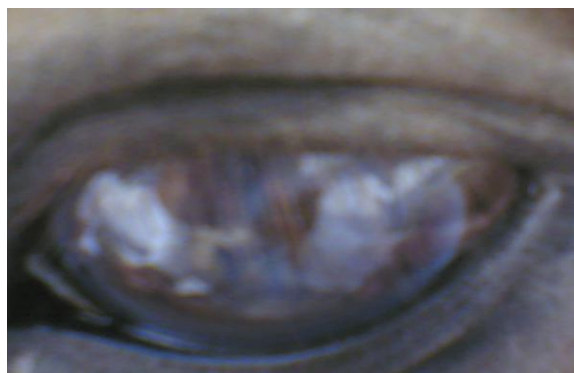

Photo 4. Corneal opacity

Results also indicated that *Thelazia lacrymalis* were detected in (21.66%) of infected drought horses ,moreover the bacterial isolates revealed that different bacterial organisms were detected in a single infection ,includes *Staphylococcus aureus*, *Klebseilla spp.* and *E. coli* which were isolated from (13.3%), where as *Streptococcus spp.* and *Pseudomonas arigenosa* were isolated from (8.3%) of infected drought horses. Results also showed that mix infection with more than one organism were also indicated which include, mixed infection of *Proteus spp.* and yeast (5%), mixed infection of *Staphylococcus aureus* with *Thelazia lacrymalis* (5%), mixed infection of *Staphylococcus aureus* and *Aspergillus niger* and yeast (3.33%), mixed infection of *Staphylococcus aureus*, *E. coli* and (3.33%), *Klebseilla spp.* with *Aspergillus niger* (1.66%) Table (2).

Table (2) Isolates of single and mixed infection of drought horses infected with keratoconjunctivitis

Causative agent	Number of isolate	%
<i>Thelazia lacrymalis</i>	13	21.66
<i>Staphylococcus aureus</i>	10	16.66
<i>E.coli</i>	8	13.3
<i>Klebseilla spp</i>	8	13.3
<i>Streptococcus spp.</i>	5	8.3
<i>Pseudomonas arigenosa</i>	5	8.3
<i>Preotus spp</i> + yeast	3	5
<i>Staphylococcus aureus</i> + <i>Thelazia lacrymalis</i>	3	5
<i>Staphylococcus aureus</i> + <i>Aspergillus niger</i> +yeast	2	3.33
<i>Staphylococcus aureus</i> + <i>E.coli</i>	2	3.33
<i>Klebseilla spp</i> + <i>Aspergillus niger</i>	1	1.66
Total	60	100

Fungi were found as filamentous or as yeast form in (16.66%) of infected drought horses with keratoconjunctivitis which include yeast (8.33%), *Cladosporium cladosporoides* and *Candida albicans* which indicated in (3.33%) of total isolates, whereas *Aspergillus niger* was found in one sample only (1.6%) Table (3).

Table (3) Fungal isolates from drought horses infected with keratoconjunctivitis

Fungi	Number of isolates	%
Yeast	5	8.33
<i>Cladosporium cladosporoides</i>	2	.33
<i>Candida albicans</i>	2	3.33
<i>Aspergillus niger</i>	1	1.66
Total	10	16.66

DISCUSSION

Keratoconjunctivitis is a serious condition that commonly results in adverse effect of diseased horses. Nevertheless corneal ulceration, abscessation with loss of the globe, might be the final results. In this study, special emphasis was placed on the drought horses exhibited clinical sings of keratoconjunctivis ,out of 200 drought horses, 77 animals were found infected and exhibited sings of keratoconjunctivitis with an prevalence rate of (38.5%). Different infection rate were also reported by others (8, 17, 18), whom mention that the variation of these rates may be attributed to the animal susceptibility, beside probability of exposure which governed by animal housing and management system, season and localities, thereby susceptibility were increased through some factors such as the presence of flies which might considered as a main transmitter, horse owners and groomers persons whom play good role in mechanical transmission of the infection and the presence of other pathogens.

Keratitis and conjunctivitis often occur simultaneously, Nevertheless, the term keratoconjunctivitis is inconsistently used by clinicians to describe diseases of the cornea with conjunctival involvement (2). Rebhun (19) describes several forms of conjunctivitis having bacterial, viral, fungal and parasitic etiology. In current study drought horses exhibited different clinical sings of the disease, which were reported by (1, 2, 10).

Blood vessels are lacking in the normal ocular tissues, vascularization of the corneal stroma occurs in response to pathologic processes and to aid in stromal healing, corneal vascularization is either superficial or deep and provides insight as to the duration of the corneal inflammation, superficial vessels are contained within the anterior third of the stroma and form an extension of the conjunctival circulation originating at the limbus, these vessels are bright red in color and tend to branch extensively, deep vessels can usually be identified by their dark red, straight appearance, and lack of branching. Because they are continuous with the ciliary circulation, they disappear at the limbus and the depth at which the vessels appear are some indication to the depth of the initiating corneal lesion (6).

Ophthalmic edema is the result of excess fluid accumulation within the stroma which forces the collagen laminae apart, thereby causing a loss of transparency, the accumulation of fluid occurs as a result of disturbances in either epithelial or endothelial regulating function, clinically, corneal edema appears hazy-blue and is either localized around a specific lesion or it seen throughout the entire surface and once the underlying cause has been removed and the fluid-balance re-established, corneal edema is usually reversible, however, in cases of chronic corneal edema, vascularization, and occasionally, bullous keratopathy may occur which is recognized as fluid-filled vesicles forming beneath and within the corneal epithelium, and finally recurring ulceration may occur as a result of their presence (20).

The pathogenesis of most bacteria responsible for keratoconjunctivitis were mentioned (2, 21, 22) which involve the expression of pili that enables the bacterium to adhere to the corneal epithelium and liberation of cytotoxin that lyses corneal epithelial cells and host neutrophils. Brooks (23) added that organisms such as *Escherichia coli* and *Pseudomonas*, *Proteus*, *Klebsiella* and *Enterobacter* species most commonly associated with melting of the corneal stroma and the polymorphonuclear inflammatory response releases collagenolytic enzymes that result in extensive tissue loss, however, beta-

haemolytic *Streptococcus* species are associated with very aggressive corneal ulceration, frequently in association with stromal malacia and a secondary uveitis .

In all species, including man, mycotic keratitis is regarded as a secondary infection by opportunistic filamentous fungi and budding yeasts, usually following a corneal injury (24). Many different fungi have been isolated from the conjunctival sac of horses, including *Aspergillus* species and other moulds such as *Cladosporium*, *Mucor*, *Fusarium*, *Alternaria* and *Candida* species (12). Other survey identified 35 genera of fungi (5).

It has been suggested that *Candida* species could infect the eye through direct contact, because it is frequently found on the hands of horse owners and the species present may depend on the geographical area and climate (24). *Aspergillus* species are the species most frequently isolated from the conjunctival sac of horses (25, 26). The disruption of the corneal epithelium may lead to the direct inoculation of the organisms into the cornea by contamination (27). Moreover the prolonged topical application of antibiotics may cause a shift in the normal conjunctival flora from Gram-positive to Gram-negative organisms, which may increase the incidence of keratomycosis, furthermore Corticosteroids will promote fungal growth (4).

Thelazia lacrymalis is a common eye worms of horses occur on the surface of the cornea and conjunctiva, under the nictitating membrane, in the lachrymal gland and its ducts, in the ducts of third eye lid gland and in the nasolacrymal duct, and may even invade the globe and anterior chamber (9). Giangaspero (28) describe the pathogenetic effect of this nematode and refer to mild to severe conjunctivitis and blepharitis with necrotic exudation. Smith (29) and Traversa (15) added that keratitis, including opacity, ulceration, perforation and permanent fibrosis may developed in severe cases. Moreover Larvae are released into the lacrymal secretion, from which they are ingested by the intermediate host *Musca spp.* (30).

ACKNOWLEDGEMENT

This article was supported by the College of Veterinary Medicine, University of Basrah, Basrah-Iraq.

التهاب الملتحمة والقرنية المعدي في خيول السحب في البصرة (البصرة- العراق)

كمال الدين مهلهل السعد* باسل عبد الزهرة عباس **جلال ياسين**

فرع الطب الباطني والوقائي كلية الطب البيطري، جامعة الموصل، موصل، العراق*

فرع الاحياء المجهرية، كلية الطب البيطري، جامعة البصرة، البصرة، العراق **

الخلاصة

كان الهدف من هذه الدراسة هو التحري عن التهاب الملتحمة والقرنية المعدي في خيول السحب في البصرة (البصرة-العراق). شملت الدراسة فحص (200) من خيول السحب باعمار تراوحت بين (3-10) سنة ومن كلا الجنسين والتي جلبت للفحص السريري الى المستشفى البيطري الاستشاري والتابع لكلية الطب البيطري -جامعة البصرة للفترة من شهر تموز 2007 وحتى حزيران 2008. بينت نتائج الدراسة ان (77) حيوانا من خيول السحب عانت من التهاب الملتحمة والقرنية المعدي و بنسبة انتشار مرضي (38.5 %). اظهرت الخيول المصابة اعراض سريرية تمثلت باحمرار الملتحمة الشديد، مع ارتشاح لافرازات مصلية او مخاطية او قيحية احيانا، كما اظهرت

الخيول المصابة علامات القلق وعدم الراحة، ولوحظ تجمع الذباب حول العيون، وذمة العيون، رهاب الضوء مع غمز العيون، كما اظهرت الخيول المصابة علامات حك العيون، وعتامة القرنية. اوضحت نتائج الدراسة ايضا ان عوامل احيائية دقيقة متعددة كانت هي المسؤولة عن احداث المرض، حيث ظهرت الديدان الخيطية نوع (*Thelazia lacrymalis*) اهمية كبيرة في احداث الخمج، فضلا عن عزل وتصنيف جراثيم المكورات العنقودية الذهبية، الاشريشيا القولونية، الكبسيلا، المكورات السبحية وزوائف الريجينوزا، كما تم عزل خمائر (*Cladosporium cladosporoides*) والمبيضات (*Candida albicans*) والرشاشيات السود (*Aspergillus niger*) كمسببات فطرية احدثت الخمج في عيون خيول السحب المصابة، وقد تم تشخيص ذباب الوجة متطفلا على عيون الخيول الخمجة من جنس *Musca spp*.

REFERENCES

- 1- Brooks, DE. Equine Ophthalmology. In: Gelatt, KN. (ed.): Veterinary Ophthalmology. 1999. Lippincott Williams & Wilkins, Baltimore, Maryland. 1053-1116.
- 2- Radostitis, OM., Gay, CC., Blood, DC and Hinchliff, KW. 2007. Veterinary Medicine. A text book of the diseases of cattle, sheep, goats and horses. 10th ed, WB Saunders Co. pp:994-995.
- 3- Robinson, N E. Current Therapy of Equine Medicine 7^{ed} ed., N. E. Saunders Company. Philadelphia, 1997. PP: 670.
- 4- Chang, M and Krohne, S. 2000. Fungal infection of the eye. *Epi. Vet. J.* 3 (2) 1-2.
- 5- Andrew, S E., Nguyen, A., Garlin, L., Jones, S. & Brooks, DE. Seasonal effects on the aerobic bacterial and fungal conjunctival flora of normal thoroughbred broodmares in Florida. *Vet. Ophthalmol.* 2003 **6**, 145-150
- 6- Slatter, DH. Fundamentals of Veterinary Ophthalmology. W.B. Saunders Company, Philadelphia. 2001: 260-313.
- 7- Cattabiani, F. Cabassi, E. Allodi, C. Gianell, F. 1976. Bacterial flora of the conjunctival sac of the horse. *Annali Sclavo.* 1976: 18: 91-119. *Vet. Bull.* 1977. 47:579.
- 8- Al-Khafaji, NJ., Hadad, JJ., Al-Saad, KM. 1996. Common eye affections in horses in Mosul, Iraq. *Iraq. J. Vet. Sci.* 1996. 9(1):53-56
- 9- Beelitz, P., Dongus, H., Schol, HG. and Gothe, R. *Thelazia lacrymalis* (Nematoda, Spirurida, Theaziidae) report in a horse in Germany and contribution to the morphology of adult worms. *Parasitol. Res.* 1997. 83:627-631.
- 10- Arbuck, J.B.R., Khalil, L.F. *Thelazia lacrymalis* in the eye lids of British horses. *Vet. Rec.* 1987. 103:158-159
- 11- Batton, S. Craken, MD. Occurance and effect of *Thelazia* in horses. *Equine Prac.* 1981. 33:5-57.
- 12- McLaughlin, S. A., Brightman, AH., Helper, LC., Manning, JP and Tones, J. Pathogenic bacteria and fungi associated with extra ocular disease in the horse. *JAVMA.* 1983 182, 241-242
- 13- Quinn, PJ., Markey, BK., Carter, ME., Donnelly, WJC and Leonard, FC. Veterinary Microbiology and Microbial Disease. 1st ed. Blackwell science Ltd. London. 2002.
- 14- Carter, GR and Jr, JRC. Diagnostic Procedures in Veterinary Bacteriology and Mycology, 5^{ed} Academic press. Inc. 1990. pp:371.
- 15- Traversa, D., Otranto, D., Iorio, R and Giangaspero, A. Molecular characterization of *Thelazia lacrymalis* (Nematoda, Spirurida) affecting equids: a tool for vector identification. *Mol. Cell Probes.* 2005. 19, 245-249.

- 16- Pont, A.C., Werner, D., Kachvoryan, EA.. A preliminary list of the Fanniidae and Muscidae (Diptera) of Armenia. Zoology in the Middle East .2005.36:. 73–86
- 17- Moore CP, Collins BK, Fales WH. Antibacterial susceptibility patterns for microbial isolates associated with infectious keratitis in horses: 63 cases (1986-1994). J AVMA.. 1995. 207:928-933.
- 18- Ball MA, Rebhun WC, Gaarder JE,. Evaluation fintraconazoledimethylsulfoxide ointment for treatment of keratomycosis in nine horses. JAVMA .1997. 211: 199-203.
- 19- Rebhun, WC .Ocular System. In: Colahan, PT., Mayhew, IG., Merrit, AM and Moore, JN. (eds.): Equine Medicine and Surgery. II.1999. Mosby, St.Louis. 1217.
- 20- Wilkie, DA. Equine Ophthalmology. In: Reed, SM., Bayly, WM. And Sellon, DC. (eds.): Equine Internal Medicine. Saunders, St. Louis, Missouri.1998. 739-751.
- 21- Clinkenbeard,KD and Thiessen,AE. Mechanism of action of *Moraxella bovis* hemolysin.Infect.Immun.1991.59:1148-1152
- 22- Beard ,MK and Moore.LJ.Reproduction of bovine keratoconjunctivitis with a purified hemolytic and cytotoxic fraction of *Moraxella bovis*.Vet.Microbiol.1994.42:15-33.
- 23- Brooks, D. E., Andrew, S. E., Biros, D. J., Denis, H. M., Cutler, T. J.STrubbe,D.T. & Gelatt,K.N. (2000a) Ulcerative keratitis caused by betahaemolytic *Streptococcus equi* in 11 horses. Veterinary Ophthalmology **3**,121-125
- 24- Gaarder, JE., Rebhun,WC., Ball,WMA., Patten, V., Shin, S. and Erb,H. Clinical appearances, healing patterns, risk factors, and outcomes of horses with fungal keratitis: 53 cases (1978-1996). JAVMA.1998,213, 105-112
- 25- Kearns, TJ., Brooks,DE. and White, MM. Equine keratomycoses:current concepts of diagnosis and therapy. Equine Vet. J. Supp.1983. 2, 33.
- 26- Rosa, M., Cardozo, LM., Da Silva ,PJ., Brooks, DE.,Martins, ALB., Florido, PSS and Stussi, JSP. Fungal flora of normal eyes of healthy horses from the States of Rio de Janeiro, Brazil Vet. Ophthalmol. 2003. 6 (1) 51-55.
- 27- Sansom,JH., Featherstone, K and Barnett,C.2005. Keratomycosis in six horses in the United Kingdom Vet,Rec,2005. 156, 13-17.
- 28- Giangaspero, AM., Lia ,R .,Vovlas, N and Otranto, D. Occurrence of *Thelazia lacrymalis* (Nematoda, Spirurida, Thelaziidae) in native horses in Italy.Parasitologia 1999 .41(4):545-548.
- 29- Smith, B. P. 1996. Large animal internal medicine, 2nd ed., New York, Mosby. pp: 1214-1217.
- 30- Lyons,ET., Drudge, JH and Tolliver , SC. *Thelazia lacrymalis* in Horses in Kentucky and Observations on the Face Fly (*Musca autumnalis*) as a Probable Intermediate Host. J.Parasitol. 1976. 62(6): 877-880