

EXPERIMENTAL INFECTION OF *ARCHANOBACTERIUM PYOGENES* IN ONE DAY OLD CHICKS

Mohammad A. Hamad, A. M. Al-Aalim, M.Y. Al-attar

Department Of Microbiology, College Of Veterinary Medicine, University of Mosul,Mosul, Iraq.

(Received 8 October 2012, Accepted 25 October 2012)

Keyword: *A.pyogenes*, experimental study, pathogenicity.

ABSTRACT

The present work aimed to study the pathogenicity of *Archanobacterium pyogenes* by using one day old chicks and chicken Embryonated eggs. The chicks were given the bacteria (4.2×10^8 CFU/ml) by orally administration and intraperitoneal injection, while the Embryonated eggs inoculated into allantoic sac at 12 days of incubation. The chicks were show dullness, decrease in food intake and nervous sings, most chicks were died after 2-3 days, and the bacteria were re-isolated from internal organs, and yolk sac. The inoculation of Embryonated chicken eggs resulting in embryonic death, reduce hatchery percentage and deformity of embryo. The study showed that *A. pyogenes* virulence to both chicken Embryonated eggs and one day old chicks.

INTRODUCTION

Archanobacterium pyogenes is coccobacilli, non-motile, gram positive bacteria belong to genus *Archanobacterium*. It's usually found in upper respiratory, urogenital and gastrointestinal tract in many domestic animals as opportunistic pathogen (1,2). These bacteria were responsible for many pyogenic infections which affecting skin, joint or internal organs in animals and birds (2,3). Its cause suppurative mastitis and liver abscesses in cattle (1,4), cellulitis in chickens (5,6) and osteomyelitis in turkeys (7,8), septicemia, visceral lesions, cutaneous abscesses and decrease in egg production in chickens (9).

The disease caused by bacteria after an injury or other bacterial or viral infection (3,10). The ability of bacteria to adhere, colonization, in vivo multiplication and then the damage of host cells result from several virulence factors which *A.pyogenes* owing. These factors include cholesterol-dependent cytolysin, pyolysin "PLO", several proteases, several adhesive mechanisms involved collagen binding protein, fibrinogen binding and fibronectin-binding protein, DNase and neuraminidases which play important role in pathogenicity of bacteria against host immunity (1, 10).

Very little studies reported *A. pyogenes* as a cause of poultry disease, rather that bacteria should be considered as avian pathogen (5,11). The objective of this study was to determine pathogenicity of *A.pyogenes* by using chicks and chick Embryonated eggs.

MATERIALS AND METHODS

Bacterial isolates: *A.pyogenes*(isolated from Quails)were obtained from lab.of microbiology/college of veterinary medicine – university of Mosul.

Prepare of inoculating dose:

The isolate of *A.pyogenes* was refreshed on 5% sheep blood agar. Five colonies from *A.pyogenes*were inoculated in Brain heart infusion broth” BHIB”, which incubate aerobically at 37°C for 24hours.A serial dilutionsin brain heart infusion broth was done, then 0.1 ml from each dilution tube is inoculated onthree nutrient agar platesand incubated aerobically at 37°C for 24 hours(12). Viable counts of bacteria were calculated and we selected the dose 4.2×10^8 CFU/ml for chicks and egg inoculation(13).

Experimental study:

- a- Egg inoculation:30 fertile eggs was obtained from (Al-Ameen hatchery company)were used for inoculating of *A.pyogenes*.After cleaning and disinfection the shell of eggs they put in egg incubator for 12 days, the eggswereexamined weekly to remove the dead and ungrowing embryonated eggs.*A. pyogenes* ($0.1 \text{ ml of } 4.2 \times 10^8 \text{ CFU /ml}$) was inoculated in allontoic sac of Embryonated eggs at the 12 days old.The opening in egg shell is sealed by paraffin(12,14). Eggs were examined daily until the day 21 of incubation.The abnormal changes and death in embryo were recorded and bacteriological sample is taken to confirm isolation of *A.pyogeneses*.
- b- One day chicks inoculation :
Thirty chicks (one day old)were divided equally into 3 groups(G1,G2,G3) G1 contain 10 chicks injected withphosphate buffer saline as control. G2 and G3 contain 10 chicks received $0.1 \text{ ml from } 4.2 \times 10^8 \text{ CFU/ml}$ of *A.pyogenes*orally (G2) and intraperitoneally (G3)(15). The signs appeared in inoculated chicks were recorded. Dead chicks were taken to bacteriological examination.
- c- *A.pyogenes*confirmation :
A. pyogenes confirmation was done by culturing of egg samples and internal organs (liver, intestine) and yolk sac of dead chicks on 5%sheep blood agar plates and incubate aerobically at 37°C for 24-48 h. (15,16).Colony which had typical cultural characteristic for *A.pyogenes*, was diagnosed according to the biochemical tests (catalase , oxidase , nitrate , gelatin hydrolysis , urease , and some sugar fermentation) (16,17).

RESULTS

a- Embryonated Egg inoculation : -

Most eggs Embryonated were dead, the hatchery percentage was 3.3% (1:30) most the embryos showed deformities in legs and yolk sac infection which appeared clearly in 5 days after inoculation. Some embryos showed fibrinous material in yolk sac, and few embryos showed liver hemorrhage (Fig. 1)

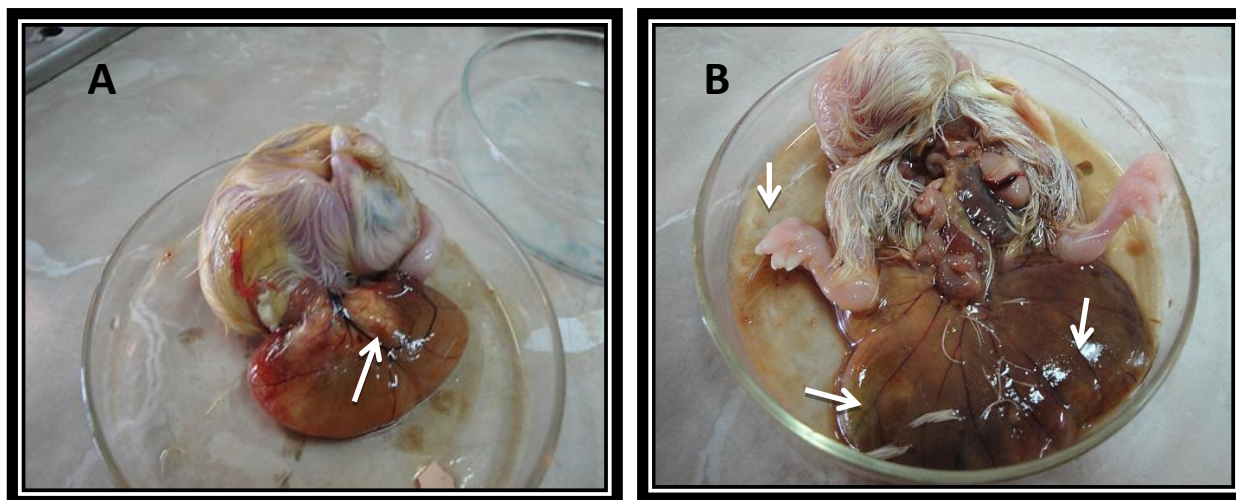


Fig 1: Twenty old day embryo: (A) show fibrinous material in yolk sac
(B) leg deformity and yolk sac infection (same age)

b- One day old chicks inoculation :

The clinical signs after inoculation included dullness, decrease in food intake in groups (G2, G3). More severe clinical signs appeared in some chicks of intraperitoneal group (G3) including incoordination, unable to stand or walk normally and nervous signs developed after 24 hours post inoculation. Most chicks died after 2-3 days of inoculation.

At postmortem in chick group (G2) showed fibrinous membrane and attached in internal organs, the intestine is empty and there was unabsorbed yolk with congestion in liver and mesenteric vessels in compare with control (fig. 2 :A). Chicks in group (G3) showed unabsorbed yolk sac with congested in blood vessels, congestion and petechial hemorrhage in liver, intestine was empty, enlarged gall bladder also appeared in some chicks of this group (fig. 3 :A). Chick group (G3) which suffered from nervous signs showed fibrinous exudates in mesenteric and fragile-pale liver also the intestine is empty and pale mesentery (fig. 3 :C).

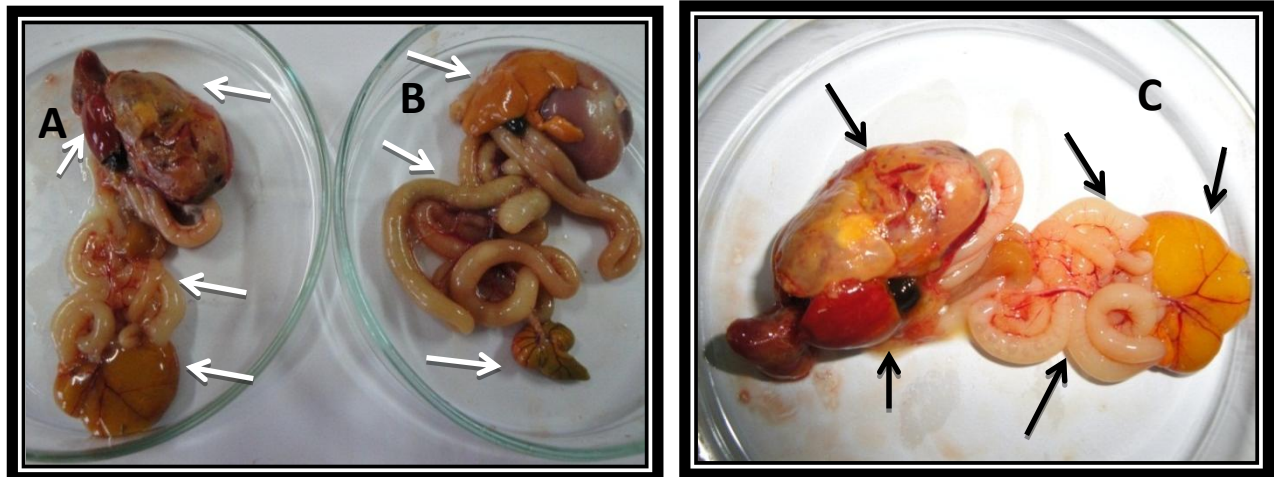


Fig. 2: G2 group three Day old chicks :A, C show fibrinous membrane and attached in internal organs ,the intestine is empty and there was unabsorbed yolk with congestion in liver and mesenteric vessels, B-Normal

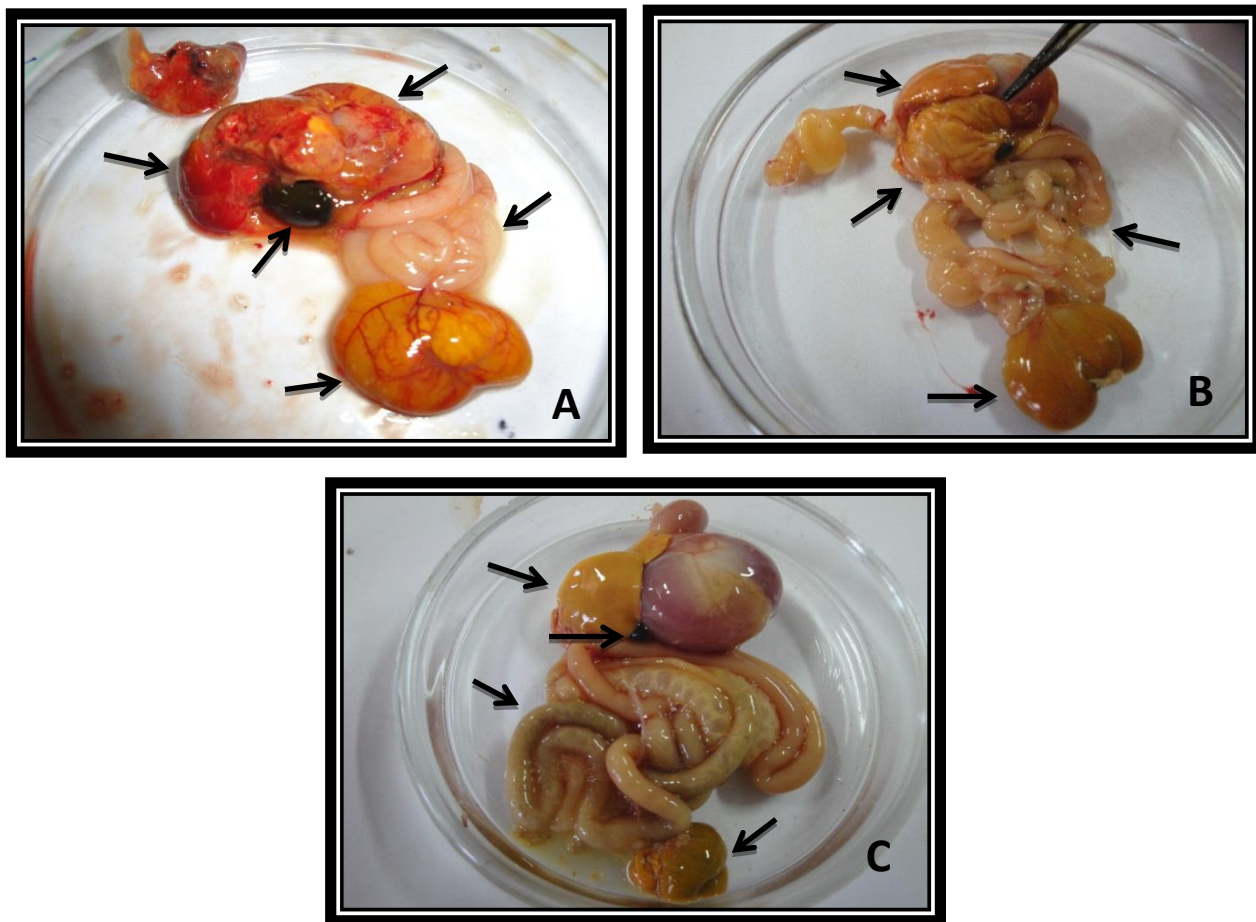


Fig. 3: G3 group : Three Day old chicks “A”: unabsorbed yolk sac with congested in blood vessels, congestion and petechial hemorrhage in liver, intestine was empty, enlarged gall bladder, “B”: fibrinous exudates in mesenteric and fragile- pale liver also the intestine is empty and pale mesentery, “C” :Normal

Bacteriological examination for dead chicks and embryonated eggs showed isolation of *A. Pyogenes* bacteria from internal organs of chicks and eggs (Table 1).

Table 1: isolation of *A. pyogenes* from embryonated eggs and chicks

Sample	Yolk sac	Liver	Internal organs
Embryonated Egg	++	+++	++
G2	+	+++	+
G3	++	+++	++
G1	-	-	-

DISCUSSION

A. pyogenes most widely reported from *Archaeobacterium* species which cause various diseases in different animal species including poultry (18).

The results of our study in embryonated Eggs inoculation were showed high embryos dead, low hatchery percentage (3.3%) and deformities. This may result from infection in yolk sac (19) and septicemia caused by bacteria injected in eggs (9,20). Also *A. pyogenes* contain extracellular matrix binding protein “collagen binding protein” CbpA which act as virulence factor to collagen rich tissue such as bone and cartilage and CbpA found in all osteomyelitis-*A. pyogenes* isolates (4,8). This factor may be responsible for colonization of bacteria in cartilage and bone leading to deformity formation appeared in embryo. Clinical signs that appeared in one-day chicks were differed from decrease in food intake and dullness (as a result from septicemia) (9), nervous signs like incoordination, unable to stand or walk normally which may be due to bacterial invasion of blood that may lead to form lesions and multiple abscessation in various organs (21), such as brain (22) which may result in cerebral and intracranial abscessation with suppuration in central nervous system (23). These nervous signs occur mainly in young animals (24).

Production and severity of gross lesions based on challenge route and affected by immune reaction that differed in different part of lymphoid system (15). In our experiment liver was most affected organ by the two routes (Intraperitoneal & orally) of administration. Some chicks in both G2 and G3 group showed congestion in liver and mesenteric vessels which may result from inflammation occurred in liver after invading by bacteria and subsequent abscess formation (18), the *A. pyogenes* inflammation contributed by up-regulation of TNF expression from macrophage under action of exotoxin “cholesterol- depending cytolysin, pyolysin” (PLO) (4). Some chicks in G3 were showed signs of fragile and pale liver with petechial hemorrhage due to distraction of cells by action of bacterial enzymes such as protease which may involve in host tissue damage and degraded host protein (4). Enlarged gall bladder appeared in chicks of G3 group was similar to that noted in *A. pyogenes* infection in turkey (7). The damage of red blood cells at liver may result from action of hemolysin effect of PLO exotoxin which able to cause lyses of red blood cells to produce B- hemolysis culture media (4).

Bacteriological re-isolation of *A. Pyogenes* from internal organs of chicks and embryonated eggs indicated that *A. Pyogenes* septicemia was occurred (20). There was high rate of isolation from liver rather than other organs and this may be result from bacterial tropism to hepatocyte, which has more abundant receptors to *A. Pyogenes* (15). Un absorbed yolk sac in chicks of G2, G3 was result from bacterial infection of the yolk and yolk stalk (omphalitis) (25).

This study concluded that *A. Pyogenes* is virulence to both chicken eggs and small chicks and the bacteria is one of the causes of embryonic death and reduce hatchery percentage in poultry industry, also is one bacterial species that cause death and unabsorbed yolk sac infection in chicks.

ACKNOWLEDGEMENTS

The authors extend thanks to the College of Veterinary Medicine, University of Mosul for support

الإصابة التجريبية بجراثيم *Arcanobacterium pyogenes* في أفراخ الدجاج

محمد علي حمد، عمار محمود العالم، مزاحم ياسين العطار

فرع الاحياء المجهرية، كلية الطب البيطري، جامعة الموصل، الموصل، العراق.

الخلاصة

الدراسة الحالية هدفت الى دراسة امراضية جراثيم الاركانوبكتريم القححية باستخدام افراخ دجاج بعمر يوم واحد وكذلك بيوض دجاج مخصبة. الافراخ اعطيت المعلق الجرثومي (4.2×10^8 / مل) عن طريق الفم وكذلك الحقن داخل البريتون، بينما البيوض المخصب حقن بالمعلق الجرثومي داخل الكيس الامنيوني في اليوم الثاني عشر من الحضن. الافراخ ظهرت عليها علامات الخمول، قلة تناول العلف وعلامات عصبية، اغلب الافراخ ماتت بعد 2-3 أيام، جراثيم الاركانوبكتريم القححية اعيد عزلها من الاعضاء الداخلية وكيس المح. حقن البيوض المخصب نتج عنه موت الاجنة، انخفاض نسبة الفقس وتشوه الاجنة. الدراسة الحالية اظهرت ان جراثيم الاركانوبكتريم القححية هي جراثيم ضارية لكل من أفراخ الدجاج والبيوض المخصب

REFERENCES

- 1-Songer G. J., Post K. W. Veterinary Microbiology: Bacterial and fungal agents of animal disease. Elseviers Saunders publisher, 1 ed. 2004.59-61.
- 2-Jost B.H., Songer J.G., Billington S.J. Identification of a second *Arcanobacterium pyogenes* neuraminidase and involvement of neuraminidase activity in host cell adhesion. Infect Immun. 2002.70 (3):1106-1112.

- 3-Billington S. J., Post K. W., Jost B. H. Isolation of *Arcanobacterium (Actinomyces) Pyogenes* from cases of feline otitis externa and canine Cystitis. J Vet Diagn Invest 2002 . 14 (2): 159-162.
- 4-Jost B. H. and Billington S. J. *Arcanobacterium pyogenes*: molecular pathogenesis of an animal opportunist. Antonie van Leeuwenhoek.(2005). 88(2): 87-102.
- 5-Derakhshanfar A., Ghanbarpour R. A study on avian cellulitis in broiler chickens .Veterinarski arhiv.2002.72 (5): 277-284.
- 6-Bozorgmehri Fard M. H., Karimi V., Fathi E., Behmanesh R. Bacteriologic survey on infectious cellulitis in broiler chickens in Masjid Soleiman slaughterhouse, Iran .Archives of Razi Institute. 2007 .62(2): 91-95
- 7-Brinton M.K., Schellberg L.C., Johnson J.B., Frank R.K., Halvorson D.A., Newman J.A. Description of osteomyelitis lesions associated with *Actinomyces pyogenes* infection in the proximal tibia of adult male turkeys. Avian Dis. 1993.37(1):259-62.
- 8-Esmay P. A., Billington S. J., Link M. A., Songer G. J., Jost H. B. The *Arcanobacterium pyogenes* collagen-binding protein, CbpA, promotes adhesion to host cells. 2003. 71(8): 4368–4374.
- 9-Saif Y. M., Fadley A. M., Glisson J. R., McDougald L. R., Nolan L. K., Swayne D. E. Diseases of Poultry: section II Bacterial disease: Other bacterial diseases. 12th ed. Blackwell Publishing. 2008:952.
- 10-Pietrocola G., Valtulina V., Rindi S., Helen Jost B., Speziale P. Functional and structural properties of CbpA, a collagen-binding protein from *Arcanobacterium pyogenes*. Microbiology .2007.153: 3380–3389.
- 11-CALNEK, B. W., JOHN BARNES H., BEARD C. W., REID W. M., YODER H. W. Diseases of poultry. 9th ed., Iowa State University Press. 1991: 294-295.
- 12-Quinn P.J., Markey B.K., Carter M.E. , Donnelly W.J. , Leonard F.C. Veterinary microbiology and microbial diseases. UK: Blackwell Science Ltd. 2002:16,297.
- 13-Jost B. H., Songer J. G., Billington S. J. An *Arcanobacterium (Actinomyces) pyogenes* mutant deficient in production of the pore-forming cytotoxin pyolysin Has Reduced Virulence. Infect Immun.1999. 67(4): 1723–1728.
- 14-Rovozzo G. C., Burke C. N. A manual of basic virological techniques. Prentice-Hall publisher.1973.16-38.
- 15-Barbour E.K., Itani H.H., Shaib H.A., Saade M.F., Sleiman F.T., Nour A.A., Harakeh S. Koch's postulate of *Arcanobacterium pyogenes* and its immunogenicity in local and imported Saanen goats. Vet Ital. (2010).46(3):319-27.
- 16-Kavitha K., Latha R., Udayashankar C., Jayanthi K., Oudeacoumar P. Three cases of *Arcanobacterium pyogenes* associated soft tissue infection. J Med Microbiol. 2010. 59:736–739.
- 17-Abdulla B. A., Al-Jammaly M. M. H., Sadoon A.S. Isolation and identification of some bacteria causing subclinical mastitis in cows. Iraq J Vet Res.(2011).25(1):63-67.
- 18-Gyles L. C., Prescott F. J., Songer J. G., Thoen O. C. Pathogenesis of bacterial infections in animals. 4 Ed. Blackwell Publishing. 2010:138-140.

- 19- Husseina S. A., Hassanb A. H., Sulaimanc R. R. Bacteriological and pathological study of yolk sac infection in broiler chicks in sulaimani district. J. Dohuk Univ. 2008. 11 (1):48-56.
- 20- Ülbeği-Mohyla H., Hijazin M., Alber J., Lämmle C., Hassan A. A., Abdulmawjood A., Prenger-Berninghoff E., Weiß R., Zschöck M. Identification of *Arcanobacterium pyogenes* isolated by post mortem examinations of a bearded dragon and a gecko by phenotypic and genotypic properties. J. Vet. Sci. (2010). 11(3):265-267.
- 21- ERTAŞ H. B., KILI A., ÖZBEY G.k., MUZ A. Isolation of *Arcanobacterium (Actinomyces) pyogenes* from abscessed cattle kidney and identification by PCR. Turk J Vet Anim. Sci. 2005. 29:455-459.
- 22- Plamondon M., Martinez G., Raynal L., and Touchette M., Valiquette L.A. fatal case of *Arcanobacterium pyogenes* endocarditis in a man with no identified animal contact: case reported review of the literature. Eur. J. Clin. Microbiol. Infect. Dis. 2007. 26:663–666
- 23- Portas T.J., Bryant B.R. Morbidity and mortality associated with *Arcanobacterium pyogenes* in a group of captive blackbuck (*Antelope cervicapra*). J Zoo Wildl Med. 2005. 36(2):286-289.
- 24- Silva R.M.M., Carvalho F.R.B., Cerqueira R. B., Macêdo J.T.S.A., Pedroso P.M.O. Spinal cord extradural abscess caused by *Arcanobacterium pyogenes* in a Lamb in the northeast region of Brazil. Brazilian journal of Veterinary Pathology. 2010. 5(2):40-41.
- 25- Buhr R. J., Northcutt J. K., Richardson L. J., Cox N. A., and Fairchild B. D. Incidence of unabsorbed yolk sacs in broilers, broiler breeder roosters, white leghorn hens, and Athens-Canadian Randombred control broilers. Poultry Science (2006). 85:1294–1297