

EFFECTS OF TESTOSTERONE HORMONE ON STRUCTURE OF UTERUS IN FEMALE MICE BALB/C

Emad. k .Abbas

Department of Anatomy , Histology and Embryology, College of medicine, University of Basrah,Basrah, Iraq

(Received 25 September 2012, Accepted 18 October 2012)

Key word: Testosterone, uterus, female mice

ABSTRACT

This study shows the effects of Testosterone hormone on uterus tissue in female mice. We used twenty laboratory mice (Ten animals for each group). The first groups used as a control by using physiological saline (0.9%) concentration. The second groups were taken the 10mg/kg for 28 days. Biopsy was taken from the animals to examine their tissue histopathologically, Results were seen in uterus form of degradation in Endometrium and bleeding .Deteriorate in epithelial tissue and infiltration in inflammatory cells .

INTRODUCTION

Testosterone is a steroid hormone from the androgen group and is found in mammals, reptiles (1), birds, and other vertebrates(2).

In mammals, testosterone is primarily secreted in the testicles of males and the ovaries of females, although small amounts are also secreted by the adrenal glands. It is the principal male sex hormone and an anabolic steroid. In man, testosterone plays a key role in the development of male reproductive tissue such as the testis and prostate as well as promoting secondary sexual characteristics such as increased muscle , bone mass, and the growth of body hair (3).

In addition, testosterone is essential for health and well-being (4).as well as the prevention of osteoporosis (5). On average, an adult human male body produces about 7-8 time more testosterone than an adult human female body (6). But females are more sensitive to the hormone (7).

Testosterone is observed in most vertebrates, fish make a slightly different form called 11-ketotestosterone (8).its counterpart in insects is an ecdysone (9).These ubiquitous steroids suggest that sex hormone has an ancient evolutionary history(10).

MATERIAL AND METHODS

Twenty adult females mice (Balb/c) were randomly divided into two equal groups (10/group). Group one served as control group injected by physiological saline while the animals second group was injected intraperitoneally 10 mg/kg B.W of Testosterone hormone production company (Pharmacia & upjohn SPA) Italy, Intraperitoneal for 28 days. At the end of experiment, post-mortem was done. specimens were taken from the Uterus organ of both groups. Histopathologic slides were prepared for histopathological examination according to (11).

RESULTS

Histological specimens of uterus reveal some pathological changes in the form of degradation in endometrium and bleeding (Fig.1), and adherence in layer uterus and degradation in connective tissue (Fig.2) and (Fig.3), and Expanded in uterus tissue (Fig.4) and degradation in epithelial for uterus and connective tissue with infiltration for inflammatory cells (Fig.5).

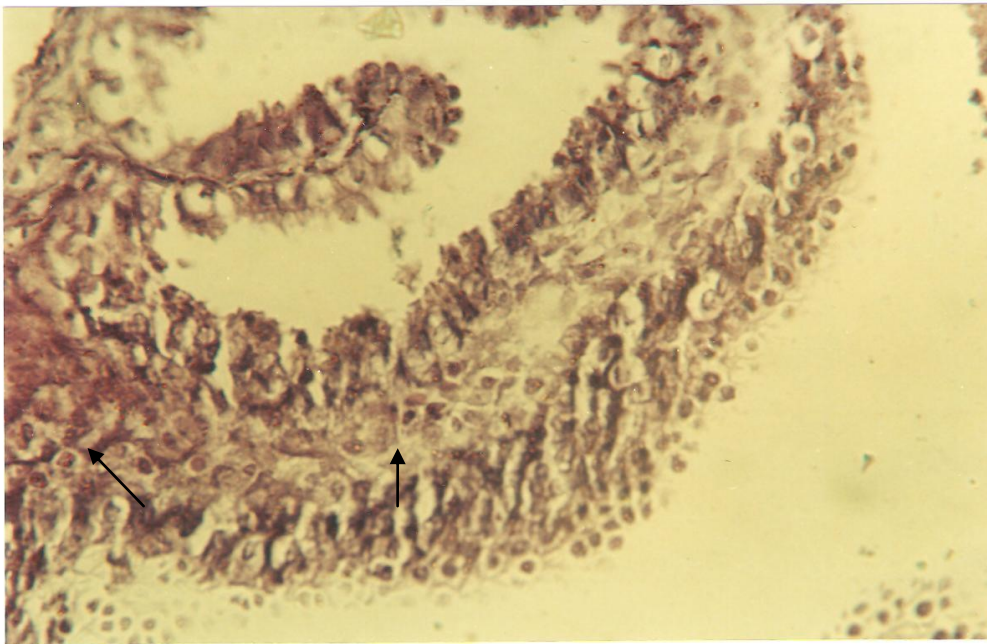


Fig.1: Histological section of the uterus tissue in animals treated with Testosterone hormone show induce the decomposition of a comprehensive layer epithelial lining of the uterus and damage to full some folds of the uterus (Endometrium) and bleeding. E&H (150x).

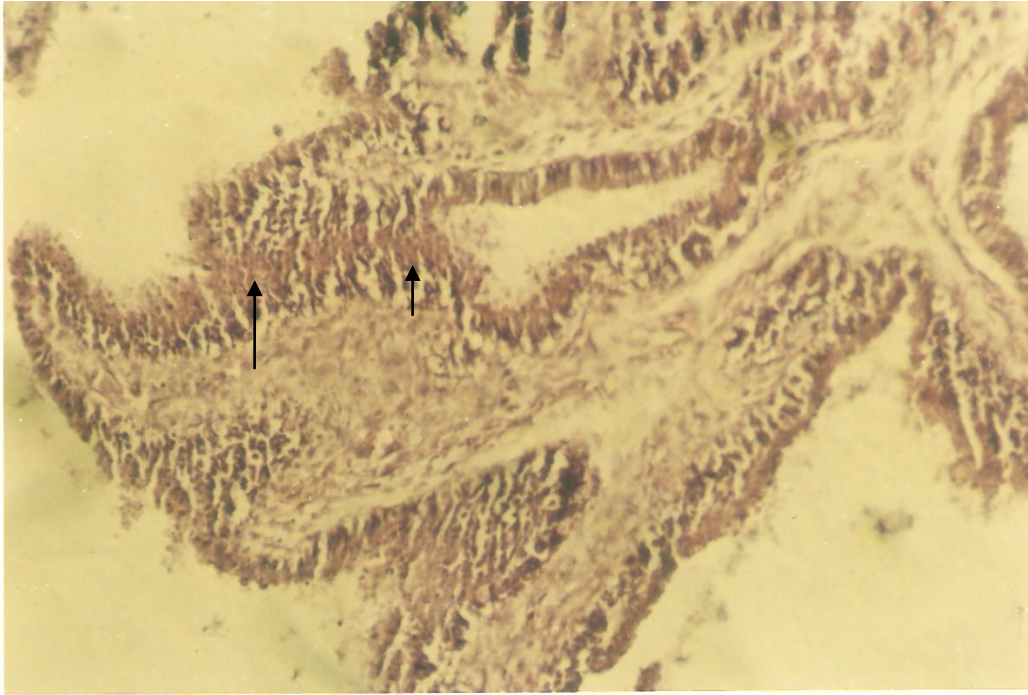


Fig.2: Histological section of the uterus tissue in animals treated with Testosterone hormone show induce adhesion in the lining of the uterus with the degradation in connective tissue because of the decomposition layer epithelial of the uterus .E&H(120x).

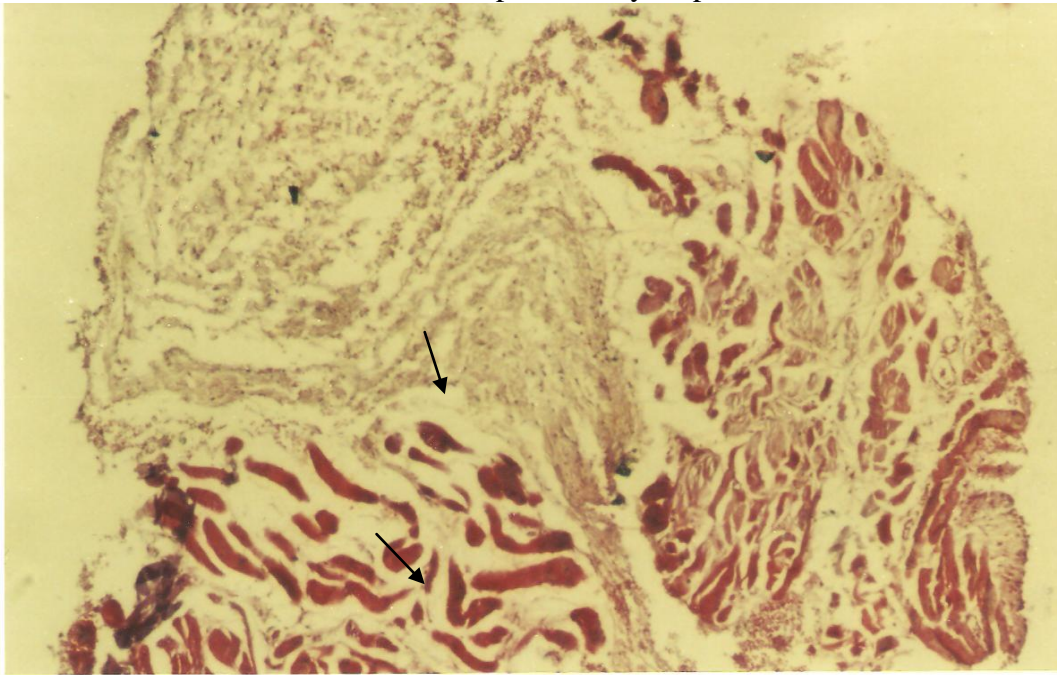


Fig.3: Histological section of the uterus tissue in animals treated with Testosterone hormone show induce decomposition of the endometrium in the uterus and survival of muscle tissue .E&H(90x).

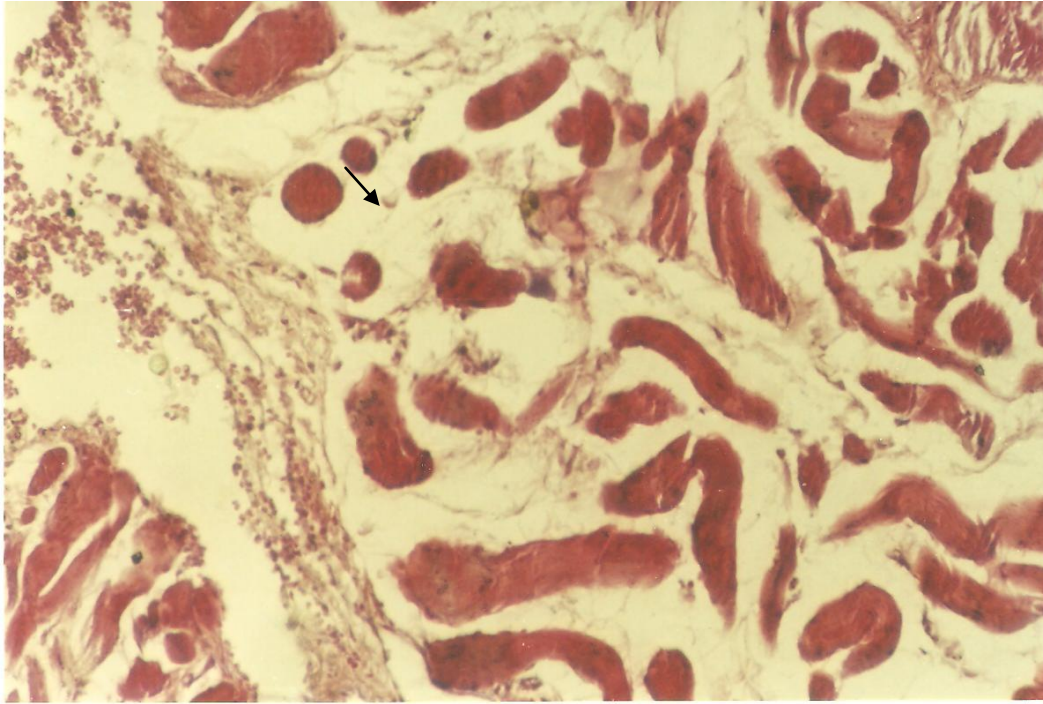


Fig.4: Histological section of the uterus tissue in animals treated with testosterone hormone show induce the expansion for uterus tissue .E&H(150x).

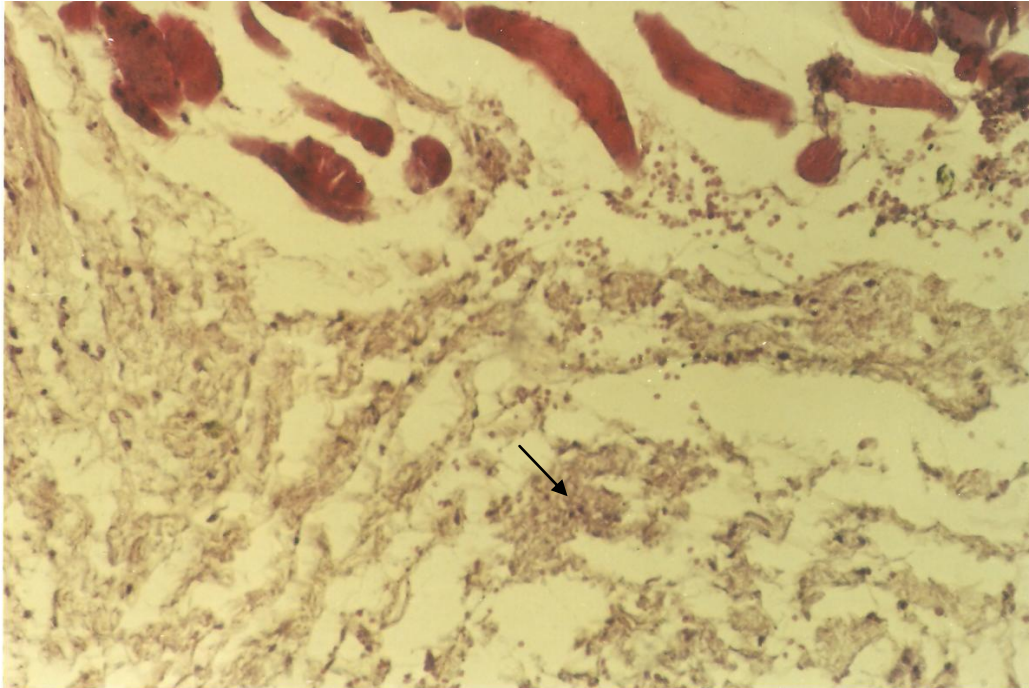


Fig.5: Histological section of the uterus tissue in animals treated with testosterone hormone show induce the damage in the epithelial layer and connective tissue with infiltration of inflammatory cells. E&H (150x).

DISCUSSION

The uterus is a major female hormone –responsive reproductive sex organ of most mammals including humans. The results of this study present a histopathological findings in uterus for the administration group of mice with the testosterone hormone ,these findings are degradation in Endometrium and bleeding ,adherence in layers uterus and degradation in connective tissue, in addition to expansion in uterus tissue and degradation in epithelial tissue and infiltration of inflammatory cells. These results are compared with results done by other investigators (12) that done on male and female rats injected by testosterone propionate ,their results revealed the striking hypertrophy of the cells of the mucosa and myometrium seen in the uterus. Another study Cynthia and his coworkers (13) used female rats treated with testosterone hormone with a dose of (0.1-10 mg/kg) these study revealed the mentioned was increased the expansion of uterus tissue.

Shouqi and his colleagues (14) explain the effect of Antiestrogen EM-800 in female mice at the daily dose of (3mg,10mg,30mg,100mg)all doses of EM-800in intact animals led to a moderate to severe uterine and vaginal atrophy, the uterine atrophy effected both the myometrium and the endometrium ,and a maximal effect being reached at the daily (10mg) dose of the antiestrogen in intact animals.

Meanwhile Hong and his coworkers(15) shows endometrial thickness was increased by treatment with estrogen alone or in combination with testosterone.

The regulation of endometrial proliferation in response to sex steroid hormone is complex and poorly understood, Estrogen which exerts its function via specific receptors (ER1 and ER2), acts both at genomic and nongenomic levels(16).The human endometrium is incapable of aromatizing androgens to produce estradiol(17,18).

Cardenas and his colleagues(19) have demonstrated that dihydrotestosterone attenuates estrogenic effects in the pig uterus by down-regulating ER1. Another study revealed that the antiprogestin mifepristone inhibits endometrial proliferation and up-regulates the androgen receptor in women (20).

In addition , the antiandrogen flutamide blocks the suppressive effects of antiprogestins in the primate endometrium ,which indicates that the androgen receptor may play a role in the antiproliferative effect of antiprogestins(21).

تأثير هرمون التستوستيرون على تركيب الرحم في إناث الفئران المختبرية

عماد خضير عباس

فرع التشريخ والأنسجة والأجنة، كلية الطب، جامعة البصرة، البصرة، العراق

الخلاصة

أجريت هذه الدراسة لمعرفة تأثير هرمون التستوستيرون على نسيج الرحم في إناث الفئران تم استخدام عشرون من إناث الفئران المختبرية تم تقسيمها عشوائياً إلى مجموعتين (عشرة لكل مجموعة) اعتبرت المجموعة الأولى مجموعة سيطرة وحيث حقنت بالمحلول الفسيولوجي أما المجموعة الثانية فقد حقنت بهرمون التستوستيرون 10 ملغم/كغم من وزن الجسم ولمدة ثمانية وعشرين يوماً تم التضحية بالحيوانات في نهاية التجربة وأخذت منها عضو الرحم لعمل المقاطع النسجية وتمثلت العلامات المرضية في نسيج الرحم لفئران المجموعة الثانية بحصول حالة التحلل في الطبقة المبطنية للرحم مع حالة النزف وكذلك حالة التآكل للطبقة الطلائية مع حالة أرتشاح للخلايا الالتهابية

REFERENCES

- 1.Cox RM,John-Alder HB(2005).Testosterone has opposite effects on male growth in lizard (Sceloporus spp.) with opposite patterns of sexual size dimorphism.J.Exp.Biol.208(pt 24):4679-87.
- 2.Reed WL, Clark ME, Parker PG, Raouf SA,Arguedas N,Monk DS,Snajdr E,Nolan V,Ketterson ED(2006).Physiological effects on demography :a long –term experimental study of testosterone effects on fitness.Am.Nat.167(5):667-83.
- 3.Mooradian AD,Morly JE,Korenman SG(1987).Biological actions of androgens.Ender.Rev.8(1):1-28.
- 4.Bassil N,Alkaade S,Morley JE (2009).The benefits and risks of testosterone replacement therapy:a review.Ther clinic Risk Manag 5(3):427-48.
- 5.Tuck SP,Francis RM(2009).Testosterone ,bone and osteoporosis.Front Horm Res.Frontiers of Hormone Research 37:123-32.
- 6.Torjesen PA ,sandnes L (2004).Serum testosterone in women as measured by an automated immunoassay and a RIA.Clin.Chem.50(3):678
- 7.Dabbs M,Dabbs JM(2000).Heroes,rogues,and lovers:testosterone and behavior .New York:McGraw-Hill.
- 8.Nelson,Randy F.(2005).An introduction to behavioral endocrinology .Sunderland, Mass: Sinauer Associates.p.143.

- 9.De Loof A.(2006). Ecdysteroids :the overlooked sex steroids of insects, Males the black box .Insect Science 13(5):325-338.
- 10.Mechoulam R,Brueggemeier RW ,Denlinger DL(1984).Estrogens in insects .Journal Cellular and Molecular Life Sciences 40(9):942-944.
- 11.Drury,R.A.B.;Wallington,E.A.and Cameron,S.R.(1967). Cariton's histological technique.4th ed., Oxford univ.press,New York:423 pp.
- 12.Vladimir,korenchevsky;Marjorie,Dennison;Kathleen,Hall.(1937).Effects of Testosterone and Testosterone propionate and adult male rats (compared with those on female rats).J.path.Bact.47:1434-1437.
- 13.Cynthia j, wolf; Andrew H ;Joseph S. ostby; Gerald A.Leb lane ;L.Earl Gray jr.(2002).Effects of prenatal Testosterone propionate on the sexual development of male and female rats :A dose –response study .Toxicological science 65:71-86.
- 14.shougi,Luo;Antigone,sourla;Claude,Labrie;Sylvain,Gauthier;Yves,Merand;Alain,Bela naer and Fernand Labrie.(1998).
Effect of Twenty-four week treatment with the Antiestrogen EM-800 on Estrogen-sensitive parameters in intact and ovariectomized mice.Endocrinology.vol.139.No.5:2645-2656.
- 15.Hong,zang;Lena,sahlin;Britt,masironi;Elina,Eriksson;Angelica,Linden Hirschberg.(2007).Effect of Testosterone treatment on Endometrial proliferation in postmenopausal women. The journal of clinical Endocrinology&Metabolism.vol.92.No.6:2169-2175.
- 16.Speroff,L.(2000).A clinical understanding of the estrogen receptor.Ann. NY.Acad.Sci.900:26-39.
- 17.Baxendale ,PM;Reed,MJ;James,VH.(1981).Inability of human endometrium or myometrium to aromatize androstenedione. J.Steroid Biochem.14:305-306.
- 18.Bulun,SE;Lin,Z;Imir,G;Amin,S;Demura,M;Yilmaz,B;Martin,R;Utsunomiya,H;Thung, S;Gurates,B;Tamura,M;Langoi,D.(2005).
Regulation of aromatase expression in estrogen-response breast and uterine disease: from bench to treatment .Pharmacol.Rev.57:359-383.
- 19.Cardenas,H;Pope,WF.(2004).Attenuation of estrogenic effects by dihydrotestosterone in the pig uterus is associated with down regulation
Of the estrogen receptors.Biol.Reprod.70:297-302.
- 20.Narvekar,N;Cammeron,S;Critchiey,HO;Lin,S;Cheng,L;Barid,DT.(2004).

Low-dose mifepristone inhibits endometrial proliferation and up-regulates androgen receptor.J.Clin.Endocrinol.mmetab.89:2491-2497.

21.Slayden,OD;Brenner,RM.(2003).Flutamide counteracts the antiproliferative effects of antiprogestins in the primate endometrium.J.Clin.Endocrinol .Metab.88:946-949.