

PATHOGENESIS OF INFECTIOUS BRONCHITIS VIRUS IN INFECTED BROILER CHICKENS

M.H. Mohammed^{1, 2*}, M. Hair-Bejo¹, Abd Al-Amir Zahid², Amer Alazawy³,
Emad Adwar Abdul Ahad⁴ and Mauida, F. Hasoon¹

1 Faculty of Veterinary Medicine, Universiti Putra Malaysia 43400 UPM Serdang, Selangor,
Malaysia

2 College of Veterinary Medicine, University of Baghdad, Baghdad, Iraq.

3 Faculty of Veterinary Medicine, University of Diyala, Diyala, Iraq.

4 College of Veterinary Medicine, University of Sulaimania, Sulaimania, Iraq.

(Received 3 June 2012, Accepted 21 June 2012)

Keywords; Infectious bronchitis, ELD₅₀, kidney.

ABSTRACT

Infectious bronchitis (IB) is one of the most common viral diseases of poultry. The objective of this study was to estimate the distribution of avian infectious bronchitis virus isolate in experimentally infected chicken. Twenty-one-day-old commercial broilers were divided randomly into two groups (fifty in the experimental and twenty in the control group). Chicks in the experimental group were inoculated intranasal with 10⁶ ELD₅₀/0.1 mL of the virus. The samples from different tissues were collected at day 0, 3, 5, 7, 10, 15 and 20 postinoculation. Chickens showed mild respiratory signs and depression. Viral RNA was detected in the kidney, lung and tracheas. The most important clinical signs and virus finding appeared on day 1 pi. Data showed that the number of infected chickens and viral RNA detection from tissues was reduced with increasing antibody titer on day 20 pi. The results demonstrated that the IB virus has wide tissue distribution for respiratory, urogenital, and digestive systems.

INTRODUCTION

Infectious bronchitis (IB) is an extremely contagious respiratory disease of chickens (18). Replication of the infectious bronchitis virus (IBV) causes feature, but not pathognomonic respiratory signs such as gasping, coughing, tracheal rales, and nasal discharge (1). Irregularly, puffy, inflamed eyes and swollen sinuses might be seen (3). The pathogenicity of IBV for different tissues has been described (1). In the respiratory tract, IBV causes deciliation and desquamation of the tracheal epithelium, resulting in a greatly contagious respiratory disease (9). In the kidneys, nephropathogenic strains induce clinical nephritis, gross and histological kidney lesions with mortality altering between 5% and 90% (16). In the oviduct, IBV replication has been connected with a decline in the internal and external quality of the eggs and a decline in egg production (7). Recently, IBV has been linked with a particular disease in the proventriculus (13). Infected birds appeared depressed with ruffled feathers and wet droppings with white and yellow milky feces, related with an infected digestive tract. In the intestines, IBV replication has been observed in the tissues of the lower

gut in cells like histiocytes and lymphoid cells in the cecal tonsils (10) The presence of the virus has also been demonstrated by immunofluorescent assay (IFA) or in situ hybridization (6) The reverse transcription-polymerase chain reaction (RT-PCR) has proved practical in the detection of numerous RNA viruses (1). Outbreaks of the disease can happen even in vaccinated flocks because there is slight or no cross-protection among serotypes (3) The requirement of IB prevention in chicken regarding the nature of the virus with a high mutation rate in the S1 gene dictates the necessity to develop effective vaccines. The aim of this study was to evaluate the pathogenesis of the disease in experimentally infected commercial broilers. RT-PCR test was used to detect the occurrence of the virus in body tissues. The clinical signs, gross lesions, and antibody of the affected chicks were also checked.

MATERIALS AND METHODS

Virus

The virus isolate used in this study was obtained from the Faculty of Veterinary Medicine / University Putra Malaysia (UPM) and was propagated three times in 9- to 11-day-old embryonated chicken eggs. The embryo lethal dose (ELD₅₀) was measured according to the Reed and Muench (16) formula.

Experimental Design

Twenty-one-day-old commercial broiler chicks were divided randomly into two groups (fifty chicks in the experimental and twenty chicks in the control group). They were reared separately in the Animal House Unit of the Veterinary Medicine University Putra Malaysia and received feed and water ad libitum during the experiment. First all birds were serologically tested using enzyme-linked immunosorbent assay (ELISA) and they were negative IBV. Also, five birds from the experimental group were killed and their organs were detected for virus. At the age of 30 days, all birds in the experimental group were challenged intranasally and with allantoic fluid containing 10⁶ ELD₅₀/0.1 mL of the virus, and remaining 20 birds were left as control. All the birds were checked daily for 30 days for clinical signs, antibody responses to infectious bronchitis virus, and mortality. On days 1, 3, 5, 7, 10, 14, and 21 postinoculation (pi), four chickens from the experimental group and two chickens from the control group were randomly selected and used for sample collection. Gross lesions were recorded, and their trachea, lungs, kidneys, caecal tonsil, testes, and oviduct were aseptically collected for virus detection using RT-PCR. Serum of the birds was collected on 0, 5, 11, 15, and 20 days pi for ELISA test.

RNA isolation

RNA was isolated from infected tissues using commercial RNeasy Mini Kit (Qiagen, USA) as recommended by the supplier.

Reverse transcription polymerase chain reaction (RT-PCR)

For RT-PCR the infected monolayers were submitted to detect IBV replication, the partial spike (S1) gene (1025 nucleotides) of IBV was amplified RT-PCR after different passages according to the manufacturer's recommendation (Takara). The specific primers for IBV S1

gene were designed according to IBV H52 sequence (accession number AF3523151) as follows: forward, 5-CTATGTAGTG CTGTTTTG-3 (nucleotides 42 to 59); reverse, 5-CCTTGAAGAGG ACCGTAA-3 (nucleotides 1049 to 1066), and the RT-PCR was run 30 min at 50⁰C and 2 min at 94⁰C for one cycle, then 30 cycles of 30 sec at 94⁰C, 30 sec at 55⁰C, 1.5 min at 72⁰C, followed by 15 min at 72⁰C (PTC-100TM Programmable Thermal Controller; MJ Research, Inc.).

Detection of PCR products

PCR products were separated in 1.5% agarose gel in 1 x TAE buffer stained with ethidium bromide, compared with molecular mass marker and visualized by ultraviolet (UV) transillumination.

Statistical Analysis

The mean antibody titer of the infected group was compared with the uninoculated control group for statistical analysis of significant using analysis of variance (two way ANOVA) followed by Duncan's multiple range test was used as the post hoc produced by using SPSS version 15 for windows (14).

RESULTS

Clinical Signs, Gross Lesion and Mortality

Some birds in the infected group showed sever tracheal rales, coughing, and gasping at 24 hours pi. The signs were less severe after 3 days pi. Add to that, the chickens showed lethargic, reluctant to move from the 1st to the 5th day pi. No mortality was observed in any of the groups throughout the experiment. These clinical signs disappeared at 4 days pi. On days 1, 2, 3, 5, 7, and 10 pi, two birds from control group and four from infected group were randomly selected; necropsied and gross lesions were recorded. Mild hyperaemia and oedema in tracheal mucosa were showed in the euthanased birds from 1 to 3 days pi (Figure 1). Pale and swollen kidneys were observed from 5 to 10 days pi. No gross lesions were observed in brain, gizzard, proventriculus, intestine, and heart muscle as well as liver and spleen. No clinical signs and gross lesions were observed in the uninfected control chickens

Virus diffusion in tissues after Virus Inoculation

Results related to IBV diffusion was checked in all tissues obtained from the infected and control groups at different days pi using RT-PCR (Figure 2). No virus was determined from the infected and control groups before infection. The virus was found in the trachea, lung, kidney, caecal tonsil at day 13 pi, and also in the kidney, caecal tonsil at day 15 pi while the virus was not detected in any other tissue. The virus was also showed in the testes consistently for 11 days. The virus was detected on days between 3 and 13 pi from the ovary and oviduct (Table 2).

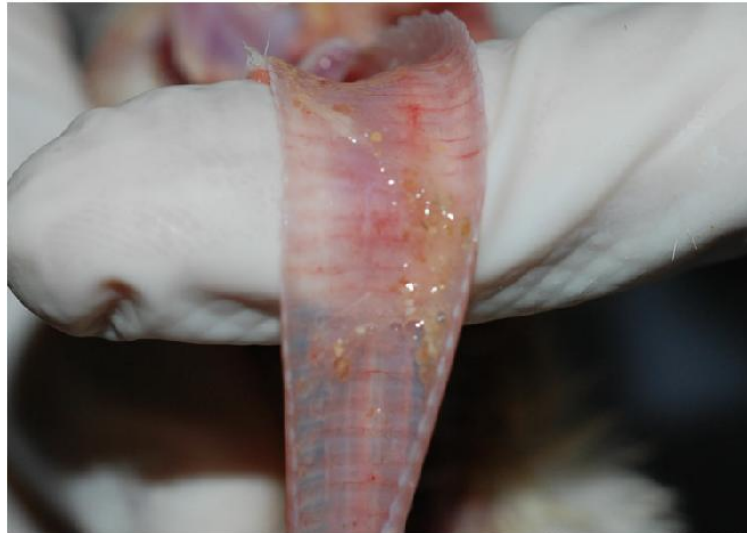


Figure 1: The tracheal mucosa shows hyperemia and petechial hemorrhages on 1 day pi.

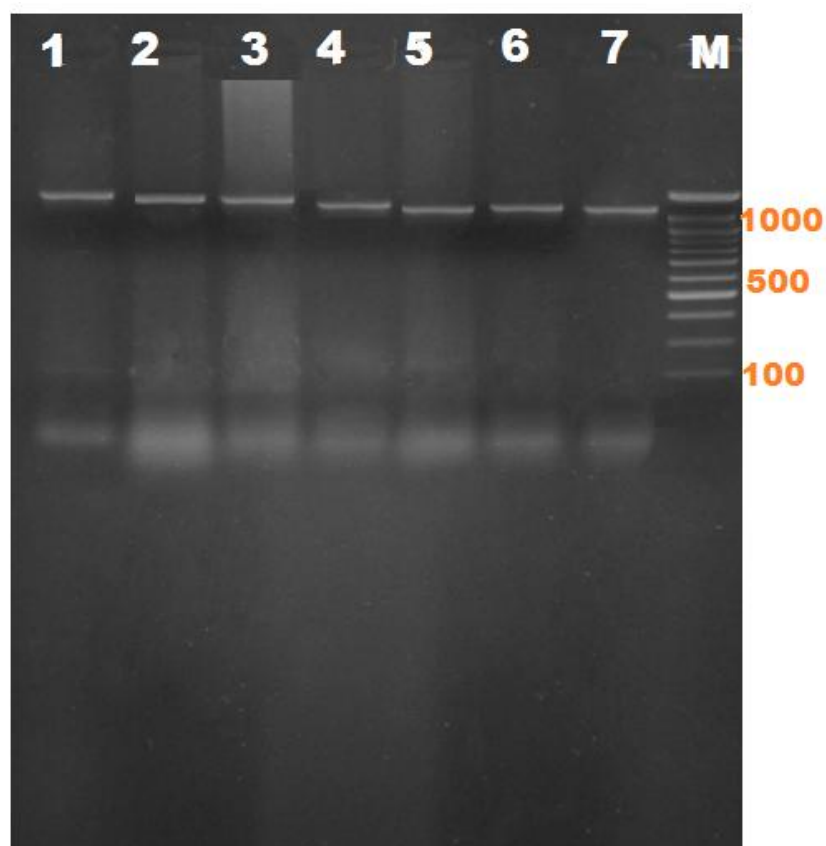


Figure 2: results of the PCR assay. Amplifying 1025-bp segment of 3' UTR gene of IBV. Lane M: DNA marker (100-bp), 1, 2, 3, 4, 5, 6, and 7: positive samples.

Table 2

Virus detection from various organs of chickens postinoculated (PI) of infectious bronchitis virus isolate

Time postinoculation (day)	Trachea	Lung	Kidney	Oviduct and ovary	Testis	Caecal tonsil
1	3/4*	1/4	1/4	0/2	1/2	4/4
2	4/4	3/4	2/4	0/2	2/2	4/4
3	4/4	4/4	4/4	1/2	2/2	4/4
5	4/4	4/4	4/4	2/2	1/2	4/4
7	4/4	3/4	4/4	2/2	1/2	4/4
11	4/4	3/4	4/4	1/2	2/2	4/4
13	4/4	3/4	2/4	1/2	0/2	4/4
15	0/4	0/4	2/4	0/2	0/2	3/4
20	0/4	0/4	0/4	0/2	0/2	2/4

* Number of positive/total samples.

Serological Result

The serum from chickens of infected and control groups were detected for antibodies (Ab) levels against IBV. In the infected group, serum was negative at day 0, 5, and 11 pi but they were positive at 15 and 20 days. The Ab titer was increase at 11 days, but it developed at 20 days pi. Serum of the control was negative on the entire days pi (Table 3).

Table 3

Comparisons of infectious bronchitis antibodies titers (ELISA) in infected and control group (mean \pm SE).

Groups	Days post inoculation				
	0	5	11	15	20
Inoculated birds	245.51 \pm 67.19	41.92 \pm 15.62	827.66 \pm 207.02	1440.14 \pm 853.15	1657.87 \pm 391.64
Control birds	63.30 \pm 10.82	124.56 \pm 41.39	205.71 \pm 39.75	154.07 \pm 127.67	294.67 \pm 112.01

DISCUSSION

In the present study, we have studied the pathogenesis of the infectious bronchitis virus isolated in Malaysia and detected the tissue tropism and distribution of the virus in the tissues by using RT-PCR.

The clinical signs reported in this study were typical of infectious bronchitis, at 24 hours pi the infected birds showed mild tracheal rales, coughing, and gasping. These signs have disappeared at day 4 pi. The clinical signs and gross lesions were in similarity with the findings that have been showed previously (2). At day 1 pi, Purcell and McFerran (15) noted cloudy and edematous abdominal and posterior airsacculitis. The lungs showed normal in all birds, like to the comments of Grgić et al. (9).

The infected birds showed severe conjunctivitis, combined with plentiful lacrimation, oedema, and cellulitis of the periorbital tissues at day 2 of infected group with IB. (19) But the main lesions have been seen in the trachea and kidneys (17) Diagnostic laboratories usually isolate the virus in specific pathogenic free embryonated eggs and use the allantoic fluid to detect IBV specific RNA by RT-PCR.

QX IBV strain has been isolated from kidney, trachea, ovary, and caecal (19). But, in our results, no related gross lesions were detected in the digestive tract after IBV challenge. Cavanagh (3) detect that infection of digestive tissues normally does not occur itself clinically. Lucio and Fabricant (12) observed that other strain M41 can infect a range of tissues and some isolates may be recovered regularly from the digestive tract. In a new study, IBV was not showed from intestine and cecal tonsils using immunofluorescence technique (5). Lee et al. (11) detect the tissue distribution of avian infectious bronchitis virus after in ovo inoculation of chicken embryos examined by in situ hybridization. Viral RNA was detected at 2 days after infection in epithelial cells of the trachea, lung, intestine, and bursa. In chickens, the virus has been regularly isolated from the trachea, lung, and caecal tonsils but the persistence of the virus in the bursa was of notice. Their results visibly prove the strict epitheliotropic nature of IBV

In this report, ELISA method was used to calculate Ab titer to IBV. ELISA detected moderate levels of the Ab at day 11 pi and high levels of Ab on day 20 pi. Serum was also positive for IBV at 15 days pi. Ghadakchi et al (8) observed that ELISA could be reliable, repeatable, and sensitive for detecting vaccination program and the fast detection of the early increase of Ab against IB.

Chen and Itakura (4) observed that the clinical signs, gross lesion and histological in the trachea and kidneys due to IBV infection were more severe and of longer period in infected birds (with Gumboro disease and IBV) than in ones inoculated with IBV.

This study confirms that IBV only cannot cause hard and devastating disease, but IBV-infected birds can be susceptible when combine with other infection like H9N2 avian influenza virus. Future work should aim to determine if the available and used IB vaccines provide sufficient protection against this IBV isolate.

أمراضية فايروس التهاب القصبات المعدي في فروج اللحم

ماجد حميد محمد، هير بيجو ، عبد الامير زاهد ، عماد ادور عبد الهادي ،مويد حسون

الخلاصة

يعد مرض التهاب القصبات المعدي واحد من الأمراض الفيروسية الأكثر شيوعا في الدواجن. اذ كان الهدف من هذه الدراسة هو تحديد انتشار فيروس التهاب القصبات المعدي في أنسجة الجسم من الدجاج المصابة تجريبيا . افراخ بعمر 21 يوما تم تقسيمها عشوائيا إلى مجموعتين (50 في المجموعه المجرعه و 20 في مجموعة السيطره). تم اصابة الدجاج في المجموعه المجرعه عن طريق الأنف . ثم جمعت عينات من الأنسجة المختلفة في اليوم 0، 3، 5، 7، 10، 15 بعد الاصابه . وأظهر الدجاج علامات تنفسية خفيفة وخمول. تم الكشف عن الحمض النووي الريبي للفايروس في الرئة والكلى والقصبات. ان اهم العلامات السريرييه ظهرت بعد اليوم الاول من الاصابه. وأظهرت البيانات ان الحامض النووي الريبي للفايروس قد انخفض في اليوم 20 من الاصابه في حين لوحظ ارتفاع في الاجسام المضاده في اليوم ذاته بعد الاصابه كما أظهرت النتائج أن الفايروس لديه قدره على الانتشار الواسع في كل من الجهاز التنفسي، والبولي التناسلي، والجهاز الهضمي

REFERENCES

- 1-Abdel-Moneim, A. S., Zlotowski, P., Veits, J., Keil, G. M. and Teifke, J. P. (2009). "Immunohistochemistry for detection of avian infectious bronchitis virus strain M41 in the proventriculus and nervous system of experimentally infected chicken embryos," *Virology Journal*, vol. 6, article 15, pp. 1–7.
- 2- Adzhar, A. , Shaw, K. , Britton, P. and Cavanagh, D. (1996). "Universal oligonucleotides for the detection of infectious bronchitis virus by the polymerase chain reaction," *Avian Pathology*, vol. 25, no. 4, pp. 817–836.
- 3-Cavanagh, D. (2003). "Severe acute respiratory syndrome vaccine development: experiences of vaccination against avian infectious bronchitis coronavirus," *Avian Pathology*, vol. 32, no. 6, pp. 567–582.
- 4-Chen, B. Y. and Itakura, C. (1997). "Histopathology and immunohistochemistry of renal lesions due to avian infectious bronchitis virus in chicks uninoculated and previously inoculated with highly virulent infectious bursal disease virus," *Avian Pathology*, vol. 26, no. 3, pp. 607–624.
- 5-Chong K. T. and Apostolov, K. (1982). "The pathogenesis of nephritis in chickens induced by infectious bronchitis virus," *Journal of Comparative Pathology*, vol. 92, no. 2, pp. 199–211.

- 6-Collisson, E. W. , Li, J. , Sneed, L. W. , Peters, M. L. and Wang, L. (1990). "Detection of avian infectious bronchitis viral infection using in situ hybridization and recombinant DNA," *Veterinary Microbiology*, vol. 24, no. 3-4, pp. 261–271.
- 7-Cook, J. K. H., Darbyshire, J. H. and Peters, R. W. (1976). "The use of chicken tracheal organ cultures for the isolation and assay of avian infectious bronchitis virus," *Archives of Virology*, vol. 50, no. 1-2, pp. 109–118.
- 8-Ghadakchi, H., Dadras, H., Pourbakhsh, S. A and Hosseini, S. M. H. (2005). "Standardization of an Enzyme-Linked Immunosorbent Assay for Detection of Infectious Bronchitis Virus Antibody," *Archives of Razi Institute*, vol. 59, pp. 75–83.
- 9-Grgić, H., Hunter, D. B., Hunton, P and Nagy, É. (2008). "Pathogenicity of infectious bronchitis virus isolates from Ontario chickens," *Canadian Journal of Veterinary Research*, vol. 72, no. 5, pp. 403–410.
- 10-Ignjatovic, J., Ashton, D. F. , Reece, R. , Scott, P. and Hooper, P. (2002). "Pathogenicity of Australian strains of avian infectious bronchitis virus," *Journal of Comparative Pathology*, vol. 126, no. 2-3, pp. 115–123.
- 11-Lee, C. W., Brown, C., and Jackwood, M. W. (2002). "Tissue distribution of avian infectious bronchitis virus following in ovo inoculation of chicken embryos examined by in situ hybridization with antisense digoxigenin-labeled universal riboprobe," *Journal of Veterinary Diagnostic Investigation*, vol. 14, no. 5, pp. 377–381.
- 12-Lucio B. and Fabricant, J. (1990). "Tissue tropism of three cloacal isolates and Massachusetts strain of infectious bronchitis virus," *Avian Diseases*, vol. 34, no. 4, pp. 865–870.
- 13-Mahdavi, S., Tavasoly, A., Pourbakhsh, S. A. and Momayez, R. (2007). "Experimental histopathologic study of the lesions induced by serotype 793/B (4/91) infectious bronchitis virus," *Archives of Razi Institute*, vol. 62, pp. 15–22.
- 14-Norusis, M.J. (2004). *SPSS 13.0 advanced statistical procedure companion*. Englewood Cliffs: Prentice Hall.
- 15-Purcell D. A. and McFerran, J. B. (1972). "The histopathology of infectious bronchitis in the domestic fowl," *Research in Veterinary Science*, vol. 13, no. 2, pp. 116–122.
- 16-Reed, L. J., and Muench, H. (1938). "A simple method of estimating fifty per cent endpoints," *American Journal of Epidemiology*, vol. 27, no. 3, pp. 493–497.
- 17-Seifi, S. , Asasi, K. , Mohammadi, A. , Shirzad, M. R. and Pourfallah, M. (2010). "Serological and gross findings in broilers with AIV and IBV," *Online Journal of Veterinary Research*, vol. 14, pp. 87–94.

- 18-Stachowiak, B., Key, D. W., Hunton, P., Gillingham, S and Nagy, É. (2005) “Infectious bronchitis virus surveillance in Ontario commercial layer flocks,” *Journal of Applied Poultry Research*, vol. 14, no. 1, pp. 141–146.
- 19-Terregino, C., Toffan, A. , Serena Beato M. (2008). “Pathogenicity of a QX strain of infectious bronchitis virus in specific pathogen free and commercial broiler chickens, and evaluation of protection induced by a vaccination programme based on the Ma5 and 4/91 serotypes,” *Avian Pathology*, vol. 37, no. 5, pp. 487–493.