

# Detection of Sperm Deformity by Kruger Strict Criteria using Pre- staining Slides Before and After Post Coital Test

Saad S. Al-Dujaily

*Chairman, Department of Clinical Reproductive Physiology, IVF Institute ,Al- Nahrain University*

Sondos K.Alatrakji,

Safaa Alhasani

*Department of Assisted Reproduction ,Lubeck University, Germany*

## Abstract

**Objective :** There are many methods to examine the sperm morphology .One of the most important method with high accuracy is Kruger strict criteria .The objective of this study is to :1-simplified the method and lowering the time consumption for examination. 2- find out any changes may occurs on sperm morphology through post coital test.

**Design:** Prospective study

**Settings:** IVF Institute, Al-Nahrain University, Baghdad-Iraq.

**Materials and Methods:** Seventy four unselected couples were involved at the present work who attend the Infertility Clinic of the IVF Institute. Semen fluid analysis(SFA) was performed for all men as recommended by WHO(1999).According to the results of SFA, the samples were divided into normal and abnormal semen . Azoospermic, sever oligospermic , sever asthenospermic samples were excluded from this investigation . Special pre-stained slides( Testsimplet® slides, Warymart-Germany) were used for examination of sperm deformity .One drop of liquefied semen was mounted on warmed pre-stained slides and covered by standard cover slip .The slides were left for 5 minutes at room temperature and examined as described by Kruger strict criteria. When the results of men samples showed normal sperm morphology, Post coital test were done for their spouses with normal cervical mucus score. The results of sperm morphology obtained from PCT were recorded by using the Kruger criteria too.

**Results:** There was 28 out of 74 semen samples with normal sperm morphology. Fifty two samples revealed abnormal sperm morphology when examined by Kruger criteria and 36 samples were abnormal by using staining method alone . The percentage of morphologically normal sperm using Kruger criteria pre-coital test was 14.8% and following PCT the percentage was 13.4%.The statistical analysis showed a significant( $P<0.05$ ) differences between them.

**Conclusion:** It is concluded from the present study that some results of normal sperm morphology were changed in the cervix to abnormal sperm form by using Kruger criteria, even the cervical mucus showed normal score. This may interpret some unexplained infertility cases. At the same time, the study noticed that the examination by the stained slides and using Kruger criteria was so simple , easy to perform and the time required to prepare the samples is short to start reading the results.

**Key words:** Kruger strict criteria, testsimplet slides, male infertility, post -coital test

## Introduction

Semen fluid analysis including sperm morphology remains the main pillar for male infertility work up. However, different methodologies for sperm morphology assessment have remained controversial because of the lack of universally acceptable method,(Said,2005).Meanwhile, there are many diagnostic laboratory techniques to evaluate semen quality, and utilize to interpretation infertility in both male and female, however explanation of infertility still obscure in about 10-15 % of cases,( Harrison *et al.*, 1997). Therefore, during the past decades, several methods of assessing sperm function have been introduced including the assessment of hyperactivated motility pattern of spermatozoa , the sperm zona pellucida (ZP) binding test, evaluation of the acrosome

status , zona free hamster egg penetration test and post coital test ,and monitoring of reactive oxygen species generation(Liu and Baker,1992) . In vitro fertilization has provided a unique opportunity to determine how predictive these tests are of the fertilizing capacity of spermatozoa(Franken *et al.*, 1990).

In 1986, Kruger and co-workers found that in a group of men with sperm densities greater than 20 million per milliliter and motility greater than 30% IVF rates were 37% for those with less than 14% normal sperm by strict criteria morphology (SCM) and 91% for those with greater than 14% normal sperm. Furthermore, Kruger noted that men with less than 4% normal SCM had an IVF rate of 7.6%, whereas those with 4% to 14% normal forms had a 63.9% fertilization rate (Kruger *et al.*,1986). Subsequent studies have confirmed the correlation between SCM and IVF rate (Ombelet *et al.*, 1995). Thus, one of the most important method to examine the sperm morphology with high accuracy is Kruger strict criteria .Therefore, the objective of this study is to :1-simplified the method and lowering the time consumption for examination. 2- find out any changes may occurs on sperm morphology through post coital test.

## Materials and Methods

A total number of seventy four unselected male patients who attended the infertility clinic of the Institute of Embryo Researches and Infertility Treatment - University of Al-Nahrain, Baghdad-Iraq, were included in this study during the period from November 2005 to October 2006. The mean age of these patients was 32 years and the majority of them (82.4%) had history of primary infertility. The duration of their infertility was ranging between 1.5-18 years with a mean of 4.6 years.

The standard semen analysis was performed according to the WHO, (1999) guidelines. Semen was collected in a clean, sterile, dry, plastic and warm disposable wide mouth dish, labeled with patient's name and the time of collection (Silverberg and Turner,2001). Semen sample was then immediately transferred to the laboratory and placed in an incubator at 37°C, waiting for liquefaction.

One drop (10µl) of liquefied thoroughly mixed semen was, mounted between warmed slides and covered with a standard cover slip. At least two hundred spermatozoa were counted and percent of normal morphology was reported ( Acosta *et al.*, 1986).

$$\text{Morphologically Normal Sperm\%} = \frac{\text{Number of normal sperms}}{\text{Total number of sperms}} \times 100$$

### 1- Modified Kruger Strict Criteria (MKSC):

In this study it has been used especial pre-stained slides for examination of sperm morphology. The stain contains two dyes, 2.1µg/cm<sup>2</sup> crystal violet acetate and 1.0µg/cm<sup>2</sup> new methylene blue. One drop (10µl) of semen was mounted between warmed slides covered with standard cover slip and left for 5 minutes at room temperature then examined under light microscope using oil-emersion power 1000X and graduated optic. Ten fields or 100 sperms were examined by measuring the length and width of the head axis for each sperm in the slide by the graduated optic and labeled in a table. The normal head axis length is 5-6 µm and normal head axis width 2.5-3.5 µm as reported by Kruger, *et al.* ( Kruger *et al.*,1987).

## 2. Post Coital Test (PCT):-

After evaluation of 74 unselected male patients who attended the infertility clinic in IVF Institute by routine seminal fluid analysis with examination of sperm morphology by MKSC ; 20 couples out of the number of men had normal semen parameters including normal sperm morphology by MKSC were done PCT. The female partners of those patients were examined physically and by vaginal ultrasound. All of them had normal reproductive hormonal profile and tubal potency. The PCT was done according to WHO recommendations ( WHO,1999).

### Post Coital Sperm Morphological Examination By Using MKSC:-

A drop of 10 $\mu$ l of collected cervical mucus (which was placed in a micro tube in an incubator) was placed on the especial pre-stained slides (mentioned previously), covered with standard cover slip and left for 5 minutes at room temperature then examined under light microscope using oil-emersion power 1000X and graduated optic. 100 sperms were examined by measuring the length and width of the head axis for each sperm in the slide. (Kruger *et al.*,1987).

### Statistical analysis

The data was shown as mean  $\pm$  SEM. The results were statistically analyzed using the Student's *t*-test and Chi-square depending on the nature of the data. When P value reaches the 0.05, the result was considered significant ( Sorlie,1995).

## Results

There was a significant ( $P<0.05$ ) different between all the semen criteria that examined of fertile and infertile men. The sperm concentration and the percentage of active sperm motility in fertile men were significantly ( $P<0.001$ ) higher than that of infertile men. There was 28 out of 74 semen samples with normal sperm morphology. Fifty two samples revealed abnormal sperm morphology when examined by Kruger criteria and 36 samples were abnormal by using staining method alone . Using Kruger strict criteria, the percentage of MNS in fertile men was  $15.5\% \pm 0.14$  and in the infertile men was  $10.3\% \pm 0.25$ . A significant ( $P<0.05$ ) different was found in the percentage of MNS between fertile and Infertile semen samples (Table-1) by using High power field method or Kruger criteria ( Figure-1).

There was a significant ( $P<0.001$ ) increase in sperm agglutination(%) between fertile and infertile semen .The number of round cells( cell/HPF) of infertile semen was significantly ( $P<0.001$ ) higher than that of fertile semen ( 8.94 vs. 3.0 , respectively) as shown in table-1.

In table-2 ,all the spouses ( $n=50$ )were shown normal cervical score ( $11.9 \pm 0.176$ ) , normal endometrial thickness( $8.76 \pm 0.269$ ) and follicle size of preovulatory period ( $19.53 \pm 0.393$ ).

The percentage of morphologically normal sperm of infertile semen using Kruger criteria pre-coital test was 14.8% and following PCT the percentage was 13.4%.The statistical analysis showed a significant( $P<0.05$ ) differences between them(Figure- 2).

**Table-1: Certain microscopic examination of the semen of fertile and infertile patients using two methods to measure the percentage of morphologically normal sperm**

<b>Sperm parameters</b>	<b>Fertile patients N=7*</b>	<b>Infertile patients N=67</b>
<b>Sperm concentration (millionx10<sup>6</sup>)</b>	49±2.14	17.57±0.53
<b>Active sperm motility(%)</b>	55.7±1.1	33.12±1.86
<b>morphologically normal sperm By /HPF(%)</b>	56.78±1.63	29.37±1.02
<b>morphologically normal sperm By Kruger strict criteria(%)</b>	15.5±0.14	10.3±0.25
<b>Sperm agglutination(%)</b>	6.6±2.3	23.3±0.8
<b>Round cells/HPF</b>	3.0±.21	8.94±0.7

Values are mean± SEM

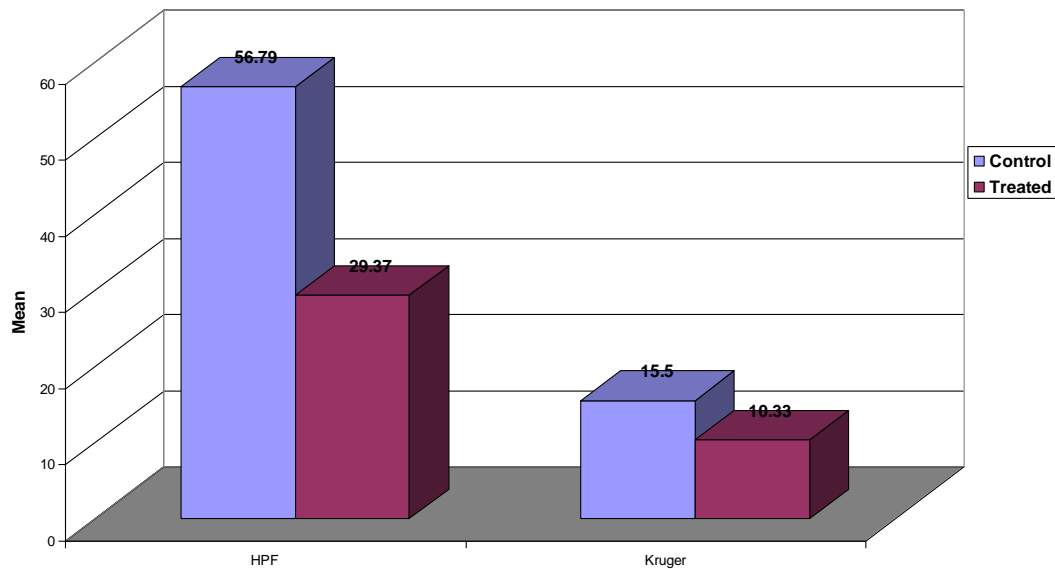
\*P<0.05: significantly different from other group

**Table-2: Some female reproductive system characters of pre-ovulatory period by using ultra-sound vaginal examination**

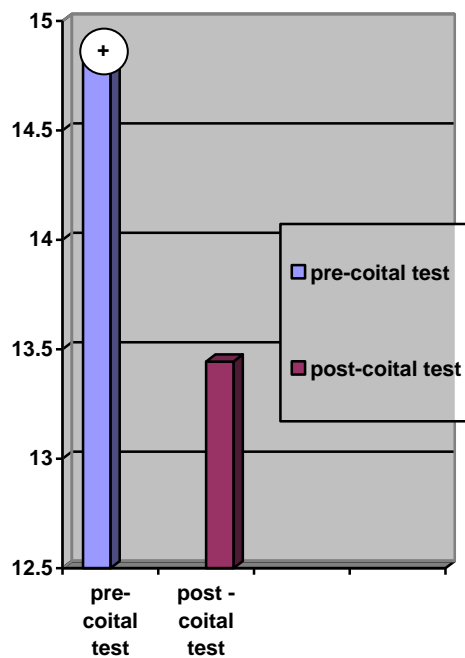
<b>Parameters</b>	<b>Mean</b>	<b>SEM</b>
Cervical score	11.90	0.176
Endometrial thickness	8.76	0.269
Follicle size	19.53	0.393

Values are mean ± SEM

No. females=50



**Figure-1:** The percentage of morphologically normal sperms of fertile (control ,n = 7 ) and infertile (treated ,n=67) men.



**Figure-2:** Morphologically normal sperm in infertile patients pre-post coital test using Kruger strict criteria  
 +P<0.05: Significantly different from post-coital test

## Discussion

In this study there was a highly significant correlation ( $P < 0.01$ ) between pre-and-PCT sperm morphology which was examined by MKSC using the special pre-stained slides mentioned previously. This data suggest that more sperm with abnormal morphology were present after migration through cervical mucus than before. Under normal condition the cervical mucus act as the first selective fluid encountered by sperm after entering the female genital tract. It selects sperm according to their kinetic efficiency and morphology (Al-Dujaily *et al.*, 2006 ; Ole *et al.*, 2003). According to this hypothesis, the percentage of live, progressively motile sperm and morphologically normal sperm must be higher after migration through cervical mucus than before (Ole *et al.*, 2003). The explanation for this controversial may be the presence of abnormal cervical mucus (providing that partner's semen were normal) either due to the presence of congenital cervical anomalies (e.g lack of endo-cervical glands, absence of hormonal receptors), silent pelvic inflammatory disease, low pH, destruction of the endocervical mucosa by previous operations, presence of anti-sperm antibodies, (Kremer and Jager, 1988 and 1992) and the treatment with anti-estrogen (e.g. Clomphen citrate ).

Although, the semen characters and cervical mucus score in some couples had shown normal values, there was an increase of abnormal sperm morphology following PCT. This finding indicates that these couples classified as unexplained infertility cases, whereas our result proved that the cervix may altered the sperm morphology due to changes in cervix secretion or the sperm may had negative response to cervical secretion affecting the permeability of cell membrane causing abnormality of sperm shapes. This in turn will decrease the possibility of sperm-oocyte interaction or sperm fusion process (Rodrigues-Martined *et al.*, 2001; Aziz *et al.*, 1996) , there will be no chance for fertilization or pregnancy.

## References

- Acosta, A. A.; Uem, J. V.; Ackorman, S. B.; Mayer, J. F. and Stecker, J. F. (1986). Estimation of Male Infertility by: Examination and Testing of Spermatozoa. In: In-Vitro Fertilization. H. W. Jones; G. S. Jones; G. D. Hodjen, and Z. Rozenmarks, (eds), Williams and Wilkins. Baltimor, Pp.126-161.
- Al-Dujaily, S. S.; Al-Nakash, A. R. and Al-Biaty, S.A. (2006). Effect of pentoxifylline on the outcome of artificial inseminations. Iraqi Postgraduate Medical Journal, 5(4):377-383
- Aziz, N.; Buchan, I.; Taylor, C.; Kingsland, C. R. and Lewis-Jones, I. (1996). The sperm deformity index: a reliable predictor of the outcome of oocyte fertilization in-vitro. Fertil. Steril., 66: 1000-1008.
- Franken, D.; Burkman, L.; Coddington, C.; Oehninger, S. and Hodgen, G. (1997). Human Hemizona Attachment Assay. In: Human Spermatozoa in Assisted Reproduction. A. Acosta; R. Swanson; S. Ackerman; T. Kruger; J. Van-Zyl; R. Menkveld; (eds), Williams and Wilkins. Baltimore, Pp. 355.
- Harrison, R.F., Barret, T., and Stalling, S. (1997). Cytogenetic analysis is essential before ICSI. Hum. Reprod., 12(8):1835.
- Liu, D.Y. and Baker, H.W. (1992). Tests of human sperm function and fertilization *in vitro*. Fertil. Steril., 58(3):465-602.

- Kremer, J. and Jager , S.( 1988). Sperm cervical mucus interaction , in particular in the presence of anti-spermatozoal antibodies. Hum.Reprod., 3: 69-73.
- Kremer, J. and Jager, S.( 1992) The significance of antibodies for sperm- cervical mucus interaction. Hum. Reprod., 7: 781-784.
- Kruger, T. F.; Menkveld, R.; Stander, F. S. H.; Lombard, C. J.; Van-Der, M. P.; Van-Zyl, J. A. and Smith, K.( 1986) Sperm Morphology Features as a Prognostic in *In-Vitro* Fertilization. Fertil. Steril., 46: 1118.
- Kruger, T. F.; Acosta, A. A.; Simmons, K. F.; Swanson, R. J.; Matta, J.F.; Veeck, L. L.; Morshidi, M. and Brugo, S.( 1987). New Method of Evaluating Sperm Morphology with Predictive Value for Human in In-Vitro Fertilization. Urol., 30(3): Pp. 248.
- Ola ,B .; Afnan ,M.; Papaioannon , S.; Sharif ,K.; Bjorndabl , L and Coomarasamy , A.(2003).Accuracy of sperm cervical-mucus penetrationtests in evaluating sperm motility in semen :a systematic quantative review .Hum.Reprod.,18(5):1037-1046.
- Ombelet, W.; Menkveld,R.;Kruger,T. F.and Steeno, O.( 1995).Sperm morphology assessment : historical review in relation to fertility. Hum. Reprod. Update , 1: 543-557.
- Rodriguez-Martinez,H.;Tienthai,P.;Suzuki,K.;Funahashi,H. Ekwall, H and Jahannisson ,A .( 2001) Involvement of oviductal in sperm capacitation and oocyte development in pigs .Reproduction ,Suppl., 58:129-145
- Said, T. M.; Grunewald ,S.;Paasch ,U.;Rasch, M., Agarwal, A. and Glander ,H. (2005).Effects of magnetic – activated cell sorting on sperm motility and cryosurvival rates. Fertil. Steril.,83:1442-1446.
- Silverberg, K.M. and Turner,T.( 2001). Evaluation of sperm In : Textbook of Assisted Reproductive Techniques and Laboratory Clinical Perspectives D K. Gardener, A. Weissman, C.M. Howles , Z. Shoham M. Dunitz m (eds),Ltd., Pp: 71-73 .
- Sorlie, D.E. (1995).Medical Biostatistics and Epidemiology: examination and board review. 1st edition. Appleton and Lang, Norwalk, Connecticut. Pp 47-88.
- World Health Organization .( 1999). WHO laboratory manual for examination of human semen and sperm-mucus interaction. 4<sup>th</sup>ed Cambridge; United Kingdom: Cambridge University press.