

# Doxorubicin Induced Nephrotoxicity: Protective Effect of Rosmary leaves

Sura Salman Ejam

College of Medicine, University of Babylon

[ejamsura@yahoo.com](mailto:ejamsura@yahoo.com)

## Abstract

**Background:** Doxorubicin (DOX) is a potent anthracycline antibiotic. It is a widely used drug in the cancer to treat a wide variety of human malignancies. Cardiotoxicity has long been recognized as a complicating factor of DOX. This study was designed to investigate the acute DOX-induced cardiotoxicity, nephrotoxicity, hepatotoxicity.

**Material and Methods:** Twenty eight male Swiss Albino mice were randomly divided into four groups including group1 (negative control), treated with distill water (D.W) intraperitoneal (i.p) injection , group 2 (positive control), treated with 15 mg/kg DOX as a single (i.p) injection, groups 3 received 30mg/kg of the aqueous extract of *Rosmarinus officinalis* leaves (ROE) orally (p.o), once daily for 2 weeks, then injected i.p with 15 mg/kg DOX. Two days after DOX or D.W (in control group) injection, animals in all groups were scarified and the levels of the blood urea and serum creatinin were measured. Also the possible cardiac histopathological changes were investigated.

**Results:** The administration of DOX (15 mg/kg i.p.) induced nephrotoxicity which manifested by significant elevation ( $p<0.05$ ) in blood urea and serum creatinin levels. In addition, kidneys histopathological sections showed development of sever glomerulosclerosis, tubular necrosis and tubulointerstitial lesion. Oral administration of 30mg/kg ROE 2 weeks prior to DOX produced a significant protection which was evidenced by significant reduction ( $p<0.05$ ) in blood urea and serum creatinin levels. Moreover, histopathological sections showed only mild tubular necrosis and in comparison to DOX positive control group ( $p<0.01$ ).

**Conclusion:** Administration of 30mg/kg ROE protect against DOX-induced nephrotoxicity.

**Key words:** Doxorubicin, *Rosmarinus officinalis*, nephrotoxicity, mice.

## الخلاصة

**المقدمة:** إن الدوكسوروبيسين يستعمل كعقار كيميائي (doxorubicin) مضاد حيوي فعال من مجموعة الانثراسايكلين وهو لمعالجة عدة أنواع من الأورام السرطانية. التأثير السمي على الكلى هو من أهم الآثار الجانبية لهذا العقار. لقد أجريت هذه الدراسة لمعرفة فاعلية نبات إكليل الجبل للحماية ضد التأثير السمي للدوكسوروبيسين على الكلى في ذكور الفئران. **المواد وطرائق العمل:** لقد تم استخدام 21 ذكرا من الفئران البالغة لإجراء هذه الدراسة حيث قسمت عشوائيا إلى أربعة مجاميع. أعطيت المجموعة الأولى الماء المقطر عن طريق الفم (بواسطة الأنبوب المعدي) لمدة أسبوعين، أما المجموعة الثانية فقد تم حقنها (داخل البريتون) بعقار الدوكسوروبيسين (15 ملغم/كغم) كجرعة مفردة، إما المجموعة الثالثة فقد عولجت بجرعة 30 ملغم/كغم من المستخلص المائي لأوراق نبات إكليل الجبل عن طريق الفم مره واحدة يوميا لمدة أسبوعين ومن ثم تم حقنها (داخل البريتون) بعقار الدوكسوروبيسين (15 ملغم/كغم) كجرعة مفردة. تم سحب الدم بعد يومين من حقن الماء المقطر (للمجموعة الأولى) او الدوكسوروبيسين (لبقية المجاميع) حيث تم قياس مستوى اليوريا في الدم والكرياتينين في مصل الدم. كما تم تقطيع كلى الفئران بعد قتلها وتحضير المقاطع النسيجية وصبغها بصيغة الهيماتوكسيلين والايوسين حيث فحصت تحت المجهر الضوئي للكشف عن أي تغيرات نسيجية محتملة.

**النتائج:** لقد بينت نتائج هذه الدراسة حصول انخفاض معنوي ( $p<0.05$ ) في مستوى اليوريا في الدم والكرياتينين في مصل الدم للمجموعة التي عولجت بالمستخلص المائي لأوراق نبات إكليل الجبل بجرعة 30 ملغم/كغم لمدة أسبوعين قبل حقنها بالدوكسوروبيسين مقارنة بالمجموعة التي حقنت بالدوكسوروبيسين فقط كما أكد هذا بنتائج الفحص النسيجي حيث حصل انخفاض معنوي ( $p<0.01$ ) في نسبة التغيرات النسيجية المرضية في العضلة القلبية لهذه المجموعة.

**الاستنتاجات:** إن نبات إكليل الجبل المعطى بجرعة 30 ملغم/كغم لمدة اسبوعين قبل حقن الدوكسوروبيسين كان له دور في حماية الكلى من التأثير السمي لعقار الدوكسوروبيسين.

**الكلمات المفتاحية:** الدوكسوروبيسين، إكليل الجبل، سمية الكلى، الفئران.

## Introduction

### Doxorubicin (DOX):

Doxorubicin (also called adriamycin) is a potent anthracycline antibiotic which have been widely used in the chemotherapy to treat a wide variety of malignancies (Sauter *et al.*, 2010; Shi *et al.*, 2011) including solid and hematopoietic tumors (Lothstein *et al.*, 2001; Simunek *et al.*, 2009). It is a valuable component of various chemotherapeutic regimens of breast carcinoma and small-cell lung carcinoma. In metastatic thyroid carcinoma, DOX is the best available agent, also it is an important ingredient for the successful therapy of Hodgkin's disease and non-Hodgkin's lymphomas and many other cancers (Kufe *et al.*, 2003; Smith *et al.*, 2010).

The exact mechanism of action of DOX as anticancer agent is not fully understood, it has been attributed to the intercalation into DNA, leading to inhibition of macromolecular synthesis, preventing the replication of rapidly growing cancer cells (Sauter *et al.*, 2010; Hynek *et al.*, 2012; Shi *et al.*, 2011).

Nowdays, the inhibition of topoisomerase II- $\alpha$  is thought to be the main cellular target of DOX (Horenstein *et al.*, 2000 ; Simunek *et al.*, 2009; Hynek *et al.*, 2012). DOX acts by stabilizing a reaction intermediate in which DNA strands are cut and covalently linked to the tyrosine residues of topoisomerase II, thus it blocks subsequent DNA resealing. Failure to relax the supercoiled DNA lead to blockage of DNA replication and transcription. So, DNA strand breaks lead for triggering of apoptosis of cancer cells, apparently via the p53-dependent pathway (Ruiz-Ruiz *et al.*, 2003). Other mechanism of action include metal ion chelation and free radical generation, leading to DNA damage or lipid peroxidation (Sparreboom *et al.*, 2002; Xu *et al.*, 2005; Sauter *et al.*, 2010), it also may induce apoptosis (Takemura and Fujiwara, 2007). DOX also can reduce the viability of cancer cells via RNA damage and inhibit the synthesis of DNA, RNA and proteins (Fimognari *et al.*, 2009; Shi *et al.*, 2011).

The optimal use of doxorubicin is limited by a number of side-effects, the most important are cardiotoxicity, haematotoxicity [Al-Harbi *et al.*, 1992] and a doselimiting nephrotoxicity [Jovanovic, *et al.*, 1996].

DOX cytotoxicity and genotoxicity may be mediated by free radicals derived from this drug and its capability to induce apoptosis through a wide variety of mechanisms including production of ROS, alkylation of cellular macromolecules, DNA intercalation and cross-linking, lipid peroxidation, cell membrane damage, ceramide production and p53 induction in various tissues (Bose *et al.*, 1995; Quiles *et al.*, 2002; Sparreboom, *et al.*, 2002; Ashikawa *et al.*, 2004).

The exact mechanism of doxorubicin-induce nephrotoxicity is not yet known. Although the exact mechanism of DXR-induced nephrotoxicity remains unknown, it is believed that the toxicity may be mediated through free radical formation, iron-dependent oxidative damage of biological macromolecules, membrane LPO, and protein oxidation [Liu *et al.*, 2007.]. DXR-induced changes in the kidneys of rats include increased glomerular capillary permeability and tubular atroph [Wapstra, *et al.*, 1999].

### **Herbal protection against chemotherapeutic toxicity:**

Herbal drug therapy is considered a common practice adopted in traditional and alternative medicine and has been used in the treatment of many diseases from ancient times (Nabavizadeh, 2009). Plant material in the human diet contains a large number of natural compounds, which may be of benefit in protecting the body. Scavenging of free radicals, elevation of cellular antioxidants, induction of bone marrow recovery and extraheamatological tissue regeneration by plants and herbs in damaged systems could be leading mechanisms of protection (Joshi *et al.*, 2010). one of the plants with constituents reputed to possess antioxidant properties was *Rosmarinus officinalis*.

### **Rosmarinus Officinalis (RO):**

*Rosmarinus Officinalis* (also called Rosemary) an evergreen shrub is one of the herb spices of the family Labiatae. It was cultivated in Mediterranean first, then transplanted to China in Dynasty, but cultivated in all of the world now (Hui-Hur *et al.*, 2001). Rosemary is a perennial evergreen herb with fragrant needle-like leaves (Bousbia *et al.*, 2008). Rosemary herbs have been widely used in the traditional medicine and cosmetics. They are also used as flavouring agents in foods (Pintore *et al.*, 2002). RO essential oil is also important for its medicinal uses and its powerful antibacterial, cytotoxic, antimutagenic, antioxidant, antiphlogistic and chemopreventive properties (Koschier *et al.*, 2003; Ohno *et al.*, 2003; Celiktas *et al.*, 2007). Leaves of RO possess a variety of bioactivities; including antioxidant (Bozin *et al.*, 2007; Wang *et al.*, 2008), antitumor (Singletary *et al.*, 1996; Abdullah *et al.*, 2010), antibacterial (Bousbia *et al.*, 2008; Celiktas *et al.*, 2007; Gachkar *et al.*, 2007) and anti-inflammatory actions (Altinier *et al.*, 2007). These bioactivities of the rosemary leaves extract are comparable with known antioxidants constituents, such as carnosic acid, carnosol, rosemarinic acid, ursolic acid, butylated hydroxyanisole and butylated hydroxytoluene, without the cytotoxic and carcinogenic risk of synthetic antioxidants (Almela *et al.*, 2006; Ramirez *et al.*, 2006).

### **Aim of the study**

To investigate the *Rosmarinus officinalis* leave extract (ROE) protective role on renal tissue against DOX-induced nephrotoxicity.

### **Materials and Methods:**

#### **1. Preparation of Plant Extract:**

Leaves of RO were purchased from the Hilla local market and identified by a competent botanist at the collage of science for girls, at Babylon university, Iraq. We washed the leaves carefully leaves , then air dried in shade at room temperature, then grinded to fine powder. The leaves extract was prepared by extracting 40 gm of leaves powder with 80 ml distilled water by refluxing with sohxcilate instrument for 36 hrs at 50-60 °C. Pellets of the extract were obtained by evaporation of its liquid contents in the incubator. We dissolved the pellets in distilled water to prepare the required dose of treatment and administered by stomach tube at a doses of 15 mg/kg and 30 mg/kg body weight daily for 14 consecutive days (Jindal *et al.*, 2006).

## 2. Animals:

Twenty eight male Swiss Albino mice (weighting 25 – 30 g) were used in our study. The mice put in the animal house in the college of medicine in Babylon university under constant conditions of temperature ( $22 \pm 2$ ) °C and lighting (12:12hr light: dark cycle) for two weeks before and through the experimental work, the mice being maintained on a standard commercial mice chow and tap water were available *ad-libitum*.

## 3. Experimental design:

The animals were randomly divided into 4 groups (7 mice in each group) as follows:

**Group 1** (negative control): received 0.3ml distilled water (D.W), orally (p.o) by using stomach tube once daily for 2 weeks, then injected i.p with D.W

**Group 2** (positive control): injected intraperitoneally (i.p) with 15mg/kg DOX (EBEWE Pharma Ges.m.b.H. Nfg.KG, AUSTRIA) (Nilesh Shinde, *et al.*, 2010)

**Group 3:** received 30 mg/kg of ROE, p.o once daily for 2 weeks, then injected i.p with 15 mg/kg DOX.

After 2 days of DOX or D.W (in negative control group) injection, animals in all groups were scarified (Abd-Allah *et al.*, 2002) under light anesthesia with diethyl ether. the kidneys were extracted and fixed in 10% formalin to investigate the probable histopathological changes.

### Blood samples preparation:

The blood was aspirated 2 days after D.W. or DOX injection from the heart of mice in all groups . The blood was directly collected through intracardiac puncture by disposable plastic syringes and immediately transferred into plastic test tubes without anticoagulant and left for 15 - 20 minutes at room temperature to promote blood coagulation. Serum was obtained after centrifugation at 3000 rpm for 10 minutes and preserved at -20 °C until the determination of blood urea and serum creatinin.

### Measurement of serum creatinine:

In an alkaline media, creatinine reacts with picrate to form a coloured (yellow-orange) complex which absorbs light at 510 nm. The rate of color formation is proportional to the creatinine concentration in the sample ( Henry, 1974). Kit used is spinreact sa kit.

### Measurement of serum urea:

According to the modified urease-Berthelot method, the salicylate and hypochlorite in the reagent react with the ammonium ions to form a coloured (green) complex, that can measured by spectrophotometer at 580 nm to determine the level of urea in the serum (Fawcett and Scott, 1960). Kit used is biomerieux sa kit.

### Histopathological slides preparation:

The kidneys of mice were sectioned and stained with haematoxiline and eosin stain and examined under light microscope to detect the histopathological changes.

## Statistical Analysis

The SPSS version 17.0 was used for the statistical analysis, test was used is this study for S.ck and LDH, while chi-square test was used for histopathological changes. The data expressed as mean  $\pm$  SD, P-values less than 0.05, 0.01 and 0.001 were considered as statistically significant, high significant and extremely significant respectively. (Daniel, 1999).

## Results

### 1. Biochemical

In group 2 (received 15mg/kg DOX only) haematological examination showed high significant ( $p < 0.001$ ) increase in serum levels of both blood urea and serum creatinin, as compared to group 1 (received D.W). In group 3 (received 30mg/kg ROE 2 weeks before DOX injection) ROE treatment resulted in a high significant reduction ( $p < 0.001$ ) in serum levels of both blood urea and serum creatinin, as compared to group 2 as shown in (Table 2).

### 2. Histopathological

- 1- Renal histopathological sections for all mice in group 1 (negative control) (100%) showed normal renal histology ( Fig. 1)
- 2- Renal histopathological sections for mice in group 2 (positive control) which injected with DOX (15mg/kg) only, showed development of sever inflammation and tubular necrosis and in 6(85.71%) mice (Fig. 2) and mild changes in 1(14.29%) mouse (Fig. 3), that was highly significantly differ from negative control group ( $P < 0.01$ ).
- 3- Renal histopathological sections for mice in group 3 which received ROE 30 mg/kg for 2 weeks before DOX (15mg/kg) injection showed mild tubular necrosis in 5 (71.43%) mice (Fig. 3). and sever changes in 2(28.57%) mice (Fig. 2).

**Table 1: Histopathological changes in each experimental group**

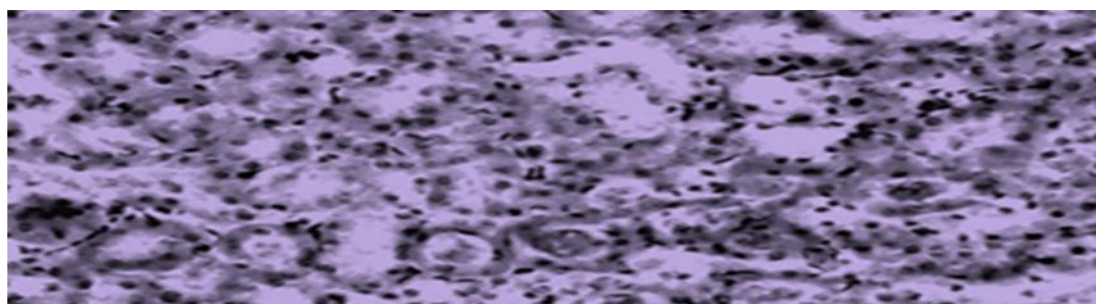
Experimental groups	Normal renal histology	Mild inflammation, and tubular necrosis	Sever inflammation and tubular necrosis	Total
Negative control	7 (100%)	0	0	7 (33.33%)
Positive control	0	1 (14.29%)	6 (85.71%) <sup>a</sup>	7 (33.33%)
DOX + ROE 30mg/kg	0	5 (71.43%) <sup>a,b</sup>	2 (28.57%) <sup>b</sup>	7 (33.33%)
Total	7 (33.33%)	6 (28.57%)	8 (38%)	21 (100%)

a=  $P < 0.01$  vs. negative control; b=  $P < 0.01$  vs. DOX positive control group.

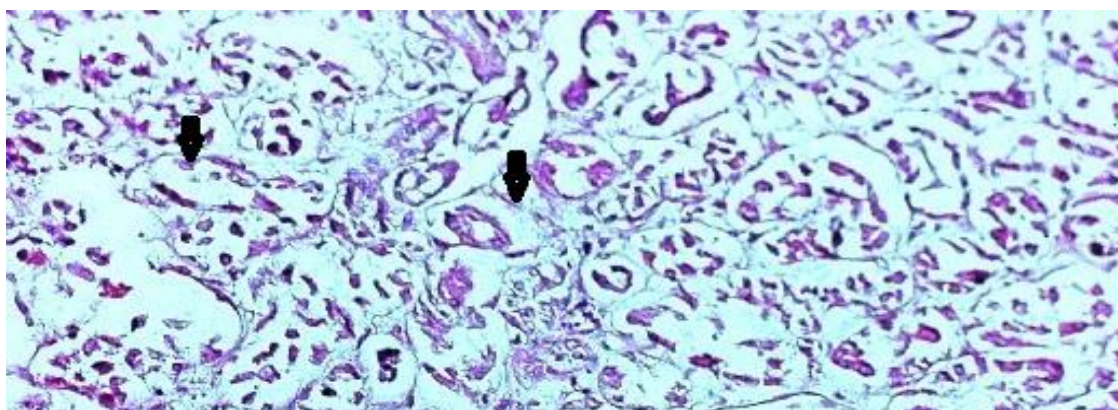
**Table 2: blood urea and serum creatinin changes in each experimental group  
(results are expressed as mean  $\pm$  SD)**

Groups	Serum CK Mean $\pm$ SD	Serum LHD Mean $\pm$ SD
Negative control	30 $\pm$ 6.2	0.36 $\pm$ 0.05
Positive control	60.8 $\pm$ 9.5 <sup>a</sup>	0.68 $\pm$ 0.035 <sup>a</sup>
DOX + ROE 30mg/kg 2 weeks before DOX	40.4 $\pm$ 40.4 <sup>a,b</sup>	0.41 $\pm$ 0.08 <sup>b</sup>


a=P< 0.05 vs. negative control; b=P< 0.05 vs. DOX positive control.



**Figure 1: kidney section show the normal histology**



**Figure 2: renal histopathological section show the sever tubular necrosis**



**Figure 3: renal histopathological section show normal renal tubules with Mild tubular necrosis (arrow)**

### Discussion:

Antioxidants were reported to have beneficial effects against DOX-induced nephrotoxicity in mice and rats (Liu *et al.*, 2002) so they protect cells and tissues from oxidative damage induced by free radical injury (Nakagawa and Yokozawa, 2002). Thus when the antioxidant defense mechanisms is less developed, kidney is more susceptible to the injury by anthracycline induced ROS (Abou-El-Hassan *et al.*, 2003).

Results of the present study indicate that DOX (15 mg/kg) induced oxidative stress in renal tissues as manifested by elevated blood urea and serum creatinin. These results are agree with (Nilesh Shinde, *et al.*, 2010;) which revealed similar elevations in blood urea and serum creatinin in rats following challenge with a single dose of DOX. Also the histopathological changes found by the our study in DOX- only treated group are consistant with (Nilesh Shinde, *et al.*, 2010) which found that light microscopic examination of kidneys of rat showed moderate tubular atrophy & dilation in DXN alone. Also, it was reported that DXR-induced changes in the kidneys of rats include tubular atrophy [Wapstra, *et al.*, 1999].

It had been found that the RO leaves extract has potent antioxidants like flavonoids, phenols, volatile oil and terpenoids (Asada, 1999; Almela *et al.*, 2006). Also Moreno *et al* (2006) reported that rosemary extracts have a high scavenging capacity of different types of ROS and nitrogen species, so free radicals, thought to be one of the major mechanisms of the antioxidant action exhibited by phenolic phytochemicals (Moreno *et al.*, 2006). Among the antioxidant compounds in the leaves of rosemary, ~90% of the antioxidant activity can be attributed to carnosol and carnosic acid. Carnosol, a naturally occurring polyphenol which is found in rosemary leaves, showed a potent antioxidative activity against  $\alpha$ -diphenyl-B-picryldrazyl free radicals produced from Fenton reaction (Lo *et al.*, 2002). In another study extract of rosemary supplemented to chicken, slowed down effectively the lipid peroxidation (Serdaroglu and Yildiz-Trup, 2004).

In our study oral administration of 30mg/kg ROE 2 weeks prior to DOX produced a reduction in blood urea and serum creatinin levels, in addition to the histopathological sections that eveal only mild tubular necrosis in comparison to DOX positive control group. This effect of RO may be due to the antioxidative activity of one or more of its constituents (Bozin *et al.*, 2007; Wang *et al.*, 2008), that may reduce nephrotoxicity due to DOX-induced oxidative stress (Moreno *et al.*, 2006).

## Conclusions

Our study revealed that rosemary aqueous extract decreases the DOX-induced nephrotoxicity in albino mice.

## References

- Abd-Allah AR**, Al-Majed AA, Mostafa AM, Al-Shabanah OA, Din AG, Nagi MN. (2002). Protective effect of arabic gum against cardiotoxicity induced by doxorubicin in mice: a possible mechanism of protection. *J Biochem Mol Toxicol.*; 16(5):254-9.
- Abdullah Ijaz** Hussain; Farooq Anwar; Shahzad Ali Shahid Chatha; Abdul Jabbar; Shahid Mahboob; Poonam Singh Nigam (2010). Rosmarinus officinalis essential oil: antiproliferative, antioxidant and antibacterial activities. *Braz. J. Microbiol.* vol.41 no.4 São Paulo Oct./Dec.
- Abou-El-Hassan M A**, Rabelink M J, van der Vijgh W J, Bast A and Hoebein RC. (2003), A comparative study between catalase gene therapy and the cardioprotector monohydroxyethylrutoside (MonoHER) in protecting against doxorubicin-induced cardiotoxicity in vitro. *Br J Cancer.*, 89, 2140-6.
- Al-Harbi M**, Al-Garably M, Al-Shabanah O, Al-Bekairi A, Osman A, Tawfik H. *Cancer Chem Pharmacol* 1992; 31: 200-204.
- Almela, L.**, B. Sanchez-Munoz, J.A. Fernandez- Lopez, M.J. Roca and V. Rabe (2006). Liquid chromatographic-mass spectrometric analysis of phenolics and free radical scavenging activity of rosemary extract from different raw material. *J. Chromatogr.*, 1120: 221-229.
- Altinier G**, Sosa S, Aquino RP, Mencherini T, Della Loggia R, Tubaro A. (2007). Characterization of topical anti-inflammatory compounds in *Rosmarinus officinalis* L. *J. Agric. Food Chem.*; 55: 1718-1723.
- Asada, K.**(1999). The water-water cycle in chloroplasts: scavenging of active oxygen and dissipation of excess photons. *Annu. Rev. Plant. Physiol. Plant. Mol. Biol.*, 50: 601-639.
- Ashikawa K**, Shishodia S, Fokt I, Priebe W, Aggarwal B B. (2004). Evidence that activation of nuclear factor- $\kappa$ B is essential for the cytotoxic effects of doxorubicin and its analogues. *Biochemical Pharmacology*. 67(2): 353-364.
- Bose R**, Verheij M, Haimovitz-Friedman A, Scotto K, Fuks Z, Kolesnick R. (1995). Ceramide synthase mediates daunorubicin-induced apoptosis: an alternative mechanism for generating death signals. *Cell*. 82: 405-414.
- Bousbia, N.**; Vian, M.A.; Ferhat, M.A.; Petitcolas, E.; Meklati, B.Y.; Chemat, F. (2008). Comparison of two isolation methods for essential oil from rosemary leaves: Hydrodistillation and microwave hydrodiffusion and gravity. *Food Chem.*14,355-362.
- Bozin, B.**; Mimica-Dukic, N.; Samojlik, I.; Jovin, E. (2007). Antimicrobial and antioxidant properties of rosmary and sage (*Rosmarinus officinalis* and *Salvia officinalis*, Lamiaceae) essential oils. *J. Agric. Food Chem.* 55, 7879-7885.
- Celiktas, O.Y.**; Kocabas, E.E.H.; Bedir, E.; Sukan, F.V.; Ozek, T.; Baser, K.H.C. (2007). Antimicrobial activities of methanol extracts and essential oils of *Rosmarinus officinalis*, depending on location and seasonal variations. *Food Chem.*100,553-559.
- Daniel, W.W.** (1999). Probability and distribution. Biostatistics. A foundation for analysis in the health sciences .7th ed.; 83-123.

- F.H.Wapstra,H.VanGoor,P.E.DeJong,G.Navis,andD. De Zeeuw, "Dose of doxorubicin determines severity of renal damage and responsiveness to ACE-inhibition in experimenta nephrosis,"Journal of Pharmacological and Toxicological Methods, vol. 41, no. 2-3, pp. 69–73, 1999.1
- Fawcett J.K.** and **Scott J.E.** (1960). Determination of urea in blood or serum. *J.Clin. Path.* ; 13: pp. 156-159.
- Fimognari, C.;** Sestili, P.; Lenzi, M.; Cantelli-Forti, G. and Hrelia, P. (2009). Protective effect of creatine against RNA damage. *Mutat Res*; 670: 59-67.
- Gachkar, L.;** Yadegari, D.; Rezaei, M.B.; Taghizadeh, M.; Astaneh, S.A.; Rasooli, I. (2007). Chemical and biological characteristics of *Cuminum cyminum* and *Rosmarinus officinalis* essential oils. *Food Chem.* 102, 898-904.
- Henry R.J.** (1974). *clinical chemistry , principles and tecnics* ,2<sup>nd</sup> editio, Harper and Raw, P.525.
- Horenstein, M.S.;** Vander Heide, R.S. and L'Ecuyer, T.J. (2000): Molecular basis of anthracycline-induced cardiotoxicity and its prevention. *Mol. Genet. Metab.*; 71(1-2):436-444.
- Hui-Hur, Z.,** T.U. Peng-Fei, Z. Kan, W. Hui, W. Bao- Huai and L.U. Jing-Feng (2001). Antioxidant properties of phenolic diterpenes from *Rosmarinus Officinalis*. *Acta. Pharmacol. Sin.*, 22(12): 1094-1098.
- Hynek, D.;** Krejcova, L.; Zitka, O.; Adam, V.; Trnkova, L. and Sochor, J. (2012). Electrochemical Study of DOX Interaction with Different Sequences of Double Stranded Oligonucleotides, Part II, *Int. J. Electrochem. Sci.*, 7: 34-49.
- Jindal, A.,** D. Soyal, I. Sihgh and R. Reszka (2006). Modification of radiation-induced damage in mice by *Rosemarinus officinalis* extracts (ROE). *Pharmacology Line.*, 2: 63-75.
- Joshi, Y.M.;** Jadhav, T.A.; Kadam, V.J. (2010). A pharmacological intervention for protection against ionizing radiations: A review. *The Internet Journal of Internal Medicine.* 8 (2): 1-20.
- Jovanovic D,** Djukanovic I, Susic D, Funduk G, Jovanovic Z, Dragojlovic Z, Boydanovic G, Starcevic Bonzovic Z. *Srp Arh Celok Lek* 1996; 124 (1): 47-49.
- Koschier, E.H.;** Sedy, K.A. (2003). Labiate essential oils affecting host selection and acceptance of Thrips, *Tabaci lindeman.* *Crop Prot.* 22, 929-934.
- Kufe, D.W.;** Holland, J.F. and Frei E. (2003). *American Cancer Society: Cancer medicine* 6., BC Decker, Hamilton.
- Liu X,** Chen Z, Chua CC, Ma Y, Youngberg GA, Hamdy R and Chua BHL. (2002). Melatonin as an effective protector against Doxorubicin induced cardiotoxicity. *Americ J Physiol Heart and Circulatory Physiol.*, 283, H254-H263.
- Liu, L. L. ;** Li, Q. X. ; Xia, L.; Li, J. and L. Shao, "Differential effects of dihydropyridine calcium antagonists on doxorubicininduced nephrotoxicity in rats,"*Toxic ology*, vol. 231, no. 1, pp.81–90, 2007.
- Lo A,** Liang Y, Lin-Shiau S, Ho C, Lin J. (2002). Carnosol, an antioxidant in rosemary, suppresses inducible nitric oxide synthase through down-regulating nuclear factor- B in mouse macrophages *Carcinogenesis.* 23 (6): 983- 991.
- Lothstein, L.;** Israel, M.; Sweatman, T. W. (2001). Anthracycline drug targeting: cytoplasmic versus nuclear-a fork in the road. *Drug Resist. Updat.* 4:169–177.
- Moreno, S.,** Scheyer T., Romano C.S., Vojnov A.A. (2006): Antioxidant and antimicrobial activities of rosemary extracts linked to their polyphenol composition. *Free Radical Research,* 40 (2): 223-231.

- Nabavizadeh, S. H.;** Majid, O. and Anushiravani, A. (2009). Direct ex vivo effects of herbal extracts on serum bilirubin in neonatal blood samples. *African Journal of Biochemistry Research*;3(5):226-228.
- Nakagawa** and Yokozawa T.( 2002). Direct scavenging of nitric oxide and superoxide by green tea. *Food Chem. Toxicol.*, 40, 1745-50.
- Nilesh Shinde,** Amit Jagtap, Vaishali Undale, Sujit Kakade, Sachin Kotwal, Ravindra Patil,2010; Protective effect of *Lepidium sativum* against doxorubicin-induced nephrotoxicity in rats, *Research Journal of Pharmaceutical, Biological and Chemical Sciences* Volume 1 Issue 3 Page No. 42-48.
- Ohno, T.;** Kita, M.; Yamaoka, Y.; Imamura, S.; Yamamoto, T.; Mitsufuji, S.; Kodama, T.; Kashima, K.; Imanishi, J. (2003). Antimicrobial activity of essential oils against *Helicobacter pylori*. *Helicobacter* 8, 207-215.
- Pintore, G.;** Usai, M.; Bradesi, P.; Juliano, C.; Boatto, G.; Tomi, F.; Chessa, M.; Cerri, R.; Casanova, J. (2002). Chemical composition and antimicrobial activity of *Rosmarinus officinalis* L. oils from Sardinia and Corsica. *Flav. Frag. J.* 17, 15-19.
- Quiles J,** Huertas J, Battino M, Mataix J, Ramirez-Tortosa M. (2002). Antioxidant nutrients and adriamycin toxicity. *Toxicology*.180, 79–95.
- Ramirez P,** Garcia-Risco M, Santoyo S, Seiorins F, Ibitez E Reglero, G. (2006). Isolation of functional ingredients from rosemary by preparative-supercritical fluid chromatography (Prep-SFC). *J. Pharm. Biomed. Anal.*;41(5):1606-13.
- Ruiz-Ruiz, C.,** Robledo, G., Cano,E., Redondo, J. M., and Lopez-Rivas, A. (2003). Characterization of p53-mediated up-regulation of CD95 gene expression upon genotoxic treatment in human breast tumor cells. *J. Biol. Chem.* 4,4.
- Sauter, K.A.D.;** Magun, E.A.; Iordanov, M.S. and Magun, B.E. (2010). ZAK is required for DOX, a novel ribotoxic stressor, to induce SAPK activation and apoptosis in HaCaT cells *Cancer Biology & Therapy*, 10 (3): 258-266.
- Serdaroglu M,** Yildiz-Turp G. (2004). The effects of ascorbic acid, rosemary extract and  $\alpha$ -tocopherol/ascorbic acid on some quality characteristics of frozen chicken patties. *Food Sci. Technol.* 7(1): 1-5.
- Shi, Y.;** Moon, M.; Dawood, S.; McManus, B. and Liu, P. (2011). Mechanisms and management of DOX cardiotoxicity. *Herz*, 36 (4): 296-305.
- Simunek, T.;** Stirba, M.; Popelova, O.; Adamcova, M.; Hrdina, R. and Gersl, V. (2009). Anthracycline-induced cardiotoxicity: Overview of studies examining the roles of oxidative stress and free cellular iron. *Pharmacological Reports*, 61 (1): 154-171.
- Singal, P.K.** and Iliskovic, N. (1998). DOX-induced cardiomyopathy. *The New England Journal of Medicine*, 339: 900–905.
- Singletary K,** MacDonald C, Wallig M. (1996). Inhibition by rosemary and carnosol of 7, 12 dimethylbenz [a] anthracene (DMBA)-induced rat mammary tumorigenesis and in vivo DMBA-DNA adduct formation. *Cancer Lett.*; 104: 43-48.
- Smith, L.A.;** Cornelius, V.R.; Plummer, C.J.; Levitt,G.; Verrill, M.; Canney, P. and Jones, A. (2010): Cardiotoxicity of anthracycline agents for the treatment of cancer: systematic review and meta-analysis of randomised controlled trials. *BMC Cancer*; 10:337.
- Sparreboom, A.;** Nooter, K. and Verweij, J. (2002). Mechanisms of Action of Antitumour Antibiotics. Rotterdam Cancer Institute, Netherlands. pp. 4.
- Takemura, G. and Fujiwara, H. (2007).** DOX-induced cardiomyopathy from the cardiotoxic mechanisms to management. *Prog Cardiovasc Dis*, 49: 330-352.

- Wang, W.;** Wu, N.; Zu, Y.G.; Fu, Y.J. (2008). Antioxidant activity of *Rosmarinus officinalis* L. essential oil compared to its main components. *Food Chem.* 108, 1019-1022.
- Wojtacki, J.;** Lewicka-Nowack, E. and Lesniewski-Kmak, K. (2000): Anthracycline-induced cardiotoxicity: clinical course, risk factors, pathogenesis, detection and prevention - review of the Literature. *Med Sci* ;6:411-420.
- Xu, X.;** Persson, H.L. and Richardson, D.R. (2005). Molecular pharmacology of the interaction of anthracyclines with iron. *Mol. Pharmacol.*, 68: 261-271.