

Effect of long term Administration of hydrocortisone on some organs in females rats

Rana Talib Al-Muswie

College of Dentistry, Thi-Qar University, Iraq

Email: ranaalmuswie@yahoo.com

Abstract

Exposure of glucocorticoids leads to numerous changes in various biological and histological. Our results were observed, no morphological damage was observed in liver of the rats in the control group. In the animals that treated with low dose of HC there were moderate changes in the hepatocytes, while in the animals that treated with high dose of HC vacuolation of hepatocytes (V) with congestion of central and sinusoids. The changes in the kidney section, the control group was within the normal histological limits. there were minimum dilatation and congestion of glomeruli was found in low dose, But that were treated with high dose of hydrocortisone sodium succinate, Increased Numbers of Nuclei, glomerular degeneration of some glomeruli and revealed dilatation of renal cortical tubules. Also in the section of spleen in the control group as white pulp was within normal limits, but there were minimum atrophy of white pulp lymphoid tissue in the low dose animals, and there was severe atrophy of white pulp lymphoid tissue of animals that were treated with high dose group compared with control group.

The histology investigation of the lung sections had shown there were some changes in tissues such as, in case of the low dose at two month of treatment showed thickening to the wall alveoli, congestion in blood vessel. We showed infiltration of inflammatory cells in the inter alveolar septa, congestion in the capillaries, sloughing in the epithelium of some bronchioles, thickening to the wall alveoli and emphysema in the animals that treated with high dose of HC compare with normal rat lung, showing normal structure such as normal alveoli and normal bronchiole. In the present study we found the prolonged used of hydrocortisone sodium succinate side effect and events histochane in some of organs. As a conclusion for this study, use of hydrocortisone for prolong deu to a lots of histopathology changes in Liver, kidney, spleen, lung.

Keywords: Hydrocortisone, (*Rattus norvegicus*), liver, kidney, spleen, lung

Introduction

Corticosteroids essential for many therapies and treatments, an imbalance from stress or long periods use in clinical applications may have overreaching or unintended consequences. Indeed, glucocorticoids are also active inducers of apoptosis in many cell types.(Lu and Cidlowski 2004). Corticosteroids is produced by the adrenal cortex, and are divided into natural and synthetic cortical steroids, hydrocortisone sodium succinate (cortisol) is predominant natural gluco corticoid in human(Gray and David., 1998) glucocorticoids - such as cortisol (hydrocortisone) in humans and corticosterone in rats are synthesized within the mid-zone of the adrenal cortex, the zona fasciculata, in response to adrenocorticotrophic hormone (ACTH) secretion from the anterior pituitary gland (Baxter and Rousseau, 1979). The half life of cortisol is about 60-90 minute (Katzung, 2001).

Cortisol is lipid soluble, therefore, it can easily spread through the cell membrane. Cortisol, as other steroid hormones, exerts its in target cells by first interacting with intracellular receptors. Once inside the cell, cortisol binds with its protein receptor in the cytoplasm, and the hormone-receptor complex then interacts with specific regulatory DNA sequences, called glucocorticoid response elements, to induce or repress gene transcription (Guyton and Hall, 2006). Hydrocortisone sodium succinate is a nearly white or white , odorless, hygroscopic amorphous solid. It is very soluble in alcohol and in water, (Pharmacia and Upjohn Company Division of Pfizer, 2010).Complications of treatment with corticosteroids are dependent on the time of treatment and the size of the dose. Long-term corticosteroid use has several severe side effects, for example: diabetes mellitus, insulin resistance, hyperglycemia, gastritis, anxiety, depression, osteoporosis, colitis, hypertension, ictus, erectile dysfunction, hypogonadism, hypothyroidism, retinopathy and amenorrhea (Gharbia, 2010).

Histomorphological changes (histological abnormalities) in the periodontal ligament P.d.L. of developing tissue that treated by cortisone have been described by many authors (Glickman *et al.*, 1953; Ayer *et al.*,1986). The aim of the present work was to find out whether hydrocortisone sodium succinate treatment of adult female rats would influence the histological,. However, this study was done to know the effect of hydrocortisone sodium succinate on histological change in some organs of rats.

Materials and Methods

Experimental Animals

Eighteen of female rats (*Rattus norvegicus*) were used in the present study. Rats supplied from the animal house of Biology department, Science collage, Thi-Qar university, Iraq with weights ranging from 200 to 250 g. We used Hydrocortisone sodium succinate (100mg) supplied in rubber-capped vials, each was dissolved in 2ml of sterile distilled water and were administered by intra-peritoneal injection for two months an alternate day injection (EL-fouhil and Turkall, 1993) according to the determinate doses of each group. Animals were divided into three groups (6 for each group). The first group (A) was a control treated with normal saline for two months, the second group (B) was treated with low dose (25 mg/kg/day) of hydrocortisone sodium succinate for two months. The third group (C) treated with high dose (50 mg/kg/day) of hydrocortisone sodium succinate for two months. At the end of the experiment the animals were anesthetized with chloroform, (Liver, Kidney, Spleen and Lungs were excised then fixed in buffered neutral formalin for 48 hours. Following the fixation procedure the tissues were dehydrated in ascending series of ethanol, cleared in xylene and embedded in paraffin wax, (5-6) μ m thick sections were obtained by a rotary microtome. These sections were stained with Harris hematoxylin and eosin (Fischer *et al.*, 2008).

Results

Histological Changes

The investigation of liver sections in the control group showed no morphological damage (figure 1), there were some histopathological changes had been shown in treated rats with low dose of hydrocortisone sodium succinate such as moderate changes in the hepatocytes (Fig. 2), while there were vacuolation of hepatocytes (V) with congestion of central and sinusoids in the animals that treated with high dose of hydrocortisone (Fig. 3). The microscopic investigation of kidney in control group have normal histological limits, like glomeruli and cortical tubules (Fig. 4). But, there were

minimum dilatation and congestion of glomeruli was found in low dose animals which treated with low dose of hydrocortisone sodium succinate (Fig. 5). While, rats were treated with high dose of hydrocortisone sodium succinate, increased numbers of Nuclei, glomerular tuft degeneration of some glomeruli and revealed dilatation of renal cortical tubules (Fig. 6). Also in the section of spleen in the control group as white pulp was within normal limits (Fig. 7), but there were minimum atrophy of white pulp lymphoid tissue in the low dose animals (Fig. 8), and there was severe atrophy of white pulp lymphoid tissue of animals that were treated with hydrocortisone sodium succinate of high dose group (Fig. 9) compared with control group.

The microscopic examination of lung section from normal rat lung showing normal structure such as normal alveoli and normal bronchiole (Fig. 10), while in case of the low dose at two months of treatment (Fig. 11) showed thickening to the wall alveoli, congestion in blood vessel. But in (Fig. 12) we showed infiltration of inflammatory cells in the inter alveolar septa, congestion in the capillaries, sloughing in the epithelium of some bronchioles, thickening to the wall alveoli and emphysema in the animals that treated with high dose of hydrocortisone.

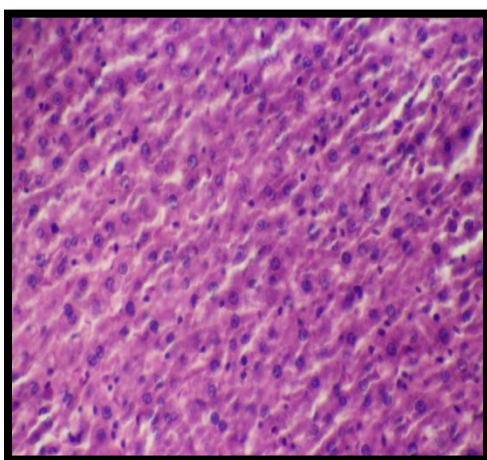


Fig 1:(Haematoxylin and Eosin stain, 100×): Control group .Liver was healthy and within normal limits Sinusoids ,Hepatocytes

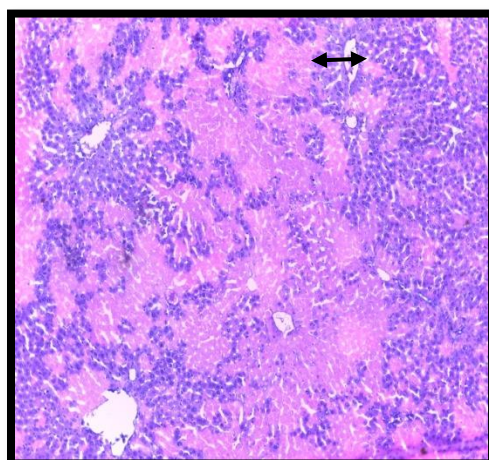


Fig.2:(Haematoxylin and Eosin stain, 200×): liver treated with 25 mg/kg/day for 2 month showing vacuolation of hepatocytes with congestion of central vein and sinusoids

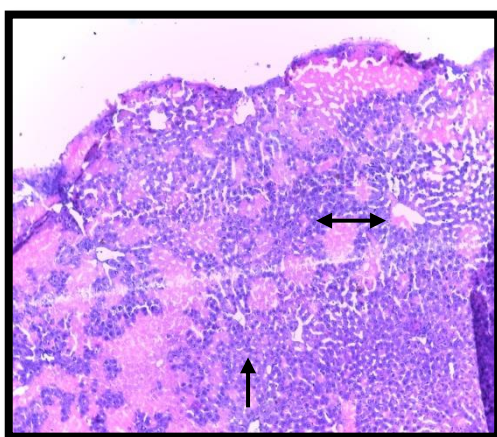


Fig.3:(Haematoxylin and Eosin stain, 200×): liver treated with 50 mg/kg/day for 2 month showing vacuolation of hepatocytes with congestion of central vein ↔ and sinusoids →

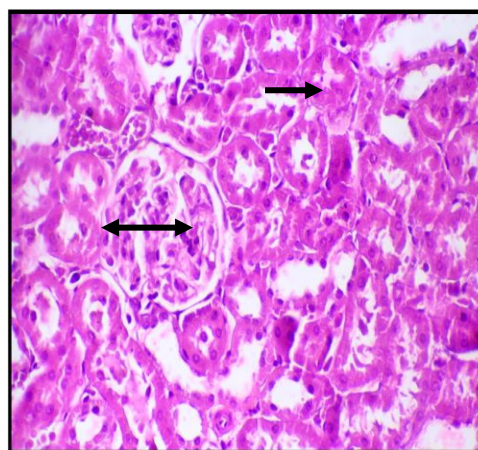


Fig.4:(Haematoxylin and Eosin stain, 800×): Control group .kidney was healthy and within normal limits glomeruli ↔ and cortical →

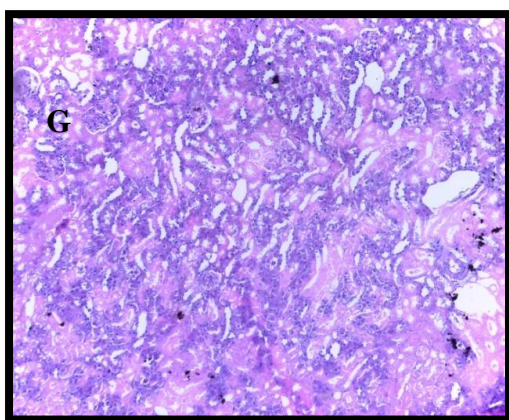


Fig. 5: (Haematoxylin and Eosin stain, 200×): kidney, treated with 25 mg/kg/day for two month showing dilatation of renal cortical T tubules and glomerular congestion G.

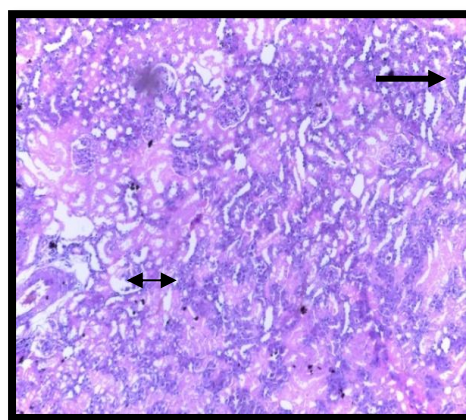


Fig .6: (Haematoxylin and Eosin stain, 200×): kidney, treated with 50 mg/kg/day for two month showing dilatation of renal cortical T. N= Increased Numbers of Nuclei, → glomerular tuft degeneration (GD). ↔

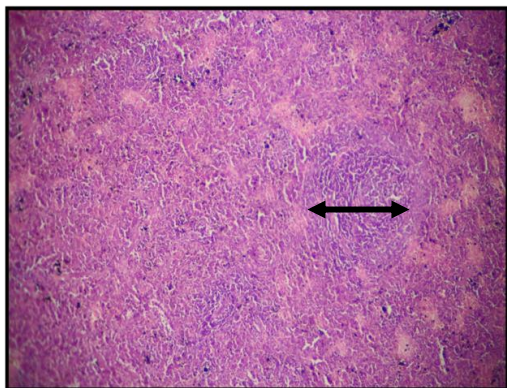


Fig. 7: (Haematoxylin and Eosin stain, 100×): Section in spleen tissue belongs to control rat showed normal white pulp and normal red pulp ↔

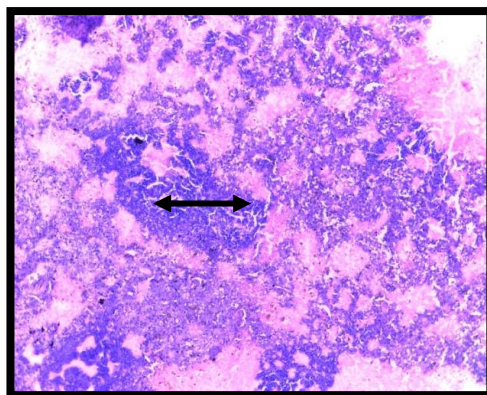


Fig. 8 : (Haematoxylin and Eosin stain, 800×): Section in spleen tissue belongs to rat treated with 25 mg/kg/day for two month showed there is severe atrophy of white pulp lymphoid tissue ↔

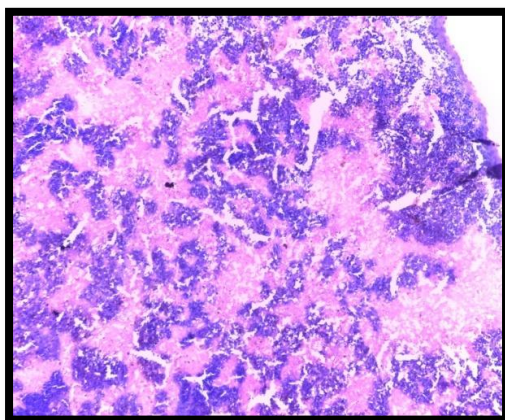


Fig. 9 :(Haematoxylin and Eosin stain, 200×): Section in spleen tissue belongs to rat treated with 50 mg/kg/day for two month showed severe atrophy of white pulp lymphoid tissue

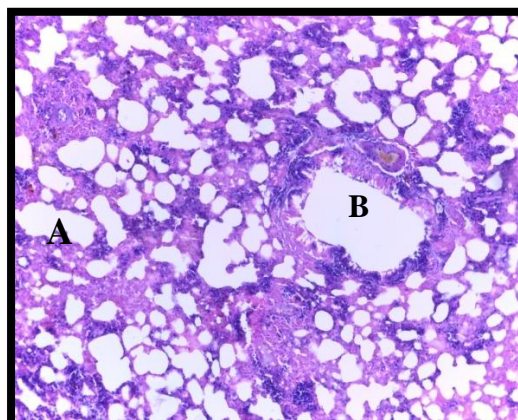


Fig. 10: (Haematoxylin and Eosin stain, 200×): Section in Lung tissue belongs to control rat showed normal limits ,showing alveoli (A) and bronchiole (B).

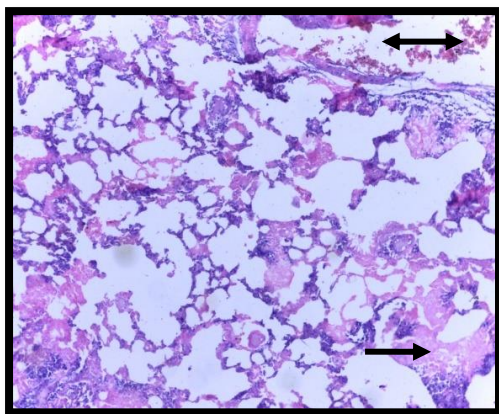


Fig. 11: (Haematoxylin and Eosin stain, 200×): Section in Lung tissue belongs to rat treated with 25 mg/kg/day for two month showed thickening of the wall of alveoli , → and congestion in blood vessel ↔

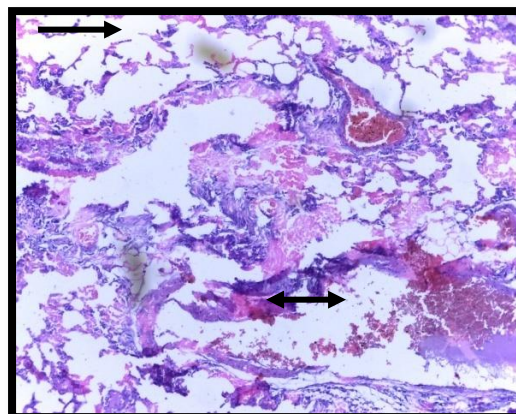


Fig. 12: (Haematoxylin and Eosin stain, 200×): Section in Lung tissue belongs to rat treated with 50 mg/kg/day for two month showed, congestion in blood vessel ↔ and emphysema →

Dissection

The result of this study have been shown that the hydrocortisone sodium succinate treatment of female rats caused histochanges in some organs such as (Liver, Kidney, Spleen and Lungs). Cortisone increases the transport of fatty acids to the cells and their use as a source of energy, an increased use of fatty acids in place of glucose for the production of energy is a characteristic feature of the activity of the hormone (Gardner and Zhang 1999, Ridges *et al.* 2001). As cortisone is a hormone of a long-lasting stress response. one of the most active glucocorticoids, had the greatest effect on the adipose tissue these are some reason to change the tissue of liver .The present work agreement with the results obtained in studies on mice by Sukhova and Ukhina (2004) and Berg *et al.* (2006) as well as by LeBlanc and Ducharme (2005) on humans, these experiments demonstrate that glucocorticoids increase fatty acid release and reduce the uptake and utilization of glucose in incubated adipose tissue from normal female rats .

In the present study there was severe atrophy of white pulp lymphoid tissue of spleen in high dose groups animals. Corticosteroid administration

has long been known, to cause demolition of lymphoid tissues in certain adult animal species, including mice and rats, some clarified this due to the lytic effect of hydrocortisone apparent in small lymphocytes agreement with research in rats to EL-fouhil and Turkall, (1995). Treatment of mice with hydrocortisone decreased the number of thymus-cells to 6 per cent and the number of spleen-cells to 32 per cent of matched controls. Per spleen, an absolute reduce of cells carrying immunoglobulin receptors on the surface as determined by immunofluorescence was found and a smaller in cells reduce with theta-antigen (Vischer, 1972). El-fouhil and Turkall, (1993) reported in the study of hydrocortisone appeared to decrease the metabolic and secretory activities of medium-sized lymphocytes and to compresses protein synthesis, which is consistent with the resultant decrease in IgM production.

In the present study there was dilatation of renal cortical tubules especially in high dose group animals, Beauchamp and pettigrew (1988) deduced that hydrocortisone intervene with the postnecrotic cellular rerestored process, an important step that responsible for the recovery of normal kidney structure and function following toxic injuries associated with aminoglycoside therapy.

Also found Chan *et al.*, that hydrocortisone caused upregulated transcripts encoding Na- K--ATPase subunits and ligands for the epidermal growth factor receptor, all previously implicated in renal cyst growth (Chan *et al.*, 2009). A long usage hydrocortisone administration in doses overrides physiological ones leads to hyperglycaemia and adrenogenous diabetes because it reduces the use of glucose by cells, Its transport through cellular membranes, and contributes to the decrease of glycolysis in peripheral tissue (Hammarqvist *et al.*,2001; Kasavina *et al.*,1979).The most important finding in this study was thickening of the wall of alveoli, congestion in blood vessel, and emphysema .Hydrocortisone induced apoptosis in airway epithelium, which could share to persistent asthma epithelium damage (Dorscheid *et al .*,2001).. In our study we found the long usage of hydrocortisone events side effect in lung such as congestion in blood vessel and emphysema .Therefore ,present report found the used of hydrocortisone to prolonged caused a side effect and histochange in some organs such liver, kidney ,spleen and lung.

References

- Ayer William, Kusek Judith C, and Steubaer Elaine A. (1968)** .Effects of cortisone preparations on human teeth. J Dent Res; 18.
- Baxter, J. D. and Rousseau, R. G. (1979).** Cited by Porter, R. M. (2002). Examination of Glucocorticoid Treatment on Bone Marrow Stroma Implications for Bone Disease and Applied Bone Regeneration. Virginia Polytechnic Institute, State University. P: 1.
- Beauchamp, D. and Pettigrew, M. (1988).** Influence of Hydrocortisone on Gentamicin-Induced Nephrotoxicity in Rats. Antimicrobial agents and chemotherapy; Pp: 992-996.
- Berg al., rafnsson at., johannsson m., dallongeville j., arnadottir m., (2006)**– The effects of adrenocorticotrophic hormone and an equivalent dose of cortisol on the serum concentrations of lipids, lipoproteins, and apolipoproteins. Metabolism 55, 1083-1087.
- Chan. S. K.; Riley, P. R.; Price, K. L.; Mcelduff, F.; Winyard, P. J.; Welham, S. J. M.; Woolf, A. S. and Long, D. A. (2009).** Corticosteroid-induced kidney dysmorphogenesis is associated with deregulated expression of known cystogenic molecules, as well as indian hedgehog. Am. J. Physiol. Renal. Physiol. 298: 346-356.
- Dorscheid, D.R.; Wojcik, K.R.; Sun, S.; Marroquin, B.; White, S.R. (2001)** Apoptosis of airway epithelial cells induced by corticosteroids. Am. J. Respir. Crit. Care Med., 164, 1939–1947.
- EL-fouhil, A. F. I. and Turkall, R. M. (1993).** Effect of alternate- day hydrocortisone therapy on the immunologically immature rat. I-effect on blood cell count, immunoglobulin concentrations, and body and organ weight. Toxicol. Pathol. 21(4): 377-382.
- EL-fouhil, A. F. I. and Turkall, R. M. (1995).** Electron microscopic study on thee of alternate-day hydrocortisone therapy on lymphocyte populations in rat spleen and lymph nodes. J. Toxicol. Pathol. 23: 72
- Fischer A H et al. (2008)** . Hematoxylin and eosin staining of tissues and cell sections. Cold Spring Harb. Protoc10.
- Gardner J.P., ZHANG L., (1999)** .Glucocorticoidmodulation of Ca homeostasis in human B lymphoblasts. Journal of Physiology 514, 385-396.

Gharbia, S. A. (2010). How do corticosteroids affect the heart and liver? Health Questions Corticosteroids. About Every dayHealth.com

Glickman Irving, Stone Irving and Chawila T et al, (1998) The effect of systemic administration of cortisone on the periodontal white mouse J Periodont 1953; 24-161.

Gray CR, David SL. (1998). Pharmacology Board Review series 3rd edition: Williams and Wilkins. Baltimore Maryland. 21: 201- 436.

Guyton, A. C. and Hall, J. E. (2006). Text book of Medical physiology. 11^{ed}. Elsevier, Philadelphia, USA. Pp: 944-955.

Hammarqvist F, Ejesson B, Wernerman J. (2001) Stress hormones initiate prolonged changes in the muscle amino acid pattern. Clin physiol; 21:44-50

Kasavina BS, Torbenko VP, Ukhina TV. (1977). Responses of different types of connective tissue to hormone administration. Biull Eksp Biol Med; 84:38-41

LE blanc j., ducharme m.b., (2005) .Influence of personality traits on plasma levels of cortisol and cholesterol. Physiology and Behavior 13, 677-680.

Lu, N.Z.; Cidlowski, J.A. (2004). The origin and functions of multiple human glucocorticoid receptor isoforms. Ann. NY Acad. Sci., 1024, 102-123.

pharmacia and Upjohn company. Division of Pfizer Inc. (2010), Ny, Ny 10017. LAB- 042-3.0. Plat, L.; Byrne, M. M.; Sturis, J.; Polonsky, K. S.; Mockel, J.; Fery, F. and Van Cauter, E. (1996). Effects of morning cortisol elevation on insulin secretion and glucose regulation in humans. American Journal of Physiology, 270: 36-42.

Ridges l., sunderland r., moerman k., meyer b., astheimer l., howe p., (2001)– Cholesterol lowering benefits of soy and linseed enriched foods. Asia and Pacific Journal of Clinical Nutrition 10, 204-211.

Sukhova t.a., ukhina t.v., (1986) . Effect of hydrocortisone on lipid metabolism in hepatocyte plasma membranes. Experimental Biology and Medicine 102, 436-437.

Vischer, T. L. (1972). Effect of hydrocortisone on the reactivity of thymus and spleen cells of mice to in vitro stimulation. J. Immunology, 23(5): 777-784.

تأثير الإعطاء طويل الأمد للهيدروكورتيزون على بعض الأعضاء في إناث الجرذان المختبرية

رنا طالب الموسوي

كلية طب الأسنان /جامعة ذي قار/العراق

الخلاصة

استخدام الهيدروكورتيزون لفترة طويلة يقود إلى العديد من التغيرات البيولوجية والنسجية. لذلك كان الهدف من هذه الدراسة أيجاد التأثيرات النسيجية بعد معاملة الحيوانات المختبرية في علاج الهيدروكورتيزون صوديوم سوكسينيت. في الدراسة الحالية ليس هنالك أي تغيرات نسيجية في مجموعة السيطرة. بينما وجد تغيرات في المجاميع المعاملة حيث وجد في مجموعة الحقن 25 ملغم/كغم تغيرات طفيفة لأنسجة الكبد بينما وجد احتقان في الوريد المركزي كذلك ترشح للخلايا الالتهابية وتفجى للخلايا الكبدية لمجموعة التي حقنت 50 ملغم. أما بالنسبة لنسيج الكلية وجد في المجموعة الثانية احتقان طفيف في الكبيبة بينما في المجموعة الثالثة ازدياد عدد الانوية وتحلل الكبيبة وتوسع في النبيبات الكلوية. كذلك وجد في المجموعة الثانية للطحال بعض الضمور للخلايا للمفاوية لللب الأبيض وفي المجموعة الثالثة ازدياد مرحلة الضمور. ولوحظ في المقاطع النسيجية للرئة في المجموعة الثانية حدوث تسمك لخلايا الغرف الهوائية وفي المجموعة الرابعة احتقان في القصبة الهوائية وارتشاح الخلايا الالتهابية واحتقان الشعيرات الدموية وحدث تمدد وانتفاخ للغرف الهوائية في الحيوانات التي حقنت 50 ملغم من الهيدروكورتيزون.

وبينت الدراسة الحالية إن الاستخدام السيئ للهيدروكورتيزون أو استخدامه لفترة طويلة يؤدي إلى حدوث ضرر وتأثيرات جانبية على بعض الأنسجة حيث يمكن الاستنتاج من ان الاستخدام الطويل للهيدروكورتيزون يؤدي إلى تغيرات نسيجية مرضية في الكبد , الكلية , الطحال والرئة.