

Spontaneous Rupture of Exogastric Hemangioma: Case Report

Khairallah M. Al-Rubaiee - Wassit University- Dept. of surgery Medical College

الانفجار التلقائي لورم وعائي في ظاهر المعدة :حالة نادرة

خيرالله مزهر الربيعي - زميل الكلية الملكية للجراحين

الخلاصة

تعرف الاورام الوعائية الحميدة بانها اورام ذات طبيعة وراثية تشمل الاوعية الدموية الكبيرة والشعرية. وهي من الندرة بمكان حيث لا تتجاوز نسبتها 0.05% فقط من جميع اورام القناة الهضمية. اما الاورام الوعائية الخاصة بالمعدة فهي نادرة جدا حيث لا تتجاوز مجموع ماوثق منها ٤٥ حالة مرضية منذ وصفها عام ١٨٦٠م اما التي وردت بشكل ورم وعائي منفجر تلقائيا فنحن بصدد توثيق الحالة الثانية في العالم -على حد علمنا- لرجل يبلغ الحادية والاربعين من العمر اتاد شعبة الطوارئ في مستشفى الكرامة-الكوت- شاكيا من الم البطن الحاد. حيث تم فحصه واسعافه ثم اجريت له عملية استكشاف البطن واستئصال الورم الوعائي الذي تم اثباته بالفحص النسيجي المبين ادناه.

Abstract

Hemangiomas are benign congenital tumors of mature blood vessels and usually consist of dense masses of capillaries or larger blood vessels. Hemangiomas of the gastrointestinal tract are uncommon and account for only 0.05% of all intestinal neoplasms; gastric hemangiomas constitute less than 2% of benign gastric neoplasms.

1 Gascoyen first described gastric hemangioma in 1860, and only 45 cases have been reported.1-5 Hemangioma of the stomach presenting with spontaneous rupture is rare. We describe a 41-year-old male who had rupture of abdominal hemangioma and subsequent hemoperitoneum. presented to the emergency unit of

our hospital Al-Karama general hospital Al-Kut city with acute abdominal pain and distention where he was examined resuscitated, investigated , and explored for profuse hemoperitoneum and an exogastric ruptured mass were resected and submitted for histopathological examination. Which confirmed the diagnosis of hemangioma.

Keywords: Hemangioma, spontaneous rupture, Exogastric.

Introduction

Hemangiomas are benign congenital tumors of mature blood vessels and usually consist of dense masses of capillaries or larger blood vessels. Hemangiomas of the gastrointestinal tract are uncommon and account for only 0.05% of all intestinal neoplasms; gastric hemangiomas constitute less than 2% of benign gastric neoplasms.

1 Gascoyen first described gastric hemangioma in 1860, and only 45 cases have been reported.^{1–5} Hemangioma of the stomach presenting with spontaneous rupture and sepsis is rare. We describe a 41-year-old male who had rupture of abdominal hemangioma and subsequent hemoperitoneum.

Case presentation:

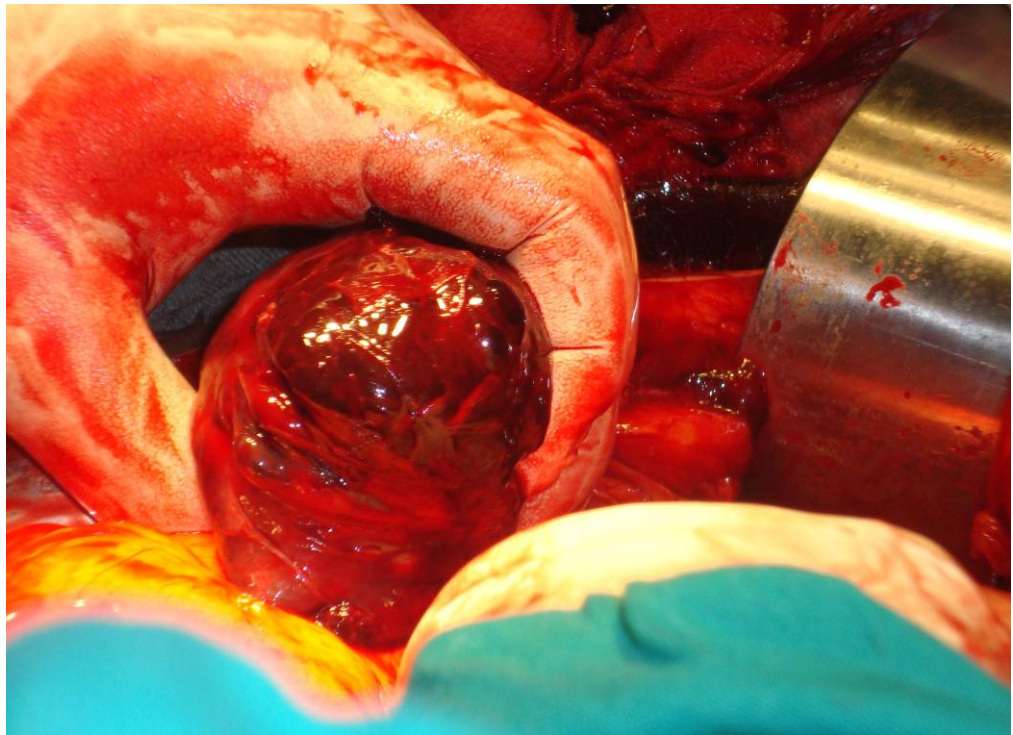
A 41year old Iraqi male driver presented to the Emergency unit with sudden -onset severe generalized abdominal pain, started just after having a meal after a long journey associated with abdominal distention, the pain increased in severity with the time ,aggravated by lying flat and relieved by leaning forward . radiating to both shoulders, associated with nausea and vomiting. the patient had no history of trauma,he had chronic history of dyspepsia relieved by intake of some antacid . there was no past history of hematemesis or malena. clinical examination of the patient revealed that he was conscious, tachypnoic , pale, puls rate was 98/min, blood pressure was 95/60mmHg.Abdomen was diffusely distended,tender allover ,there was one pigmented spot in the left submandibular region,of about 1x1.5cm.propably indicate a site of faded vascular lesion. Resuscitation was done and the patient sent for Abdominal sonography after stabilization which revealed a huge amount of fluid in the pelvic cavity.Chest –x-ray and plain x- -ray of abdomen

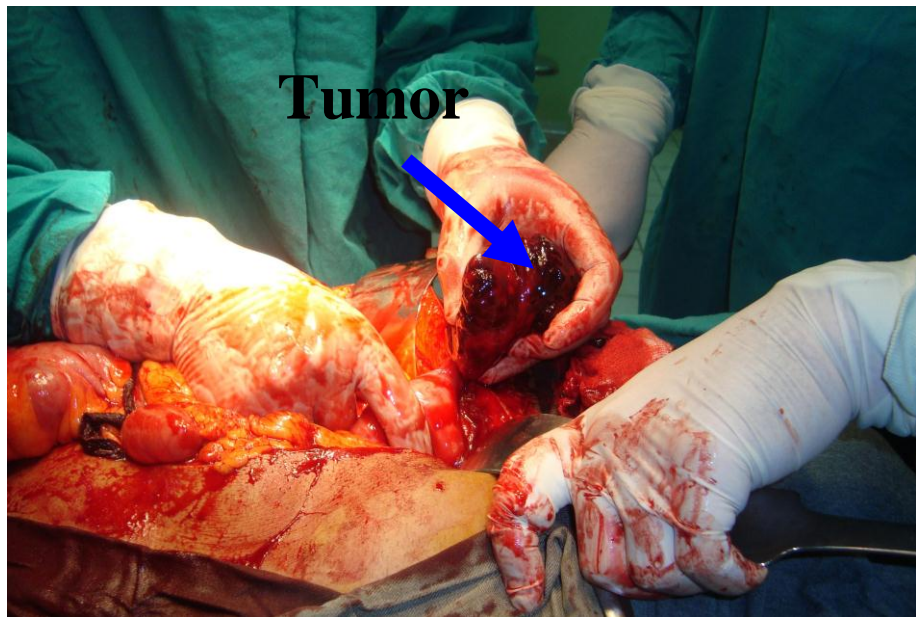
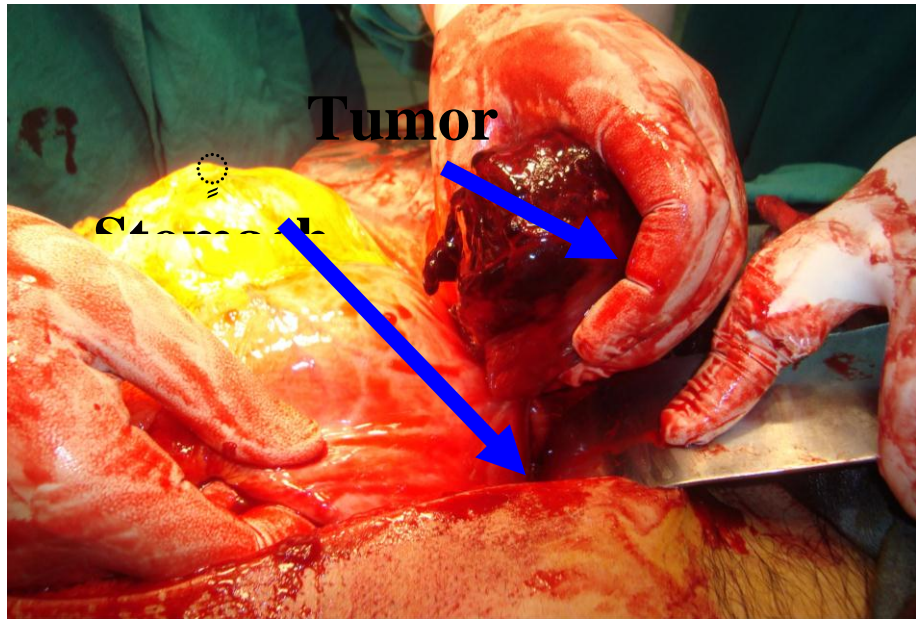
,in erect position revealed non specific findings.heamtological investigation showed that Hb.% was10.8% WBC. Count was13.200/cmm. Platelete was265000/cmm.Explorative laparotomy under general anesthesia was performed thinking of two main differential diagnosis

1.Perforated peptic ulcer

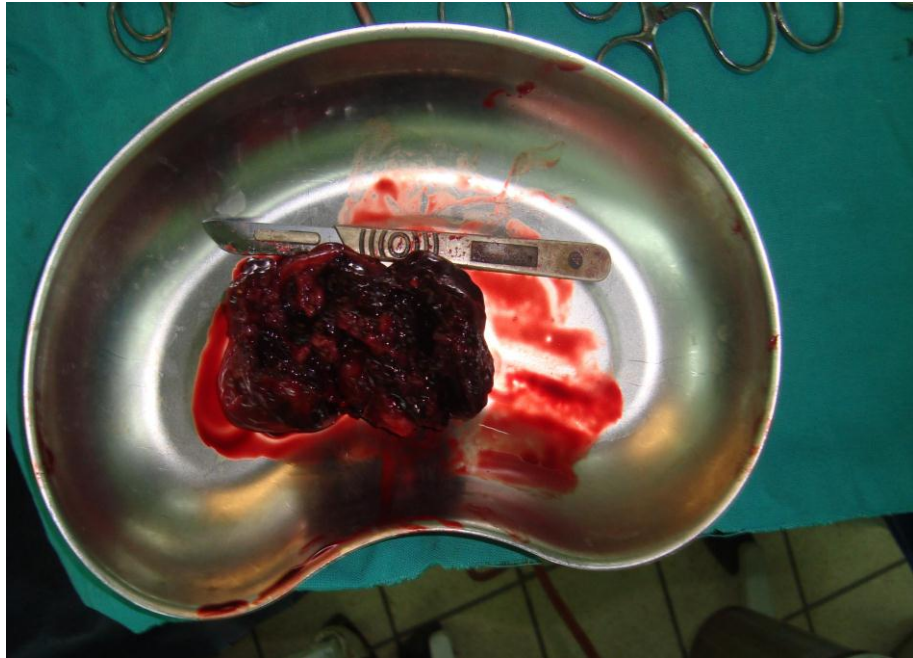2.Acute pancreatitis., and the peritoneal cavity was found to be flooded with blood ,Aspiration of about 1150CC.s of blood and evacuation of clots (equal to about two closed fists) and control of the bleeding source was done by clamping of the pedicle of a ruptured mass measuring about 12x9x7cm. the mass was dark brown highly vascular pedunculated with its stalk attached to the greater curvature of stomach, the mass proper was friable.

encapsulated with rupture of the anterior aspect of mass showing dilated blood vessels and multiple clots studding the ruptured surface. As shown in photograph{1(A,B,C,D,E)}.



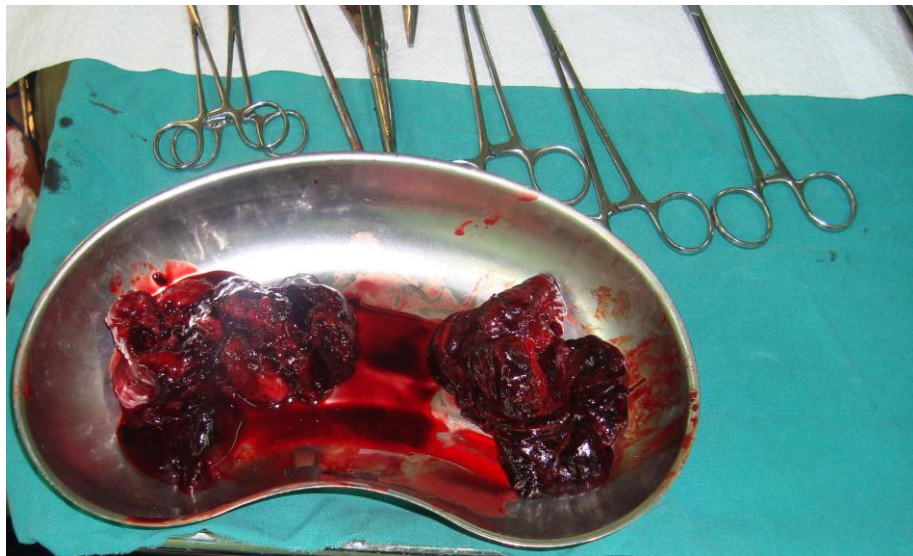


Intraoperative view



D

The resected tumor

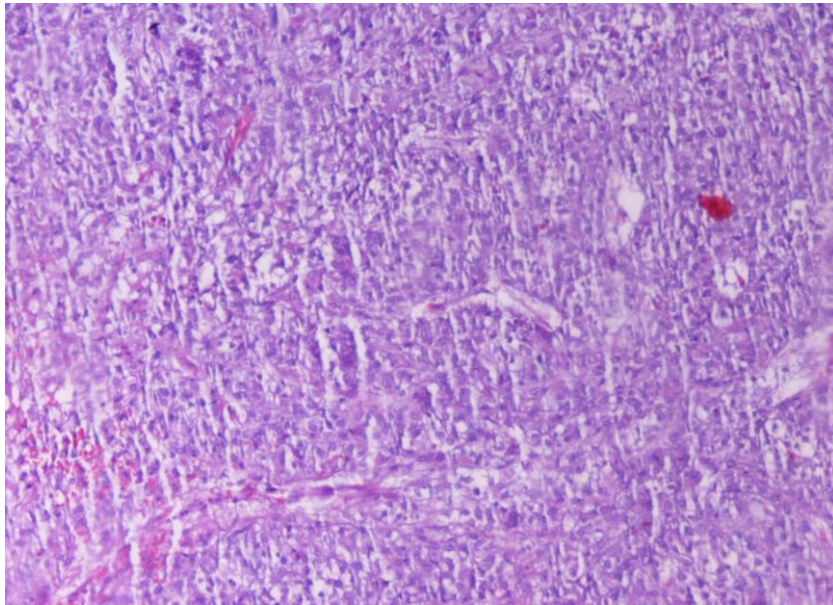


E

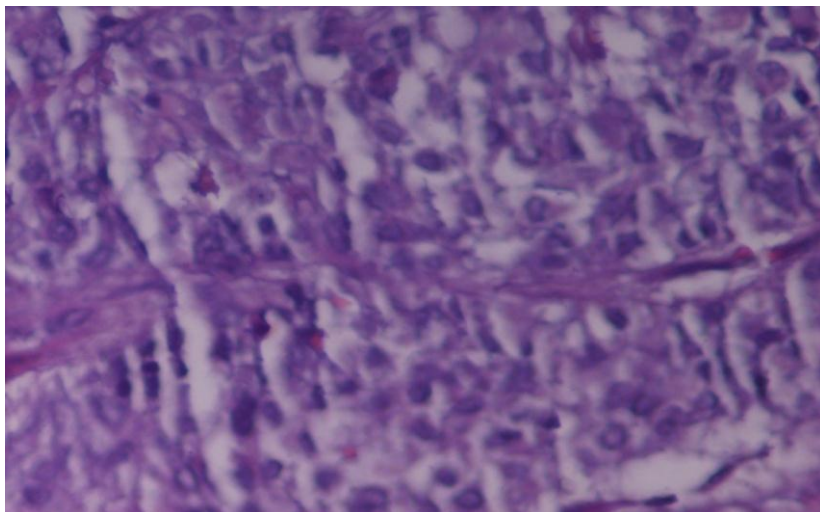
The tumor and its ruptured pieces

Resection of the mass was done .careful e examination of other abdominal viscera for any concomitant vascular lesion, showed normal looking, peritoneal irrigation with saline ,drain tube was left inside the peritoneal cavity and closure. The patient run uneventful post operative

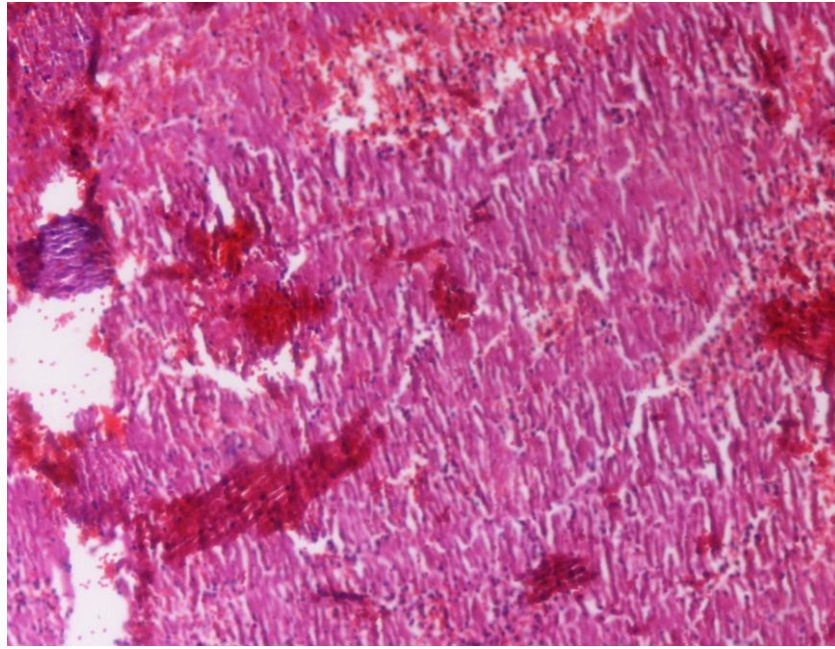
period and he was discharged home in the 6th.postoperative day. Histopathological examination of the specimen revealed that the section showed vascular proliferation with hemorrhage and dilated vascular spaces with plumpy endothelial cells growing in small cords and tubules with vesicular nuclei and cytoplasm contain occasional vacuoles, with areas shows extensive necrosis concluding that the picture goes with histiocytoid hemangioendothelioma.as shown in figure{2(A,B,C)}



A



B



C

Discussion:

Hemangioma of the gastrointestinal tract are rare and account for only 0.05% of all intestinal neoplasms; gastric hemangiomas constitute less than 2% of benign gastric neoplasms, and only 45 cases reported thus far. [1-5]. Abrahamson and Shandling divides intestinal hemangioma into three categories, on the basis of histological appearance: capillary, cavernous and mixed type [6]. The most common type is the cavernous hemangioma [6,7]. Gastrointestinal hemangiomas arise from the submucosal vascular plexuses and may invade the muscularis layer. There is rarely penetration beyond the serosa [10]. Gastrointestinal hemangiomas have been reported in patients ranging from 2 months to 79 years of age. No obvious sex predominance has been identified. They usually present in young men and women, often in the third decade of life [1-3].

The symptoms of hemangioma depend on the localization of the primary tumor. Eighty percent of patients with gastrointestinal hemangiomas present with symptoms such as bleeding or obstruction [7,8]. The major symptom of gastrointestinal hemangiomas is bleeding [7]. Whereas bleeding from capillary type lesions tends to be slow or

may be occult, the hemorrhage in association with a cavernous hemangioma is usually of sudden onset and may present as either hematemesis or melena [7,8]. Hemangiomas may result in hemoperitoneum or intestinal obstruction due to the intussusception of the polypoid tumor. Whereas abdominal pain may become the major complaint in these patients, nausea, vomiting, and abdominal distention may also be found [8-11]. The type of treatment depends on the type of lesions, location, extent of involvement, extent of symptoms, and general operability [10,11].

Gastrointestinal hemangiomas of well-defined segment of intestine are usually suitable for surgical resection at the time of diagnosis [10,11]. Recurrences after resection are rare [10].

Gastric hemangiomas are rare. Tumors should be differentiated from exophytic gastric leiomyoma, leiomyoblastoma, leiomyosarcoma or, rarely,

neurilemmoma.6 Gastric hemangiomas are usually intragastric, but our patient's hemangioma was exogastric. Wan et al reported an exophytic gastric hemangioma with torsion and intratumoral hemorrhage.

6. This is the second report of a case of exogastric hemangioma presenting with spontaneous rupture and hemoperitoneum,. The classic treatment for intraperitoneal hemangioma is surgical resection, but transarterial embolization is helpful for treating ruptured hemangioma with

an arterial supply. Bamanikar et al described the use of left gastric arterial embolization to treat a 36-year-old woman with gastric hemangioma.1

Surgical resection appeared to be the best option for our patient because of the large size of the hemangioma and because it was complicated by central necrosis, rupture, and peritonitis. In our opinion, a large gastric hemangioma may compress the stomach and surrounding organs. As these tumors may also have an increased risk of spontaneous rupture, a potentially fatal complication, surgical removal is the treatment of choice.

References

1. Bamanikar AA, Diwan AG, Benoj D. Gastric hemangioma. An unusual cause of upper gastrointestinal bleed. *Indian J Gastroenterol* 2004;23:113–4.
2. Bellantone R, Lombardi CP, Rubino F, et al. Spontaneous gastric rupture and hemoperitoneum due to gastric hemangioma. *Dig Dis Sci* 2001;46:852–3.
3. Schlecht I, Hierholzer J, Maurer J, et al. Gastric hemangioma: a rare cause of gastrointestinal bleeding. *Pediatr Radiol* 1999;29:63.
4. Medina V, Alarco A, Martin A, et al. Gastric cavernous hemangioma as a cause of upper digestive hemorrhage. *Rev Esp Enferm Dig* 1995;87:323–6.
5. Nagaya M, Kato J, Niimi N, et al. Isolated cavernous hemangioma of the stomach in a neonate. *J Pediatr Surg* 1998;33:653–4.
6. Wan YL, Eng HL, Lee TY, et al. Computed tomography of an exophytic gastric hemangioma with torsion and intratumoral hemorrhage. *Clin Imaging* 1993;17:210–2.
7. Abrahamson J, Shandling B. Intestinal hemangiomata in childhood and a syndrome for diagnosis: a collective review. *J Pediatr Surg*. 1973;8:487–95. doi: 10.1016/0022-3468(73)90211-X. [[PubMed](#)]
8. Enzinger FM, Weiss SW. *Soft tissue tumors*. 3. St. Louis, Mo: Mosby-Yearbook; 1995. pp. 679–89.
9. Nader PR, Margolin F. Hemangioma causing gastrointestinal bleeding: Case report and review of literature. *Am J Dis Child*. 1967;111:215–22. [[PubMed](#)]
10. Ruiz AR, Ginsberg AL. Giant mesenteric hemangioma with small intestinal involvement: An unusual cause of recurrent gastrointestinal bleeding and review of gastrointestinal hemangiomas. *Dig Dis Sci*. 1999;12:2545–51. doi: 10.1023/A:1026659710815. [[PubMed](#)]
11. Corsi A, Ingegnoli A, Abelli P, De Chiara F, Mancini C, Cavestro GM, Fanigliulo L, Di Mario F, Franzi A, Zompatori M. Imaging of a small bowel cavernous hemangioma: Report of a case with emphasis on the use of computed tomography and enteroclysis. *Acta Biomed*. 2007;78:139–143. [[PubMed](#)]

Received (7/7/2009)

Accepted (29/9 /2009)

