

Glossitis in wild Canadian goose A Case report

Saleh,K.Majeed ; Zuhair,H.Oudh ; Samira,A.DaaJe

التهاب اللسان في الاوز الكندي تقرير حالة

صالح كاظم مجيد
كلية الطب البيطري/فرع الامراض
جامعة البصرة

زهير حبيب عودة
كلية الطب البيطري/فرع الامراض
جامعة البصرة

سميرة
كلية الطب البيطري/فرع التشريح
جامعة البصرة

الخلاصة

في هذا البحث نستعرض حالة واحدة من التهاب اللسان في الإوز الكندي الذي يتميز سريريا باللعب المفرط واللون الشاحب للسان. خضع اللسان لإجراء التشريح المرضي وبجميع أجزائه والتي أظهرت تغيرات مرضية مختلفة وجميع هذه التغيرات أشارت إلى التهاب اللسان وبدرجات مختلفة.

Abstract

This article present one case of Canadian goose glossitis which clinically characterized by excessive salivation and pale colored-tongue. Tongue was submitted for histopathology procedure to all parts of the tongue which show different pathological changes, all those changes gave indication to glossitis of variable severity.

Introduction

Glossitis is a condition refer to an inflammation of the tongue; it may be caused by injury, infection, allergy reaction. All these causes can be inducing glossitis with varying severity.

Morphologically, the tongue of Egyptian goose composed three parts (anterior, middle, and posterior). The anterior part represented one half of the tongue, while the two remaining parts comprise the other half (1). Histological structure of it revealed that the anterior part was covered externally by keratinized stratified squamous epithelial tissue , deep to it lamina propria with striated muscle cells and phagocytes with collagen fibers intermingled with skeletal muscle, under skeletal muscle the adventitia consists of adipose tissue. While the middle part consisted of stratified squamous epithelial tissue more cellular than anterior, the lamina propria consisted of skeletal muscle intermingled with few collagen fiber. The posterior parts consisted of stratified squamous epithelium but there was crypt formation. Lamina properia of posterior part contain thick skeletal muscle layer and more salivary glands. Also we find that the posterior part contain cartilage in between adipose tissue under lamina propria (2).

Glossitis could be caused by several causes; which can be illustrated down below:

- ❖ Bacterial or viral infections (including oral herpes simplex).
- ❖ Mechanical irritation or injury from burns, rough edges to teeth or due to appliances, or other trauma.
- ❖ Exposure to irritants such as tobacco, alcohol, hot food or spices.
- ❖ Allergic reaction to toothpaste, mouthwash.
- ❖ Disorders such as iron deficiency anemia, pernicious anemia, and other B-vitamin deficiencies, oral syphilis and others.
- ❖ Yeast infection.
- ❖ Dry mouth associated with connective tissue disorder, such as sjogren studies. Occasionally Glossitis can be inherited (3).

(4) reported symptomatic benign migratory glossitis in two cases associated with lingual ulceration affecting daily activity, eating, and sleeping. While (5) reported glossitis and tongue trauma subsequent to administration of an oral medication using an udder infusion cannula in a horse.

Case description

A wild Canadian goose was hunted and kept in cage for two weeks .during continuous observation, it was found to be suffering from excessive salivation, anorexia, and difficulty of eating with gradual body weight loss. Gross examination of the tongue appeared roughness palpation with pale-whitish coloration. While microscopic findings of it revealed glossitis with varying severity (mild, moderate, and severe glossitis).

The pathological changes of the posterior part of the tongue characterized by infiltration of heterophils and degenerated vacuolated epithelium (moderate glossitis) as seen in figures (4, 7, and 8), while in these figures (2 and 6) appeared heavy infiltration of heterophils and vacuolated/folded epithelium (severe glossitis).All these changes associated by inflammatory response and evidence of primary phases of tissue healing.

In middle and anterior parts of the tongue; the main features were proliferation of fibrocytes, collagen fiber formation, and thickened epithelium which indicate the proliferative and regeneration phases of tissue healing.

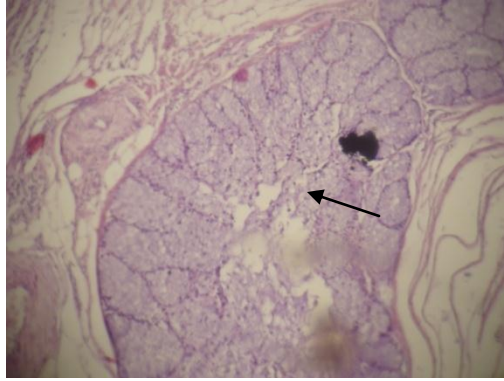


Fig (1): section of salivary gland with primary stage of glossitis characterized by edema at the base of lamina propria .(posterior part of the tongue).(H&E staining , 100X)

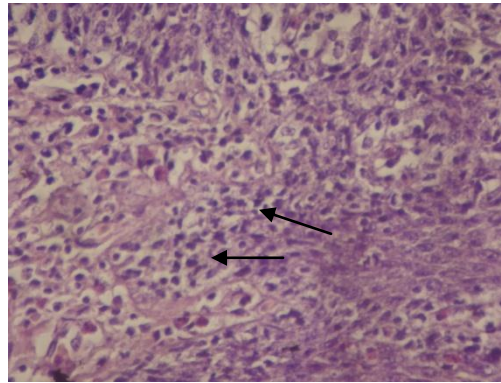


Fig (2): severe glossitis associated with infiltration of heterophils , vacuolation of stratified squamous epithelium . (Posterior part of the tongue). (H&E staining , 400X)

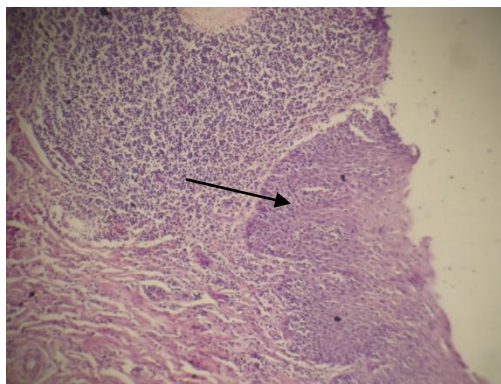


Fig (3): thickened stratified squamous epithelium (over twenty layers), note area of glossitis with heterophils .(posterior part of the tongue). (H&E staining , 100X)

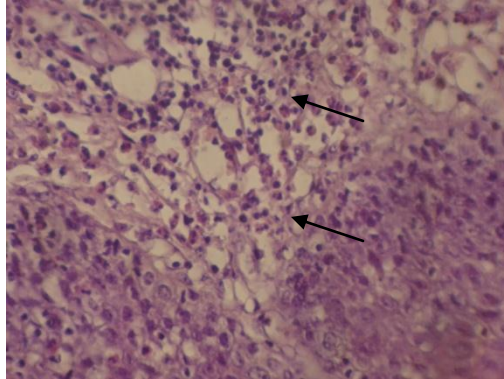


Fig (4): glossitis charaterized by heterophils infiltration associated with vacuolated stratified squamous epithelium .(posterior part of the tongue). (H&E staining, 400X)

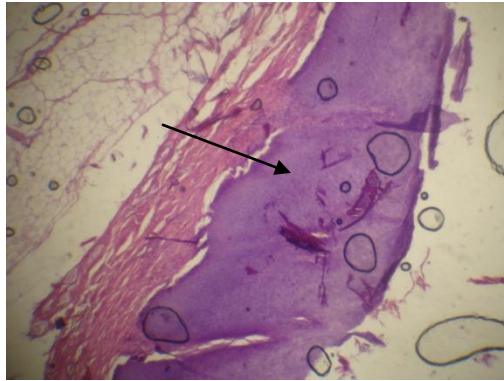


Fig (5): thickened stratified squamous epithelium (over fifteen layers) covered by keratinized non-cellular material, skeletal muscles ,associated with few fibrocytes (with collagen fibers) intermingled with skeletal muscles .(anterior part of the tongue). (H&E staining,100X)

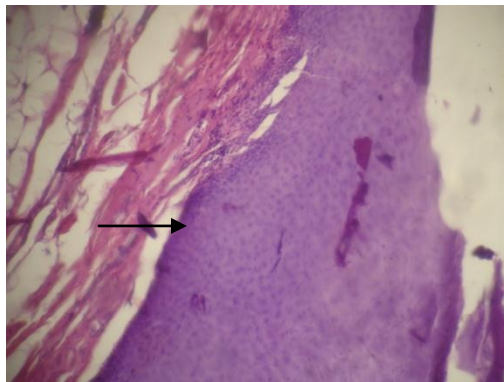


Fig (6): thickened stratified squamous epithelium (more cellular than anterior part) at the base of lamina propria ; skeletal muscles intermingled with fibrocytes contains collagen fibers.(middle part of the tongue). (H&E staining,100X)

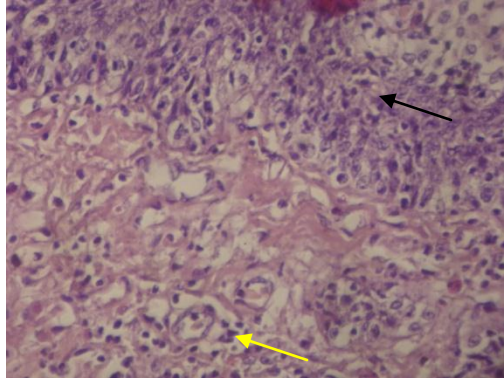


Fig (7): Vacuolated stratified squamous epithelial cells (yellow arrow) associated with infiltration of heterophils .(posterior part of the tongue). (H&E staining ,400X)

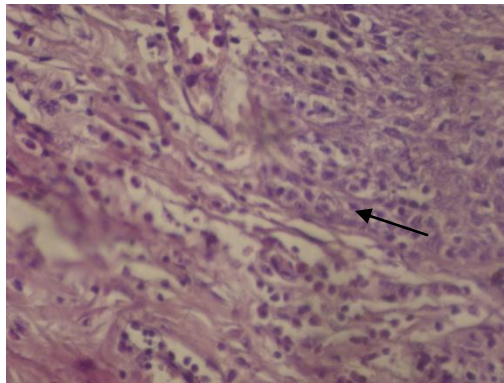


Fig (8): moderate glossitis mostly characterized by heavy infiltration of heterophils with vacuolated squamous epithelial cells.(posterior part of the tongue). (H&E staining, 400X)

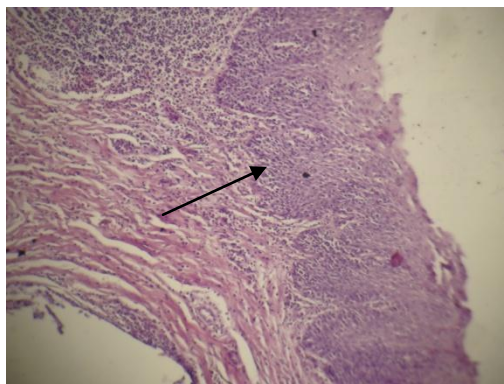


Fig (9): showing folded stratified squamous epithelium with crypt formation associated with infiltration of heterophils, note lamina propria rich in skeletal muscles .(posterior part of the tongue). (H&E staining, 100X)

Discussion

It appeared to be the first case of glossitis reported in wild goose .it is possible that the tongue could be injured during feeding, as it is normally used as knife to cut grass and plant materials, which the goose live on them, then this could be followed by contamination with bacterial or other microbial agent which later included inflammation as what appeared in the present case. As the case is very rare hardly any previous work was reported as glossitis in goose /geese.

Glossitis could be found as routine pediatric dentistry which discovered on routine clinical examination as a symptomatic glossitis in two children with oral pain which was affecting daily activity, eating and sleeping. The lesions appeared as ulcer in which the filiform papillae were denuded, treated with topical and systemic antihistamine (4) the above report could be compared with present case, as the glossitis also present in the dorsum of the tongue, but there is no ulceration.

While (6) described the development and inflammatory features of radiotherapy induced glossitis in rat, the report showed that at the beginning there was no clinical lesion but later there was evidence of glossitis, with ulceration, late signs of healing and growth of new epithelium was noted .The above case, showed some similarities with the present case as there was glossitis but no ulceration, and also healing process in this case appeared as multiple keratinized layers with some evidences of fibrosis , the goose in the present case showed more proliferation and keratinization of the epidermal layer than in the rat.

A case reported by (7) as oral manifestation of vitamin , B₁₂ deficiency causing megalaplastic anemia, clinically giving rise to glossitis with associated oral ulceration. Possibility of vitamin deficiency in the present case could not be excluded completely and therefore it could be compared with incidence of glossitis induced by vitamin B₁₂ deficiency.

Furthermore (5) presented a case of glossitis and tongue trauma subsequent to administration of an oral medication using udder infusion cannula in a horse, the case of ten years old gelding showed a tongue that had swelled immediately after oral administration of oxafendazole using an udder infusion cannula, the tongue appeared to have been punctured . The horse was recovered after treatment with intravenous fluid , antibiotics and anti-inflammatory drugs.

The trauma in the tongue of horse by (5) causing glossitis that could be compared with the present case as the glossitis in the goose could be traumatic due to sharp object during feeding, as the goose was not in the wild but was cared by a family.

Finally, the only report on the goose was in press by (2), in which they reported the histological structure of goose tongue.

Conclusion

It appeared to be the first case to be published of case of glossitis in goose, the case showed varying degrees of lingual changes, as areas of glossitis with infiltration of hetrophils, then other areas which could be a manifestation of healing characterized by proliferation and hyperkeratinization of the epithelial layer, also some areas of fibrosis and collagen fibers formation.

It pointed out that the healing process in case of glossitis in goose, mostly manifested by proliferation and keratinization of newly formed epithelial layer to replace the damaged epidermis, with no evidence that fibrosis plays a big role in healing.

References

- 1-Hassan SM, Moussa EA, Cartwright AL .2010. Variations by Sex in Anatomical and Morphological Features of the Tongue of Egyptian Goose (*Alopochen aegyptiacus*). J. of cell tissue organs . 191(2):161-165.
- 2-Saleh,K.Majeed ; Alaa ,H.Saadon ; Samira , A. Daaje.2011. Morphological , Anatomical and Histological studies on goose tongue.science jornal for scientific research: In press 2011.
- 3- David Zieve, Greg Juhn ; David R. Eltz.2009. Previously reviewed by James L. Demetroulakos, MD, FACS, Department of Otolaryngology, North Shore Medical Center, Salem, MA. Clinical Instructor in Otology and Laryngology, Harvard Medical School. VeriMed Healthcare Network .
- 4- Michael J. Sigal, Dip Paed, David Mock.1992. Symptomatic benign migratory glossitis: report of two cases and literature review. *Pediatr Dent* 14:392-396.
- 5- Mark C Fuller, Sameeh M Abutarbush.2007. Glossitis and tongue trauma subsequent to administration of an oral medication, using an udder infusion cannula. *The Canadian veterinary journal*. 48(8):845-7.
- 6- Chun-Yang Li, Xiao-Hua Chen, Xiao-An Tao, Juan Xia, Bin Cheng.2010. The development and inflammatory features of radiotherapy-induced glossitis in rats. *Review Med Oral Patol Oral Cir Bucal* .In press 2010.
- 7- Hélder Antônio Rebelo Pontes, Karen Bechara Ferreira, Flavia Sirotheau Corrêa Pontes, Décio dos Santos Pinto Jr.2009._Oral Manifestations of Vitamin B₁₂ Deficiency.*JCDA*.Vol 75.No. 7.

Recived (9/6 /2010)

Accepted (24/8/2010)