

The histological and hormonal changes that occur on reproductive system and pregnancy in adult albino mice after treatment of tramadol

Assist lecture Noor Noori Abid AL-Shemary

Department of Pathological Analysis- Kut Technical Institute / Middle Technical University-Iraq

م.م نور نوري عبد الشمري قسم التحليلات المرضية المعهد التقني كوت/ الجامعة التقنية الوسطى

المستخلص

الترامال ماده مصنعه فعاله تستخدم كمسكن للألم على نطاق واسع. الهدف من البحث لغرض تلخيص التغييرات الهستولوجية على الجهاز التناسلي الذكري (الخصى) والجهاز التناسلي الانثوي (المبايض والارحام) والهرمونات للفئران البالغة. اربعون فأراً (ذكور وإناث) تزن تقريبا حوالي 25-30 غم استخدمت في الدراسة الحالية. قسمت الحيوانات الى مجموعتين (20 حيوان لكل مجموعة) المجموعة الاولى (السيطرة) التي تم حقنه عضليا بالماء المقطر وبشكل يومي ، والمجموعة الثانية اعطيت عقار الترامال عن طريق الحقن العضلي وبشكل يومي وبجرعه 25ملغم/كغم /اليوم لمدة ستون يوما. وفي نهاية التجربة قتلت الحيوانات واخذت الاعضاء التناسلية (الخصى الارحام و المبايض) وحفظت بالفورمالين بتركيز 10% لغرض التحضير النسيجي. جمعت عينه الدم بواسطه الطعن بالقلب لغرض قياس مستوى الهرمونات الجنسية الذكرية والانثوية. أظهرت النتائج للهرمونات انخفاض معنوي كبير في مستوى الهرمون التيستوستيرون وزيادة معنويه كبيره في مستوى هرمون البرولاكتين وانخفاض معنوي في مستوى المحفز للجريب والهرمون اللوتيني بينما اظهرت النتائج للهرمونات الأنثوية انخفاض معنوي في مستوى الهرمونات المحفز للجريب والهرمون اللوتيني والبروجيسترون وانخفاض معنوي كبير في مستوى الاستروجين. وظهر الفحص النسيجي للمبيض تضرر الحوصلة النامية وتحطم الحوصلة الكيسية واضمحلال بطانة الرحم وتضرر النبيبات المنوية للخصية .

Abstract

Tramadol is a centrally active synthetic opioid analgesic that is used extensively. The present research conducted to outline the histological changes on reproductive system (ovaries and uterus of females and testis of male) and hormonal status of mature albino mice . Fourty mice (male and female) weighing approximately 25-30g were used in the present study. Animals were divided into two groups control male and females (n=20) and tramadol treatment male and female group (n=20). Applied tramadol doses 25mg /Kg/day were daily injected intramuscular for 60 days. At the end of treatment, the animals were sacrificed and their ovary, uterus and testis were incised and fixed in 10% formalin for histological investigation .The blood sample were collected for measure hormonal levels (sex hormones) of both sex. The results of males hormones levels showing highly significant reduce in the level of testosterone and highly significant increase in the level of prolactin hormone while (FSH and LH) showed significant decrease as compared with control group. The result of female hormones levels showed a highly significant reduce in the level of Estradiol and significant decrease in the level of (FSH and LH) hormones as compared with control group. The histological section of ovary showing damage of growing follicles, increase cellularity of stroma, cystic follicle degeneration. There were hypertrophied endometrium glands , atrophic endometrium lining of uterus, testis possessed disorganization of the seminiferous tubules with inflammatory cells, degenerative change in germ cell with vacuolated epithelium.

The author concluded that tramadol reduced the fertility of both male and female
Key words; Tramadol, Testis, Ovary, Uterus, Males and Females albino mice.

Introduction

Tramadol is a centrally active synthetic opioid analgesic that is used specially. It was first introduced in 1977 in Germany [1]. The mechanism of action is not completely understood, are binding to mu opioid receptors (MOR) and inhibition of reuptake of noradrenaline and serotonin [2] by stimulating releasing of 5-hydroxytryptamine. The drug exerted hypoglycemia in users[3] which effect on growth hormone (GH) secretion. GH deficiency has a hypothalamic rather than pituitary origin [4]. Tramadol toxicity include central nervous system depression ,nausea, vomiting, tachycardia and seizures [5]. Fatal cases have been reported as a result of tramadol overdose. In these cases, death has been result due to cardiopulmonary arrest and hepatic failure, In addition hypoglycemia [6,7].

Tramadol prescribed for acute and chronic pain of moderate to osteoarthritis fibromyalgia,diabetic, neuropathy, neuropathic pain, and even perioperative pain in human patients [8,9]. Also, tramadol is the primary drugs used in the treatment of opiate addict. Opiates cause loss of libido and erectile and ejaculatory dysfunctions among men [10]. Opiate abuse may result in hypogonadism, primarily by decrease in liberate of gonadotropin-releasing hormone (GnRH), testosterone deficiency and infertility [11,12]. Several research have indicated that long time treatment of opiate compounds had harmful effects on sperm cell motility and morphology [13], long used opiate increases DNA damage in sperm in male rats [14]. Oxidative stress induced by opiate exposure is a significant factor in the etiology of male infertility and lead to an increased DNA fragmentation [13]. In addition to the potential adverse effects of opiate on male fertility, the current study investigates the epididymis.

sperm quality and testicular tissue damages following long term treatment of tramadol in male mice [15]. Tramadol is absorbed rapidly in the small intestine and reached highest peak after 5 hours [16]. One of the active metabolites of tramadol, and the product of oxidation by the hepatic enzyme cytochrome P450, is O-dimethyl- tramadol, which is two- to fourfold more potent than tramadol including the opioid activity [17, 18]. The aim of research to detect the effect of tramadol on male and female reproductive system in adult albino mice.

Material and methods.

Animal, dosing and experimental design:- fourty Swiss albino mice (males and females) were obtained from animal house at kut technical institutes .The body weight of its animal is about 25-30g and age 10 weeks. The mice kept in plastic cage and left 10 days for naturalized before experimental and maintained at room temperature about (22-25C) and light(12 h light; 12h dark) .The animals were fed with pellet. After that the animal were left for mating (1male +3females). The animal were divided into two groups : control groups male +female (n=20) injected 1ml/day distill water intramuscular for 60day and group tramadol treatment male +female (n=20) injected 25mg/kg/day for 60 days. After 60 days of treatment the animals were killed by cervical dislocation and the blood sample were collected in dry centrifuge tube for serum preparation , sera were separated and preserved at -20°C to detect sexual hormone level (FSH, LH, prolactin and testosterone). After that the ovaries, uterus and testis were incised and kept in 10% formalin (pH 7.4) for routine histological investigation.

Table (1) :Effect of tramadol (25mg/kg/day) for 60 days on sex hormones (Testosterone, FSH,LH and prolactin levels in male mice.

Variable Groups	Testosterone pg/ml	FSH mIU/ml	LH mIU/ml	Prolactin mIU/ml
Control	3.64±0.08 ^a	1.58± 0.0	1.35± 0.00	4.60±0.53
Treated	1.83±0.0 A	0.58±0.0 A	0.76±0.1 a	15.90±1.10 A

Values= mean ± SE

P<0.05 from control group significantly different

P<0.0001 highly significantly different from control group

(A)Represent highly significant
,(a) Represent significant

2-Sex hormones of adult female mice .

The results in the table (2) shows a highly significant P<0.001 decrease in the level of estradiol from control group .Whereas the level of FSH ,LH, progesterone show significantly decrease P<0.05 decrease from control group.

Table (2) :Effect of tramadol(25mg/kg/day) for 60 days on sex hormone levels (Estrogen, FSH,LH and progesterone in females mice.

Variable Group	Estradiol pg /ml	Progesterone pg /ml	FSH mIU/ml	LH mIU/ml
Control	9.40±1.262	0.26±0.01	3.40± 0.075	24±0.263
Treated	6.25±0.363 A	0.11±0.004 A	2.19±0.042 a	4.21±0.131 a

Values= mean ± SE

P<0.05 significant different from control group

P<0.0001 highly significantly different from control group

(A)Represent highly significant ,(a) Represent significant

Drug: The chemical name is cis-2 dimethylamino) methyl]-1-(3- methoxypheny cyclohexanol). Tramal (Tramadol HCl), ampule 50 mg/ml, were suspended in normal saline and was obtained from Al-khadra pharmacy at kut.

Histological investigations: Testis, ovaries and uterus of both control and experimental groups were incised immediately fixed in 10% phosphate buffered formalin (pH 7.4) dehydrated in ascending grades of ethyl alcohol, cleared in xylene and mounted in molten paraplast 58-62°C Serial 5 µm thick sections were cut and stained with Haematoxylin and eosin (H&E), examined under bright field light microscopy, and photographed [19].

Statistical analysis.

Data from treated and control groups were expressed as mean ± standard error(SEM) and analyzed using students t-test to compare values from experimental and control groups at individual time points. Differences between were considered significant at p<0. 05 and highly significant at p<0.001.

Results

1.Sex hormones of adult males mice.

The results in the table (1) shows a highly significant P<0.001 different in the level of testosterone and prolactin from control group. Whereas the level of FSH and LH show significantly P<0.05 different from control group

Table 3: Frequency of pregnant mice in controlled and treated.

Sample	Pregnancy		Total
	<i>Present</i>	<i>Abscent</i>	
Controlled	9	1	10
Treated	4	6	10
	13	7	20

Odd Ratio 13.5, Fisher Exact test: p-value 0.03, sig. <0.05

2-Frequency of pregnant mice in controlled and treated group.

The results in the table (3) indicated that 9 of 10 in controlled were pregnant, while, 4 of 10 in treated mice were. Pregnant (Odds Ratio) 13.5, p-value <0.05) Number of fetus were twofold in control than treated (42/9 and 12/4 respectively), fetus ratio 2:1.

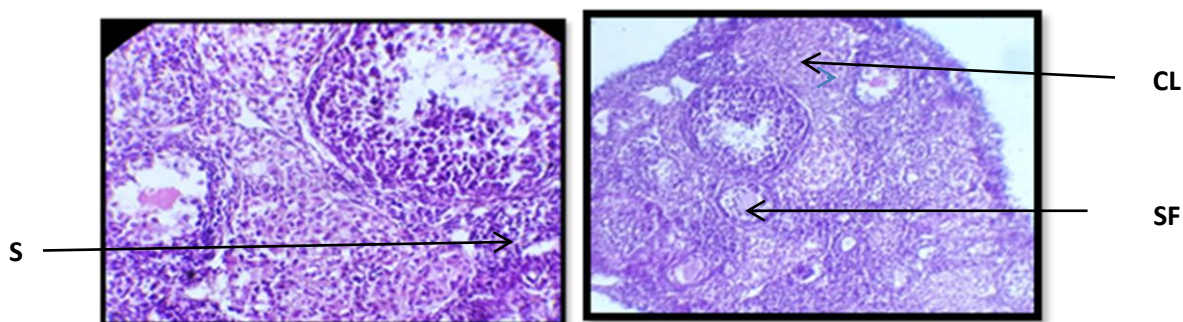


Figure1:.. photomicrographs of histological sections ovary (control group) in mice showing different stage of growing secondary follicles(SF), germinal epithelium, corpus luteum (CL)and stroma(S). (H&E)

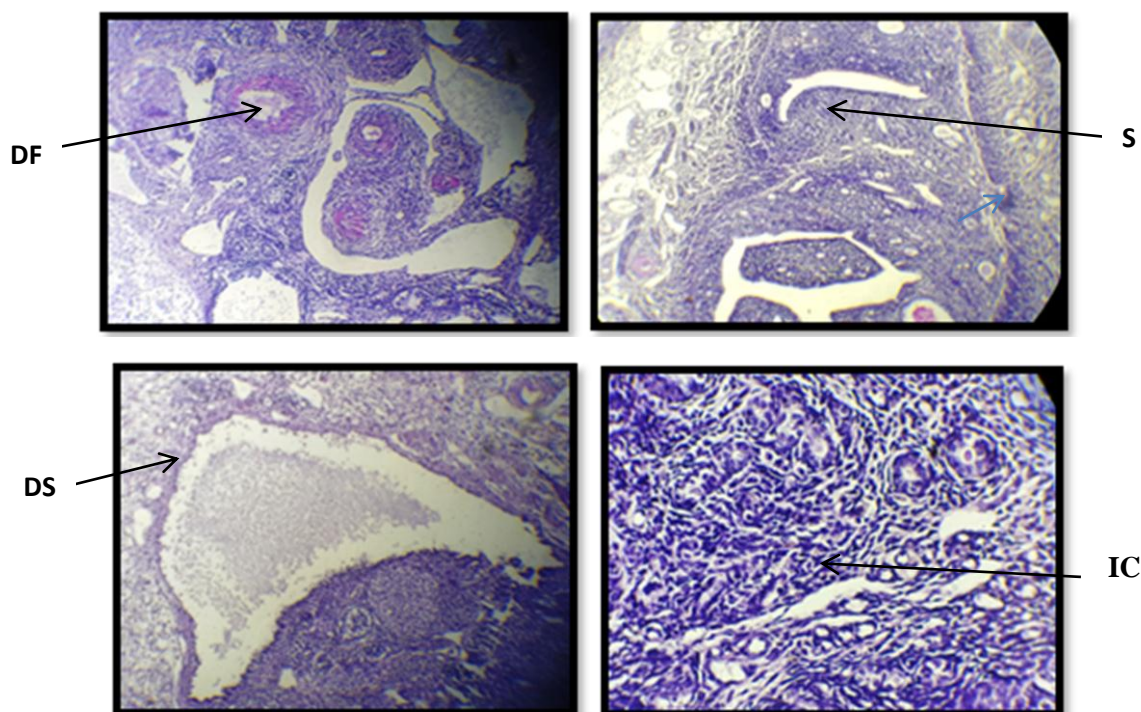


Figure2:.. photomicrographs of histological sections of tramadol (25mg/kg/day for 60 days) treated ovary of mice showing degenerative changes of ovarian stroma (DS), damage of growing follicles(DF), increase cellularity of stroma(S), inflammatory cells (IC). (H&E).

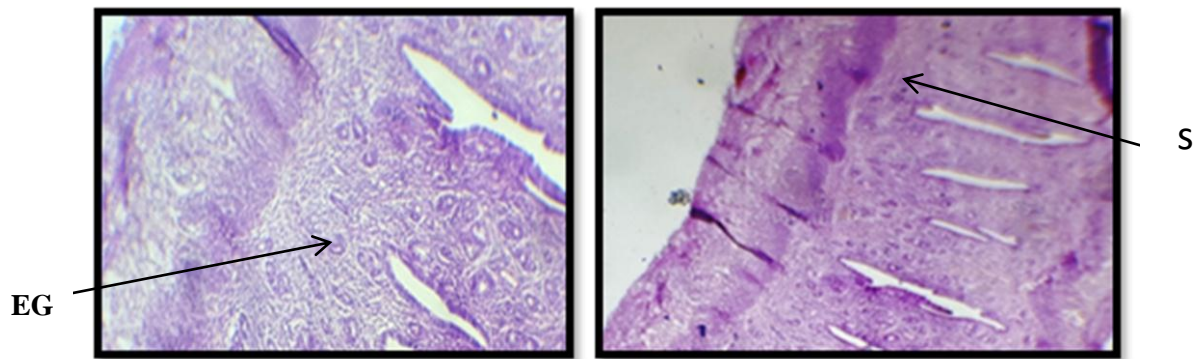


Figure3: photomicrographs of histological section of uterus (control group) in mice showing normal structure of Stroma (S) and endometrium glands(EG) of uterus (H&E)

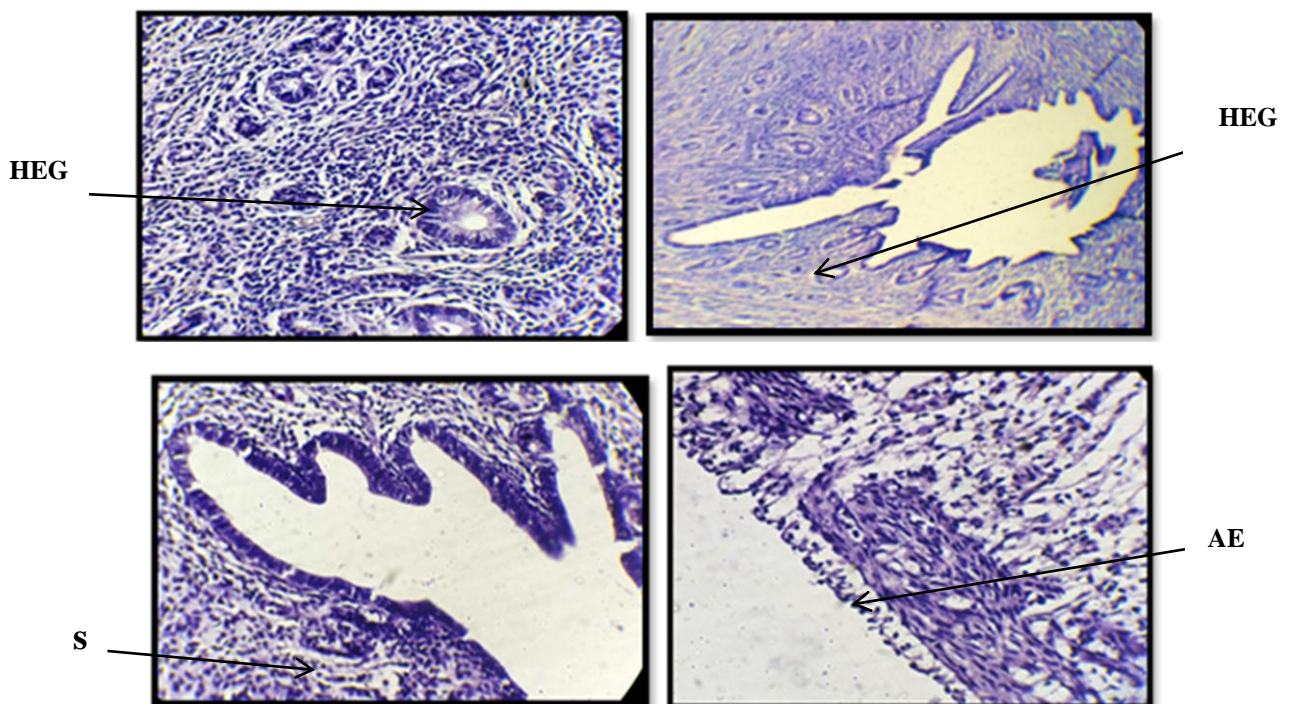


Figure 4 : photomicrographs of histological sections of tramadol(25mg/kg/day for 60 days) treated uterus in mice showing hypertrophied endometrium glands(HEG) , increased cellularity of stroma(S). atrophic endometrium lining(AE) of uterus (H&E)

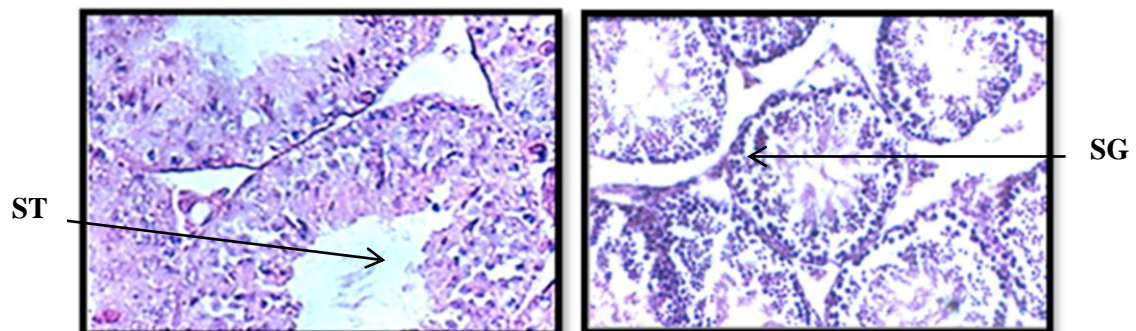


Figure5:.. photomicrographs of histological sections of testis (control group) showing normal seminiferous tubules (ST);normal arrangement of Spermatogenic cells (SG). (H&E).

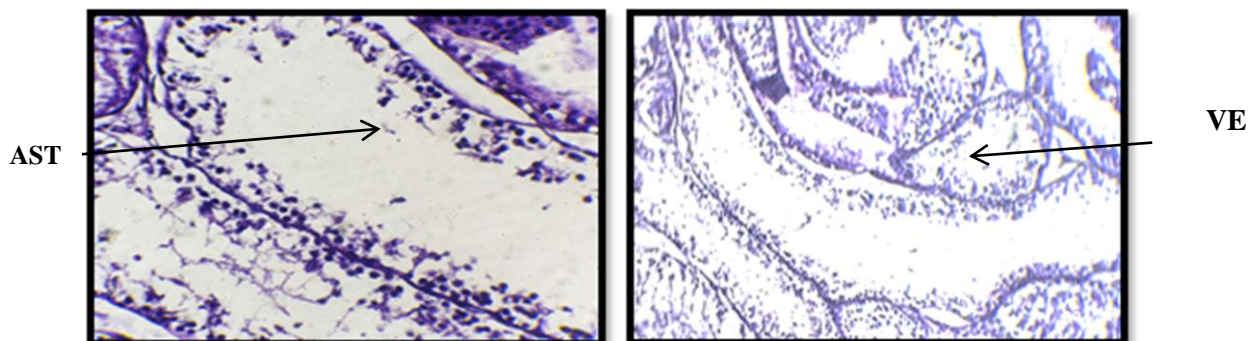


Figure 4 :- photomicrographs of histological sections of tramadol(25mg/kg/day for 60 days) treated testis in mice showing inflammatory cells, degenerative change in germ cell with vacuolated epithelium(VE) and atrophy of seminiferous tubules(ST).(H&E)

Discussion

Tramadol is a centrally acting opioid analgesic which is mainly used for the treatment of moderate to severe pain [20] . Opioid (Tramadol) have the main side effect on reproductive system in both sex (hypogonadism) [21]. The our study show significant association between tramadol administration and lowered plasma levels of sex hormone in both sexes. The result in the table (1) showed a significant decrease in the level of testosterone, LH, FSH and increased level of prolactin in both sex of mice. The decreased in the levels LH and FSH due to the effect of opioid on gonadotropin –releasing hormone (GnRH) through the increased level of prolactin ,due to testosterone synthesis could be directly inhibited [22]. The results suggest that tramadol might affect testosterone release through the hypothalamus hypophyseal – gonadal axis[23,24] the present results in

agreement with Tennese and Wevrick [2011][25] who reported decreased levels of LH and testosterone with increased prolactin hormone after morphine and methadone administration.

The study demonstrated that tramadol administration in mice cause diminished both pituitary sex hormones; LH and FSH. [26]. It's well established that opioids decrease the release of GnRH or interfere with its normal pulsatile at the level of the hypothalamus, resulting in a decreased release of LH and FSH from the pituitary and a secondary fall in gonadal steroid production [27], lead to decreased gonadal hormones estrogen and progesterone. These results in a good agreements with several reports of the inhibitory effects of morphine on ovulation in rats [28, 29] and with opioid mediated inhibition of gonadotropin release and decreases in circulating reproductive

hormones [30]. This effect is attributed to the previously mentioned fall on LH and FSH because opioid receptors have also been localized in ovarian tissue and opioid have been shown to directly suppress ovarian steroid production [31].

The histological section of ovary showed deterioration of ovarian follicles , cystic follicles and ovarian stroma showed marked increase of hypercellularity. This depletion was found to be associated with impaired ovarian function as measured by the number of oocyte ovulated and the duration of the subsequent estrous cycle. The ovarian dysfunction was confirmed by massive atrophy and decreased secretory function of the endometrial glands. The observed ovarian damage was supported by flowcytometric analysis which indicated increased average of apoptosis(28). The present study in agree with recent studies carried out by Ahmed and Kurkar (31) who reported that rats received subcutaneous injections of tramadol (40mg/kg body weight) three time per week for 8 weeks was found to reduced plasma levels of luteinizing hormone, follicle-stimulating hormone .

The histological section of uterus show hypertrophied endometrium glands , increased cellularity of stroma, atrophic of endometrium lining of uterus because Tramadol caused inhibition of potassium chloride -induced myometrium contractility

[32]. Estradiol responsible for increase cell density and stimulate of cell proliferation of uterus. However, tramadol effect on estrogen levels caused inhibition of uterine cell proliferation which was mediated mainly by the mu opiate receptor [33].

The histological section of testis showed

The histological section of testis showed inflammatory cells, degenerative change in germ cell with vacuolated epithelium and atrophy of seminiferous tubules these changes may attributed to many reason to the oxidative damaging effect of free radicals so that the testicular cells and sperms contain abundant polyunsaturated fatty acids in their plasma membranes; because lipid peroxidation induced by tramadol lead to dysfunction and structural damage of cells .They explained this testicular change by disorders in the endocrine and paracrine functions through disordered LH, somatotropin, somatostatin In addition tramadol induced reduction of serum testosterone prolactin and GnRH (gonadotropin-releasing hormone) that acted on the hypothalamus or directly on pituitary glands which cause abnormal structural and functional abnormalities of the secondary sex organs[34,35].

References

- 1.Osterloh, G. ; Friderichs, E. ; Felgenhauer, F. ; Gunzler, W. ; AHenmi, Z. ; Kitano, T. ; Nakamura, M. ; Hayashi, H. ; Ishii ,I.(1978).General pharmacological studies on tramadol a potent analgesic agent. *Arzenmittle - Forschung* 28:135-151.
- 2.Raffa, R.B. ; Friderichs, E. ; Reimann, W. Shank, R.P. ; Codd, E. E. ; Vaught, J.L. (1992). *Pharmacol Exp:Ther.*260-275
- 3.Grandvuillemin, A. ; Jolimoy, G. ; Authier, F. Dautriche. ; A.C.(2006). *Presse Med.* 35:1842
- 4.Tennese, A.A. and Wevrick, R.(1978). *Endocrinology* 152(3) 967 .
- 5.Spiller, H.A. ; Gorman, S.E. ; Benson, B.E. ; Anderson, D.L. (1997).*Clin Toxicol.*
6. Daubin, C. ; Quentin, C. ; Goulle, J.P. ; Guillotin, D. ; Lehoux, P. ; Lepage, O(2007). *ClinToxicol (Phila)* 45:961.
- 7.Mugunthan, N. and Davoren, P. (2012). *Endocrine pract.*18,151.
- 8.Collart, L. ; Luthy, C. ; Dayer, P.(1993). Multimodal analgesic effect of tramadol. *Clin Pharmacol Ther* 53:223.
- 9.Lamont, L. A. and Mathews, K. A.(2007). Opioids, nonsteroidal anti-inflammatories and analgesic adjuvants in Lumb and Jones. *Veterinary anesthesia and analgesia*, 4th Ed.Blackwell Publishing, Iowa: 264.
- 10.Deglon, J. J. and MJaIR, (2004). Methadone patients' sexual dysfunctions, *Clinical and treatment issues. Rel Clin Probl;* 6(3):17-26.
- 11.Vuong, C. ; Uum, S. H.; Odell, L.E. ; Lutfy, K. ; Friedman, T.C.(2010). The effects of opioids and opioid analogs on animal and human endocrine systems. *Endocrine Rev* 31:98-132
- 12 .Bliesener, N. ; Albrecht, S. ; Schwager, A. ; KLichter mann, D. ; Klingmuller, D.(2005). Plasma testosterone and sexual function in men receiving buprenorphine maintenance for opioid dependence *clin endocrinol metab;* 90(1):203-206.
- 13.Cacciola, G. ; Chioccarelli, T. ; Ricci, G. ; Meccariello, R. ; Fasano, S. ; Pierantoni, R. (2008).The endocannabinoid system in vertebrate male reproduction: a comparative overview *MolCell Endocrinol;* 286:24–30
- 14.Barenys, M. ; Macia, N. ; Camps, L. ; Lapuente, J. ; GomezCatalan, J. ; Linares, J.(2009).Chronic exposure to MDMA (ecstasy) increases DNA damage in sperm and alters testes histopathology in male rats. *Toxicol Lett;* 191:40-6
- 15.Pasqualotto, F. F. ; Sharma, R. K. ; Nelson, D. R. ; Thomas, A. (2000).semen characteristics and clinical diagnosis in men undergoing infertility investigation. *Fertil-Steril.*73:459- 64
- 16.Lintz, W.; Erlaçin, S. ; Frankus, E . Uragg, H.(1981). *Drug Res.*
- 17.Tao, Q. ; Stone, D.J. ; Borenstein, M.R. ; Codd, E.E. ; (2002). Differential tramadol and O-desmethymet-

- abolitelevels in brain vs plasma of mice and rats administered tramadol hydrochl-
orideorally J. Clin. Pharm. Ther. 27: 99–
106.
- 18.Grond, S. and Sablotzki, A.(2004).
Clinical pharmacology of treatment. Clin
Pharmacokinetics. 43(3): 879–923 .
20. Bancroft, J.D and Gamble, M. (2002)
Theory and practice histological
techniques, 5th ed., Churchill living
stone New York, Edinburgh and London.
Pp:126-175.
- 19.Bancroft, J.D and Gamble, M. (2002).
Theory and practice histological techniques
5th ed., Churchill living stone New York,
Edinburgh and London. Pp.126-175
- 20.Rasor, J. and Harris, G. (2005). Opioid
use for moderate to severe pain. Assoc. 105:
2–7 .
- 21.Marwa, A. and Adel, K.(2014). Effects of
opioid (tramadol) treatment on testicular
functions in adult male rats. Clinical and
Experimental Pharmacology and Physiology
41, 317–323 .
- 22.Bliesener, N. ; Albrecht, S. ; Schwager, A.
; Weckbecker, K. ; Lichtermann, D. ;
Klingmüller, D. (2005). Plasma testosterone
and sexual function in men receiving
buprenorphine maintenance for opioid
dependence. J. Clin Endocrinol. Metab. 90(1):
203–6
23. El-Gaafarawi, I.I. (2006). Biochemical
toxicity induced by tramadol administration
in male rats. Egypt. J. Hosp Med23: 353–62.
24. Tennesse, A.A. and Wevrick, R. (2011).
Impaired hypothalamic regulation of
endocrine function and delayed counter
regulatory response to hypoglycemia in
Magel2-null mice. Endocrinology 152: 967-
978.
- 25.Behrman, H.R. ; Kodaman, P.H. ;
Preston S.L. ; Gao, S. (2001). Oxidative
stress and the ovary. Gynecol Investig. 8:
40-42. .
- 26.Katz, N. and Mazer, N.A. (2009). The
impact of opioids on the endocrine system.
The Clinical journal of pain 25(2) 170-175.
- 27.Packman PM, Rothchild JA (1976):
Morphine inhibition of ovulation: reversal
by naloxone. Endocrinology, 99(1), 7-10.
28. Howlett, T.A. and Rees, L.H. (1986).
Endogenous opioid peptides and
hypothalamo-pituitary function. Ann Rev
Physiol 48:527–536
- 30.Kaminski, T. (2006). The .
involvement of protein kinases in
signalling of opioid agonist FK 33-824 in
porcine granulosa cells. Animal
reproduction science, 91(1), 107-122
- 31.Ahmed, A.M. and Kurkar, A.(2014).
Cline Exp pharmacol physiol 41(4),317.
- 32.Shah, N.H. ; Thomas, E. ; Jose, R. ;
Peedicayil, J.(2013). Autacoid
Pharmacol. 33(1-2).
- 33.Kaminski, T. (2006). The involvement
of protein kinases in signalling of opioid
agonist FK 33-824 in porcine granulosa
cells. Animal reproduction science, 91(1),
107-122. .
- 34.Kornyei, J.L. ; Vertes, Z. ; Oszter, A. ;
Kovacs, S. ; Vertes, M.(1997). Eur
pharmacol.336(1) 65.
35. Abou El Fatoh MF, Farag M, Sayed
AE, Kamel MA, Nora E .(2014)
pharmacotoxicological and
histopathological alterations induced by
long-term administration of tramadol in
male rats. Int J Pharm Sci 4565–571.

